PROC (BAYL UNIV MED CENT)
2020;33(3):455–456
Copyright © 2020 Baylor University Medical Center
https://doi.org/10.1080/08998280.2020.1759334

Taylor & Francis
Taylor & Francis Group

HeartMate 3 left ventricular assist device implant after excision of a large apical aneurysm

Themistokles Chamogeorgakis, MD[a], Konstantinos Kostopanagiotou, MD[b], Allison Behler, RN[a], and Dimitrios Apostolou, MD[a]

[a]Division of Cardiac Surgery, Henry Ford Hospital, Detroit, Michigan; [b]Attikon University Hospital, Athens, Greece

ABSTRACT

The presence of a left ventricular apical aneurysm may pose a technical challenge during implantation of a left ventricular assist device (LVAD). We describe implantation of a HeartMate III LVAD under cardioplegic arrest. A ventricular aneurysmectomy was performed and the LVAD was implanted at the left ventricular apex at the level of the transition zone between the scar tissue and the viable myocardium. Two pursestring 2-0 Prolene Fontan sutures were placed circumferentially at the transition zone to make up for the size discrepancy between the left ventricular opening and the HeartMate 3 pump. The echocardiographic analysis demonstrated optimal inflow cannula orientation, and the patient had an uneventful recovery.

KEYWORDS Left ventricular aneurysm; ventricular assist device

The introduction of new-generation centrifugal left ventricular assist device (LVAD) pumps has revolutionized the treatment of heart failure patients.[1] The presence of a left ventricular apical aneurysm may pose a technical challenge during the LVAD implant. We describe the implantation technique of a HeartMate III LVAD (Abbott, Abbott Park, IL) in an inotrope-dependent patient with ischemic cardiomyopathy and a large left ventricular aneurysm; the patient was not a transplant candidate due to a recent history of malignancy.

TECHNIQUE

After induction of general anesthesia, transesophageal echocardiographic analysis confirmed the presence of a large left ventricular aneurysm with organized clot and a left ventricular cavity of adequate size to accommodate the HeartMate III LVAD inflow cannula. Cardiopulmonary bypass was initiated through a median sternotomy approach with an aortic cannula and bicaval venous cannulation for optimal venous drainage. Cardioplegic arrest was accomplished with cardioplegic solution infusion in the aortic root. The aneurysmal sac was opened *(Figure 1a)*. A large amount of organized thrombus was extracted from the aneurysm. The aneurysm was excised and the transition zone between the scar and the viable myocardial muscle was identified. The left ventricular opening at the level of the transition zone was larger than the LVAD ring. Two pursestring 2-0 Prolene Fontan sutures were placed circumferentially at the transition zone, and the HeartMate III apical ring was sutured with multiple circumferential pledgeted sutures at the same level. The LVAD pump was secured to the ring and the two Fontan stitches were tied to make up for the size discrepancy between the left ventricular opening and the pump *(Figure 1b)*. The outflow graft anastomosis was constructed at the ascending aorta. The aortic root and the left ventricle were carefully inspected to ensure no clot was present. The patient was weaned off cardiopulmonary bypass. Transesophageal echocardiographic analysis confirmed good inflow cannula alignment *(Figure 2)*. The speed was started at 3000 rpm and was gradually increased to 5300 rpm the first postoperative day *(Table 1)*.

Postoperatively, the patient was neurologically intact, did not have any suction events, and was discharged from the hospital with optimal LVAD parameters; he is alive on LVAD support 9 months after the LVAD implant and is free from stroke, gastrointestinal bleeding, and driveline infection. His serum lactate dehydrogenase was 322 IU/L on postoperative day 30 and decreased to 216 IU/L 3 months after the LVAD implant. Follow-up echocardiogram 3

Corresponding author: Themistokles Chamogeorgakis, MD, Division of Cardiac Surgery, Henry Ford Hospital, 2799 West Grand Blvd., Detroit, MI 48202 (e-mail: tchamog1@hfhs.org)
Received February 14, 2020; Revised April 16, 2020; Accepted April 20, 2020.

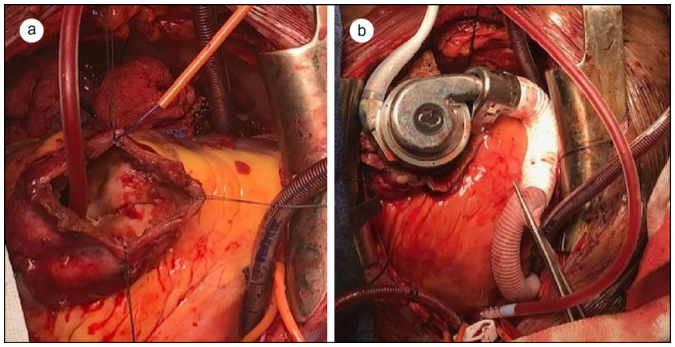

Figure 1. Operative pictures. **(a)** Opening of the aneurysmal sac. **(b)** Use of Fontan stitches to make up for the size discrepancy between the left ventricular opening and the pump.

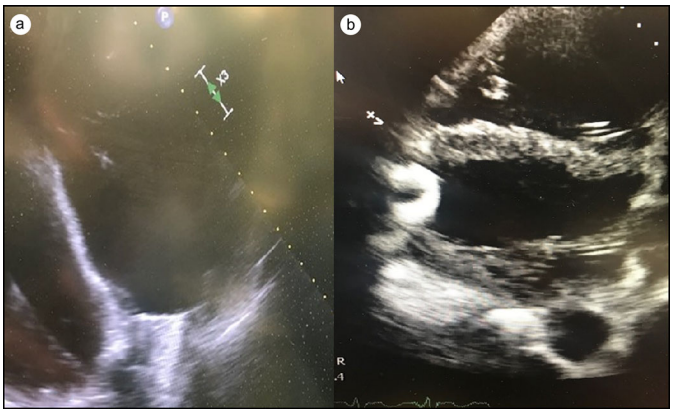

Figure 2. Echocardiograms **(a)** intraoperatively and **(b)** on the day of discharge.

Table 1. Left ventricular assist device parameters at different time intervals postoperatively

Time	Flow (L/min)	Speed (rpm)	Pulsatility index	Power (watts)
Postoperative day 1	4.2	5300	4.7	3.6
Postoperative day 2	4.4	5300	3.4	3.7
Discharge	4.2	5300	3.2	3.8
Postoperative day 30	4.4	5500	3.2	4.1

months after discharge demonstrated absence of thrombus in the left ventricular cavity with good inflow cannula alignment and neutral interventricular septal position.

DISCUSSION

Surgical left ventricular restoration improves ventricular function and is effective therapy for ischemic cardiomyopathy.[2] Our patient was not a candidate for ventricular restoration due to severely compromised left ventricular function. Left ventricular aneurysmectomy was indicated for two reasons: (a) the thin scar wall of the aneurysm was highly mobile during the cardiac cycle and the hemodynamic performance of the LVAD was unpredictable, with suction events very likely to occur postoperatively; and (b) de novo formation of clot in the aneurysm can cause LVAD thrombosis and cardioembolic adverse events.

The heavy load presence of organized clot in the left ventricle is an independent risk factor of perioperative stroke. Conducting the procedure under cardioplegic arrest minimized the risk of clot dislodgement during surgical manipulations and cardiac contractions and minimized the risk of cardioembolic stroke.

The left ventricular opening was larger than the LVAD sewing ring. We compensated for the size mismatch with the two Fontan stitches that were tied snug when the ring was sutured and the pump secured. A similar technique has been described for a HeartWare LVAD (Medtronic, Minneapolis, MN) implant in a patient with a left ventricular aneurysm.[3] Alternatively, a Dor procedure has been described with patch ventriculoplasty and HeartMate II LVAD implant with interposition tube graft in more complex anatomy, when the inflow cannula is anticipated to be in close proximity to the mitral valve annulus.[4] The shorter inflow cannula of the two centrifugal LVADs most commonly used in the USA (HeartMate III and HeartWare) avoids this problem. Small apical aneurysms during LVAD implant can be incorporated in the left ventricular apical coring.[5]

We believe the HeartMate III LVAD implant technique described is feasible and reproducible for patients with end-stage ischemic cardiomyopathy and large apical ventricular aneurysms, if the ventricular cavity is large enough to accommodate the LVAD inflow cannula when ventricular surgical restoration or heart transplant is not an option.

1. Mehra MR, Goldstein DJ. Magnetically levitated cardiac pump at 2 years. *N Engl J Med*. 2018;379(9):897. doi:10.1056/NEJMc1809738.
2. Athanasuleas CL, Buckberg GD, Stanley AW, et al; RESTORE group. Surgical ventricular restoration in the treatment of congestive heart failure due to post-infarction ventricular dilation. *J Am Coll Cardiol*. 2004;44(7):1439–1445. doi:10.1016/j.jacc.2004.07.017.
3. Palmen M, Verwey HF, Haeck ML, Holman ER, Schalij MJ, Klautz RJ. Implantation of a left ventricular assist device in patients with a complex apical anatomy. *Ann Thorac Surg*. 2012;94(6):2122–2125. doi:10.1016/j.athoracsur.2012.05.036.
4. Garbade J, Bittner HB, Barten MJ, et al. Combined surgical left ventricular reconstruction and left ventricular assist device implantation for destination therapy in end-stage heart failure. *Circ Heart Fail*. 2011; 4(4):e14–e15. doi:10.1161/CIRCHEARTFAILURE.111.961219.
5. Spiliopoulos S, Wasler A, Fruehwald F, Ablasser K, Stoschitzky G, Dapunt O. Implantation of the HeartMate III left ventricular assist device in a giant left ventricular aneurysm: is left ventricular reconstruction mandatory? *Circ Heart Fail*. 2017;10(3):e003803. doi:10.1161/CIRCHEARTFAILURE.116.003803.