Europe PMC Funders Group
Author Manuscript
Semin Thromb Hemost. Author manuscript; available in PMC 2020 June 01.

Published in final edited form as:
Semin Thromb Hemost. 2019 April 30; 45(4): 334–341. doi:10.1055/s-0039-1688493.

Venous Thromboembolism in Brain Tumors: Risk Factors, Molecular Mechanisms, and Clinical Challenges

Julia Riedl, MD PhD[1] and **Cihan Ay, MD**[1,2]

[1]Clinical Division of Haematology and Haemostaseology, Department of Medicine I, Comprehensive Cancer Center, Medical University of Vienna, Vienna, Austria

[2]I.M. Sechenov First Moscow State Medical University (Sechenov University), Moscow, Russia

Abstract

Venous thromboembolism (VTE) is a common complication in patients with primary brain tumors, with up to 20% of patients per year having a VTE event. Clinical risk factors for VTE include glioblastoma subtype, paresis, or surgery. Furthermore, specific factors playing a role in tumor biology were recently identified to predispose to prothrombotic risk. For instance, mutations in the *isocitrate dehydrogenase 1 (IDH1)* gene, which occurs in a subgroup of glioma, correlate with risk of VTE, with low incidence in patients with presence of an *IDH1* mutation compared with those with *IDH1* wild-type status. In addition, expression of the glycoprotein podoplanin on brain tumors was associated with both intratumoral thrombi and high risk of VTE. As podoplanin has the ability to activate platelets, a mechanistic role of podoplanin-mediated platelet activation in VTE development has been suggested. From a clinical point of view, the management of patients with primary brain tumors and VTE is challenging. Anticoagulation is required to treat patients; however, it is associated with increased risk of intracranial hemorrhage. This review focuses on describing the epidemiology, risk factors, and mechanisms of brain tumor-associated thrombosis and discusses clinical challenges in the prevention and treatment of VTE in patients with brain tumors.

Keywords

brain tumors; venous thromboembolism; cancer-associated thrombosis; podoplanin; platelets

Patients with cancer are at an increased risk of developing venous thromboembolism (VTE), including deep vein thrombosis (DVT) and pulmonary embolism (PE). In population-based cohort studies, the risk of VTE was reported to be four- to 7-fold higher in patients with cancer compared with noncancer patients.1 However, the risk of VTE varies among cancer types and is particularly increased in patients with brain tumors. According to a

Address for correspondence Cihan Ay, MD, Clinical Division of Haematology and Haemostaseology, Department of Medicine I, Comprehensive Cancer Center, Medical University of Vienna, Waehringer Guertel 18-20 A-1090 Vienna, Austria (cihan.ay@meduniwien.ac.at).
Issue Theme Emergent Paradigms of Thrombosis and Cancer;
Guest Editors: Hau C. Kwaan, MD, PhD, Paul F. Lindholm, MD.

Conflict of Interest
None.

Europe PMC Funders Author Manuscripts
Europe PMC Funders Author Manuscripts

Europe PMC Funders Author Manuscripts

Europe PMC Funders Author Manuscripts

comprehensive meta-analysis, up to 20% of brain cancer patients develop VTE per year.2 The risk of VTE is especially high in the postoperative period, but remains increased throughout the course of the disease.3 Data from our own prospective and observational cohort study, the Vienna Cancer and Thrombosis Study (CATS), have indicated a cumulative VTE risk of 14.8% after 2 years in a cohort of patients with different types of primary brain tumors, with 89% of those having a high-grade glioma.4

The occurrence of VTE is generally associated with poor outcome of patients with cancer.5 However, data on the prognostic impact of VTE in patients with brain tumors are conflicting. In a small analysis of 63 patients with high-grade glioma, overall survival did not significantly differ between patients who developed VTE during the course of their disease compared with those without VTE.6 In a larger study by Smith et al, including 336 patients with high-grade glioma, of whom 53 (15.7%) developed VTE, no association of VTE with risk of mortality was also observed.7 However, a very large retrospective study of 9,489 patients with malignant glioma reported a 30% higher mortality risk after 2 years in patients who had experienced VTE.8 The reasons for these diverging results are not entirely clear. It has been suggested that the variability in mortality associated with VTE in patients with brain tumors may be mediated by differences in screening and managing strategies of VTE.9 Differences in the design of studies, definition of eligible patients, and methodology of data capture and analysis may also explain the discrepancy.

Risk Factors for VTE in Patients with Brain Tumors

Multiple clinical and laboratory parameters have been described as risk factors for VTE in brain tumor patients, which have also been reviewed in previous publications in this journal. 9,10 As in the general cancer population, risk factors in brain tumor can be grouped into patient-, treatment-, and tumor-related risk factors (summarized in ▸Table 1). Patient-related risk factors include older age,3,8,11 comorbidities,8 leg paresis,3,12 or history of VTE.7,13 ABO blood group was suggested as a risk factor for VTE, with highest risks for blood groups A and AB compared with blood group 0 in a retrospective study.11 It is well known that blood group A and AB is linked to higher von Willebrand factor (VWF) and coagulation factor VIII (FVIII) levels than blood group O,14 and both VWF and FVIII have been described as risk factors for cancer-associated VTE,15,16 which might explain this finding. However, the association between ABO blood group and VTE risk in brain tumors could not be confirmed in a subsequent prospective study by the same authors.17

The brain tumor subtype, with highest risks in glioblastoma,3,12 a larger tumor size,3,11 and presence of intratumoral thrombi have been described as tumor-related risk factors for VTE.4,18 In 2016, Unruh et al described a very low risk of VTE in patients with gliomas harboring the *isocitrate dehydrogenase 1* (*IDH1*) mutation.19 The association of *IDH1* mutation status and risk of VTE could be recently confirmed in an analysis from the Vienna CATS.20 Furthermore, we identified high expression levels of podoplanin, a transmembrane glycoprotein, by brain tumor cells as risk factor for VTE.4 Further details are described in the next section of this review.

Europe PMC Funders Author Manuscripts

Europe PMC Funders Author Manuscripts

The risk of VTE in brain tumors is time dependent. An increased risk of VTE is observed during the postoperative period. The risk is also higher in patients undergoing tumor biopsy than in those undergoing surgery for tumor resection.17 The risk ranges between 3 and 60% in the first 6 weeks after surgery, depending on the prophylaxis regimen, methods of diagnosis, and the reporting studies.3 In an analysis of 7376 patients with primary malignant brain tumors who underwent craniotomy for tumor surgery, 3.5% of patients developed VTE within 30 days after surgery.21 The rates of inhospital VTE correlated with duration of surgery. VTE was also associated with older age and obesity, and was higher in those with dependent functional status (i.e., patients who require assistance from another person for activities of daily living). Interestingly, male gender and steroid use predicted a higher risk of VTE in the postdischarge period from hospital. The effect of thromboprophylaxis on VTE risk could not be evaluated in this study, as no data on the use of thrombo-prophylaxis were available.

Also, anticancer treatments, such as antiangiogenic therapy with antivascular endothelial growth factor antibodies22,23 and use of steroids13 may increase risk of VTE.

Mechanisms of Thrombosis in Patients with Brain Tumors

The pathophysiology of VTE in brain tumors is still not fully understood. However, in recent years, novel insights into mechanisms of VTE have been gained. Previously, several authors suggested a pathomechanism based on tissue factor overexpression by cancer cells as major driver for VTE.10 Tissue factor is the major initiator of the coagulation system in vivo. It is highly expressed on the cell surface by most high-grade gliomas. Specific oncogenic pathways linking glioma aggressiveness to tissue factor expression have been identified, and it is thought that this expression also contributes to the thrombotic risk.24,25 However, clinical data did not reveal an association between tissue factor expression in brain tumor specimens or microvesicle-associated tissue factor activity in patient plasma and risk of VTE.26,27 Therefore, other concepts of mechanisms driving thrombosis in brain tumors have been assumed on the basis of the clinical observations. In this regard, our group demonstrated that patients with low platelet counts and high levels of the soluble P-selectin, a platelet activation marker, were at highest risk for developing VTE.28 This observation was surprising, as for the general cancer population, a high platelet count is known to be associated with increased risk of VTE.29,30 These findings support the hypothesis that platelets play a special role in the pathogenesis of thrombosis in brain tumors.

Association of Podoplanin with Risk of VTE in Brain Tumors

Podoplanin is a type-I transmembrane sialomucin-like glycoprotein that is highly expressed on lymphatic endothelial cells and a variety of other cells including kidney podocytes, type I lung alveolar cells, and fibroblastic reticular cells in lymph nodes. Podoplanin is not expressed in the blood vascular endothelium and under normal circumstances there is no direct contact between podoplanin and the blood stream. Podoplanin is a ligand of the platelet surface receptor C-type lectin receptor type-2 (CLEC-2) and binding of podoplanin to CLEC-2 induces platelet aggregation.31 Physiological functions of the podoplanin–CLEC-2 interaction include separation of the lymphatic system from the blood vascular

Europe PMC Funders Author Manuscripts

Europe PMC Funders Author Manuscripts

system during the embryonic period and regulation of lymphatic vessel integrity (more details are described in the next section on “Interaction and physiological functions of Podoplanin and CLEC-2”).32–34 A variety of cancer types, including brain tumors, also express podoplanin, which has been linked to decreased survival of patients.35

Based on the ability of podoplanin to activate platelets, we were interested in investigating the role of podoplanin in cancer-associated thrombosis. In 2017, we reported an association between expression levels of podoplanin in tumor tissue and risk of VTE in patients with primary malignant brain tumors.4 In this study, we stained brain tumor specimens of 213 brain tumor patients, who were prospectively followed until occurrence of VTE and death during a 2-year observation period, for podoplanin expression by immuno-histochemistry. Patients with tumors that did not express podoplanin had a risk of ~5% to develop VTE, while the risk was 25% in patients with high podoplanin expression. Notably, a gradual increase in thrombotic risk with increasing podoplanin expression levels was also observed. Podoplanin expression in the tumor tissue was furthermore associated with intratumoral platelet aggregates, with higher D-dimer levels in the plasma of patients and with lower blood platelet counts. We hypothesized that the lower platelet count might be due to platelet activation by podoplanin and consecutive platelet consumption. To support our hypothesis, we performed in vitro experiments using a podoplanin-expressing human brain tumor cell line, which had been established from a patient with glioblastoma who had been included in this study and who developed PE during follow-up. This podoplanin-expressing cell line induced potent platelet activation, as measured by release of platelet factor-4 from platelet granules, and platelet aggregation, which could be abrogated by an antipodoplanin antibody. ▸Fig. 1 summarizes our findings and our proposed hypothesis regarding how podoplanin leads to VTE in brain tumors.

In vivo experimental studies are needed to confirm our hypothesis that podoplanin triggers the development of thrombosis in brain cancer by activating platelets.

Interaction and Physiological Functions of Podoplanin and CLEC-2

In 2006, Suzuki-Inoue et al identified CLEC-2 as a novel platelet activation receptor.36 CLEC-2 was first discovered as a receptor for the snake venom rhodocytin, a powerful inducer of platelet aggregation.37 Later, podoplanin was identified as—the so far only known—endogenous ligand for CLEC-2. The CLEC-2 protein contains a hemi-immunoreceptor tyrosine-based activation motif and signals via an intracellular cascade involving activation of the nonreceptor tyrosine kinase Syk, which leads to further downstream activation of Bruton’s tyrosine kinase and phospholipase Cγ2, thereby inducing platelet aggregation.32

Podoplanin-induced platelet aggregation is essential during the embryonic period for separation of the blood and the lymphatic vascular system. Podoplanin knockout mice show a phenotype with a nonseparated, blood-filled lymphatic system.33 The podoplanin–CLEC-2 interaction was also found to be essential for lung and cerebrovascular development during the embryonic period.38,39 After embryonic development, a role for podoplanin and CLEC-2 in immune response and in the maintenance of lymph nodes was described.34 With

Europe PMC Funders Author Manuscripts

Europe PMC Funders Author Manuscripts

regard to the hemostatic system, platelet CLEC-2 was suggested not to play a critical role for physiologic hemostasis, as evidenced by in vitro studies and by a normal tail bleeding time in CLEC-2-deficient mice. Furthermore, in the healthy organism podoplanin expression is restricted to tissues outside the blood vasculature.40–42

Role of the Podoplanin and CLEC-2 Pathway in Thrombosis: Functional Studies

Several experimental studies were recently published, which indicate a functional role of podoplanin and CLEC-2 in the development of thrombosis. Using a melanoma-mouse model, Shirai et al demonstrated that podoplanin-positive melanoma cells support thrombosis formation in tumor vessels, as well as hematogenous metastasis, by activating platelets via CLEC-2.43 Inhibition of CLEC-2 was able to prevent thrombus formation in tumor vessels and hematogenous metastasis.43

Next to cancer, inflammation is another driver of thrombosis. The role of podoplanin/CLEC-2 in thrombus development in sepsis has been examined in a mouse model of systemic *Salmonella Typhimurium* infection. Podoplanin-expressing monocytes and Kupffer cells in the liver induced local thrombosis in liver vessels via interaction with platelet CLEC-2.44 Development of thrombosis was markedly reduced in mice with a platelet-specific CLEC-2 knockout.

In a third study, Payne et al used a murine DVT model, whereby hypoxia of the venous wall was induced by inferior vena cava ligation to study the role of CLEC-2 and podoplanin. In this study, the authors found an upregulation of podoplanin in the venous wall under hypoxic conditions, leading to platelet activation and DVT.45 The authors also showed that mice deficient in CLEC-2 were protected against DVT. The study by Payne et al provides the first in vivo evidence that the podoplanin–CLEC-2 axis plays a role in the development of VTE.45

Taken together, functional studies using mouse models indicate that the podoplanin–CLEC-2 axis is involved in thrombogenesis. The concept of podoplanin-triggered thrombosis needs to be confirmed in studies of specific tumor and DVT mouse models.

Podoplanin and Thrombocytopenia

Previously, we observed that patients with podoplanin-expressing brain tumors had lower blood platelet counts.4 One other recent study also described a link between podoplanin expression and decreased platelet counts in cancer: Lavallèe et al identified podoplanin expression on leukemic blasts as a major mechanism causing severe thrombocytopenia in patients with acute promyelocytic leukemia.46

Interestingly, in one experimental study, ectopic expression of a podoplanin-Fc fusion protein in the skin generated in transgenic mice was examined. The original purpose of this study was to investigate the effect of podoplanin on the lymphatic vascular system. Unexpectedly, the authors observed that ectopic podoplanin expression in the skin induced

Europe PMC Funders Author Manuscripts

Europe PMC Funders Author Manuscripts

thrombocytopenia and disseminated intravascular coagulation in mice.47 This study indicates that podoplanin is indeed able to induce platelet consumption in vivo.

These data support our hypothesis that the platelet count in patients with podoplanin-expressing brain tumors might be decreased due to activation of platelets by podoplanin and consequent platelet consumption.

Unanswered Questions

Despite the existing clinical and experimental evidence pointing to a role of podplanin and CLEC-2 in the pathophysiology of VTE in brain tumors, several questions remain unsolved. Most importantly, it is not known how local platelet activation in the tumor tissue can lead to systemic thrombosis. Another question is how podoplanin expressed by local tumors in the brain is released into the circulation. Possibly, tumor-derived microvesicles expressing podoplanin are released into the circulation. However, so far, podoplanin has not been detected in the blood circulation of brain tumor patients. This might be due to technical issues, as currently no reliable detection method for podoplanin in blood samples exists. Furthermore, presumably circulating podoplanin, whether in a free form or on the surface of microvesicles, might be very quickly cleared from circulation, possibly by binding to and activating platelets. Further research, including development of validated methods to quantify podoplanin, is needed to answer these questions.

IDH1 Mutation and VTE in Brain Tumor Patients

In 2016, Unruh et al reported that the risk of VTE is extremely low in patients with *IDH1* mutated gliomas.19 VTE occurred in 26 to 30% of patients with wild-type *IDH1* and no patient with an *IDH1* mutant tumor developed VTE. The association between *IDH1* mutation and low risk of VTE could be externally validated by our group. Data from the Vienna CATS indicate a 2-year cumulative VTE risk of 17% in *IDH1* wild-type tumors as opposed to 2.4% in *IDH1* mutant tumors.20 In fact, in our study only one out of 42 patients with *IDH1* mutant tumors developed VTE, and this patient had several VTE events in his medical history (already years before diagnosis of glioma), suggesting that other thrombotic risk factors independently from glioma might have contributed to VTE development in this patient.

Unruh et al showed that D-2-hydroxyglutarate, an oncometabolite produced in *IDH1* mutated tumors, has an inhibitory effect on platelet aggregation and blood clotting and therefore a specific antithrombotic activity of *IDH1* mutation in gliomas was suggested.19 Moreover it was shown that *IDH1* mutation inversely correlates with tissue factor expression.19

We further investigated the interrelation between *IDH1* status and podoplanin expression and observed that podoplanin overexpression occurs exclusively in *IDH1* wild-type tumors, while *IDH1* mutant tumors did not express podoplanin.20 A score incorporating podoplanin expression levels and *IDH1* status enabled an improved risk stratification for VTE. Patients with *IDH1* mutant tumors and no podoplanin expression had a VTE risk of 0% after 6

Europe PMC Funders Author Manuscripts

Europe PMC Funders Author Manuscripts

months as compared with 18.2% in patients with *IDH1* wild-type tumors and high podoplanin expression.20

Of note, analysis of molecular expression patterns of glioma revealed that podoplanin expression is closely linked to tissue factor expression.25 Therefore, the prothrombotic phenotype of podoplanin-positive brain tumors might also be mediated via tissue factor overexpression. However, as previous clinical studies did not reveal an association between tissue factor expression and VTE in glioma,27 a specific prothrombotic mechanism of podoplanin independent of tissue factor is suggested.

The proposed hypothesis of brain-cancer-associated thrombosis is depicted in ▸Fig. 1.

Podoplanin as an Antineoplastic Treatment Target

Podoplanin is expressed by a variety of cancer types including malignant glioma and its expression is linked to tumor aggressiveness and poor prognosis.4,35,48,49 Several steps of tumor progression, including invasion, epithelial to mesenchymal transition and metastasis, were shown to be promoted by podoplanin.49 Consequently, several experimental studies aimed at targeting podoplanin for anticancer treatment by using different strategies, such as antibodies, synthetic molecules, and also chimeric antigen receptor (CAR) T cell therapy (reviewed recently by Krishnan et al).49 Promising results have been derived from a murine glioblastoma model, in which CAR-T cells targeting podoplanin were shown to effectively inhibit tumor growth.50 In contrast, a recent study by Eisemann et al suggested that podoplanin is rather a marker of malignancy than directly involved in tumor progression, as deletion of podoplanin in their mouse model did not interfere with tumor growth or survival of mice.51 The authors concluded, however, that podoplanin might still be used as marker for tumor aggressiveness and also as a target to deliver antineoplastic drugs and as a target for CAR T cell therapy. Moreover, targeting podoplanin might decrease the risk of VTE.

Clinical Challenges and Management of VTE in Brain Cancer

Treatment of VTE in Patients with Brain Tumors

In the absence of contraindications (e.g., activebleeding orhigh risk of bleeding), treatment of VTE in all patients should be performed with anticoagulant therapy. Current guidelines recommend low-molecular-weight heparin (LMWH) over vitamin-K antagonists in cancer-associated VTE.52 This recommendation is mainly based on results of the CLOT (Randomized Comparison of Low-Molecular-Weight Heparin versus Oral Anticoagulant Therapy for the Prevention of Recurrent Venous Thromboembolism in Patients with Cancer) trial, which showed better efficacy and safety of LMWH over vitamin-K-antagonists for treatment of VTE in cancer patients.53 However, only a small number of patients included in the CLOT trial had brain tumors ($n = 27$), and there are no outcome data reported specifically for this subgroup.

In 2018, the Hokusai VTE-Cancer study was published, which was the first head-to-head comparison of a direct oral anticoagulant (DOAC) with LMWH for treatment of cancer-associated VTE. This study tested the efficacy and safety of edoxaban, an anti-Xa inhibitor,

Europe PMC Funders Author Manuscripts

Europe PMC Funders Author Manuscripts

against dalteparin, an LMWH, in patients with active cancer and acute VTE.54 The primary outcome of the study, a composite of recurrent VTE and major bleeding during 12 months after randomization, did not differ significantly between treatment groups, demonstrating noninferiority of edoxaban to LMWH. While the rates of recurrent VTE were lower in patients treated with edoxaban, there were higher rates of major bleeding compared with dalteparin. The higher bleeding risk with edoxaban resulted from an excess of gastrointestinal bleeding, which occurred predominately in patients with primary gastrointestinal tumors. A small number of patients with brain tumors or brain metastasis were included in this study ($n = 74$). In subgroup analysis, the efficacy and safety of edoxaban seemed to be comparable to LMWH (▸Table 2): The primary outcome occurred in 6 out of 31 patients in the edoxaban group (19.4%) and in 8 out of 43 patients (18.6%) in the LMWH group (p for interaction = 0.677). Recurrent VTE occurred in 5 out of 31 patients in the edoxaban group (16.1%) and in 5 out of 43 patients (11.6%) in the LMWH group (p for interaction = 0.1799); and major bleeding episodes occurred in 2 out of 31 patients in the edoxaban group (6.5%) and in 4 out of 43 patients (9.3%) in the LMWH group. These results indicate both a high risk of recurrent VTE and high risk of major bleeding in patients with brain tumors and VTE; however, efficacy and safety did not differ between treatment arms. It has to be noted that details on subtypes of brain tumors (proportion of primary brain tumors versus brain metastasis) or types of bleeding (rate of intracranial bleeds versus other major bleeding) were not reported separately for this subgroup.

Very recently, a second trial comparing a DOAC to LMWH for the treatment of cancer-associated VTE was published. In the SELECT-D study, the anti-Xa-inhibitor rivaroxaban was compared with dalteparin.55 Rivaroxaban was associated with a low risk of recurrent VTE, no increased risk of major bleeding events, but a higher risk of clinically relevant nonmajor bleeding. However, in this study, only three patients with brain tumors were included, not allowing a specific conclusion.55

Taken together, current data suggest similar efficacy and safety for edoxaban compared with dalteparin for treatment of VTE in brain tumor patients. However, current evidence is so far limited, and based on one subgroup analysis of one randomized controlled trial.

The use of anticoagulation is associated with an increased risk of bleeding, and intracranial hemorrhage (ICH) is the most feared type of bleeding. The perceived risk of ICH plays a role in treatment decisions, especially in patients with brain tumors. Whether anticoagulation is safe to be administered in patients with brain tumors has been long debated. Al Megren et al described a 7-fold increase in risk of ICH in patients with glioma who received full dose anticoagulation for treatment of acute VTE compared with matched glioma patients without VTE.56 The best evidence for risk of ICH during anticoagulation in brain tumors is currently provided by a meta-analysis of nine retrospective cohort studies from Zwicker et al.57 Overall, a 3-fold higher risk of ICH in glioma patients receiving therapeutic anticoagulation was reported, as compared with matched controls without anticoagulant treatment. The risk of fatal ICH, however, was low, with an incidence of less than 1%. It should be noted that the type of anticoagulation used in most of the studies was a vitamin-K-antagonists, and differences in bleeding risk between types of anticoagulation (LMWH versus vitamin-K-antagonist) have not been investigated. Interestingly, in this meta-analysis

Europe PMC Funders Author Manuscripts

Europe PMC Funders Author Manuscripts

patients with brain metastases did not have an elevated intracranial bleeding risk during anticoagulation.57 The authors concluded that special caution must be taken in patients with primary brain tumors in whom anticoagulation is indicated. However, as the risk of fatal ICH was low and as there is a lack of alternative treatment options, anticoagulant therapy should still be administered to patients with acute VTE, as far as there are no contraindications (active bleeding, severe thrombocytopenia, etc.).

Primary Prophylaxis of VTE in Brain Tumors

For the general cancer population, pharmacological thromboprophylaxis with LMWH is recommended in hospitalized patients and in the perioperative setting.52 Surgery is a well-established risk factor for VTE also in brain tumor patients. Guidelines recommend postoperative pharmacological thromboprophylaxis with LMWH for all tumor patients undergoing major surgery for 7 to 10 days.52 As the risk of VTE remains high throughout the course of disease, a phase III randomized placebo-controlled trial (the PRODIGE study) aimed at evaluating the efficacy and safety of primary thromboprophylaxis with LMWH (dalteparin) for up to 12 months in patients with malignant glioma.58 This study was terminated early due to low patient accrual and expiration of the study medication, and therefore definitive conclusions cannot be drawn. Finally, the data on 99 patients randomized to LMWH and 87 randomized to placebo showed a trend toward a reduced risk of VTE in the LMWH group after 6 months of therapy (9 in the LMWH group versus 13 in the placebo group developed VTE corresponding to a hazard ratio [HR] of 0.51, 95% confidence interval [CI]: 0.19–1.4, $p = 0.29$). However, in this study also a trend toward increased risk of major bleeding after 12 months was seen (five patients [5.1%] on LMWH versus one patient [1.2%] on placebo developed major bleeding; HR 4.2, 95% CI: 0.48–36, $p = 0.22$), and all major bleeds were ICH. Mortality after 12 months was not different between groups (47.8 versus 45.4% for LMWH versus placebo, respectively; HR = 1.2, 95% CI: 0.73–2.0, $p = 0.48$). In the absence of high-quality data, primary pharmacological thromboprophylaxis cannot be recommended for patients with malignant glioma beyond the postoperative period.10

Use of Anticoagulant Therapy and Survival in Glioma

The high risk of VTE and also the presence of intratumoral thrombosis, as well as potential modifying effects of anticoagulant drugs on cancer biology, angiogenesis, and tumor invasion prompted the hypothesis that anticoagulants might improve the clinical outcome and improve prognosis of glioma patients. A recent study of more than 1,000 patients with newly diagnosed glioblastoma, however, did not support this hypothesis.59 In fact, patients who were treated with anticoagulant drugs while on radio/chemotherapy had a worse survival compared with patients who did not use anticoagulants. This analysis is likely to be confounded by the fact that patients on anticoagulants mainly had prior VTE events, which might per se be associated with poor prognosis.8 However, according to currently available data, anticoagulant drugs do not seem to have a beneficial effect on survival in glioma patients.

Europe PMC Funders Author Manuscripts

Europe PMC Funders Author Manuscripts

Summary, Conclusion, and Perspective

The risk of VTE is very high in patients with primary brain tumors, with rates of up to 20% per year. The risk of VTE is particularly high in the postoperative period and remains elevated throughout the course of the disease. Pharmacological thromboprophylaxis is currently recommended for the post-operative period; however, current studies do not support the prolongation of thromboprophylaxis beyond discharge from hospital. Treatment of VTE requires therapeutic anticoagulation and is challenging in patients with primary brain tumors, as it is associated with increased risk of ICH. In contrast, no increased ICH risk was observed in patients with brain metastasis who receive anticoagulant therapy. Current guidelines recommend LMWH as the anticoagulant drug of choice for treatment of VTE in patients with cancer. Studies comparing DOAC with LMWH have been recently published and the results are promising for the majority of cancer patients, although data on the subgroup of brain tumor patients are limited so far.

In the past couple of years, novel insights into risk factors and pathomechanisms of VTE in primary brain tumors could be gained. Patients with *IDH1* mutant gliomas were identified to be at a very low risk of VTE, while intratumoral podoplanin expression was found to be associated with risk of VTE, and podoplanin-induced platelet activation was proposed to play a key role in developing VTE in brain tumors. Further knowledge on risk factors and improved risk stratification might help to develop tailored strategies to prevent VTE. Clinical studies are needed to prove efficacy and safety of thromboprophylaxis based on individual risk assessment.

Finally, we believe that the better understanding of specific mechanisms of VTE, such as the podoplanin–CLEC-2 axis, might lead to identification of novel treatment targets and potentially to the development of novel therapies for prevention and improved treatment of VTE with less side effects, especially less bleeding complications.

Acknowledgments

We thank the Austrian Science Fund (FWF), Special Research Program (SFB) 54 for supporting our research.

References

1. Heit JA, Silverstein MD, Mohr DN, Petterson TM, O'Fallon WM, Melton LJ III. Risk factors for deep vein thrombosis and pulmonary embolism: a population-based case-control study. Arch Intern Med. 2000; 160(06):809–815. [PubMed: 10737280]
2. Horsted F, West J, Grainge MJ. Risk of venous thromboembolism in patients with cancer: a systematic review and meta-analysis. PLoS Med. 2012; 9(07):e1001275. [PubMed: 22859911]
3. Marras LC, Geerts WH, Perry JR. The risk of venous thromboembolism is increased throughout the course of malignant glioma: an evidence-based review. Cancer. 2000; 89(03):640–646. [PubMed: 10931464]
4. Riedl J, Preusser M, Nazari PM, et al. Podoplanin expression in primary brain tumors induces platelet aggregation and increases risk of venous thromboembolism. Blood. 2017; 129(13):1831–1839. [PubMed: 28073783]
5. Ay C, Dunkler D, Pirker R, et al. High D-dimer levels are associated with poor prognosis in cancer patients. Haematologica. 2012; 97(08):1158–1164. [PubMed: 22371182]

Europe PMC Funders Author Manuscripts

Europe PMC Funders Author Manuscripts

6. Simanek R, Vormittag R, Hassler M, et al. Venous thromboembolism and survival in patients with high-grade glioma. Neurooncol. 2007; 9(02):89–95.
7. Smith TR, Lall RR, Graham RB, et al. Venous thromboembolism in high grade glioma among surgical patients: results from a single center over a 10 year period. J Neurooncol. 2014; 120(02): 347–352. [PubMed: 25062669]
8. Semrad TJ, O'Donnell R, Wun T, et al. Epidemiology of venous thromboembolism in 9489 patients with malignant glioma. J Neurosurg. 2007; 106(04):601–608. [PubMed: 17432710]
9. Cote DJ, Dawood HY, Smith TR. Venous thromboembolism in patients with high-grade glioma. Semin Thromb Hemost. 2016; 42(08):877–883. [PubMed: 27574964]
10. Jo JT, Schiff D, Perry JR. Thrombosis in brain tumors. Semin Thromb Hemost. 2014; 40(03):325–331. [PubMed: 24599439]
11. Streiff MB, Segal J, Grossman SA, Kickler TS, Weir EG. ABO blood group is a potent risk factor for venous thromboembolism in patients with malignant gliomas. Cancer. 2004; 100(08):1717–1723. [PubMed: 15073862]
12. Brandes AA, Scelzi E, Salmistraro G, et al. Incidence of risk of thromboembolism during treatment high-grade gliomas: a prospective study. Eur J Cancer. 1997; 33(10):1592–1596. [PubMed: 9389920]
13. Yust-Katz S, Mandel JJ, Wu J, et al. Venous thromboembolism (VTE) and glioblastoma. J Neurooncol. 2015; 124(01):87–94. [PubMed: 25985958]
14. O'Donnell J, Laffan MA. The relationship between ABO histo-blood group, factor VIII and von Willebrand factor. Transfus Med. 2001; 11(04):343–351. [PubMed: 11532189]
15. Vormittag R, Simanek R, Ay C, et al. High factor VIII levels independently predict venous thromboembolism in cancer patients: the cancer and thrombosis study. Arterioscler Thromb Vasc Biol. 2009; 29(12):2176–2181. [PubMed: 19778945]
16. Pépin M, Kleinjan A, Hajage D, et al. ADAMTS-13 and von Willebrand factor predict venous thromboembolism in patients with cancer. J Thromb Haemost. 2016; 14(02):306–315. [PubMed: 26589836]
17. Streiff MB, Ye X, Kickler TS, et al. A prospective multicenter study of venous thromboembolism in patients with newly-diagnosed high-grade glioma: hazard rate and risk factors. J Neurooncol. 2015; 124(02):299–305. [PubMed: 26100546]
18. Rodas RA, Fenstermaker RA, McKeever PE, et al. Correlation of intraluminal thrombosis in brain tumor vessels with postoperative thrombotic complications: a preliminary report. J Neurosurg. 1998; 89(02):200–205. [PubMed: 9688113]
19. Unruh D, Schwarze SR, Khoury L, et al. Mutant IDH1 and thrombosis in gliomas. Acta Neuropathol. 2016; 132(06):917–930. [PubMed: 27664011]
20. Mir Seyed Nazari P, Riedl J, Preusser M, et al. Combination of isocitrate dehydrogenase 1 (IDH1) mutation and podoplanin expression in brain tumors identifies patients at high or low risk of venous thromboembolism. J Thromb Haemost. 2018; 16(06):1121–1127. [PubMed: 29676036]
21. Senders JT, Goldhaber NH, Cote DJ, et al. Venous thromboembolism and intracranial hemorrhage after craniotomy for primary malignant brain tumors: a National Surgical Quality Improvement Program analysis. J Neurooncol. 2018; 136(01):135–145. [PubMed: 29039075]
22. Perry JR. Anticoagulation of malignant glioma patients in the era of novel antiangiogenic agents. Curr Opin Neurol. 2010; 23(06):592–596. [PubMed: 20881488]
23. Li X, Huang R, Xu Z. Risk of adverse vascular events in newly diagnosed glioblastoma multiforme patients treated with beva-cizumab: a systematic review and meta-analysis. Sci Rep. 2015; 5
24. D'Asti E, Rak J. Biological basis of personalized anticoagulation in cancer: oncogene and oncomir networks as putative regulators of coagulopathy. Thromb Res. 2016; 140(1):S37–S43. [PubMed: 27067976]
25. Tawil N, Chennakrishnaiah S, Bassawon R, Johnson R, D'Asti E, Rak J. Single cell coagulomes as constituents of the oncogene-driven coagulant phenotype in brain tumours. Thromb Res. 2018; 164(1):S136–S142. [PubMed: 29703472]
26. Thaler J, Ay C, Mackman N, et al. Microparticle-associated tissue factor activity, venous thromboembolism and mortality in pan-creatic, gastric, colorectal and brain cancer patients. J Thromb Haemost. 2012; 10(07):1363–1370. [PubMed: 22520016]

Europe PMC Funders Author Manuscripts

Europe PMC Funders Author Manuscripts

27. Thaler J, Preusser M, Ay C, et al. Intratumoral tissue factor expression and risk of venous thromboembolism in brain tumor patients. Thromb Res. 2013; 131(02):162–165. [PubMed: 23084660]
28. Thaler J, Ay C, Kaider A, et al. Biomarkers predictive of venous thromboembolism in patients with newly diagnosed high-grade gliomas. Neuro-oncol. 2014; 16(12):1645–1651. [PubMed: 24987133]
29. Simanek R, Vormittag R, Ay C, et al. High platelet count associated with venous thromboembolism in cancer patients: results from the Vienna Cancer and Thrombosis Study (CATS). J Thromb Haemost. 2010; 8(01):114–120.
30. Khorana AA, Francis CW, Culakova E, Lyman GH. Risk factors for chemotherapy-associated venous thromboembolism in a prospective observational study. Cancer. 2005; 104(12):2822–2829. [PubMed: 16284987]
31. Suzuki-Inoue K, Kato Y, Inoue O, et al. Involvement of the snake toxin receptor CLEC-2, in podoplanin-mediated platelet activation, by cancer cells. J Biol Chem. 2007; 282(36):25993–26001. [PubMed: 17616532]
32. Suzuki-Inoue K, Tsukiji N, Shirai T, Osada M, Inoue O, Ozaki Y. Platelet CLEC-2: roles beyond hemostasis. Semin Thromb Hemost. 2018; 44(02):126–134. [PubMed: 28992650]
33. Uhrin P, Zaujec J, Breuss JM, et al. Novel function for blood platelets and podoplanin in developmental separation of blood and lymphatic circulation. Blood. 2010; 115(19):3997–4005. [PubMed: 20110424]
34. Herzog BH, Fu J, Wilson SJ, et al. Podoplanin maintains high endothelial venule integrity by interacting with platelet CLEC-2. Nature. 2013; 502(7469):105–109. [PubMed: 23995678]
35. Birner P, Pusch S, Christov C, et al. Mutant IDH1 inhibits PI3K/Akt signaling in human glioma. Cancer. 2014; 120(16):2440–2447. [PubMed: 24771584]
36. Suzuki-Inoue K, Inoue O, Ozaki Y. Novel platelet activation receptor CLEC-2: from discovery to prospects. J Thromb Haemost. 2011; 9(1):44–55. [PubMed: 21781241]
37. Suzuki-Inoue K, Fuller GL, García A, et al. A novel Syk-dependent mechanism of platelet activation by the C-type lectin receptor CLEC-2. Blood. 2006; 107(02):542–549. [PubMed: 16174766]
38. Tsukiji N, Inoue O, Morimoto M, et al. Platelets play an essential role in murine lung development through Clec-2/podoplanin interaction. Blood. 2018; 132(11):1167–1179. [PubMed: 29853539]
39. Lowe KL, Finney BA, Deppermann C, et al. Podoplanin and CLEC-2 drive cerebrovascular patterning and integrity during development. Blood. 2015; 125(24):3769–3777. [PubMed: 25908104]
40. Rayes J, Watson SP, Nieswandt B. Functional significance of the platelet immune receptors GPVI and CLEC-2. J Clin Invest. 2019; 129(01):12–23. [PubMed: 30601137]
41. Suzuki-Inoue K, Inoue O, Ding G, et al. Essential in vivo roles of the C-type lectin receptor CLEC-2: embryonic/neonatal lethality of CLEC-2-deficient mice by blood/lymphatic misconnections and impaired thrombus formation of CLEC-2-deficient platelets. J Biol Chem. 2010; 285(32):24494–24507. [PubMed: 20525685]
42. Hughes CE, Navarro-Núñez L, Finney BA, Mourão-Sá D, Pollitt AY, Watson SP. CLEC-2 is not required for platelet aggregation at arteriolar shear. J Thromb Haemost. 2010; 8(10):2328–2332. [PubMed: 20695981]
43. Shirai T, Inoue O, Tamura S, et al. C-type lectin-like receptor 2 promotes hematogenous tumor metastasis and prothrombotic state in tumor-bearing mice. J Thromb Haemost. 2017; 15(03):513–525. [PubMed: 28028907]
44. Hitchcock JR, Cook CN, Bobat S, et al. Inflammation drives thrombosis after Salmonella infection via CLEC-2 on platelets. J Clin Invest. 2015; 125(12):4429–4446. [PubMed: 26571395]
45. Payne H, Ponomaryov T, Watson SP, Brill A. Mice with a deficiency in CLEC-2 are protected against deep vein thrombosis. Blood. 2017; 129(14):2013–2020. [PubMed: 28104688]
46. Lavallée VP, Chagraoui J, MacRae T, et al. Transcriptomic landscape of acute promyelocytic leukemia reveals aberrant surface expression of the platelet aggregation agonist Podoplanin. Leukemia. 2018; 32(06):1349–1357. [PubMed: 29550835]

Europe PMC Funders Author Manuscripts

Europe PMC Funders Author Manuscripts

47. Cueni LN, Chen L, Zhang H, et al. Podoplanin-Fc reduces lymphatic vessel formation in vitro and in vivo and causes disseminated intravascular coagulation when transgenically expressed in the skin. Blood. 2010; 116(20):4376–4384. [PubMed: 20716773]
48. Ernst A, Hofmann S, Ahmadi R, et al. Genomic and expression profiling of glioblastoma stem cell-like spheroid cultures identifies novel tumor-relevant genes associated with survival. Clin Cancer Res. 2009; 15(21):6541–6550. [PubMed: 19861460]
49. Krishnan H, Rayes J, Miyashita T, et al. Podoplanin: An emerging cancer biomarker and therapeutic target. Cancer Sci. 2018; 109(05):1292–1299. [PubMed: 29575529]
50. Shiina S, Ohno M, Ohka F, et al. CAR T cells targeting podoplanin reduce orthotopic glioblastomas in mouse brains. Cancer Immunol Res. 2016; 4(03):259–268. [PubMed: 26822025]
51. Eisemann T, Costa B, Harter PN, et al. Podoplanin expression is a prognostic biomarker but may be dispensable for the malignancy of glioblastoma. Neuro Oncol. 2019; 21(03):326–336.
52. Lyman GH, Bohlke K, Khorana AA, et al. American Society of Clinical Oncology. Venous thromboembolism prophylaxis and treatment in patients with cancer: american society of clinical oncology clinical practice guideline update 2014. J Clin Oncol. 2015; 33(06):654–656. [PubMed: 25605844]
53. Lee AYY, Levine MN, Baker RI, et al. Randomized Comparison of Low-Molecular-Weight Heparin versus Oral Anticoagulant Therapy for the Prevention of Recurrent Venous Thromboembolism in Patients with Cancer (CLOT) Investigators. Low-molecular-weight heparin versus a coumarin for the prevention of recurrent venous thromboembolism in patients with cancer. N Engl J Med. 2003; 349(02):146–153. [PubMed: 12853587]
54. Raskob GE, van Es N, Verhamme P, et al. Hokusai VTE Cancer Investigators. Edoxaban for the treatment of cancer-associated venous thromboembolism. N Engl J Med. 2018; 378(07):615–624. [PubMed: 29231094]
55. Young AM, Marshall A, Thirlwall J, et al. Comparison of an oral factor Xa inhibitor with low molecular weight heparin in patients with cancer with venous thromboembolism: results of a randomized trial (SELECT-D). J Clin Oncol. 2018; 36(20):2017–2023. [PubMed: 29746227]
56. Al Megren M, De Wit C, Al Qahtani M, Le Gal G, Carrier M. Management of venous thromboembolism in patients with glioma. Thromb Res. 2017; 156:105–108. [PubMed: 28624717]
57. Zwicker JI, Karp Leaf R, Carrier M. A meta-analysis of intracranial hemorrhage in patients with brain tumors receiving therapeutic anticoagulation. J Thromb Haemost. 2016; 14(09):1736–1740. [PubMed: 27306689]
58. Perry JR, Julian JA, Laperriere NJ, et al. PRODIGE: a randomized placebo-controlled trial of dalteparin low-molecular-weight heparin thromboprophylaxis in patients with newly diagnosed malignant glioma. J Thromb Haemost. 2010; 8(09):1959–1965. [PubMed: 20598077]
59. Le Rhun E, Genbrugge E, Stupp R, et al. Associations of anticoagulant use with outcome in newly diagnosed glioblastoma. Eur J Cancer. 2018; 101(101):95–104. [PubMed: 30036741]

Europe PMC Funders Author Manuscripts

Europe PMC Funders Author Manuscripts

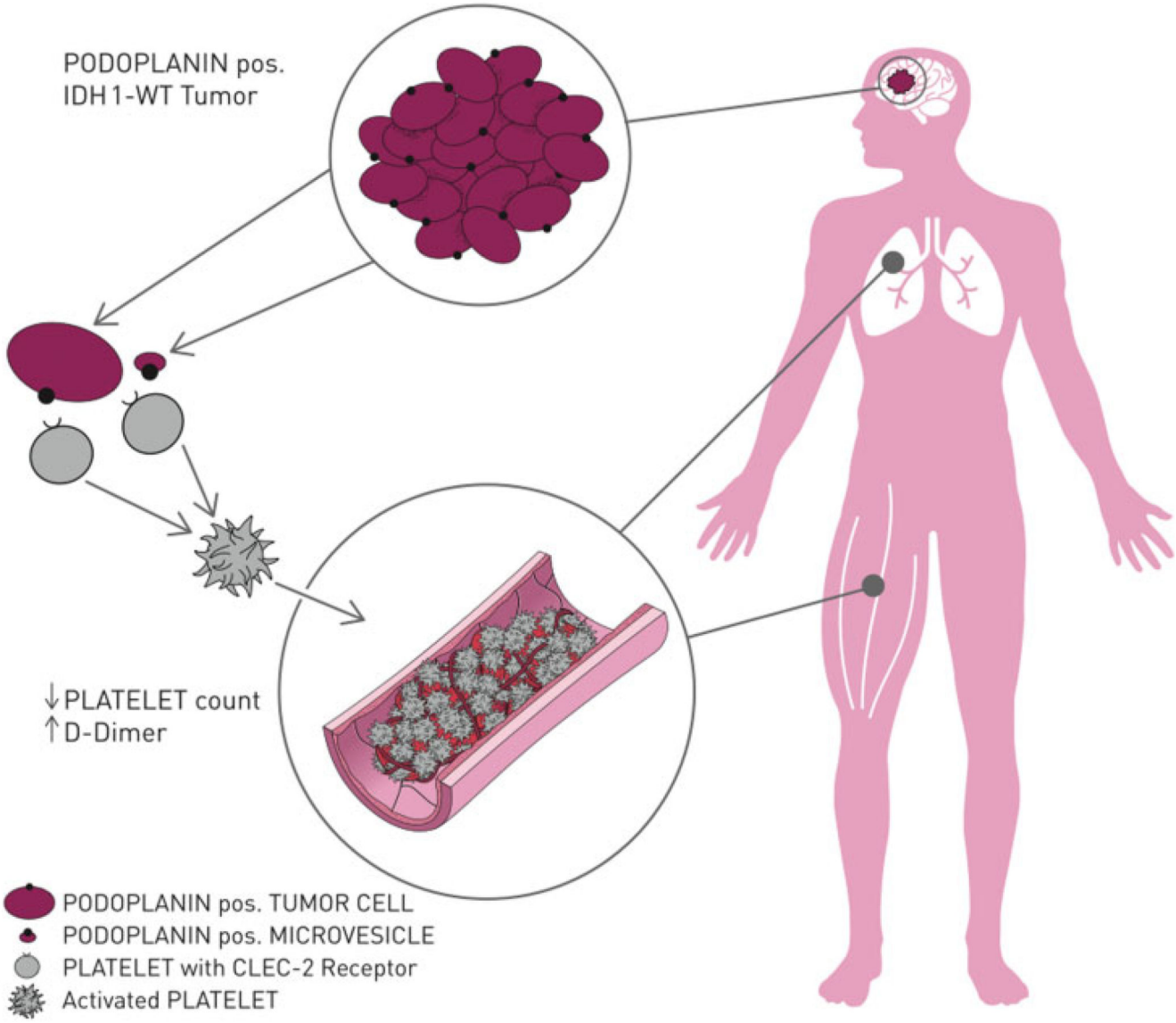

Fig. 1.

Proposed mechanism of venous thromboembolism (VTE) in patients with primary malignant brain tumors. Isocitrate dehydrogenase 1 wild-type tumors (IDH1 WT) express podoplanin on the surface of brain tumor cells. Podoplanin-expressing cancer cells or podoplanin-positive microvesicles enter the blood circulation and can directly activate platelets via binding of platelet activating receptor C-type lectin receptor type 2 (CLEC-2). Platelet activation leads to platelet aggregation and platelet consumption, subsequently resulting in lower systemic platelet counts. The process of activation of platelets is further associated with hypercoagulability (as evidenced by higher D-dimer levels) and culminates in higher risk of VTE.

Europe PMC Funders Author Manuscripts

Europe PMC Funders Author Manuscripts

Table 1

Factors associated with an increased risk of VTE in patients with primary malignant brain tumors

Patient-related risk factors	• Older age • Obesity • Dependent functional status (i.e., patients who require assistance from another person for activities of daily living) • Leg paresis
Treatment-related risk factors	• Surgery • Tumor biopsy • Subtotal tumor resection • Use of corticosteroids • Anti-VEGF therapy
Tumor-related risk factors	• Glioblastoma subtype (as compared with lower-grade gliomas) • Intratumoral thrombosis • *IDH1* wild-type status • Podoplanin expression
Laboratory parameters and hemostatic biomarkers	• High white blood cell count • Low platelet count (in contrast to solid tumors) • High soluble P-selectin levels • Elevated coagulation factor VIII activity • Increased D-dimer levels

Abbreviation: IDH1, isocitrate dehydrogenase 1; VEGF, vascular endothelial growth factor; VTE, venous thromboembolism.

Europe PMC Funders Author Manuscripts

Europe PMC Funders Author Manuscripts

Table 2

Subgroup analysis of patients with brain tumors or brain metastasis included in the Hokusai VTE-Cancer study54 (*n* = 74)

	Edoxaban (*n* = 31)	Dalteparin (*n* = 43)	*p*-value for interaction
Primary outcome,[a] *n* (%)	6 (19.4)	8 (18.6)	0.677
Recurrent VTE, *n* (%)	5 (16.1)	5 (11.6)	0.180
Major bleeding, *n* (%)	2 (6.5)	4 (9.3)	–

Abbreviation: VTE, venous thromboembolism.

[a]Composite of recurrent VTE or major bleeding during 12 months after randomization.