



Published in final edited form as:

*Urology*. 2018 November ; 121: 175–181. doi:10.1016/j.urology.2018.06.052.

## Outcomes and Quality of Life Among Men After Anal Sphincter-Sparing Transperineal Rectourethral Fistula Repair

Lindsay A. Hampson, MD MAS<sup>a,d</sup>, Wade Muncey, MD<sup>b,e</sup>, Mika N. Sinanan, MD PhD<sup>c</sup>, and Bryan B. Voelzke, MD MS<sup>a</sup>

<sup>a</sup>University of Washington, Department of Urology

<sup>b</sup>University of Washington, School of Medicine

<sup>c</sup>University of Washington, Department of Surgery

<sup>d</sup>University of California San Francisco, Department of Urology

<sup>e</sup>Case Western Reserve University, Department of Urology

### Abstract

**Objective:** To describe long-term quality of life (QOL) outcomes after rectourethral fistula (RUF) repair. RUF is a debilitating diagnosis and complex surgical dilemma with limited data regarding QOL after repair.

**Methods:** Patients at a tertiary referral center undergoing transperineal RUF repair 1/2009 – 5/2016 were analyzed. Patients were contacted by telephone to assess QOL following repair. Descriptive analysis performed of short-term surgical data (success and complications) and long-term QOL data (novel questionnaire).

**Results:** 21 men underwent RUF surgery with 95% success after initial repair. 52% had a history of radiation/ablation. 4 individuals (19%) experienced a Clavien-Dindo complication within 30 days, with 3 of those being grade III+. 15 had post-operative urinary incontinence, of whom 73% underwent artificial urinary sphincter placement. Three previously radiated individuals underwent subsequent urethral stricture surgery. At long-term follow-up (mean 45.6 ± 27.1 months), 53% reported perineal pain, 43% reported problems related to the gracilis flap, and 80% reported urinary incontinence (primarily occasional mild leakage). 21% were unable to do the things they wanted in their daily lives, while 80% reported that surgery positively impacted their life. None would have opted for complete urinary diversion.

**Conclusion:** RUF repair leads to patient satisfaction and improved QOL, despite possible residual issues such as perineal pain and urinary incontinence. Definitive RUF repair should be offered to suitable radiated and non-radiated patients.

---

Corresponding author: Dr. Bryan B. Voelzke, Associate Professor, Dept. of Urology, Harborview Medical Center, 325 9<sup>th</sup> Avenue, Box 359868, Seattle, WA 98101, Phone: 206-744-6384, Fax: 206-543-3272, voelzke@uw.edu.

**Publisher's Disclaimer:** This is a PDF file of an unedited manuscript that has been accepted for publication. As a service to our customers we are providing this early version of the manuscript. The manuscript will undergo copyediting, typesetting, and review of the resulting proof before it is published in its final form. Please note that during the production process errors may be discovered which could affect the content, and all legal disclaimers that apply to the journal pertain.

**Keywords**

gracilis flap; incontinence; outcomes; quality of life; rectourethral fistula; urethral stricture

**INTRODUCTION**

Rectourethral fistula (RUF) is a debilitating diagnosis and complex surgical dilemma. RUF is most often related to the treatment of pelvic cancers, but can also result from pelvic trauma, iatrogenic injury, inflammatory and neoplastic conditions, and infection. [1] There are variety of surgical approaches, including transabdominal, transanal, transsphincteric and transperineal approaches.[2] Utilization of tissue interposition flaps or grafts is done in many cases, most often a gracilis flap.[3] Overall success of fistula repair is high, up to 87.5% in one systematic review of 416 RUF repairs, with 8.3% permanent urinary diversion and 10.6% permanent fecal diversion rates. [3]

There are few reported studies about quality of life (QOL) following RUF repair. One study of 13 patients who underwent transperineal repair with gracilis muscle interposition showed that 75% of the patients had some degree of urinary incontinence, and 25% had fecal incontinence after repair. [4] Six of the 13 patients (46%) reported urinary symptoms that interfered with their lives “somewhat” or “a lot”. This study suggests that that even after repair, residual urinary and fecal symptoms may persist and impact QOL.

Given limited qualitative data, we examined the long-term functional and QOL outcomes in patients undergoing anal sphincter-sparing transperineal RUF repair. We hypothesized that RUF repair would lead to improvements in QOL.

**PATIENTS & METHODS**

21 men underwent anal sphincter-sparing transperineal RUF repair between January 2009 and May 2016 at the University of Washington. In all cases, patients had a suprapubic tube placed and the absence of a urethral catheter for at least 6 weeks prior to repair. A transperineal anal sphincter-sparing surgical approach was utilized. Repair of the urethral fistula was based upon the location and size of the fistula, with a buccal graft utilized when necessary. The rectal side of the fistula was closed primarily after rectal mobilization, and an interposition muscle flap was utilized for all radiated/ablative fistulae and select non-radiated repairs. One urological and one colorectal surgeon participated in all surgical repairs. Urological objective success was defined as: absence of fistula on voiding cystourethrogram at the time of catheter removal, resolution of RUF on cystoscopy at 3 months, and absence of adjuvant fistula-related procedures. All patients underwent cystoscopy at 3 months and 1 year to assess for stricture formation.

Patient data were abstracted via retrospective chart review. Long-term QOL was assessed in all patients who could be reached by telephone. To minimize bias, the operating surgeons (BV & MS) were excluded from obtaining QOL data. No validated questionnaire exists for RUF. A novel survey was designed to evaluate long-term functional and QOL issues related to RUF. (Supplemental Material) Questions regarding daily activities and depression were

added from the PROMIS® measures (©2006-2017 PROMIS Health Organization, Evanston, Illinois, USA).

Descriptive analyses were undertaken using STATA® (STATA Corporation, Texas, USA). Given the small size of the study cohort, univariate and multivariate analyses were not performed. IRB approval at the University of Washington was obtained for this study (IRB# 40963).

## RESULTS

21 men fit the selection criteria for having undergone rectal-sparing transperineal RUF repair. (Table 1 and Supplementary Table) The median  $\pm$  interquartile range (IQR) time from diagnosis to referral was  $10.5 \pm 22.0$  months. Median age at the time of surgery was  $62.7 \pm 18.5$ . Most fistulae were related to prior treatment for prostate cancer (71 %). Just over half (11/21) had undergone radiation or ablation therapy. 20% had undergone RUF repair prior to referral. The vast majority (90%) underwent fecal diversion prior to RUF repair with one additional person with a history of imperforate anus undergoing permanent diversion at the time of repair.

Upon presentation, the majority noted pneumaturia (15/21), one-third (7/21) noted urethral or bladder pain, over one-fourth (6/21) presented with recurrent urinary tract infections, and a few individuals presented with other symptoms such as dysuria (3/21), urinary retention (1/21), straining with urination (3/21), or sensation of incomplete emptying (2/21). Most patients (81%) had pre-existing erectile dysfunction. Nine patients (43%) had a concomitant urethral stricture at presentation.

All patients underwent an anal sphincter-sparing, transperineal repair. Three patients required a combined abdomino-perineal approach. The fistula was located at the bladder neck in six cases, prostatic urethra in five cases, membranous urethra in four cases, the bulbar urethra in two cases, prostatic-membranous in 3 cases, and prostatic-membranous-bulbar in one case. In terms of the urethral repair, fourteen patients underwent fistula excision with anastomotic urethroplasty. Ventral-onlay buccal mucosal graft urethroplasty supported by gracilis flap (n=5) and primary closure of the fistula edges (n=2) was performed in the remaining patients. Partial pubectomy was necessary in one patient. The rectal side of the fistula was repaired by mobilizing the rectum laterally and proximally, debriding the fistula margins, and performing a transverse, two-layer anterior rectal wall closure without tension. Twenty patients had an interposition muscle flap harvested to buttress the RUF repair and/or fill the dead space (19 patients with gracilis flap interposition (3 with bilateral gracilis) and 1 patient with rectus flap interposition).

After surgery, a catheter was maintained for 4-6 weeks. Voiding cystourethrogram was performed before catheter removal, to ensure no leak or fistula recurrence. Four patients had at least one complication within 30 days (3/11 in the radiated/ablated group, and 1/10 in the non-radiated group). Complications included a perineal abscess requiring incision and drainage (I&D) (2), pelvic abscess requiring I&D (1), wound dehiscence requiring repeat primary closure (1), acute kidney injury (1), gastrointestinal bleed requiring endoscopy (1),

urinary tract infection treated with antibiotics (1), and deep venous thrombosis treated with anticoagulation (1).

Successful RUF repair occurred in 95% of patients after initial RUF repair (mean follow-up 2.6 years). The one patient with RUF persistence had a large HIFU-related RUF following initial repair with a single gracilis flap and underwent successful repeat RUF repair with contralateral gracilis flap one year later. Three patients, all of whom were previously radiated and had a pre-operative urethral stricture, developed a urethral stricture recurrence requiring surgery. This urethroplasty was successful for two patients (follow-up 2 and 5 years), while the other required a subsequent endoscopic bladder neck incision with Mitomycin C injection (patent cystoscopic urethra at 3 years followup). At the time of chart review, 6 individuals (29%) still had a fecal diversion (10% for non-radiated cases versus 45% for radiated cases).

Regarding urinary incontinence, 15/21 (71%) experienced urinary incontinence after RUF repair. Four patients chose to manage this with pads (1 with small leakage, 2 with moderate leakage, 1 with large leakage), and eleven underwent artificial urinary sphincter (AUS) placement at a median of 12 months from RUF repair (perineal n=8; trans-scrotal n=3). Eight individuals had placement of a trans-corporal AUS cuff. Our standard is generally to place a trans-corporal cuff in all patients with a history of radiation, and in any non-irradiated patients who would have otherwise required a 3.5 cm cuff.

At the time of long-term telephone follow-up, two patients had died of unrelated causes. Fifteen patients (71%) were reached for follow-up (mean  $44.6 \pm 27.1$  months) (Table 2). Among these patients, none required additional RUF-related surgery. Half of the patients (53%) reported perineal pain (mean  $2.1 \pm 1.3$ ; 10-point scale where 0 = no pain and 10 = worst pain). 43% reported residual problems related to the gracilis (one each with numbness, weakness, limited groin mobility, difficulty walking/climbing stairs, occasional leg cramping, and leg swelling; none reported pain). Of the patients contacted, 80% reported continued urinary incontinence, the majority with occasional mild leakage (Figure 1). All patients with an AUS had no or only a small amount of leakage after AUS placement (mean  $\pm$  SD time from AUS placement =  $37.8 \pm 54.3$  months). One individual with large amount of leakage at long-term follow-up had had his AUS removed due to pain. He had a prior history of radiation and his pain did improve with removal of the AUS cuff, although he still reported some mild residual perineal pain (3/10) at long-term follow-up. To date, no individuals have required AUS removal due to infection or erosion.

87% of patients were satisfied or very satisfied with the outcome of the operation (mean satisfaction  $3.5 \pm 0.7$ , 4-point scale where 1 = very unsatisfied and 4 = very satisfied). Most (80%) felt the surgery led to a positive change in their lives. Those who did not report a positive change attributed this to the inability to be intimate or due to constant urinary leakage. Half of patients reported not being able to do the things they want to do in their daily lives, with 43% attributing this to the RUF and/or RUF surgery.

Regarding PROMIS® questions specific to general daily lives, 11/14 reported that they were moderately, mostly, or completely able to carry out “everyday physical activities such as

walking, climbing stairs, carrying groceries, or moving a chair”. Only one person reported that in the past seven days, they had been often or always “bothered by emotional problems such as feeling anxious, depressed, or irritable” (Figure 2).

87% of patients reported that they would undergo surgery again, and 80% would recommend it to others. Nine patients reported they would have done things differently: four would have initially sought a different treatment or provider for the RUF-inciting medical condition, three would have undergone RUF repair sooner, two would have sought a referral to a reconstructive specialist in lieu of local repair, and one would have requested bilateral over unilateral gracilis flap. None would have opted for complete urinary diversion instead of RUF repair.

## DISCUSSION

Our outcomes are comparable to other large series that show a similar success rate among radiated or ablated patients (range 84–87%).<sup>[5,6]</sup> Likely these relatively high success rates, even among radiated patients, are a result of utilizing a transperineal approach and interposition muscle flaps when necessary, as some series not using these techniques have reported lower success rates. <sup>[7–9]</sup>

Our reported complication rate was higher among those with previous pelvic radiation/ablation, with a 27% overall complication rate and 18% grade III+ complication rate in this subset, which is comparable to other series which have found that individuals with previous energy ablation therapy have a nearly doubled likelihood of complications compared to non-irradiated patients.<sup>[5,6]</sup> It is worth noting that radiated/ablated patients not only have a higher likelihood of complications, but the complications are often more severe, with higher Clavien-Dindo grades. In our series, grade III+ complications occurred in only 10% of non-radiated compared to 18% of radiated individuals, often requiring surgical intervention for abscess drainage or repair of wound dehiscence. Published series from larger patient cohorts at centers of excellence have noted more severe complications, such as deep venous thromboses, pulmonary emboli, and even death. These data provide valuable information to patients about what to expect when undergoing RUF repairs.

Importantly, when compared to patients undergoing cystectomy with urinary diversion for benign etiologies, the 30-day complication rates for RUF repair are lower.<sup>[10–12]</sup> In a series of 139 cystectomy patients, a 57% rate of Clavien-Dindo grade II+ complications was reported.<sup>[10]</sup> Another series noted a 47% rate of Clavien-Dindo grade III+ complications within 30 days.<sup>[11]</sup> The authors reported that complications among patients with fistulae were more likely than those patients undergoing cystectomy for neurogenic bladder. 44% (4/9) of their patient cohort who underwent cystectomy for neurogenic bladder developed a 30-day complication, compared to 100% of patients with a radiation-induced fistulae ( $p = 0.03$ ) and 78% (7/9 patients,  $p = 0.34$ ) of patients with non-radiation-induced fistulae. Their results highlight the finding that complications among patients with any type of fistula are high. A third series evaluating cystectomy for benign disease secondary to radiation therapy found a 65.5% rate of 30-day complications, of which 20% were Clavien-Dindo grade III+. <sup>[12]</sup> When combined with our data, these studies help set expectations when counseling

patients regarding the potential for serious complications during recovery regardless of the type of treatment – staged fistula repair versus cystectomy with diversion. We found it very interesting that in our series, even among patients who were not satisfied with surgery, no patient would have chosen urinary diversion over RUF repair.

When asking patients about their quality of life in long-term follow-up, we were surprised that some patients attributed symptoms to the gracilis flap. This complaint has not been evident during clinical visits, and came to light only with specific questioning. Over 40% of patients reported problems related to the gracilis flap. While these problems were minor, this information has subsequently improved our patient counseling prior to RUF repair.

Surgical repair of a RUF is technically challenging. Recovery and healing can be complicated by the fact that most patients are older and may have poor QOL prior to repair. While we did not assess preoperative QOL in this study, another study of patients undergoing cystectomy and diversion for benign etiologies showed that in five of the eight QOL domains, patients scored at or below the national average. There was an “exceptional detriment” in the mental domain that assessed “role limitations due to emotional problems” with a median score of 0 on a 100-point scale normalized to a mean score of 50.[12] The authors note that this is similar to QOL findings among patients undergoing treatment for refractory anal fistulae, where patients had scores below the national average in 6 of 8 domains.[13] This is reflected in our own data where, even after RUF repair, half of patients report not being able to do the things they want to do in their daily lives, and 10% of patients reported some fecal incontinence. In spite of this, our findings show that RUF repair does lead to improvements in QOL, with a vast majority reporting that surgery lead to a positive change in their lives and that they would make the same choice again.

QOL for these patients can often be further improved by treating their incontinence. In our study, all patients who had an AUS in place at the time of follow-up had only a small amount of leakage at most. This is similar to another small series that reported that all six individuals who underwent artificial urinary sphincter placement after transperineal RUF repair were using 1 pad per day at 3 months of follow-up. AUS placement is durable in our limited series, with only one patient who underwent AUS removal for pain. This is similar to one other small series of AUS after RUF showing that, with a median follow-up of 43.5 months, there were no revisions or removals for infection, erosion, or mechanical complications.[14] Published data supports treating urinary incontinence, as it can lead to significant improvements in overall QOL, and thus this can be a key step in improving patient-centered outcomes in these patients who have overall poor QOL.[15,16]

This is the first study to report on comprehensive QOL outcomes following RUF. However, this study is not without its limitations, as it is a small, single-institution series. Given the lack of QOL data following RUF repair, our contribution does add to the existing data pool and allows for meta-analyses that can draw from existing series. Since there is no validated patient-reported outcome measure for QOL or symptoms following RUF, we were unable to use a validated questionnaire. Instead, we utilized validated PROMIS® questions and asked additional QOL questions to target content that we hypothesized was most important following RUF repair. As evidenced by our results, surgical success is more than a lack of



recurrence following RUF repair. A validated patient-reported outcome measure for RUF repair is needed to better analyze outcomes; however, the rarity of this condition may preclude validation of such a measure. In the absence of such a measure, utilization of a generic validated QOL measure would be a significant addition to merely reporting anatomic success.

## CONCLUSION

RUF repair leads to patient satisfaction and improvement in QOL, despite possible residual issues such as mild perineal pain, minor problems related to gracilis flap, and urinary incontinence. Definitive RUF repair should be offered to radiated and non-radiated patients who are suitable candidates.

## Supplementary Material

Refer to Web version on PubMed Central for supplementary material.

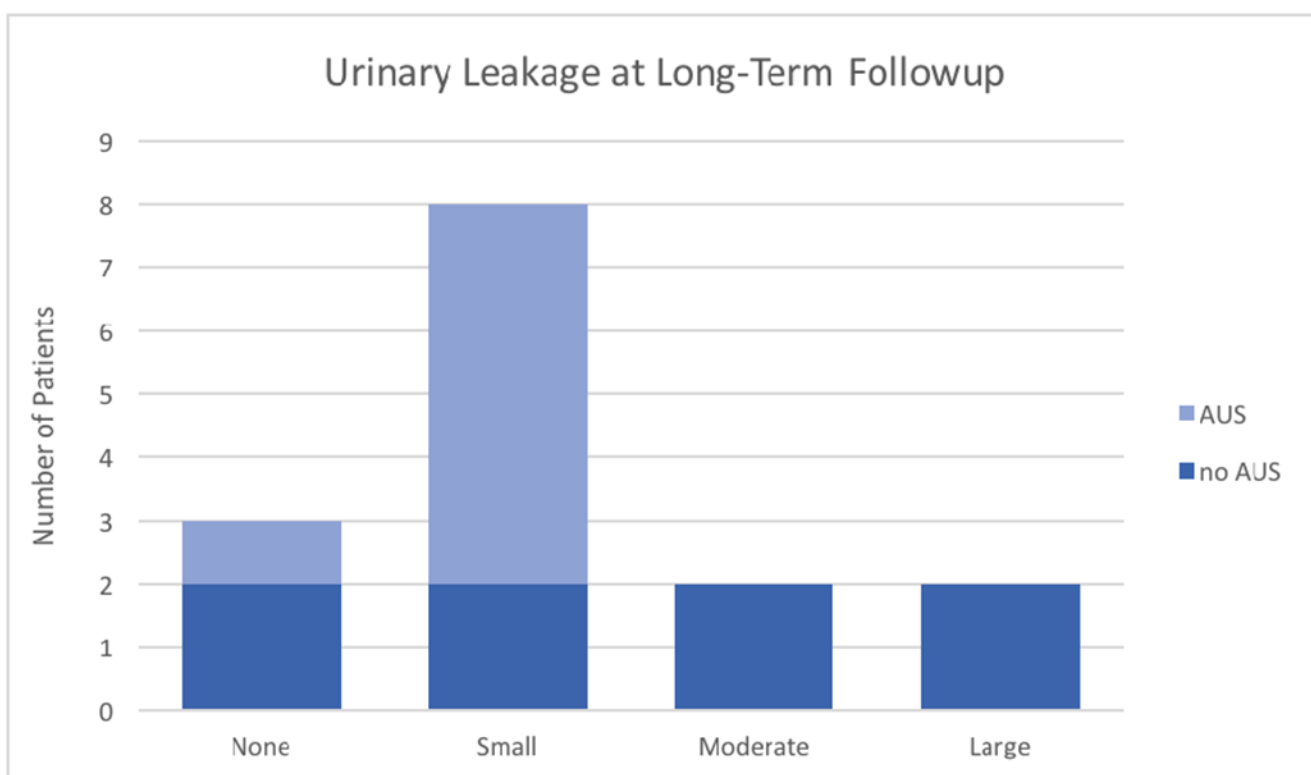
## REFERENCES

- [1]. Singla N, Morey AF. Rectourethral fistula reconstruction in elderly patients. *Current Opinion in Urology* 2016;26:171–6. doi: 10.1097/MOU.0000000000000263. [PubMed: 26716565]
- [2]. Bukowski TP, Chakrabarty A, Powell IJ, Frontera R, Perlmutter AD, Montie JE. Acquired rectourethral fistula: methods of repair. *The Journal of Urology* 1995;153:730–3. [PubMed: 7861523]
- [3]. Hechenbleikner EM, Buckley JC, Wick EC. Acquired rectourethral fistulas in adults: a systematic review of surgical repair techniques and outcomes. *Dis Colon Rectum* 2013;56:374–83. doi: 10.1097/DCR.0b013e318274dc87. [PubMed: 23392154]
- [4]. Samplaski MK, Wood HM, Lane BR, Remzi FH, Lucas A, Angermeier KW. Functional and quality-of-life outcomes in patients undergoing transperineal repair with gracilis muscle interposition for complex rectourethral fistula. *Urology* 2011;77:736–41. doi:10.1016/j.urology.2010.08.009. [PubMed: 21377021]
- [5]. Harris CR, McAninch JW, Mundy AR, Zinman LN, Jordan GH, Andrich D, et al. Rectourethral Fistulas Secondary to Prostate Cancer Treatment: Management and Outcomes from a Multi-Institutional Combined Experience. *The Journal of Urology* 2017;197:191–4. doi:10.1016/j.juro.2016.08.080. [PubMed: 27544625]
- [6]. Vanni AJ, Buckley JC, Zinman LN. Management of surgical and radiation induced rectourethral fistulas with an interposition muscle flap and selective buccal mucosal onlay graft. *The Journal of Urology* 2010;184:2400–4. doi:10.1016/j.juro.2010.08.004. [PubMed: 20952036]
- [7]. Beddy D, Poskus T, Umbreit E, Larson DW, Elliott DS, Dozois EJ. Impact of radiotherapy on surgical repair and outcome in patients with rectourethral fistula. *Colorectal Dis* 2013;15:1515–20. doi:10.1111/codi.12350. [PubMed: 23841640]
- [8]. Hanna JM, Peterson AC, Mantyh C. Rectourethral fistulas in the cancer survivor. *Current Opinion in Urology* 2014;24:382–8. doi: 10.1097/MOU.0000000000000073. [PubMed: 24841377]
- [9]. Linder BJ, Umbreit EC, Larson D, Dozois EJ, Thapa P, Elliott DS. Effect of prior radiotherapy and ablative therapy on surgical outcomes for the treatment of rectourethral fistulas. *The Journal of Urology* 2013;190:1287–91. doi:10.1016/j.juro.2013.03.077. [PubMed: 23538238]
- [10]. Osborn DJ, Dmochowski RR, Kaufman MR, Milam DF, Mock S, Reynolds WS. Cystectomy with urinary diversion for benign disease: indications and outcomes. *Urology* 2014;83:1433–7. doi:10.1016/j.urology.2014.02.030. [PubMed: 24767824]
- [11]. Cohn JA, Large MC, Richards KA, Steinberg GD, Bales GT. Cystectomy and urinary diversion as management of treatment-refractory benign disease: the impact of preoperative urological

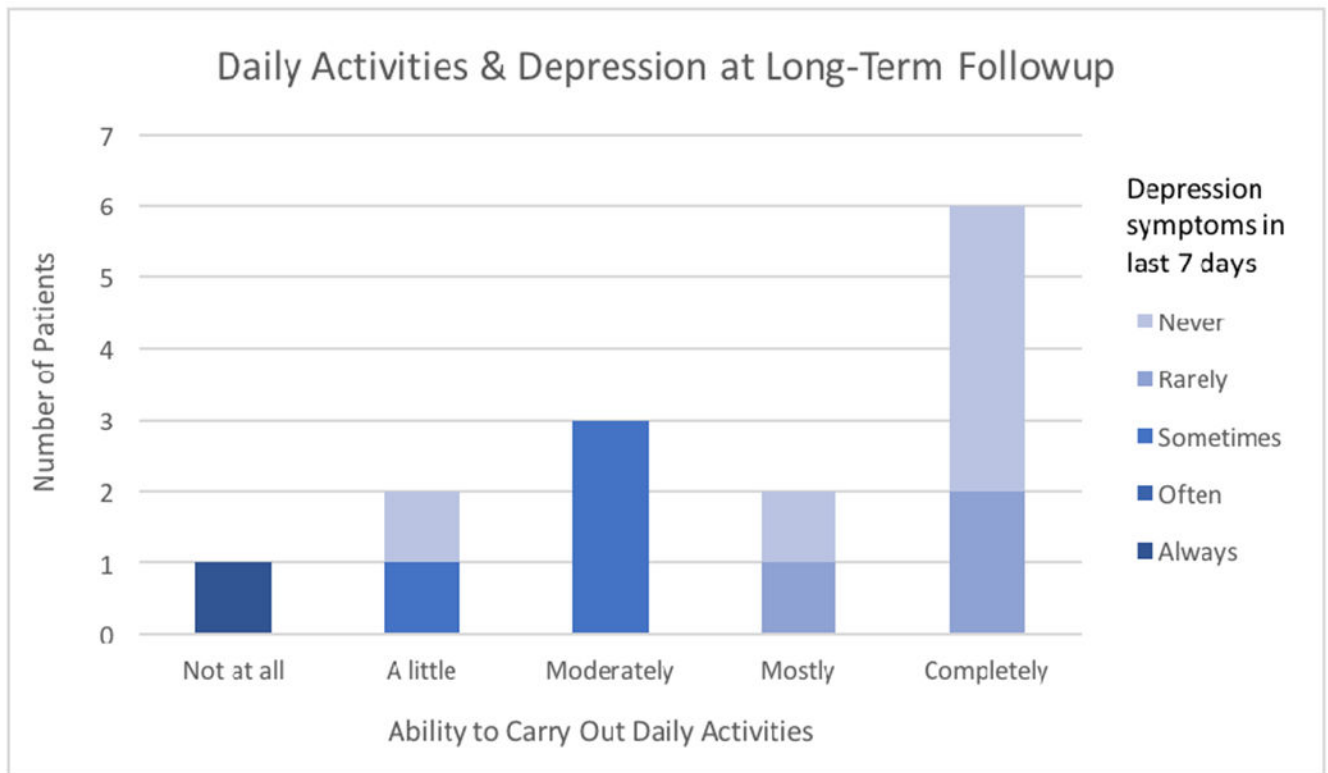
conditions on perioperative outcomes. *Int J Urol* 2014;21:382–6. doi:10.1111/iju.12284. [PubMed: 24118653]

- [12]. Hussein Al Awamlh Al B, Lee DJ, Nguyen DP, Green DA, Shariat SF, Scherr DS. Assessment of the quality-of-life and functional outcomes in patients undergoing cystectomy and urinary diversion for the management of radiation-induced refractory benign disease. *Urology* 2015;85:394–400. doi: 10.1016/j.urology.2014.08.047. [PubMed: 25623700]
- [13]. Adamina M, Ross T, Guenin MO, Warschkow R, Rodger C, Cohen Z, et al. Anal fistula plug: a prospective evaluation of success, continence and quality of life in the treatment of complex fistulae. *Colorectal Dis* 2014;16:547–54. doi:10.1111/codi.12594. [PubMed: 24521307]
- [14]. Selph JP, Madden-Fuentes R, Peterson AC, Webster GD, Lentz AC. Long-term Artificial Urinary Sphincter Outcomes Following a Prior Rectourethral Fistula Repair. *Urology* 2015;86:608–12. doi:10.1016/j.urology.2015.06.012. [PubMed: 26141139]
- [15]. Holm HV, Fosså SD, Hedlund H, Dahl AA. Study of generic quality of life in patients operated on for post-prostatectomy incontinence. *Int J Urol* 2013;20:889–95. doi: 10.1111/iju.12077. [PubMed: 23418855]
- [16]. Wingate JT, Erickson BA, Murphy G, Smith TG, Breyer BN, Voelzke BB. Multicenter Analysis of Patient Reported Outcomes Following Artificial Urinary Sphincter Placement for Male Stress Urinary Incontinence. *The Journal of Urology* 2017. doi: 10.1016/j.juro.2017.09.089.





**Figure 1:**  
Urinary incontinence following RUF repair and possible adjuvant AUS placement.



**Figure 2:**  
Patient assessment of ability to perform daily activities and depression following RUF repair.

**Table 1:**

## Demographic and Surgical Characteristics

	Non-Radiated n = 10	Radiated/Ablated n = 11
Age (mean $\pm$ SD)	53.8 $\pm$ 16.8	66.5 $\pm$ 8.6
Preop erectile dysfunction	5/7 (71%)	8/9 (89%)
Disease etiology		
Prostate cancer	6 (60%)	10 (91%)
Trauma	2 (20%)	0
Rectal cancer	1 (10%)	0
Other	1 (10%)	1 (9%)
Prior RUF repair	2 (20%)	2 (18%)
Parks transanal repair	1	1
York-Mason repair	1	0
Transperineal repair	0	1
Fecal diversion		
Prior to RUF repair	8 (80%)	11 (100%)
At the time of diversion	1 (10%)	0
No fecal diversion	1 (10%)	0
Urethral stricture or BNC	4 (40%)	5 (45%)
Fistula location		
Bladder neck	6 (60%)	0
Prostatic urethra	0	5 (45%)
Membranous urethra	2 (20%)	2 (18%)
Prostato-membranous	1 (10%)	2 (18%)
Bulbar urethra	1 (10%)	1 (9%)
Prostato-membranous-bulbar	0	1 (9%)
Surgical approach		
Abdomino-perineal	0	2 (18%)
Gracilis flap	9 (90%)	11 (100%)
Rectus flap	1 (10%)	0
Partial pubectomy	1 (10%)	0
Urethral repair		
Anastomotic urethroplasty	5 (50%)	9 (82%)
Ventral-onlay BMG	3 (30%)	2 (18%)
Primary closure	2 (20%)	0
30-day complication rate	1 (10%)	3 (27%)
Clavien-Dindo Grade III+	1 (10%)	2 (18%)
Initial definitive repair	10 (100%)	10 (91%)
Successful adjuvant repair	n/a	1 (100%)

**Table 2:****Functional and Quality of Life Outcomes in Long-Term Follow-up**

	Non-Radiated n = 6	Radiated/Ablated n = 9
Reversal of fecal diversion	4/5 * (80%)	4/9 (44%)
Perineal pain present	2/6 (33%)	6/9 (67%)
Pain scale, 0-10 (mean $\pm$ SD)	1.5 $\pm$ 0.7	2.3 $\pm$ 1.2
Problem related to gracilis flap	2/6 (33%)	4/9 (44%)
AUS placed	2/6 (33%)	5/9 (56%)
Transperineal	2/3	2/4
Transscrotal	1/3	2/4
Transcorporal	2/3	4/4
Mean time from AUS placement (in months)	44.6 $\pm$ 83.7	33.2 $\pm$ 32.1
Current urinary incontinence	4/6 (67%)	8/9 (89%)
Small leakage	1/6 (25%)	6/8 (75%)
Moderate leakage	2/6 (50%)	0/8 (0%)
Large leakage	1/6 (25%)	2/8 (25%)
Satisfaction with outcome (mean $\pm$ SD)	3.5 $\pm$ 0.8	3.6 $\pm$ 0.7
Very satisfied (score = 4)	4/6 (67%)	6/9 (67%)
Satisfied (score = 3)	1/6 (17%)	2/9 (22%)
Unsatisfied (score = 2)	1/6 (17%)	1/9 (11%)
Very unsatisfied (score = 1)	0/6 (0%)	0/9 (0%)
Positive change in life	5/6 (83%)	7/9 (78%)
Able to do the things you want in your daily life	4/6 (67%)	3/8 (38%)
PROMIS Physical activity ** (mean $\pm$ SD)	4.3 $\pm$ 1.0	3.3 $\pm$ 1.5
PROMIS Emotional ** (mean $\pm$ SD)	4.3 $\pm$ 1.0	3.6 $\pm$ 1.3
Would undergo same surgery again	6/6 (100%)	7/9 (78%)
Would recommend surgery	6/6 (100%)	6/9 (67%)
Urinary diversion instead	0/6 (0%)	0/9 (0%)
Follow-up (months)	48.5 $\pm$ 25.0	43.0 $\pm$ 30.3

\* One non-radiated individual was never diverted before RUF and remained undiverted after RUF repair

\*\* PROMIS questions and scoring:

**Physical activity:** To what extent are you able to carry out your everyday physical activities such as walking, climbing stairs, carrying groceries, or moving a chair? 1 – not at all, 2 – a little, 3 – moderately, 4 – mostly, 5 – completely.

**Emotional:** In the past 7 days, how often have you been bothered by emotional problems such as feeling anxious, depressed, or irritable? 1 – always, 2 – often, 3 – sometimes, 4 – rarely, 5 – never.