



ORIGINAL ARTICLE

Differential Benefit of Two Different Tooth-Borne Rapid Maxillary Expansion Appliances in Female Subjects

Lale Taner, Gamze Metin-Gürsoy, Naciye Derin Sarısu-Demircioğlu

Department of Orthodontics, Gazi University University School of Dentistry, Ankara, Turkey

Cite this article as: Taner L, Metin-Gürsoy G, Sarısu-Demircioğlu ND. Differential Benefit of Two Different Tooth-Borne Rapid Maxillary Expansion Appliances in Female Subjects. Turk J Orthod 2018; 31: 67-72.

ABSTRACT

Objective: The aim of the present study was to evaluate the effects of tooth-borne acrylic-bonded rapid maxillary expansion (RME) appliances with or without the anterior teeth anchorage on the skeletal and dentoalveolar structures, as well as soft tissues.

Methods: This study included 44 patients who were treated with two different tooth-borne bonded acrylic RME appliances. Lateral cephalometric radiographs were taken before the treatment (T0) and in the post-retention (T1) phase of the RME treatment. The posterior-bonded RME appliance group and full-bonded RME appliance group were created as the two different groups of treatment. The following statistical analyses were performed: intra- and inter-group comparisons were made using the paired t-test, Wilcoxon test, independent t-test, and Mann-Whitney U-test for normal and non-normal distribution data.

Results: Significant increases were observed in R1-A, R1-ANS, R1-U1, R1-AR, R1-St, R1-Li, and R1-Pn in both groups. R1-PNS, R1-Ls, R1-Sn, and R1-B' were found to be significantly larger at T1 than at T0 in the posterior-bonded RME appliance group. R2-A, R2-ANS, R2-L1, R2-A', and R2-Pn were significantly larger at T1 than at T0 in the full-bonded RME appliance group. The R2-A' was significantly different between the groups.

Conclusion: The soft tissue A point appears to be the most important differing matter between the two different RME appliances, and a full acrylic-bonded RME appliance may be beneficial for subjects with a maxillary retrognathic profile.

Keywords: Rapid maxillary expansion, growing subjects, tooth-borne expander, soft tissue profile

INTRODUCTION

Maxillary transverse deficiency is one of the most common skeletal and dental problems and may be observed as posterior cross-bite at the primary, mixed, or permanent dentition at an incidence of 9.6%, 12%, and 14%, respectively (1, 2). When maxillary narrowing is diagnosed, treatment should be started as soon as possible to provide a normal growth and development of the craniofacial structures and soft tissue (3).

Treatment of maxillary transverse deficiency was conducted with appliances which use the orthopedic forces demonstrated by Angell (4) during 1860s. About 100 years after these studies, Haas's (5) work has increased the interest in RME. To date, many different types of appliances have been used to treat transverse skeletal disharmonies. The overall objective of these appliances is to create a force greater than the optimum amount to accomplish the opening of the median palatine suture. Although there are varying designs, a tooth-borne appliance, as opposed to an implant-borne appliance, has historically been the appliance most widely used (6). Studies showed that changes occurred in the maxilla, dentoalveolar structures, bone associated with the maxilla, and the surrounding soft tissues after the RME treatment (6, 7). The design of the RME device may sometimes cause undesirable changes in the anchorage area (8).

The aim of the present study was to assess the effects of tooth-borne acrylic-bonded RME appliances with and without inclusion of the anterior teeth on the skeletal structures, dentoalveolar structures, and soft tissues.

Address for Correspondence: Gamze Metin Gürsoy, Department of Orthodontics, Gazi University University School of Dentistry, Ankara, Turkey
E-mail: gamgursoy@gmail.com

©Copyright 2018 by Turkish Orthodontic Society - Available online at www.turkjorthod.org

Received: 22 November 2017

Accepted: 8 February 2018

Available Online Date: 11 July 2018

METHODS

This study was approved by the Ethical Committee of Gazi University (10.09.2015/08).

A sample of 44 female subjects treated with tooth-borne acrylic-bonded RME appliances was included from the Department of Orthodontics, Gazi University. Inclusion criteria of the subjects were as follows:

- No history of orthodontic or orthopedic treatments
- Age of the subjects between 9.5 and 13.5 years
- Female subjects with bilateral cross-bite

Two groups were created according to inclusion of the anterior teeth in the acrylic block for the RME treatment; Group1 (n=22) included the subjects treated with the posterior acrylic-bonded tooth-borne RME appliance (Figure 1a), whereas Group2 (n=22) included subjects treated with the full acrylic-bonded tooth-borne RME appliance (Figure 1b). The acrylic part of the appliance was extended over the occlusal, palatal, and vestibular surfaces of the included teeth. The vertical height of the occlusal acrylic was limited to the freeway space with the occlusal acrylic having a contact with all lower teeth except the anterior teeth in Group1. The standardized lateral cephalometric radiographs were taken in the pre-treatment (T0) and post-retention (T1) phases of RME (Orthophos XG 5 DS/Ceph, Sirona Dental System, Bensheim, Germany).

After all the RME appliances were installed, the screws were activated as one turn/day until the palatal cusp of the maxillary first molar occluded on the most superior portion of the lingual-buccal incline of the corresponding mandibular tooth. All the patients underwent retention, and the appliances were removed approximately 6 months after the active expansion phase.

The measurements were made according to the R1 and R2 coordinate system. R1 was constructed 7° to the SN plane, and R2 was constructed perpendicular to R1 at sella (Figure 2) (9). For didactic purposes, the cephalometric measurements were presented as in the following three groups:

1. Skeletal values: SN-GoGn, SNA, SNB, ANB, R1-A, R1-ANS, R1-PNS, R2-A, R2-ANS, and R2-PNS
2. Dental values: R1-U1, R1-Ar, R1-L1, R2-U1, R2-Ar, and R2-L1
3. Soft tissue values: R1-Ls, R1-St, R1-Sn, R1-A', R1-B', R1-Li, R1-Pn, R2-Ls, R2-St, R2-Sn, R2-A', R2-B', R2-Li, R2-Pn, and NLA

Statistical Analysis

All the analyses were performed through the Statistical Package for Social Sciences (SPSS) statistical software program version 20 (IBM Corp.; Armonk, NY, USA). Descriptive statistics and the mean and standard deviations were calculated for all measurements.

The Shapiro-Wilk test was performed to test the normal distribution of the data. The data were not normally distributed in certain cases. Therefore, we used the Wilcoxon test and paired t-test for the normal and non-normal data within group comparisons, respectively. We also used the independent t-test and Mann-Whitney U-test for the normal and non-normal data between group comparisons, respectively.

The values were considered statistically significant at $p \leq 0.05$.

Table 1. Descriptive statistics of the groups

	Groups	N	Mean±SD	p
Chronological age (year)	1	22	11.54±1.5	†0.861
	2	22	11.63±1.5	
Treatment duration (months)	1	22	8.09±2.6	*0.3
	2	22	8.95±3	
SN-GoGn	1	22	35.2±4.8	†0.462
	2	22	34.1±5.2	
ANB	1	22	3.07±2.2	†0.67
	2	22	2.77±2.3	

*The Mann-Whitney U-test was used because the treatment duration was not normally distributed; †Other variables were analyzed with an independent t-test; $p \leq 0.05$.

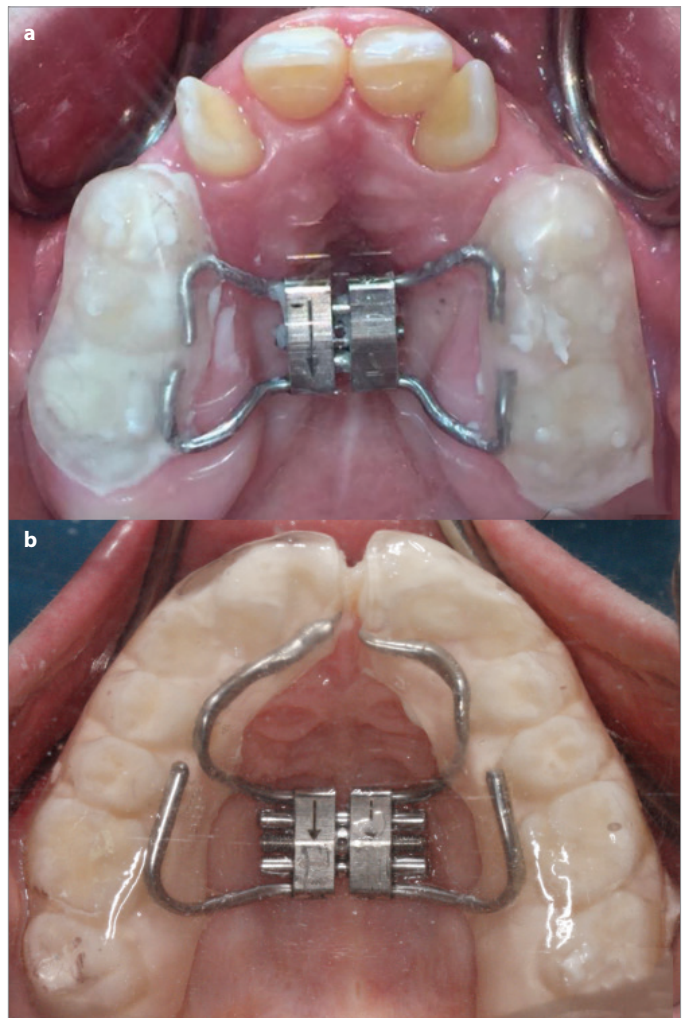


Figure 1. a, b. Posterior acrylic-bonded tooth-borne RME (Group1) (a); full acrylic-bonded tooth-borne RME (Group2) (b)

RESULTS

A power analysis showed that 22 patients would be required for each group for a power of 0.93 at $\alpha = 0.05$.

The two groups analyzed were homogeneous, and there were no statistically significant difference in terms of chronological

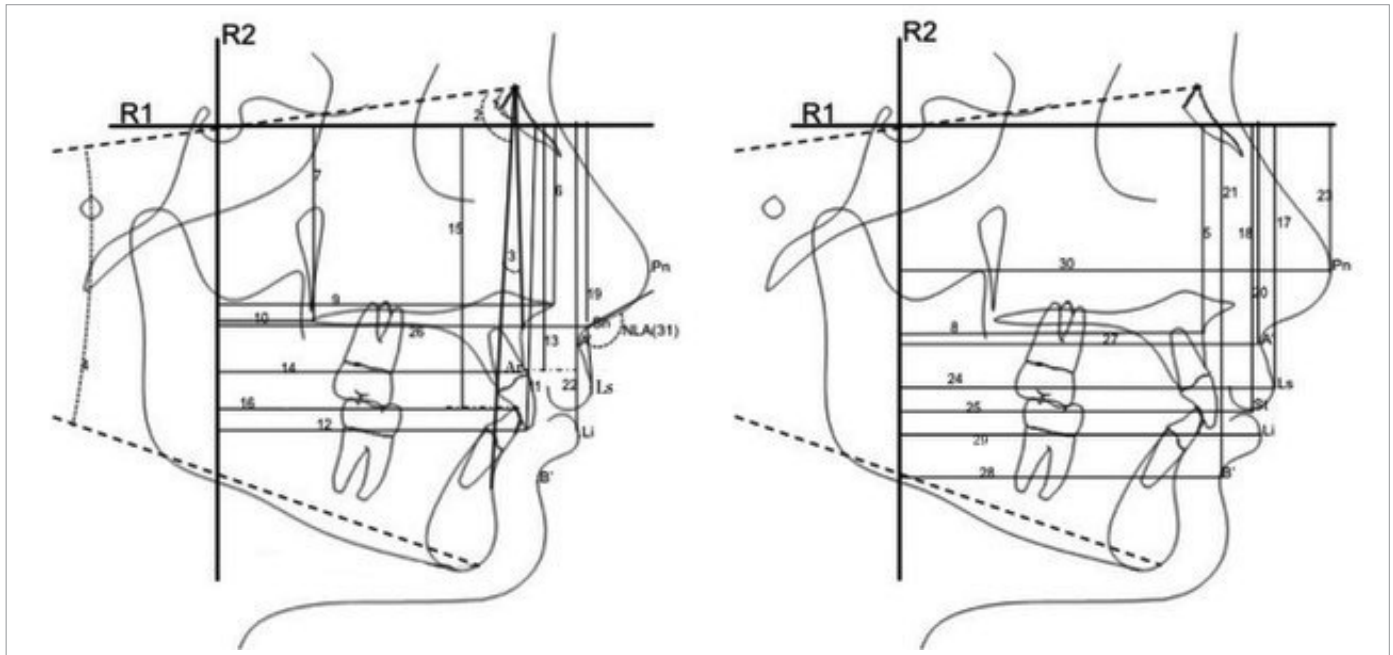


Figure 2. Reference line, landmarks, and measurements

SNA(°)(1), SNB(°)(2), ANB(°)(3), SN-GoGN(°)(4), R1-A(mm)(5), R1-ANS(mm)(6), R1-PNS(mm)(7), R2-A(mm)(8), R2-ANS(mm)(9), R2-PNS(mm)(10), R1-U1(mm)(11), R2-U1(mm)(12), R1-Ar(mm)(13), R2-Ar(mm)(14), R1-L1(mm)(15), R2-L1(mm)(16), R1-Ls(mm)(17), R1-St(mm)(18), R1-Sn(mm)(19), R1-A'(mm)(20), R1-B'(mm)(21), R1-Li(mm)(22), R1-Pn(mm)(23), R2-Ls(mm)(24), R2-St(mm)(25), R2-Sn(mm)(26), R2-A'(mm)(27), R2-B'(mm)(28), R2-Li(mm)(29), R2-Pn(mm)(30), NLA(°)(31)

age, duration of treatment, vertical growth pattern, and skeletal sagittal relationships (Table 1).

The descriptive statistical values and comparisons of the craniofacial, dentoalveolar, and soft tissue changes between Group 1 and 2 at T0-T1 are presented in Table 2.

Skeletal Changes: Significant increases were observed in R1-A and R1-ANS in both groups. R1-PNS ($p=0.004$) was found to be significantly larger at T1 than at T0 in Group 1. R2-A ($p=0.021$) and R2-ANS ($p=0.044$) were found to be significantly larger at T1 than at T0 in Group 2.

Dental and Dentoalveolar Changes: Significant increases were found in R1-U1 and R1-Ar in both groups. R2-L1 ($p=0.049$) was found to be significantly larger at T1 than at T0 in Group 2.

Soft Tissue Changes: Significant increases were found in R1-St, R1-Li, and R1-Pn in both groups. There were significant increases in R1-Ls ($p=0.005$), R1-Sn ($p=0.003$), and R1-B' ($p=0.007$) in Group 1. R2-A' ($p=0.015$) and R2-Pn ($p=0.018$) were found to be significantly greater in Group 2 at T1 than at T0.

R2-A' was significantly different between the groups.

DISCUSSION

The RME treatment is useful for the correction of a narrow transverse maxillary width, unilateral or bilateral posterior cross-bite, and severe maxillary crowding. Many different designs exist for

RME, including tissue-borne, tooth-borne, and bone borne, depending on the age, the cooperation of the patient, and indication (10-13).

In the previous RME studies, the complexity of the groups might have prevented the detection of the pure effects of the appliance. The growth pattern and potential of the patients are the major impediments to determine the pure effects of the RME appliance (7, 14).

In the present study, we preferred to include only female subjects to eliminate the differential growth potentials and craniofacial structures between the genders. The SN-GoGn angle has been used for assessment of the vertical growth, whereas the ANB angle has been used for the prediction of the sagittal skeletal relationship. To identify the sole effects of the RME appliance, the SN-GoGn and ANB angles, duration of the treatment, and the chronological age were matched.

The initial aim of the RME treatment is to obtain the opening of the mid-palatal suture. The researchers paid close attention to the different developmental stages shown by the maturation of the mid-palatal suture (15). The general belief is that the opening ability of the mid-palatal suture decreases after 14-15 years of age (16-18). In the present study, the opening of the mid-palatal suture of all subjects was achieved because the mean age was 11 years 5 months for Group 1 and 11 years 6 months for Group 2. A diastema between the central incisors was observed in all the subjects at the end of treatment. There were no problems, such as pain, oral hygiene, feeding, or cooperation, concerning the RME appliances.

Table 2. Intragroup and inter-group statistical comparison of variables

		Group 1 The Posterior-Bonded RME			Group 2 The Full-Bonded RME			Differences Between the Groups
		T0	T1	p	T0	T1	p	T1-T0
		Mean±SD	Mean±SD		Mean±SD	Mean±SD		p
Skeletal Values	SNA	78.5±3	78.6±3.5	0.71**	79.7±3.9	80±3.7	0.561**	0.924*
	SNB	75.1±3.7	75.4±4.4	0.607**	76±3.5	76.3±3.6	0.608∞	0.636*
	ANB	3.07±2.2	3.14±2.1	0.684∞	2.77±2.3	2.73±2.2	0.863**	0.755†
	SN-GoGn	35.2±4.8	35.7±5.8	0.272**	34.1±5.2	34.6±5.5	0.289**	0.914†
	R1-A	52.4±4.77	53.83±4.8	0.001**	51.45±4	52.3±3.7	0.040**	0.522*
	R1-ANS	45.5±4.1	46.7±4.4	0.001**	44.8±3.1	45.7±2.8	0.001**	0.981*
	R1-PNS	43.9±2.8	44.6±3	0.004**	43.5±3.2	43.9±3	0.168**	0.827*
	R2-A	66±3.7	66±4.2	0.833**	67.5±5.2	68.2±5.3	0.021**	0.086†
	R2-ANS	73.4±3.8	73.7±3.9	0.527**	73.9±5.4	74.9±5.4	0.044**	0.438*
	R2-PNS	18.5±3.8	18.3±4.2	0.56**	19.7±3.4	20.2±3.8	0.083∞	0.135*
Dental and Dentoalveolar Values	R1-U1	73.7±5.5	75.3±6.2	0.001**	72.4±4.1	73.8±4.3	0.001**	0.689†
	R1-Ar	60.5±5.9	62±6.3	0.001**	59.7±4	60.7±4	0.001**	0.2†
	R1-L1	71.2±6.1	72.1±7.4	0.168**	70.1±5.4	71.1±4.5	0.127**	0.671*
	R2-U1	69.5±5.8	68.7±6.5	0.127**	71.8±5.8	72.1±5.4	0.612**	0.098*
	R2-Ar	68.5±4.3	68.1±4.8	0.32**	69.9±6	70.6±5.4	0.1∞	0.06†
	R2-L1	64.6±4.6	64.5±5.6	0.866∞	66.3±6.4	67.2±6.1	0.049**	0.14†
Soft Tissue Values	R1-Ls	64.9±5.3	66.6±5.7	0.005**	64±4.5	64.5±3.8	0.294**	0.435*
	R1-St	70.8±5.4	72.6±5.8	0.001**	69.7±4	70.7±3.7	0.028**	0.421*
	R1-Sn	50.3±5.2	52.2±5.9	0.003**	48.8±4.7	49.7±4.4	0.075**	0.286*
	R1-A'	56.6±5.4	57.6±6	0.061**	55±4.4	55.3±4.1	0.42**	0.321*
	R1-B'	88.3±6.7	89.9±7.8	0.007**	87.3±4.6	88.2±4.7	0.074**	0.339†
	R1-Li	78.8±5.9	80.5±6.7	0.005**	77.8±4	79±4.4	0.007**	0.465†
	R1-Pn	38.6±4.6	39.9±5	0.019**	37±3.5	38±4.2	0.001**	0.516*
	R2-Ls	84±4.9	83.6±5.6	0.548**	86.1±6.1	86.8±5.6	0.078**	0.141†
	R2-St	76.9±5.1	76.2±5.8	0.288**	79.5±6	79.8±5.9	0.432**	0.183†
	R2-Sn	83.4±4.1	83.6±4.5	0.757**	85.7±6	86.2±5.4	0.221**	0.54†
	R2-A'	81.7±4.6	80.7±5.3	0.233**	83±5.8	83.8±5.3	0.015**	0.05*
	R2-B'	71.5±6.7	70.7±8.2	0.584∞	72.3±8.1	73.3±7.8	0.09**	0.169*
	R2-Li	79.7±4.8	79.4±5.6	0.646**	81.8±7	82.5±6.6	0.326∞	0.278†
	R2-Pn	97.5±4.1	98.2±4.1	0.59**	99±7	99.9±6.5	0.018**	0.715†
	NLA	110.9±12.4	113.5±12.6	0.264**	113.2±9.5	112.6±9.3	0.594**	0.223†

*Mann-Whitney U-test; †Independent t-test; **Paired sample t-test; ∞Wilcoxon test; p≤0.05

S: sella; N: nasion; A: skeletal A point; B: skeletal B point; ANS: anterior nasal spine; PNS: posterior nasal spine; Ar: alveolar ridge; U1: the most occlusal tip of the upper incisor; L1: the most occlusal tip of the lower incisor; Ls: labiale superior; Li: labiale inferior; St: stomion; Sn: subnasale; A': soft tissue A point; B': soft tissue B point; Pn: pronasale; NLA: nasolabial angle

The application of an acrylic-bonded RME generates a force to the anchor teeth transmitted to the corresponding alveolar bone. This force is translated to the mid-palatal suture as the periodontal ligaments of the anchor teeth are compressed. The tipping of the teeth and bending of the alveolar process occur, and gradual separation is observed (19).

Skeletal Changes

Various movements of the skeletal point A were reported after the application of the RME device. The skeletal point A has been

shown to mostly move to the posterior in patients treated with bonded RME appliances at the end of the retention phase (3 months) (20). On the contrary, it has been declared that immediately after using the full- and posterior-bonded RME appliance, the skeletal point A showed a forward movement according to the SNA (21, 22). Furthermore, treatment with the conventional Haas-type RME appliance showed that the SNA angle increased during the active phase, whereas it decreased at the retention phase because of the sutural fusion between the maxilla and the craniofacial bones (5, 6).

The sagittal position of the skeletal point A (SNA, R2-A, and R2-ANS) did not show significant changes at the end of the retention phase, which was 6 months on average in Group1, whereas the skeletal point A (R2-A and R2-ANS) showed significant increases in Group2. The SNA angle did not show any changes, but the growth of nasion may have prevented the sagittal movement of the skeletal point A from being noticed.

Differences in the measurement methods, appliance design, retention time, sample's age, and gender can affect the results and be confusing. Varying results concerning the skeletal point A may be observed in the same study according to the different measurement methods used (21). This situation makes the evaluation of the effects of the used devices even more complicated.

Lateral cephalometric radiographs were taken at the end of the retention period, and not the treatment period, because of ethical reasons in the present study. There are some different results presented between immediately after the active expansion phase and retention phase outcomes in literature (5, 6, 20-22). The pure outcome following this treatment should be obtained before beginning the fixed appliance therapy to reduce the relapse.

Vertical changes of the point A were noted in line with previous studies (1, 5), and point A moved downward in both groups. However, a downward movement of the PNS was observed only in Group1. Vertical movement was only seen at point A and ANS, whereas it was not seen in Group2. Therefore, we interpreted this result as a maxillary posterior rotation of Group2. Despite the maxillary posterior rotation in Group2, the skeletal point A moved forward. This is very useful for specific treatments, especially maxillary deficiency.

Dental and Dentoalveolar Changes

The upper teeth showed a downward movement, and maxillary alveolar bones followed the upper incisors in both groups. Although the anterior teeth were not in contact with each other during the RME treatment in Group1, the extrusion of the anterior teeth including the upper anterior alveolar ridge was not significantly different between the groups. The extrusion of the upper incisors in Group2 may have been affected by the downward movement of the ANS point and, at the same time, the unchanging vertical position of the PNS point. Therefore, this can be interpreted as the posterior rotation of the maxilla. This residual effect was not differentiated in previous studies and should be considered with caution especially in the presence of "gummy smile," as emphasized in this study where specific details in the appliance design have been discussed.

Although there were no changes in the sagittal position of the upper teeth in our study, extrusions of the upper teeth were observed. No significant differences were found in previous studies regarding the vertical or sagittal position of the upper and lower incisors after treatment with an acrylic-bonded full tooth- and tissue-borne RME appliance (12, 23). Unlike the design of the appliance in the presented study, a tissue-borne portion of the RME appliance in the previous studies may have created an intrusion

effect via tongue; as a result, the vertical growth of the dentoalveolar region may have been inhibited even though the acrylic part thickness was within the freeway space (12, 23).

Protrusion of the lower teeth was seen in Group2, but it was not seen in Group1. This may have occurred because of the anterior acrylic part of the full acrylic-bonded RME appliance.

In line with the findings of our study, researchers (22, 24) showed that there was a retrusion of the upper incisors at the end of the retention phase in Group1.

Soft Tissue Changes

There is a complex relationship between the orthodontic treatment and soft tissue changes. Researchers especially evaluated the effects of the extraction orthodontic treatment on soft tissues (25-27). Soft tissue changes were neglected when the RME effects were assessed in the majority of the previous studies (10, 14, 24, 28). The various results declared in the studies are as follows. The upper lip did not move forward after the RME, although the maxilla showed an anterior movement (12). The H angle increased after the RME treatment. It is not clear whether this increase in the H angle was a result of the forward movement of the lips (7); in addition, there were no changes in the sagittal position of the skeletal point A and the upper lip, despite the protrusion of upper incisors (21). Conversely, the lips followed the maxilla and mandible, which moved posteriorly in hypothetical skeletal changes associated with the posterior-bonded RME appliance (20).

In the present study, the increase in the vertical growth of the upper lip and subnasale may be the result of sole vertical maxillary growth in the subjects from Group1 and the release of anterior teeth.

The soft tissue point A moved forward in Group2 compared with Group1. This result is an important finding, especially in the maxillary deficiency Class 3 patients. The posterior rotation of the maxilla and a forward movement of the soft tissue point A will be beneficial for maxillary protraction treatment.

Tooth-borne acrylic-bonded RME appliances are the most commonly used expansion devices in the orthodontics practice for narrow upper arch corrections owing to their easy and inexpensive laboratory steps, simple, and non-invasive bonding procedure, and successful patient compliance. For impressive smiles and appealing profiles, it is essential to start treatment at a suitable age while growth and development are continuing and to use the most beneficial appliance design for the patient. Treatment with the specific target related expansion device would help to decrease the complexity of the orthodontic problem and anxiety due to the unpleasant appearance, providing a better social orientation.

CONCLUSION

The differential results of the RME treatment reveal the complexity of the response of midfacial structures depending on the

stimulated areas; the soft tissue A point appears to be the most important matter between the two different RME appliances in this study. The vertical effects were apparent around the upper lip and subnasale in the posterior acrylic-bonded RME, whereas the sagittal changes in the soft tissue point A and pronasale and rotational maxillary movement were observed in the full acrylic-bonded RME.

As a recommendation, full acrylic-bonded RME appliance may be beneficial for subjects with maxillary retrognathic profile, whereas posterior acrylic-bonded RME appliance may be advantageous for subjects with a short upper lip.

Ethics Committee Approval: Ethics committee approval was received for this study from the Ethical Committee of Gazi University (10.09.2015/08).

Informed Consent: Written informed consent was obtained from the volunteers who participated in this study.

Peer-review: Externally peer-reviewed.

Author Contributions: Concept - L.T., G.M.G.; Design - L.T., G.M.G.; Supervision - L.T., G.M.G.; Data Collection and/or Processing - G.M.G., N.D.S.D.; Analysis and/or Interpretation - G.M.G., N.D.S.D.; Writing Manuscript - L.T., G.M.G.

Conflict of Interest: No conflict of interest was declared by the authors.

Financial Disclosure: The authors declared that this study has received no financial support.

REFERENCES

- da Silva Filho OG, Boas MC, Capelozza Filho L. Rapid maxillary expansion in the primary and mixed dentitions: a cephalometric evaluation. *Am J Orthod Dentofacial Orthop* 1991; 100: 171-9. [\[CrossRef\]](#)
- Thilander B, Wahlund S, Lennartsson B. The effect of early interceptive treatment in children with posterior cross-bite. *Eur J Orthod* 1984; 6: 25-34. [\[CrossRef\]](#)
- Lux CJ, Conradt C, Burden D, Komposch G. Dental arch widths and mandibular-maxillary base widths in Class II malocclusions between early mixed and permanent dentitions. *Angle Orthod* 2003; 73: 674-85.
- Angell EC. Irregularities of teeth and their treatment. San Francisco Medical Press 1860; 181-5.
- Haas AJ. Rapid Expansion of the Maxillary Dental Arch and Nasal Cavity by Opening the Midpalatal Suture. *Angle Orthod* 1961; 32: 73-89.
- Haas AJ. The Treatment of Maxillary Deficiency by Opening the Midpalatal Suture. *Angle Orthod* 1965; 35: 200-17.
- Kilic N, Kiki A, Oktay H, Erdem A. Effects of rapid maxillary expansion on Holdaway soft tissue measurements. *Eur J Orthod* 2008; 30: 239-43. [\[CrossRef\]](#)
- Langford SR, Sims MR. Root surface resorption, repair, and periodontal attachment following rapid maxillary expansion in man. *Am J Orthod* 1982; 81: 108-15. [\[CrossRef\]](#)
- Taner-Sarisoy L. Early treatment of a severe Class II Division 1 malocclusion. *J Clin Pediatr Dent* 1998; 23: 23-6.
- Lin L, Ahn HW, Kim SJ, Moon SC, Kim SH, Nelson G. Tooth-borne vs bone-borne rapid maxillary expanders in late adolescence. *Angle Orthod* 2015; 85: 253-62. [\[CrossRef\]](#)
- Akin M, Baka ZM, Ileri Z, Basciftci FA. Alveolar bone changes after asymmetric rapid maxillary expansion. *Angle Orthod* 2015; 85: 799-805. [\[CrossRef\]](#)
- Doruk C, Bicakci AA, Basciftci FA, Agar U, Babacan H. A comparison of the effects of rapid maxillary expansion and fan-type rapid maxillary expansion on dentofacial structures. *Angle Orthod* 2004; 74: 184-94.
- Canan S, Senisik NE. Comparison of the treatment effects of different rapid maxillary expansion devices on the maxilla and the mandible. Part 1: Evaluation of dentoalveolar changes. *Am J Orthod Dentofacial Orthop* 2017; 151: 1125-38. [\[CrossRef\]](#)
- Memikoglu TU, Ileri H. Effects of a bonded rapid maxillary expansion appliance during orthodontic treatment. *Angle Orthod* 1999; 69: 251-6.
- Melsen B. Palatal growth studied on human autopsy material. A histologic microradiographic study. *Am J Orthod* 1975; 68: 42-54. [\[CrossRef\]](#)
- Baccetti T, Franchi L, Cameron CG, McNamara JAJr. Treatment timing for rapid maxillary expansion. *Angle Orthod* 2001; 71: 343-50.
- Zimring JF, Isaacson RJ. Forces Produced by Rapid Maxillary Expansion. 3. Forces Present during Retention. *Angle Orthod* 1965; 35: 178-86.
- Angelieri F, Cevidanes LH, Franchi L, Goncalves JR, Benavides E, McNamara JAJr. Midpalatal suture maturation: classification method for individual assessment before rapid maxillary expansion. *Am J Orthod Dentofacial Orthop* 2013; 144: 759-69. [\[CrossRef\]](#)
- Bishara SE, Staley RN. Maxillary Expansion - Clinical Implications. *American Journal of Orthodontics and Dentofacial Orthopedics* 1987; 91: 3-14. [\[CrossRef\]](#)
- Sarver DM, Johnston MW. Skeletal changes in vertical and anterior displacement of the maxilla with bonded rapid palatal expansion appliances. *Am J Orthod Dentofacial Orthop* 1989; 95: 462-6. [\[CrossRef\]](#)
- Corekci B, Goyenc YB. Dentofacial changes from fan-type rapid maxillary expansion vs traditional rapid maxillary expansion in early mixed dentition. *Angle Orthod* 2013; 83: 842-50. [\[CrossRef\]](#)
- Akkaya S, Lorenzon S, Ucem TT. A comparison of sagittal and vertical effects between bonded rapid and slow maxillary expansion procedures. *Eur J Orthod* 1999; 21: 75-80. [\[CrossRef\]](#)
- Ramoglu SI, Sari Z. Maxillary expansion in the mixed dentition: rapid or semi-rapid? *Eur J Orthod* 2010; 32: 11-18. [\[CrossRef\]](#)
- Asanza S, Cisneros GJ, Nieberg LG. Comparison of Hyrax and bonded expansion appliances. *Angle Orthod* 1997; 67: 15-22.
- Darendeliler N, Taner L. Changes in the soft tissue profile after extraction orthodontic therapy. *J Dent Child (Chic)* 2006; 73: 164-9.
- Bravo LA. Soft tissue facial profile changes after orthodontic treatment with four premolars extracted. *Angle Orthod* 1994; 64: 31-42.
- Kocadereli I. Changes in soft tissue profile after orthodontic treatment with and without extractions. *Am J Orthod Dentofacial Orthop* 2002; 122: 67-72. [\[CrossRef\]](#)
- Wertz RA. Skeletal and dental changes accompanying rapid midpalatal suture opening. *Am J Orthod* 1970; 58: 41-66. [\[CrossRef\]](#)