CASE REPORT

Unusual presentation of silently growing abdominal aortic aneurysm causing biliary obstruction

Khalid Hamid Changal,[1] Francis Lim,[1] Tejasvi Sunkara,[1] Syed Uzair Hamdani[2]

[1]Department of Internal Medicine, Mercy St. Vincent's Medical Center, Toledo, Ohio, USA
[2]Department of Gastroenterology, Mercy St. Vincent's Medical Center, Toledo, Ohio, USA

Correspondence to
Dr Khalid Hamid Changal, khalidchangal@gmail.com

Accepted 15 September 2017

SUMMARY

Biliary obstruction is a rare presentation of abdominal aortic aneurysm (AAA). The most common symptoms of AAA are abdominal or back pain and limb ischaemia from thromboembolism. We report a case of a 67-year-old male who was diagnosed with obstructive jaundice secondary to an AAA. CT angiogram revealed compression of the common bile duct by the large AAA, causing diffuse intrahepatic and extrahepatic ductal dilatation. Surgical repair of the aortic aneurysm was successful, and patient's symptoms improved.

BACKGROUND

The correlation between abdominal aortic aneurysm (AAA) and biliary obstruction is uncommon. We reviewed the literature and share our experience to show that, though uncommon, it is not impossible to have AAA causing obstructive biliary symptoms.

CASE PRESENTATION

A 67-year-old Caucasian male with poorly controlled essential hypertension was seen by his family physician for a chief complaint of dark urine and unintentional weight loss of 5 pounds over a 3-week period. There was no associated nausea, vomiting or abdominal pain. On physical examination, he was jaundiced but had no abdominal tenderness, hepatomegaly or clinical signs of cirrhosis. The remainder of his exam was unremarkable. His family history was notable for coronary artery disease, colon and lung cancers but no vascular aneurysms.

INVESTIGATIONS

Initial lab tests included complete blood count, complete metabolic panel, erythrocyte sedimentation rate, lipid panel and urinalysis. An elevated alkaline phosphatase at 482 U/L, AST of 62 U/L and ALT at 55 U/L with a total bilirubin of 10.5 mg/dL and a direct bilirubin of 7.2 mg/dL indicated a cholestatic pattern of jaundice. Urinalysis was remarkable for significant bilirubinuria. An abdominal ultrasonogram revealed an AAA with axial measurement of 5.7 cm that extended at least 12 cm in length around the head and uncinate process of the pancreas, compressing the distal common bile duct (CBD). Liver parenchyma was heterogeneous, CBD measured 8 mm and there was gallbladder sludge without inflammation. The patient was referred to vascular surgery and gastroenterology for further evaluation. Repeat liver function tests 3 weeks later showed total bilirubin of 8.3 mg/dL with a direct bilirubin of 4.5 mg/dL. Autoimmune markers (DsDNA, antinuclear antibody and antimitochondrial antibodies) sent to establish the cause of the cholestatic jaundice were negative, ruling out primary biliary cirrhosis. He was not taking any medications that would cause cholestatic jaundice. There was no pancreatic or biliary mass lesion evident on the ultrasonogram to suggest a malignant lesion. CT angiogram done at this time showed an infrarenal fusiform AAA 5.8×5.9 cm with no evidence of a rupture (figure 1 and figure 2). There was aneurysmal dilatation of the common as well as internal iliac arteries, and a focal dissection was seen involving the proximal aspect of the right common internal iliac artery. Diffuse intrahepatic and extrahepatic ductal dilatation and gallbladder dilatation was seen from compression by the AAA (figure 3). There was no evidence of a tumour or choledocholithiasis. An endoscopic ultrasound was performed to confirm the cause of cholestasis. The ultrasound findings were significant for CBD (common bile duct) dilatation of 11 mm and extensive sludge in gall bladder. AAA was again noted around the head and uncinate process of the pancreas compressing the distal CBD. No pancreatic tumour was seen.

DIFFERENTIAL DIAGNOSES

For the initial presentation of cholestasis, the differential diagnosis is broad, and AAA is typically not immediately considered. The differentials commonly reviewed includes hepatitis, primary biliary cirrhosis, drug-related cholestasis, gall stones related, biliary stricture, biliary carcinomas, pancreatic cancer or a mass from surrounding tissues compressing the biliary system.

TREATMENT

Endoscopic retrograde cholangiopancreatography (ERCP) was done to balloon-sweep the CBD of gallbladder sludge, and a stent was placed for relief of jaundice. He was admitted to the hospital about 2 months later for elective AAA repair. His preoperative liver enzymes showed improvement after ERCP. He underwent open repair of the AAA, bilateral common iliac artery aneurysms and left internal iliac artery aneurysm with resection of the aneurysms and placement of 16 mm × 8 mm bifurcated aorto-bi-iliac graft. He recovered from surgery without any complication, and the plastic stent was removed from the CBD.

To cite: Changal KH, Lim F, Sunkara T, *et al*. *BMJ Case Rep* Published Online First: [*please include* Day Month Year]. doi:10.1136/bcr-2017-220539

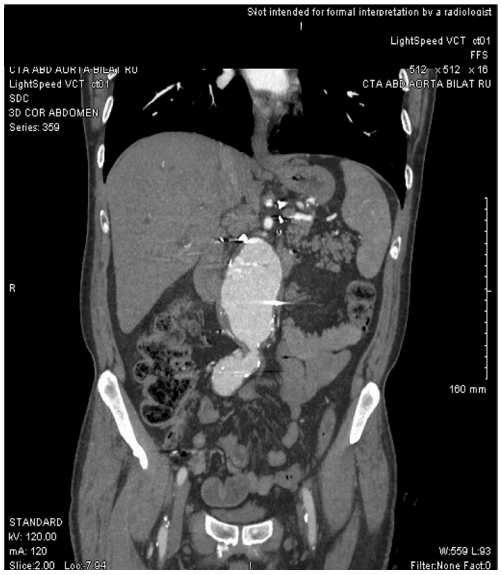

Figure 1 CT angiogram of the abdomen demonstrating the close relation of the abdominal aortic aneurysm with the biliary system.

OUTCOME AND FOLLOW-UP

At his 3-month post-operative visit, he was doing well with normalisation of his liver enzymes and bilirubin. A repeat CT angiogram showed resolution of the AAA and no biliary ductal dilatation.

DISCUSSION

The prevalence of AAA is reported to be 4%–8% in men aged 65–80 years per the ultrasound screening studies.[1–4] In women of the same age group, AAA prevalence is 4–6 times lower at 1.3%.[5]

Small aneurysms (<4.0 cm) are at a lower risk of rupture compared with larger ones (>6 cm). The risk of rupture also depends on the rate of expansion of the aneurysm. On average, aneurysms may expand at a rate of 0.3–0.4 cm per year.[6]

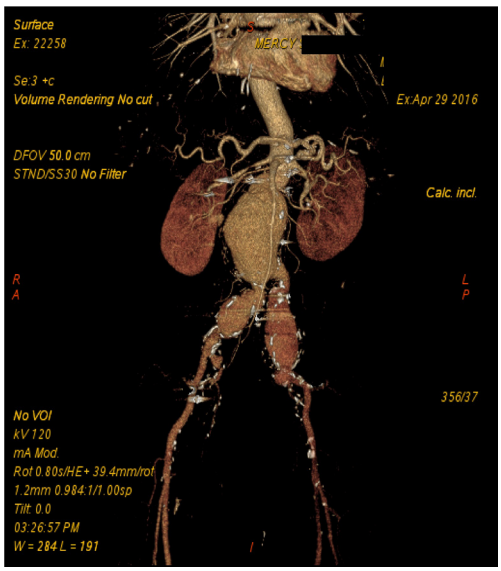

Figure 2 Showing the CT angiogram of the abdominal vessels demonstrating the abdominal aortic aneurysm and its close relation to the biliary system. The aneurysmal dilation of iliac arteries can be seen too.

Biliary obstruction can be classified as either intrahepatic, extrahepatic or both. Intrahepatic causes of biliary obstruction include hepatitis, cirrhosis and drugs. Extrahepatic causes are further subclassified as intraductal or extraductal. Common intraductal causes include neoplasms, gallstones, strictures, parasitic causes, primary sclerosing cholangitis, AIDS-related cholangiopathy and biliary tuberculosis. Extraductal obstruction caused by external compression of the biliary ducts may be caused by tumours, pancreatitis or other compressive pathologies. Compression of the biliary system by a large AAA is classified as an extrahepatic cause. It is extremely uncommon. We did an extensive search of the literature and found eight substantial case reports on this rare presentation.

In the majority of the reported cases, patients were noted to be jaundiced.[7–14] Other prominent clinical findings include abdominal pain, fever, loss of appetite and weight loss. In one case there was disseminated intravascular coagulation.[6] Other pathologies associated with the aorta causing biliary obstruction reported in the literature include chronic periaortitis with AAA[15] and traumatic pseudoaneurysm of the aorta.[16] A recent extensive review of literature was published to find out cases of acquired abdominal arterial abnormalities resulting in biliary obstruction. Tin *et al* identified 39 cases of biliary obstruction secondary to acquired aortic or splanchnic vessel abnormalities: 16 were caused by AAAs and 23 by splanchnic vessels.[17]In this review, both genders were equally affected, and mean age of presentation was in seventh and eighth decade. Most common presentations were abdominal pain and jaundice. Seven patients were treated with surgery with one having preprocedure ERCP and stent placement. One underwent ERCP and stent placement without further intervention, and one had an endovascular aortic aneurysm repair. Seven patients were either too unstable for intervention or opted for conservative management. It is important to recognise that biliary compression from AAA may present as only abnormal liver function tests also. In our case, the patient had interestingly presented with painless jaundice.

Other compressive symptoms associated with AAA are lumbar pain due to compression of nerve roots, lower extremity oedema due to compression of iliac veins, hydronephrosis due to compression of ureters, varicocele, hydrocele and nausea or vomiting due to compression on the duodenum. These presentations are rare.

Management of AAAs should be per the latest guidelines. Ultrasound should be used to screen for the presence of AAA in men 65–75 years of age who have ever smoked and should be considered for patients with a strong family history of AAA.[18] Beta blockade, with a goal resting heart rate of 60 beats per minute, should be instituted before AAA repair in all patients unless contraindicated.[19] Surgical repair of an AAA should be considered when the aneurysm reaches 5.5 cm in maximal diameter in men.[20] Repair of an AAA also should be considered when the aneurysm expands by more than 0.6–0.8 cm per year.[21]

Our case describes a rare presentation of AAA presenting as a painless jaundice. Uncommon presentations of common diseases can baffle a clinician, and thus an open mind is always needed to consider less common causes when the clinical picture is not a classic presentation. AAA is a fatal disease, and smokers are more prone to get it. AAAs can cause circulatory complications and compressive complications that can make presentation, diagnosis and treatment difficult and challenging. This case demonstrated the importance of team work, beginning with the primary care physician who did an effective diagnostic work-up, promptly referred the patient to the appropriate specialty groups, and looped follow-up back to the primary care physician.

Figure 3 CT abdomen showing the dilated gall bladder (left side) and biliary ducts (right side).

Learning points

- Abdominal aortic aneurysm can cause compressive symptoms, and these symptoms can sometimes be the presenting features.
- Obstructive jaundice is an unusual but possible presentation of AAA secondary to biliary compression.
- Communication between physicians from different specialties is important when dealing with complex pathologies.

Contributors KHC: writing the case, corresponding author, editing the case and gathering and editing the radiological pictures. FL: writing the case, editing the case and gathering and editing the radiological pictures. TS: editing the case. SUH: gastroenterologist taking care of the patient and critical review of the manuscript.

Competing interests None declared.

Patient consent Obtained.

Provenance and peer review Not commissioned; externally peer reviewed.

© BMJ Publishing Group Ltd (unless otherwise stated in the text of the article) 2017. All rights reserved. No commercial use is permitted unless otherwise expressly granted.

REFERENCES

1 Ashton HA, Buxton MJ, Day NE, *et al*. The Multicentre Aneurysm Screening Study (MASS) into the effect of abdominal aortic aneurysm screening on mortality in men: a randomised controlled trial. *Lancet* 2002;360:1531.
2 Norman PE, Jamrozik K, Lawrence-Brown MM, *et al*. Population based randomised controlled trial on impact of screening on mortality from abdominal aortic aneurysm. *BMJ* 2004;329:1259.
3 Lindholt JS, Juul S, Fasting H, *et al*. Screening for abdominal aortic aneurysms: single centre randomised controlled trial. *BMJ* 2005;330:750.
4 Ashton HA, Gao L, Kim LG, *et al*. Fifteen-year follow-up of a randomized clinical trial of ultrasonographic screening for abdominal aortic aneurysms. *Br J Surg* 2007;94:696–701.
5 Scott RA, Bridgewater SG, Ashton HA. Randomized clinical trial of screening for abdominal aortic aneurysm in women. *Br J Surg* 2002;89:283–5.
6 Brewster DC, Cronenwett JL, Hallett JW, *et al*. . Guidelines for the treatment of abdominal aortic aneurysms. report of a subcommittee of the Joint council of the American association for vascular surgery and society for vascular surgery. *J Vasc Surg* 2003;37:1106–17.
7 Dickinson WL. Aneurysm of abdominal aorta compressing the common bile-duct and rupturing into duodenum. *Trans Pathol Soc London* 1891;42:77–8.
8 Sondheimer FK, Steinberg I. Gastrointestinal manifestations of abdominal aortic aneurysms . *Am J Roentgenol Radium Ther Nucl Med* 1964;92:1110–22.
9 Spinelli GD, Kleinclaus DH, Wenger JJ, *et al*. Obstructive jaundice and abdominal aortic aneurysm: an ultrasonographic study. *Radiology* 1982;144:872.
10 Lieberman DA, Keeffe EB, Rahatzad M, *et al*. Ruptured abdominal aortic aneurysm causing obstructive jaundice. *Dig Dis Sci* 1983;28:88–93.
11 Dohi K, Fukuda Y, Nakagawa K, *et al*. A case of obstructive jaundice due to abdominal aneurysm compression. *Hiroshima J Med Sci* 1984;33:819–23.
12 van Gossum A, Rubinstein M, Engelholm L, *et al*. Common bile duct compression by an abdominal aortic aneurysm. *Endoscopy* 1986;18:69–70.
13 van Someren N, Benson M, Jacomb-Hood J, *et al*. Aneurysmal dilation of the abdominal aorta: a rare cause of obstructive jaundice. *Gastrointest Endosc* 1993;39:85–7.
14 Remedios D, Coppen M, Bradbeer J, *et al*. Chronic periaortitis presenting as common bile duct obstruction. *Gut* 1991;32:713–4.
15 Chase CW, Layman TS, Barker DE, *et al*. Traumatic abdominal aortic pseudoaneurysm causing biliary obstruction: a case report and review of the literature. *J Vasc Surg* 1997;25:936–40.
16 Smith AD, Mohammed F, Watson GM, *et al*. Common bile duct compression by an abdominal aortic aneurysm: an unusual cause of biliary tract dilatation. *Eur J Gastroenterol Hepatol* 2002;14:767–9.
17 Tin K, Sobani ZA, Horovitz J, *et al*. Aortic and splanchnic artery aneurysms: unusual causes of biliary obstruction - A retrospective cohort from literature. *Int J Surg* 2017;39:163–8.
18 Kent KC, Zwolak RM, Jaff MR, *et al*. Screening for abdominal aortic aneurysm. *J Vasc Surg* 2004;39:267–9.
19 Lindenauer PK, Pekow P, Wang K, *et al*. Perioperative beta-blocker therapy and mortality after major noncardiac surgery. *N Engl J Med* 2005;353:349–61.
20 Lederle FA, Wilson SE, Johnson GR, *et al*. Immediate repair compared with surveillance of small abdominal aortic aneurysms. *N Engl J Med* 2002;346:1437–44.
21 Brewster DC, Cronenwett JL, Hallett JW, *et al*. Guidelines for the treatment of abdominal aortic aneurysms. *J Vasc Surg* 2003;37:1106–17.

Copyright 2017 BMJ Publishing Group. All rights reserved. For permission to reuse any of this content visit http://group.bmj.com/group/rights-licensing/permissions.
BMJ Case Report Fellows may re-use this article for personal use and teaching without any further permission.

Become a Fellow of BMJ Case Reports today and you can:
- Submit as many cases as you like
- Enjoy fast sympathetic peer review and rapid publication of accepted articles
- Access all the published articles
- Re-use any of the published material for personal use and teaching without further permission

For information on Institutional Fellowships contact consortiasales@bmjgroup.com

Visit casereports.bmj.com for more articles like this and to become a Fellow