Author Manuscript

Author Manuscript

Author Manuscript

Author Manuscript

HHS Public Access

Author manuscript

Stroke. Author manuscript; available in PMC 2018 August 01.

Published in final edited form as:

Stroke. 2017 August ; 48(8): 2129–2135. doi:10.1161/STROKEAHA.117.017877.

Age-Specific Sex Differences in MRI Depicted Carotid Intraplaque Hemorrhage

Navneet Singh, MD, MPH[1], **Alan R. Moody, MBBS, MA, FRCP, FRCR**[1], **Bowen Zhang, BSc**[1], **Isabella Kaminski, BSc**[1], **Kush Kapur, PhD**[2], **Stephanie Chiu, PhD**[1], and **Pascal N. Tyrrell, PhD**[1,3]

[1]Department of Medical Imaging, Faculty of Medicine, University of Toronto

[2]Department of Neurology, Boston Children's Hospital, Harvard Medical School

[3]Department of Statistical Sciences, University of Toronto

Abstract

Background and Purpose—Stroke rates are higher in males compared to females in the fourth through seventh decades of life, and higher rates may result from differences in carotid intraplaque hemorrhage (IPH), an unstable atherosclerotic plaque component. We report age-specific sex differences in the presence of MRI depicted carotid IPH.

Methods—Patients (n=1115) underwent MRI for carotid IPH between 2005 and 2014. Low-grade carotid stenosis patients (n=906) without prior endarterectomy were eligible for this cross-sectional study.

Results—Of the 906 patients included (mean age ± SD in years, 66.98 +/− 15.15), 63 (6.95%) had carotid IPH. In males and females, carotid IPH was present in 11.43% (48/420) and 3.09% (15/486), respectively ($p<0.0001$). Multivariable logistic regression analysis confirmed greater odds of carotid IPH in males for all ages: 45 to 54 (OR=45.45, 95% CI 3.43 to 500), 55 to 64 years (OR=21.74, 95% CI 3.21 to 142.86), 65 to 74 years (OR=10.42, 95% CI 2.91 to 37.04), and ≥75 years (OR=5.00, 95% CI 2.31 to 10.75). Male sex modified the effect of age on the presence of carotid IPH (β= 0.074, SE=0.036, p=0.0411).

Conclusions—Males have greater age-specific odds of MRI depicted carotid IPH compared to females. With increasing age post-menopause, the odds of carotid IPH in females becomes closer to that of males. Delayed onset of carotid IPH in females, an unstable plaque component, may partly explain differential stroke rates between sexes and further studies are warranted.

MeSH Keywords

carotid atherosclerosis; magnetic resonance imaging; carotid stenosis; carotid plaque; stroke

Address for Correspondence: Prof. Alan R. Moody, MBBS, MA, FRCP, FRCR, Department of Medical Imaging, University of Toronto, 2075 Bayview Avenue, Toronto, Ontario M4N 3M5, tel: 416-480-6100, ext. 4341, fax: 416-480-5855 alan.moody@sunnybrook.ca.

Conflicts-of-Interest/Disclosures

None.

Author Manuscript Author Manuscript Author Manuscript Author Manuscript

Introduction

Stroke incidence is lower in females compared to males between the ages of 45 to 74 years.[1, 2] The difference in stroke incidence, however, is eliminated after 75 years of age.[1, 2] The protection from stroke conferred upon females between the ages of 45 to 74 years may be related to the protective effects of pre-menopausal sex hormones that delay the onset of atherosclerosis.[3, 4] Women have been reported to have less plaque burden and more stenosis compared to men,[5] suggesting that sex hormones play a role in arterial remodeling. Data on the age-specific sex differences in carotid plaque components and their natural course is sparse.

Pathology and imaging studies have reported carotid atherosclerosis composition differences between the sexes.[6, 7] One specific plaque component, intraplaque hemorrhage (IPH), is a biomarker of plaque instabilty associated with the progression of atherosclerosis,[8] a high-risk cardiovascular phenotype,[9, 10] and future cerebrovascular outcomes including stroke.[11–14] Several recent studies point to IPH as a potential source of thromboembolism among patients with embolic stroke of undetermined source, which by definition have non-stenotic carotid artery disease (<50%).[15, 16] Studies are needed understand the determinants of IPH in low-grade (<50%) carotid stenosis and data on the age-specific sex differences in carotid plaque components and their natural course is sparse in these patients. Further, prior studies have demonstrated that male sex and age are associated with the presence of IPH[6, 7, 17], however, whether sex modifies the effect of age remains to be investigated.

MRI can identify carotid IPH.[18–21] Validated carotid IPH pulse sequences such as 3D T1-weighted gradient echo (GRE)[18, 22, 23] may be implemented into routine clinical protocols.[22] 3D T1-weighted GRE is routinely combined with magnetic resonance angiography (MRA) at our institution providing an opportunity to study the IPH biomarker in a large clinical population.

The objective of this study was to report age-specific sex differences in MRI depicted carotid IPH in an institutional sample comprising ten years of data. Given that age-specific stroke rates are lower in females between age 45 to 74 compared to males, carotid artery disease is a major cause of stroke, and females may have greater proportions of stable plaque components, we hypothesized that age-specific sex differences in carotid IPH exist to help explain previously reported differences in stroke rates. Specifically, we hypothesized that males have greater age-specific odds of MRI depicted carotid IPH compared to females and that with increasing age, the odds of carotid IPH in females becomes closer to that of males. We report age-specific sex differences in the presence of MRI depicted carotid IPH in patients with less than 50% stenosis.

Methods

Institutional ethics board approval was received for this study and the requirement for informed consent was waived.

Author Manuscript Author Manuscript Author Manuscript Author Manuscript

Participants and Study Groups

Patients (n=1115) referred for neurovascular MRI undergoing 3D T1-weighted GRE black-blood imaging for the presence of carotid IPH between 2005 and 2014 were considered for study inclusion. Study exclusion criteria included i) carotid artery disease ≥50% stenosis to exclude patients with higher plaque volumes given that plaque volume and stenosis are positively correlated[24], and ii) patients with prior carotid endarterectomy since plaque components may have been altered as a result of iatrogenic causes.

Age groups were defined *a priori* as < 45 years, 45 to 54 years, 55 to 64 years, 65 to 74 years, and ≥75 years paralleling studies of age-specific sex differences in stroke such as The Greater Cincinnati/Northern Kentucky Stroke Study.[2, 25] Patients undergoing neurovascular MRI including 3D T1 weighted GRE imaging at our institution in this study included suspected neurovascular disease patients (usually symptomatic) referred by physicians, including stroke neurologists for neurovascular evaluation.

Carotid MRI Protocols

3D T1-weighted GRE imaging allows for the identification of carotid IPH.[18, 19] This acquisition exploits the T1-shortening effects of methemoglobin resulting in high signal intensity that indicates the presence of carotid IPH (See Figure 1 and 2).[26]

3D T1-weighted GRE imaging was performed on a Philips Medical System Scanner with a 16 channel neurovascular coil employing a T1-weighted fat-saturated (using a selected water excitation RF pulse) fast field echo sequence, with imaging acquired in the coronal plane (repetition time (TR), 11 msec; echo time (TE), 4 msec; field of view (FOV), 270x190 mm^2; matrix, 512x256 mm^2; slices, 100; through-plane thickness, 0.5mm; voxel size 0.5 mm x 0.7 mm x 0.5 mm interpolated. Imaging was also performed on a GE 1.5 Tesla MR (Twinspeed) with an eight-channel neurovascular phased-array coil (USA Instruments, Aurora, Ohio) using a T1-weighted fat saturated (Special [spectral inversion at lipids]; GE Healthcare) GRE sequence (TR, 6.7 msec; TE, 1.7 msec; flip angle, 15°; field of view, 300 mm^2; matrix size, 320 × 320; through-plane thickness, 2 mm; pixel size, 0.94mm × 0.94mm × 1 mm). 3D T1-weighted GRE imaging is robust, vendor agnostic, and similar IPH characteristics have been demonstrated at both 3T and 1.5T field strengths.[27]

Carotid IPH Imaging Analysis and Reliability

Carotid IPH is defined as plaque signal intensity that exceeds the intensity of the adjacent sternocleidomastoid by 50%.[9, 28–31] Since patients at our institution underwent imaging with neurovascular rather than surface coils, issues of coil sensitivity related to magnetic field inhomogeneity were not an issue. Experienced neuroradiologists (range of experience, 15 to 40 years) and a cardiothoracic radiologist with subspecialty and academic expertise in vascular biology imaging (A.R.M., experience, 27 years), routinely report the presence of IPH on the clinically acquired 3D T1-weighted GRE imaging acquisition. Increased signal intensity was considered to be carotid IPH if it was in the carotid artery wall. The dichotomous interpretation of carotid IPH has well established reliability[27, 32] and kappa coefficients are 0.75 and 0.9 for inter- and intra-observer reliability.[18] Concordance of

Author Manuscript Author Manuscript Author Manuscript Author Manuscript

clinical reports and an independent rater (N.S.) (n=50) for carotid IPH was found to have a kappa of 0.902 (95% CI, 0.769 to 1.000, SE 0.068).

Clinical Records Review

Data collection included abstraction of data from neurovascular MRI reports and patients' charts using available physician consultation letters. Patients' electronic and paper charts were reviewed for cardiovascular risk factors, medication history, and atherosclerotic end-organ events including history of transient ischemic stroke, stroke, and myocardial infarction. Traditional cardiovascular risk factors were included since they are independently associated with cardiovascular outcomes and therefore confound the evaluation of the effect of age and sex on the presence of carotid IPH.

Statistical Analysis

Continuous variables with a normal distribution were expressed as a mean and accompanied by a standard deviation. Comparisons of age between males and females were made using an unpaired two-sided *t*-test. Pooled rather than Satterthwaite *p*-values were reported since equal variances could be assumed. Categorical variables were reported as counts and percentages, and were compared between the sexes using a two-sided Chi-squared test. Comparisons of binary matched data for differences in carotid IPH in the right versus left carotid arteries were made using a two-sided McNemar's test.

Logistic regression was used to evaluate the relationship of sex and carotid IPH. Multivariable logistic regression covariates included hypertension, dyslipidemia, diabetes mellitus type two, and smoking history. To evaluate age-specific sex differences in carotid IPH, we included an age-by-sex covariate interaction term in reference and adjusted models. Statistical analysis was performed using SAS Version 9.4 (SAS Institute, Cary, NC, USA). A *p*-value of less than 0.05 indicated a statistically significant difference.

Results

Nine hundred and six patients (mean age ± SD in years, 66.98 +/− 15.15) were eligible for study (See Figure 3). Carotid IPH was found in 63 (6.95%) of included patients. Demographic, clinical characteristics and carotid IPH presence are summarized in Table 1. Males had greater proportions of hypertension, dyslipidemia, type 2 diabetes, and smoking history.

In males and females, carotid IPH was present in 11.43% (48/420) and 3.09% (15/486), respectively (p<0.0001). Figure 4 depicts the proportion of patients with carotid IPH stratified by sex and age. No patients had carotid IPH under the age of 45. Between ages 45 to 54 years, only two males had carotid IPH. Females less than the age of 65 were not found to have carotid IPH. Table 2 includes the proportions of males and females with carotid IPH by age group.

Based on logistic regression, compared to women, men were found to have greater odds of carotid IPH at ages 45 to 54 (OR=52.63, 95% CI 4.27 to 1000), 55 to 64 (OR=25.00, 95%

Author Manuscript Author Manuscript Author Manuscript Author Manuscript

CI 3.88 to 166.67), 65 to 74 (OR=11.90, 95% CI 3.39 to 41.67) and ≥ 75 years (OR=5.56, 95% CI 2.61 to 11.76).

Multivariable logistic regression confirmed that males have greater odds of carotid IPH than females at ages 45 to 54 (OR=45.45, 95% CI 3.43 to 500), 55 to 64 (OR=21.74, 95% CI 3.21 to 142.86), 65 to 74 (OR=10.42, 95% CI 2.91 to 37.04) and ≥ 75 years (OR=5.00, 95% CI 2.31 to 10.75).

The odds of carotid IPH was greater with age in both males and females, and the effect of carotid IPH on age was modified by sex in both univariable (β=0.075, SE=0.0352, p=0.0312) and multivariable (β= 0.0737, SE=0.0361, p=0.0411) logistic regression. The odds of IPH among females converged with that of males with age as shown in the unadjusted and adjusted odds of age-specific sex differences in carotid IPH reported in Table 2.

Bilateral carotid IPH was found in nine of 420 (2.14%) males, and two of 486 (0.41%) females and significantly differed between the sexes (p=0.0287). Males in the older age categories had higher proportions of bilateral IPH (see Table 2).

Of the 52 patients with only unilateral carotid IPH, 32 (61.54%) and 20 (38.46%) patients had an affected left and right side, respectively (p<0.0001). In these patients with unilateral disease, the left side was affected in 53.85% (7/13) of females (p=0.0006) and 64.10% (25/39) males (p<0.0001).

Discussion

Findings

The data in this single institution study revealed that in patients with low-grade carotid artery stenosis, carotid IPH occurs after the age of 45 years, is present in less than 1% of patients before the age of 55 years, and by the age of 75 years, affects as many as 12% of all patients. Females were not affected by carotid IPH before the age of 65 years. Moreover, males have greater odds of carotid IPH compared to females, and with increasing age post-menopause, the odds of carotid IPH in females also increases and becomes closer to that of males. In other words, sex modifies the effect of age on carotid IPH. To our knowledge, no other studies have investigated or demonstrated the convergence of risk of carotid IPH between the sexes with increasing age. The infrequency of carotid IPH, an unstable plaque component associated with future stroke, in women before the age of 75 may *in part* explain the reason that women are relatively protected from stroke compared to men before the seventh decade of life. Our findings additionally suggest a delayed onset of carotid IPH in females.

Novelty

This study comprising nearly ten years of data, as a result of institutional incorporation of 3D T1-weighted carotid MRI into routine neurovascular imaging, provided an opportunity to test our hypothesis that, carotid IPH exhibits age-specific sex differences. Thus, an opportunity was afforded to evaluate the age-specific sex differences in a large group of

Author Manuscript Author Manuscript Author Manuscript Author Manuscript

patients without significant carotid artery stenosis or higher pre-test probabilities of vessel wall disease. The use of a large homogenous group of low vessel wall volume disease patients reduces confounding factors in evaluating the relationship of age and sex that might be associated with higher-grade disease such as lifestyle differences. Since only a few minutes additional scan time is necessary to evaluate for IPH within existing neurovascular MRI protocols, it was possible to capture a relatively large dataset of patients with low-grade carotid stenosis with information on their IPH status.

Other Studies

Observational and population studies including MRI of plaque components have found that age and sex are determinants of carotid IPH.[7,33] Overall, our data found carotid IPH in 11% and 3% of males and females, respectively. Ota and colleagues found a prevalence of 24% and 6%.[7] The higher prevalence of carotid IPH in the latter study may be attributed to Ota using an overall higher-risk group, low-grade carotid stenosis arteries of patients with contralateral moderate-to-high grade carotid stenosis. In our study, the carotid IPH status in patients with bilateral low-grade stenosis was captured by incorporating carotid IPH imaging into routine clinical neurovascular MRI. This is in contrast to other studies and trials that select patients for vessel wall imaging as a result of their carotid stenosis[7] or intima-media thickness.

In our study, men had 4.1 (95% CI, 2.2 to 7.4) greater odds of carotid IPH compared to women, which is similar to some reports.[7] While our confidence intervals overlap, our point estimate is higher compared to a population-based study reporting that plaques from males had a 2.2 (95% CI, 1.7 to 2.9) greater odds of IPH compared to females.[17] One reason for the difference in our study may be that, among the patients referred for neurovascular MRI and selected for <50% stenosis, rather than known carotid artery disease, a greater proportion of females may have been referred for MRI for neurovascular symptoms ultimately unrelated to carotid artery disease.

Men and women also had a slightly greater and statistically significant prevalence of carotid IPH within the left carotid artery. Ischemic stroke is more often diagnosed in the left hemisphere,[34] and the underlying etiology of this discrepancy is unclear. This predilection may in theory be due to differences in shear stress resulting from anatomical differences between the left and right carotid arteries and plaque components. While the increased diagnosis of stroke in the left hemisphere may be related to the underdiagnoses of right hemisphere stroke in clinical practice,[35, 36] the possibility of differences in plaque components and hemodynamic differences remains to be rigorously studied. Recently, differences in plaque components have been described and our findings of sidedness are in line with these.[37] Together the findings of sidedness and lack of symmetry in carotid IPH between the carotid arteries, suggest that both local and systemic factors play a role in the development of carotid IPH.

Strengths

The strengths of the present study included the power to ascertain age-specific differences in carotid IPH with MRI using data acquired in the routine clinical setting that allowed us to

Author Manuscript Author Manuscript Author Manuscript Author Manuscript

capture a large dataset of patients with bilateral low-grade carotid stenosis. The benefit of extracting our study sample from a clinical setting allows both potential application of any results to the clinical population of the sample studied (i.e., external validity), as well as the ability to apply strict inclusion and exclusion criteria to ensure sufficient homogeneity allowing for greater internal validity. In addition to being rapid, the 3D T1-weighted GRE acquisition used is scanner agnostic and multi-vendor for the diagnosis of carotid IPH. The acquisition can also be incorporated into routine clinical protocols[22] as demonstrated in the group within this study. We chose to use this particular pulse sequence since it does not require surface coils and has been validated using neurovascular coils that are routinely available in the clinical setting.[18] The IPH biomarker is also detectable with other validated MRI acquisitions.

Limitations

This study had several limitations. *First,* the study was cross-sectional and retrospective rather than longitudinal and prospective. Serial imaging studies are required to further understand the natural history of carotid atherosclerosis, and provide deeper insights into the natural course of IPH. Such trials are underway, and their results are anticipated.[38] Serial imaging studies involving advanced imaging are costly, and this study exploited an opportunity to collect a large set of data in the course of routine clinical practice. While understanding the incidence of disease would require cohort studies, cross-sectional studies cost-effectively provide information on prevalence of disease. *Second,* information on age at menopause and menarche, parity, and use of hormone replacement therapy, were not consistently available from charts. In developed countries, the average age of natural menopause of 51 years is used as a reference in cardiovascular studies,[39] and we interpreted our data with this knowledge. *Third,* while we were able to restrict our analysis to patients with less than 50% stenosis to exclude patients with higher plaque volumes given the correlation of stenosis with plaque volume,[24] our analyses were not adjusted for degree of stenosis. *Finally,* we did not evaluate plaque components such as lipid core, fibrous cap or calcium, and any age-specific sex differences they may exhibit. Carotid IPH is emerging as a critically important plaque component in prediction of end-organ events. Time constraints limit routine inclusion of multi-contrast acquisitions necessary to identify other plaque components in routine clinical practice, though more recent technological advancements in pulse sequence design may address this issue in the future.

Future Studies

Differences in sex-steroids may explain the observations in this study including the lower odds of carotid IPH in women per decade of life, the delayed onset of IPH in women, and convergent risk between men and women with increasing age. Estrogen is known to play a role in the age-specific sex differences in cardiovascular disease and the 10 to 15 year delayed onset of coronary disease in women.[3, 4] Histopathology studies of the coronaries have demonstrated that post-menopausal women are at an increased risk of plaque rupture.[40] Carotid endarterectomy specimen studies have shown that plaques obtained from women are less inflammatory with lower macrophage and interleukin-8 content, and with greater smooth muscle and collagen.[41] Plaque stabilization may be achieved via anti-inflammatory effects of estrogen modulated by its antioxidant and anti-apoptosis effects.[42] Furthermore,

Author Manuscript Author Manuscript Author Manuscript Author Manuscript

estrogen may confer protection against atherosclerosis via several mechanisms including the promotion of endothelial mediated dilation and blood flow, and cerebrovascular reactivity. Nitric oxide synthase and nitric oxide generation are increased by estrogen and may explain in part the protective role of estrogen in atherosclerosis.[42] While the effects of estrogen on IPH require further investigation, estrogen's ability to attenuate the inflammatory processes that have been implicated in IPH suggest that sex-steroid differences may account for some differences in carotid IPH presence.

The potential of menopause hormone therapy providing cardiovascular benefits remains unproven[43] although recent investigations demonstrate that timing of hormone therapy administration is critical to appreciate cardiovascular protection benefits. Post-menopausal administration of estradiol within six years of menopause onset may reduce progression of carotid intima-media thickness,[44] a marker of atherosclerosis that is strongly associated with cardiovascular outcomes. The relationship of post-menopause hormone therapy with plaque components using well-designed trials appears to be an avenue for future investigation.

Our results suggest that future cohort studies may be warranted to understand the role of carotid IPH and age-specific stroke rates, as well as further investigate the possibility of delayed incidence of carotid IPH in women. Prospective longitudinal studies to evaluate carotid IPH incidence rates in men and women would also clarify the natural history of carotid IPH, and affirm the role of estrogen in sex differences.

Conclusions

Males have greater age-specific odds of MRI depicted carotid IPH compared to females, and with increasing age, the odds of carotid IPH in females becomes closer to that of males. Differences in the presence of carotid IPH, an unstable plaque component, may partly explain differential stroke rates between the sexes, and further studies are warranted.

Acknowledgments

Sources of Funding

NS was supported by a Canadian Institute of Health Research (CIHR) Fellowship (FRN 120988) and RSNA R&E Research Resident Grants (# RR1561 and # RR1237). KK was supported by the Harvard Catalyst and The Harvard Clinical and Translational Science Center (NCRR, NCATS, NIH UL1 TR001102).

References

1. Reeves MJ, Bushnell CD, Howard G, Gargano JW, Duncan PW, Lynch G, et al. Sex differences in stroke: Epidemiology, clinical presentation, medical care, and outcomes. Lancet Neurol. 2008; 7:915–926. [PubMed: 18722812]
2. Kissela B, Schneider A, Kleindorfer D, Khoury J, Miller R, Alwell K, et al. Stroke in a biracial population: The excess burden of stroke among blacks. Stroke. 2004; 35:426–431. [PubMed: 14757893]
3. Jousilahti P, Vartiainen E, Tuomilehto J, Puska P. Sex, age, cardiovascular risk factors, and coronary heart disease: A prospective follow-up study of 14 786 middle-aged men and women in Finland. Circulation. 1999; 99:1165–1172. [PubMed: 10069784]
4. Yahagi K, Davis HR, Arbustini E, Virmani R. Sex differences in coronary artery disease: Pathological observations. Atherosclerosis. 2015; 239:260–267. [PubMed: 25634157]

Author Manuscript Author Manuscript Author Manuscript Author Manuscript

5. Iemolo F, Martiniuk A, Steinman DA, Spence JD. Sex differences in carotid plaque and stenosis. Stroke. 2004; 35:477–481. [PubMed: 14739419]
6. Ota H, Reeves MJ, Zhu DC, Majid A, Collar A, Yuan C, et al. Sex differences in patients with asymptomatic carotid atherosclerotic plaque: In vivo 3.0-t magnetic resonance study. Stroke. 2010; 41:1630–1635. [PubMed: 20616325]
7. Ota H, Reeves MJ, Zhu DC, Majid A, Collar A, Yuan C, et al. Sex differences of high-risk carotid atherosclerotic plaque with less than 50% stenosis in asymptomatic patients: An in vivo 3T MRI study. AJNR Am J Neuroradiol. 2013; 34:1049–1055. [PubMed: 23194832]
8. Takaya N, Yuan C, Chu B, Saam T, Polissar NL, Jarvik GP, et al. Presence of intraplaque hemorrhage stimulates progression of carotid atherosclerotic plaques: A high-resolution magnetic resonance imaging study. Circulation. 2005; 111:2768–2775. [PubMed: 15911695]
9. Singh N, Moody AR, Rochon-Terry G, Kiss A, Zavodni A. Identifying a high risk cardiovascular phenotype by carotid MRI-depicted intraplaque hemorrhage. Int J CV Imag. 2013; 29:1477–1483.
10. Noguchi T, Yamada N, Higashi M, Goto Y, Naito H. High-intensity signals in carotid plaques on t1-weighted magnetic resonance imaging predict coronary events in patients with coronary artery disease. J Am Coll Cardiol. 2011; 58:416–422. [PubMed: 21757120]
11. Singh N, Moody AR, Gladstone DJ, Leung G, Ravikumar R, Zhan J, et al. Moderate carotid artery stenosis: MR imaging-depicted intraplaque hemorrhage predicts risk of cerebrovascular ischemic events in asymptomatic men. Radiology. 2009; 252:502–508. [PubMed: 19508983]
12. Saam T, Hetterich H, Hoffmann V, Yuan C, Dichgans M, Poppert H, et al. Meta-analysis and systematic review of the predictive value of carotid plaque hemorrhage on cerebrovascular events by magnetic resonance imaging. J Am Coll Cardiol. 2013; 62:1081–1091. [PubMed: 23850912]
13. Gupta A, Baradaran H, Schweitzer AD, Kamel H, Pandya A, Delgado D, et al. Carotid plaque mri and stroke risk: A systematic review and meta-analysis. Stroke. 2013; 44:3071–3077. [PubMed: 23988640]
14. Singh N, Zavodni AE, Moody AR. Magnetic resonance imaging of carotid atherosclerosis and the risk of stroke. Curr Cardiovasc Imaging Rep. 2012; 6:25–33.
15. Freilinger TM, Schindler A, Schmidt C, Grimm J, Cyran C, Schwarz F, et al. Prevalence of nonstenosing, complicated atherosclerotic plaques in cryptogenic stroke. JACC Cardiovasc Imaging. 2012; 5:397–405. [PubMed: 22498329]
16. Gupta A, Gialdini G, Giambrone AE, Lerario MP, Baradaran H, Navi BB, et al. Association between nonstenosing carotid artery plaque on mr angiography and acute ischemic stroke. JACC Cardiovasc Imaging. 2016; 9:1228–1229. [PubMed: 26897689]
17. van den Bouwhuijsen QJ, Vernooij MW, Hofman A, Krestin GP, van der Lugt A, Witteman JC. Determinants of magnetic resonance imaging detected carotid plaque components: The Rotterdam Study. Eur Heart J. 2012; 33:221–229. [PubMed: 21821844]
18. Moody AR, Murphy RE, Morgan PS, Martel AL, Delay GS, Allder S, et al. Characterization of complicated carotid plaque with magnetic resonance direct thrombus imaging in patients with cerebral ischemia. Circulation. 2003; 107:3047–3052. [PubMed: 12796133]
19. Bitar R, Moody AR, Leung G, Symons S, Crisp S, Butany J, et al. In vivo 3D high-spatial-resolution MR imaging of intraplaque hemorrhage. Radiology. 2008; 249:259–267. [PubMed: 18796681]
20. Singh N, Moody AR, Roifman I, Bluemke DA, Zavodni AE. Advanced MRI for carotid plaque imaging. Int J Cardiovasc Imaging. 2016; 32:83–9.
21. Yuan C, Parker DL. Three-dimensional carotid plaque MR imaging. Neuroimaging Clin N Am. 2016; 26:1–12. [PubMed: 26610656]
22. Moody AR, Singh N. Incorporating carotid plaque imaging into routine clinical carotid magnetic resonance angiography. Neuroimaging Clin N Am. 2016; 26:29–44. [PubMed: 26610658]
23. Moody AR, Allder S, Lennox G, Gladman J, Fentem P. Direct magnetic resonance imaging of carotid artery thrombus in acute stroke. The Lancet. 1999; 353:122–123.
24. Rozie S, de Weert TT, de Monyé C, Homburg PJ, Tanghe HLJ, Dippel DWJ, et al. Atherosclerotic plaque volume and composition in symptomatic carotid arteries assessed with multidetector CT angiography; relationship with severity of stenosis and cardiovascular risk factors. Eur Radiol. 2009; 19:2294–2301. [PubMed: 19384548]

Author Manuscript Author Manuscript Author Manuscript Author Manuscript

25. Broderick J, Brott T, Kothari R, Miller R, Khoury J, Pancioli A, et al. The greater Cincinnati/Northern Kentucky stroke study: Preliminary first-ever and total incidence rates of stroke among blacks. Stroke. 1998; 29:415–421. [PubMed: 9472883]
26. Leung G, Moody AR. MR imaging depicts oxidative stress induced by methemoglobin. Radiology. 2010; 257:470–476. [PubMed: 20829533]
27. Scott McNally J, Yoon HC, Kim SE, Narra KK, McLaughlin MS, Parker DL, et al. Carotid mri detection of intraplaque hemorrhage at 3T and 1.5T. J Neuroimaging. 2015; 25:390–6. [PubMed: 25040677]
28. Altaf N, Kandiyil N, Hosseini A, Mehta R, MacSweeney S, Auer D. Risk factors associated with cerebrovascular recurrence in symptomatic carotid disease: A comparative study of carotid plaque morphology, microemboli assessment and the european carotid surgery trial risk model. J Am Heart Assoc. 2014; 3:e000173. [PubMed: 24895159]
29. Hosseini AA, Kandiyil N, Macsweeney ST, Altaf N, Auer DP. Carotid plaque hemorrhage on magnetic resonance imaging strongly predicts recurrent ischemia and stroke. Ann Neurol. 2013; 73:774–784. [PubMed: 23463579]
30. Murphy RE, Moody AR, Morgan PS, Martel AL, Delay GS, Allder S, et al. Prevalence of complicated carotid atheroma as detected by magnetic resonance direct thrombus imaging in patients with suspected carotid artery stenosis and previous acute cerebral ischemia. Circulation. 2003; 107:3053–3058. [PubMed: 12796136]
31. Mendes J, Parker DL, Kim SE, Treiman GS. Reduced blood flow artifact in intraplaque hemorrhage imaging using cinemprage. Magn Reson Med. 2013; 69:1276–1284. [PubMed: 22760825]
32. Ota H, Yarnykh VL, Ferguson MS, Underhill HR, Demarco JK, Zhu DC, et al. Carotid intraplaque hemorrhage imaging at 3.0-T MR imaging: Comparison of the diagnostic performance of three T1-weighted sequences. Radiology. 2010; 254:551–563. [PubMed: 20093526]
33. Cheung HM, Moody AR, Singh N, Bitar R, Zhan J, Leung G. Late stage complicated atheroma in low-grade stenotic carotid disease: MR imaging depiction--prevalence and risk factors. Radiology. 2011; 260:841–847. [PubMed: 21734157]
34. Hedna VS, Bodhit AN, Ansari S, Falchook AD, Stead L, Heilman KM, et al. Hemispheric differences in ischemic stroke: Is left-hemisphere stroke more common? J Clin Neurol. 2013; 9:97–102. [PubMed: 23626647]
35. Heidenreich PA, Trogdon JG, Khavjou OA, Butler J, Dracup K, Ezekowitz MD, et al. Forecasting the future of cardiovascular disease in the united states: A policy statement from the American Heart Association. Circulation. 2011; 123:933–944. [PubMed: 21262990]
36. Portegies MLP, Selwaness M, Hofman A, Koudstaal PJ, Vernooij MW, Ikram MA. Left-sided strokes are more often recognized than right-sided strokes. The Rotterdam Study. Stroke. 2015; 46:252–254. [PubMed: 25492906]
37. Selwaness M, van den Bouwhuijsen Q, van Onkelen RS, Hofman A, Franco OH, van der Lugt A, et al. Atherosclerotic plaque in the left carotid artery is more vulnerable than in the right. Stroke. 2014; 45:3226–3230. [PubMed: 25228259]
38. Tardif JC, Spence JD, Heinonen TM, Moody A, Pressacco J, Frayne R, et al. Atherosclerosis imaging and the canadian atherosclerosis imaging network. Can J Cardiol. 2013; 29:297–303. [PubMed: 23245557]
39. Appiah D, Schreiner PJ, Demerath EW, Loehr LR, Chang PP, Folsom AR. Association of age at menopause with incident heart failure: A prospective cohort study and meta-analysis. J Am Heart Assoc. 2016; 28:5. pii: e003769.
40. Burke AP, Farb A, Malcom G, Virmani R. Effect of menopause on plaque morphologic characteristics in coronary atherosclerosis. Am Heart J. 2001; 141:S58–62. [PubMed: 11174360]
41. Hellings WE, Pasterkamp G, Verhoeven BA, De Kleijn DP, De Vries JP, Seldenrijk KA, et al. Gender-associated differences in plaque phenotype of patients undergoing carotid endarterectomy. J Vasc Surg. 2007; 45:289–296. [PubMed: 17264005]
42. Nofer JR. Estrogens and atherosclerosis: Insights from animal models and cell systems. J Mol Endocrinol. 2012; 48:R13–29. [PubMed: 22355098]

Author Manuscript Author Manuscript Author Manuscript Author Manuscript

43. Bhavnani BR, Strickler RC. Menopausal hormone therapy. J Obstet Gynaecol Can. 2005; 27:137–62. [PubMed: 15937590]

44. Hodis HN, Mack WJ, Henderson VW, Shoupe D, Budoff MJ, Hwang-Levine J, et al. Vascular effects of early versus late postmenopausal treatment with estradiol. N Engl J Med. 2016; 374:1221–1231. [PubMed: 27028912]

Author Manuscript Author Manuscript Author Manuscript Author Manuscript

Figure 1.
MRI Depicted Carotid Intraplaque Hemorrhage Indicated by Signal Hyperintensity in the Vessel Wall.

Author Manuscript Author Manuscript Author Manuscript Author Manuscript

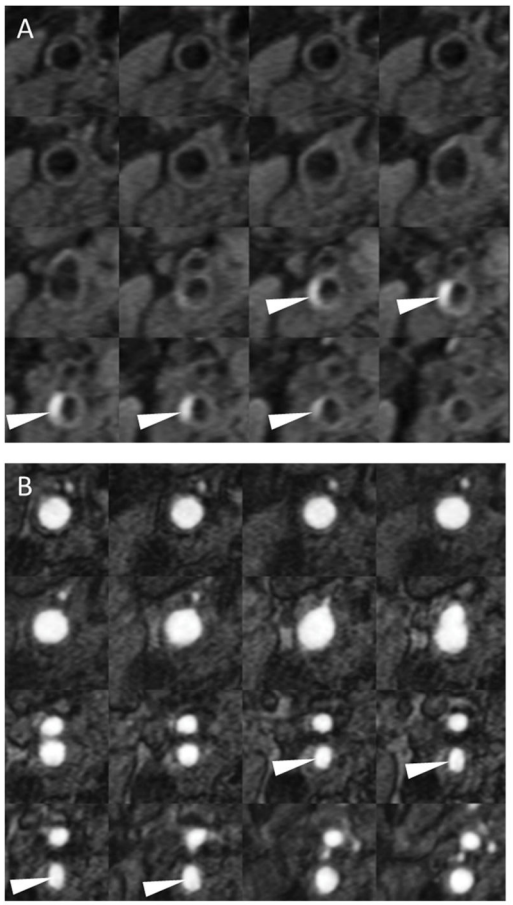

Figure 2.

Axial Images of Low-grade Carotid Stenosis and Intraplaque Hemorrhage. *Panel A* depicts intraplaque hemorrhage in the 6 o'clock to 12 o'clock position. *Panel B* demonstrates corresponding angiographic imaging depicting low-grade stenosis.

Author Manuscript Author Manuscript Author Manuscript Author Manuscript

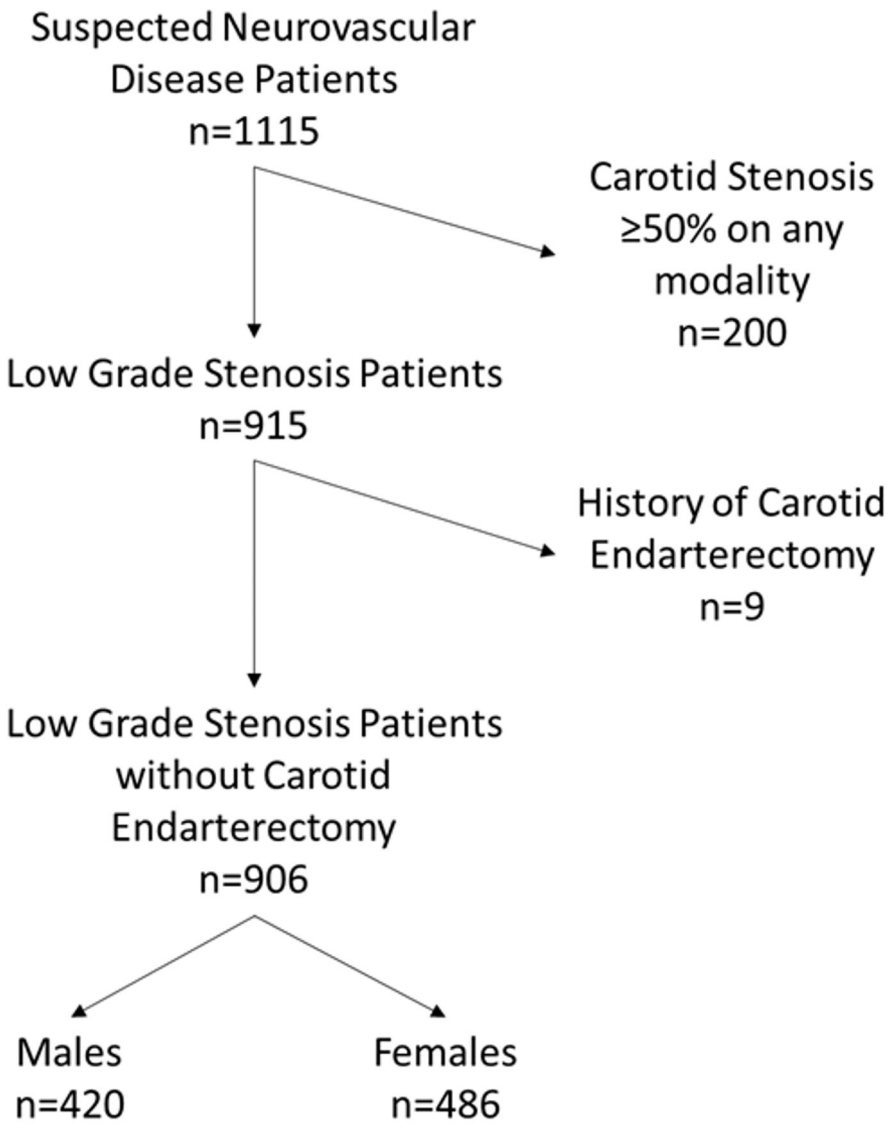

Figure 3.
Study Flow Chart of Participants.

Author Manuscript Author Manuscript Author Manuscript Author Manuscript

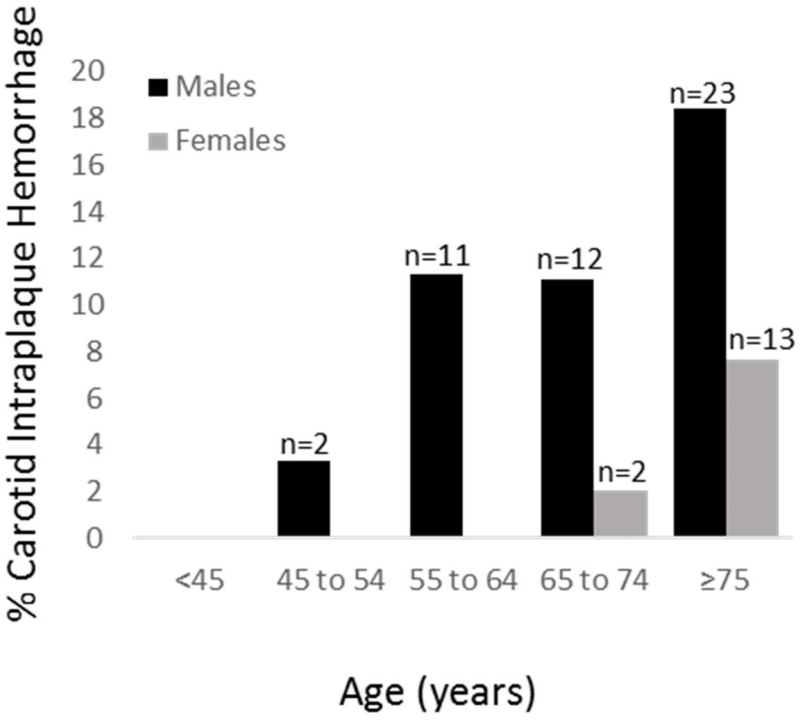

Figure 4.
Age-specific Sex Differences in the Presence of Carotid Intraplaque Hemorrhage.

Author Manuscript Author Manuscript Author Manuscript Author Manuscript

Table 1

Demographic Characteristics of Study Participants.

	All Patients (n=906)	Men (n=420)	Women (n=486)	p-value
Age, mean +/− SD	66.98 +/− 15.15	66.28+/−13.75	65.52+/−16.27	0.4548
MR-IPH, any	63 (6.95)	48 (11.43)	15 (3.09)	<0.0001
MR-IPH, Right n (%)	31 (3.42)	23 (5.48)	8 (1.65)	0.0017
MR-IPH, Left, n (%)	43 (4.75)	34 (8.10)	9 (1.85)	<0.0001
MR-IPH, Bilateral, n (%)	11 (1.21)	9 (2.14)	2 (0.41)	0.0287
Cardiovascular Risk Factors				
Hypertension, n (%)	561 (61.92)	276 (65.71)	285 (58.64)	0.0334
Dyslipidemia, n (%)	497 (54.86)	252 (60.00)	245 (50.41)	0.0040
Diabetes Mellitus 2, n (%)	200 (22.08)	118 (28.10)	82 (16.87)	<0.0001
Atrial Fibrillation, n (%)	120 (13.25)	62 (14.76)	58 (11.93)	0.2383
Smoking History (any), n (%)	280 (30.91)	165 (39.29)	115 (23.66)	<0.0001
Family History CAD, n (%)	242 (26.71)	108 (25.71)	134 (27.57)	0.5475
Medication History				
Antihypertensive, n (%)	452 (49.89)	223 (53.10)	229 (47.12)	0.0832
Statin, n (%)	384 (42.38)	203 (48.33)	181 (37.24)	0.0009
Antiplatelet, n (%)	169 (18.65)	81 (16.67)	88 (20.95)	0.1046
Anticoagulant, n (%)	501 (55.30)	237 (56.43)	264 (54.32)	0.5468
Antidiabetic Agent, n (%)	148 (16.34)	86 (20.48)	62 (12.76)	0.0021

Author Manuscript Author Manuscript Author Manuscript Author Manuscript

Table 2

Age-Specific Differences in Carotid Intraplaque Hemorrhage between Men and Women.

	Carotid IPH Presence, %						Reference Model*	Adjusted Model†
	Any		Unilateral Only		Bilateral Only			
Age in years	Men	Women	Men	Women	Men	Women	OR (95% CI)	OR (95% CI)
<45	0.00 (0/30)	0.00 (0/60)	0.00 (0/30)	0.00 (0/60)	0.00 (0/30)	0.00 (0/60)	--	--
45 to 54	3.33 (2/60)	0.00 (0/63)	1.67 (1/60)	0.00 (0/63)	1.67 (1/60)	0.00 (0/63)	52.63 (4.27 to 1000)	45.45 (3.42 to 500)
55 to 64	11.34 (11/97)	0.00 (0/95)	9.28 (9/97)	0.00 (0/95)	2.06 (2/97)	0.00 (0/95)	25.00 (3.88 to 166.67)	21.74 (3.21 to 142.86)
65 to 74	11.11 (12/108)	2.04 (2/98)	9.26 (10/108)	2.04 (2/98)	1.85 (2/108)	0.00 (0/98)	11.90 (3.39 to 41.67)	10.42 (2.91 to 37.04)
≥75	18.40 (23/125)	7.65 (13/170)	15.20 (19/125)	6.47 (11/170)	3.20 (4/125)	1.18 (2/170)	5.56 (2.61 to 11.76)	5.00 (2.31 to 10.75)

*The reference model shows the odds of carotid intraplaque hemorrhage in males versus females, and was adjusted for sex and a sex-by-age interaction term.

†The adjusted model shows the odds of carotid intraplaque hemorrhage in males versus females and was adjusted by hypertension, dyslipidemia, smoking history, diabetes, sex, and sex-by-age interaction term.