

## Case report

## Neglected acetabular fracture: Fix or replace?

Ismail Hadisoebroto Dilog<sup>a</sup>, Jephtah Furano Lumban Tobing<sup>b,\*</sup><sup>a</sup> Orthopaedic and Traumatology Department of Cipto Mangunkusumo General Hospital, Faculty of Medicine, Universitas Indonesia, Indonesia<sup>b</sup> Orthopaedic and Traumatology Resident of Faculty of Medicine, Universitas Indonesia, Indonesia

## ARTICLE INFO

## Article history:

Received 18 March 2017

Received in revised form 14 May 2017

Accepted 1 June 2017

Available online 2 June 2017

## Keywords:

Neglected acetabular fracture

Internal fixation

Total hip arthroplasty

## ABSTRACT

**Introduction:** Operative treatment of acute acetabular fractures has shown better results than the non-operative approach. There is, however, limited data regarding the operative treatment of neglected acetabular fracture.

**Methods:** We present six subjects with neglected fracture of the acetabulum in Cipto Mangunkusumo National Hospital, Jakarta, Indonesia. One had only open reduction and internal fixation, three had open reduction and internal fixation first before we performed arthroplasty later, one had both open reduction and internal fixation with arthroplasty, and another had immediate arthroplasty.

**Results:** Our subjects were 4 males and 2 females with the average age of 41.1 years and the average neglect period was 18 months. In four of our subjects, the fractures had posterior wall involvement, one had an anterior column-posterior hemitransverse fracture, and the last one had transverse fracture. All fractures were classified to either Elementary or Associated type according to the Letournel classification. We observed all subjects up to eighteen months post-operatively. One subject had poor outcome, four subjects had fair outcome, and one subject had excellent outcome according to the Harris Hip Score.

**Conclusion:** Even in neglected acetabular fracture, open reduction and internal fixation where possible should be attempted to restore the anatomical relationship to facilitate immediate or late total hip arthroplasty. Surgical treatment of such fractures should be based on individual case characteristics, which includes age, associated comorbidity, neglect period, as well as the type and union state of the fracture for a better outcome. Neglected Associated acetabular fracture types are more difficult to reduce and have poorer outcome compared to Elementary types. Likewise, malunited acetabular fractures are more difficult to operate on than non-united neglected acetabular fractures, where reduction is relatively easier.

© 2017

## 1. Introduction

Acute acetabular fracture remains a major injury to the hip joint where operative treatment has been shown to produce better results than the non-operative approaches.<sup>1,2</sup> There is, however, limited data regarding the operative treatment of neglected acetabular fracture. Although most authors recommend not delaying surgery for more than 11 days, there are still neglected cases found in the clinical setting, especially in developing countries.<sup>3</sup> The boundaries as to how a fracture is determined as “neglected” are also debatable, as terms in the literature vary. Nevertheless, it is common to describe an acetabular fracture as neglected if it had been more than 3 weeks. While the results are predictably poorer due to excessive callus formation in these

neglected cases, the consequences of a non-united or malunited acetabular fractures still bring about great impact on the patients' quality of life.<sup>4</sup> The major difference in treating neglected acetabular fracture to an acute one is the possible finding of malunion of the fracture fragments. While reports have shown that accurate reduction is obligatory to achieve good outcome, fracture fragments that are already united in an unsatisfactory position are very difficult, if not impossible, to reduce in neglected cases. The possible findings range from (1) removable callus, (2) organised non-unions, and (3) malunions.<sup>4</sup> Moreover, the longer it takes from the injury to the surgery means less probability of achieving a good reduction, hence leads to poor clinical outcome. This brings about the suggestion of whether one should proceed straight to arthroplasty in cases of malunited acetabular fracture. This report aims to share some experience in treating six cases of acetabular fracture that had been treated in our center.

We are reporting 6 cases of neglected acetabular fracture to which we performed either: open reduction and internal fixation

\* Corresponding author.

E-mail address: [jepthurano@gmail.com](mailto:jepthurano@gmail.com) (J.F.L. Tobing).

only; open reduction and internal fixation first before conducting a late arthroplasty; open reduction and internal fixation along with arthroplasty; or immediate arthroplasty without internal fixation.

## 2. Methods

Over the course of 2014–2016, we treated 6 subjects with neglected fracture of the acetabulum in Cipto Mangunkusumo National Hospital, Jakarta, Indonesia. All subjects underwent pre-operative pelvic x-rays (AP and Judet views) and non-contrast pelvic CT-scans with 3-dimensional reconstruction. One of these cases was treated with open reduction and internal fixation only, three cases were treated with open reduction and internal fixation first before we performed late arthroplasty, one case where we conducted both open reduction and internal fixation with arthroplasty, and another case where we did immediate arthroplasty. All of our reductions were internally fixated with 3.5 reconstruction plates and screws. In all patients that had total hip arthroplasty, we used ceramic-on-polyethylene bearing surfaces in all subjects.

The first subject was a 35-year old female with 3-year neglected malunited left posterior wall fracture of the acetabulum and non-union of the left midshaft femur, with a 4-cm discrepancy (Fig. 1A). On the first surgery, the posterior acetabular wall and the femur were fixated (Fig. 1B). We performed total hip arthroplasty 1 year later due to hip pain secondary to osteoarthritis (Fig. 1C). Post-operatively there was still a 2-cm leg-length discrepancy (Fig. 8A–E).

The second subject was a 48-year old male with 18-month neglected malunited left posterior wall and posterior column fracture of the acetabulum, with a 6-cm discrepancy (Fig. 2A and D). This particular subject had type-2 diabetes and a diabetic foot. After fixating the acetabular fracture (Fig. 2B), a year later the total hip arthroplasty was done in 2 stages (Fig. 2C), where the acetabular component and femoral component was inserted a week apart, in between which we performed a heavy skeletal traction to the femur to loosen the soft tissue contracture. There was no leg-length discrepancy post-operatively.

The third subject was a 58-year old male with 9-month neglected non-united left posterior wall fracture of the acetabulum, with a 1.5-cm discrepancy (Fig. 3A). We conducted open reduction and internal fixation of the posterior wall (Fig. 3B), and the total hip arthroplasty was done a year later. There was no leg-length discrepancy post-operatively (Fig. 3C).

The fourth subject was a 35-year old female with 1-year neglected non-united left anterior column-posterior hemitransverse fracture of the acetabulum with neglected posterior hip dislocation, with a 4-cm discrepancy (Fig. 4A and D). The first surgery was done to reduce and fix the acetabular fracture along with the acetabular component insertion for total hip arthroplasty (Fig. 4B). The patient was then put on heavy femoral traction for a week before the femoral component was inserted. There was no leg-length discrepancy post-operatively (Fig. 4C).

The fifth subject was a 40-year old male with 9-month neglected malunited right transverse posterior wall fracture of the acetabulum with central dislocation of the hip, with a 2-cm

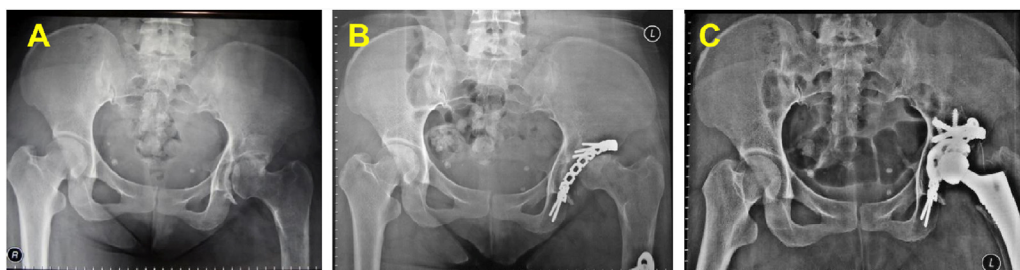

Fig. 1. First subject: (A) Preoperative x-ray; (B) After internal fixation; (C) After total hip arthroplasty.

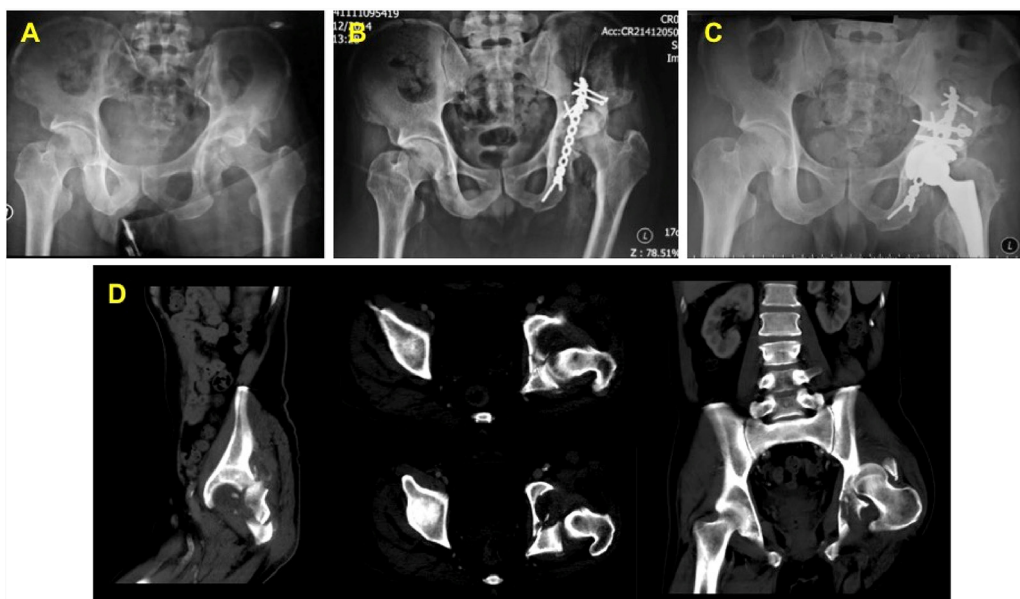
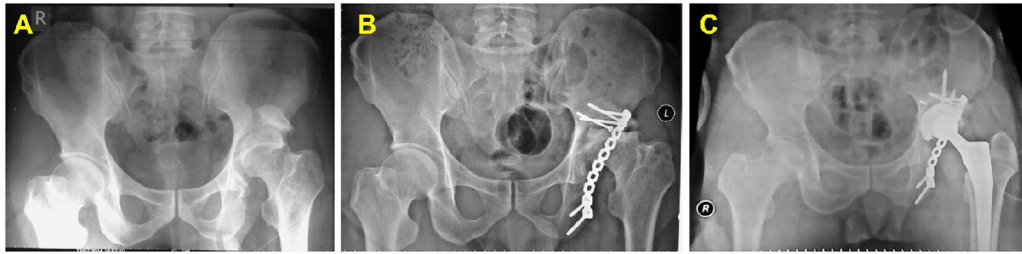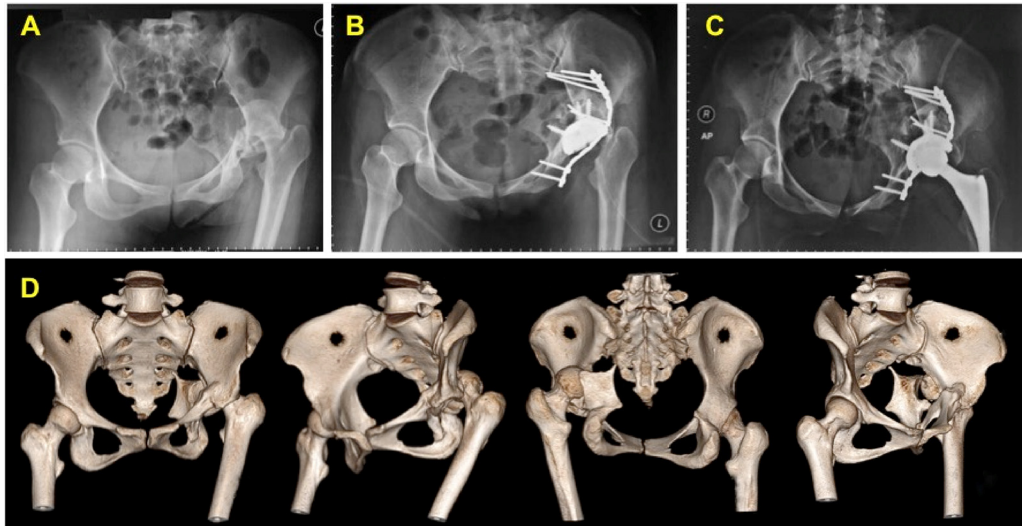


Fig. 2. Second subject: (A) Preoperative x-ray; (B) After internal fixation; (C) After total hip arthroplasty; (D) Pre-operative 2D CT-scan.



**Fig. 3.** Third subject: (A) Preoperative X-ray; (B) After internal fixation.; (C) After total hip arthroplasty.



**Fig. 4.** Fourth subject: (A) Preoperative X-ray; (B) After internal fixation and skeletal traction applied; (C) After femoral component insertion a week later; (D) Pre-operative 3D CT-scan.

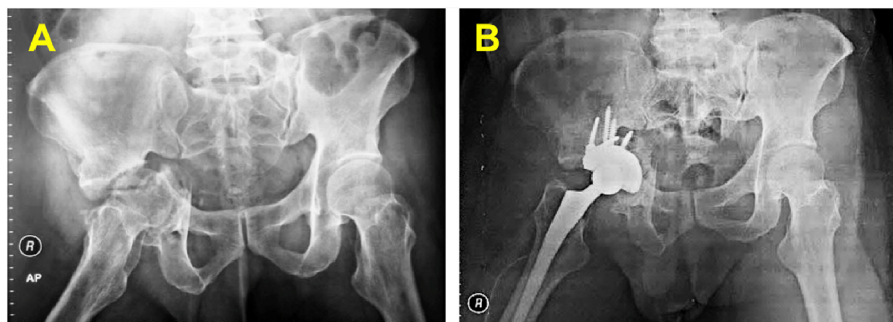
discrepancy (Fig. 5A). Total hip arthroplasty, acetabuloplasty and defect filling with bone graft were immediately performed on this case (Fig. 5B). The acetabuloplasty and bone graft were acquired from the bone block of the resected femoral head, fixated with two 6.5 cannulated screws. There was no leg-length discrepancy post-operatively.

The sixth subject was a 39-year old male with 24-month neglected non-united right transverse fracture of the acetabulum and right Denis zone II sacral fracture, with a 2-cm discrepancy (Fig. 6A and C). We conducted an open reduction and internal fixation of the posterior wall (Fig. 6B). There was still a 2-cm discrepancy post-operatively (Fig. 9A–F).

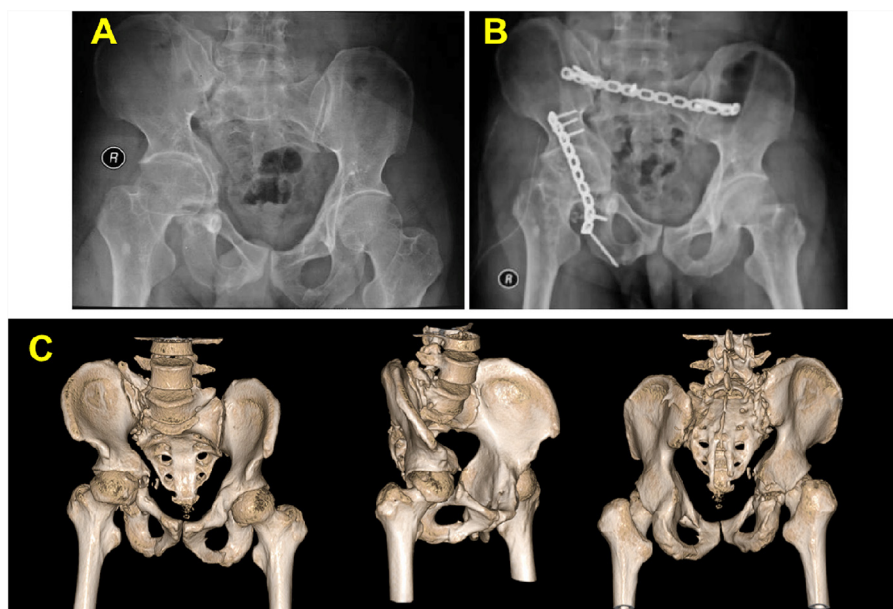
For all subjects, the posterior approach to the acetabulum was utilized. Post-operative assessment of the fracture was done through radiologic pelvic AP and Judet views, and functional outcome evaluation was measured using the Harris Hip Score (HHS),<sup>5</sup> which was done 6 months post-operatively (Fig. 7).

### 3. Results

Our subjects were active young adults, 4 males and 2 females, with the average age of 41.1 years (Table 1). The average period of neglect was 18 months. In four of our subjects the fractures had posterior wall involvement, one had an anterior column-posterior



**Fig. 5.** Fifth subject: (A) Preoperative X-ray; (B) After immediate total hip arthroplasty.



**Fig. 6.** Sixth subject: (A) Preoperative x-ray; (B) After internal fixation; (C) Pre-operative 3D CT-scan.

hemitransverse fracture, and the last one had transverse fracture of the acetabulum. Based on the Letournel classification,<sup>1</sup> three of our subjects fall into the Associated type, and the other three were the Elementary types. One of our subjects had an open reduction and internal fixation only, three underwent open reductions and internal fixations before total hip arthroplasties were performed a year later, one subject had both internal fixation and total hip arthroplasties performed simultaneously, and another subject got immediate total hip arthroplasty. In two of our subjects, the total hip arthroplasties were done in two stages: the acetabular components were fitted a week prior to the femoral component insertion, in between which we performed heavy tractions.

Complications that were found in these series were one subject complicated with infection and recurrent dislocation of the femoral component; and another subject had peroneal nerve palsy. One subject had poor outcome, four had fair outcome, and one had excellent outcome according to the HHS.

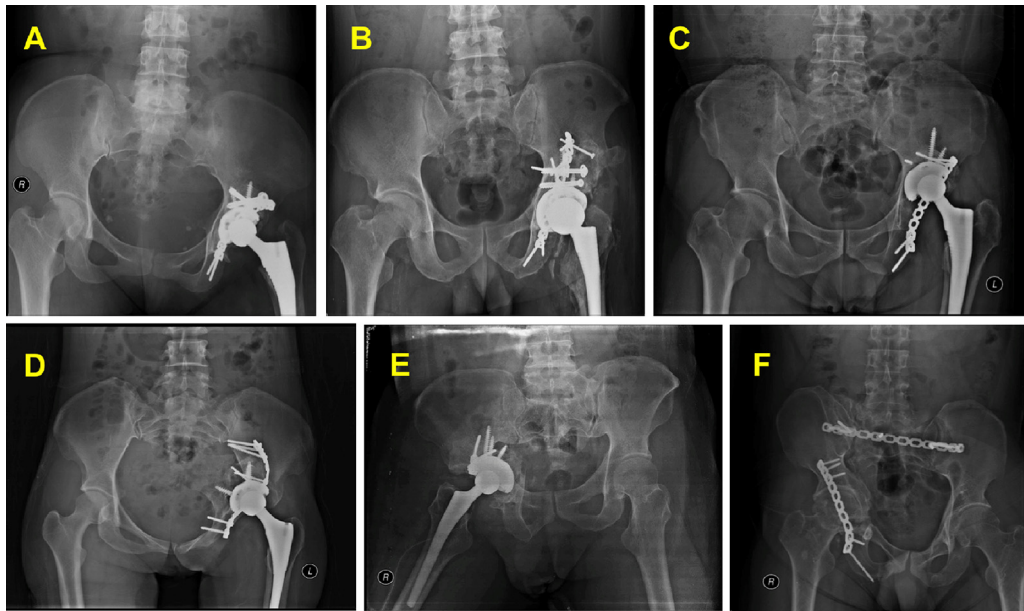
#### 4. Discussion

Generally, a reconstructive surgery for neglected acetabular fracture is indicated when there is incongruity between the femoral head and the acetabular cup.<sup>4</sup> Consistent with other articular fractures, acetabular fractures need anatomical reduction, and it has been confirmed that better reduction leads to better outcome clinically.<sup>3</sup> Bastian et al. reported that imperfect reduction of the acetabulum hastens the need of total hip replacement.<sup>6</sup> Hence is it is understandable that in acute acetabular fracture, the aim is to achieve anatomical reduction in order to delay degenerative changes that may lead to earlier need of total hip replacement. In a study of 424 acetabular fractures, it was reported that even in the hands of expert surgeons, 9–12% of those fractures were still poorly reduced.<sup>3</sup> Factors contributing to poor reduction are Associated fractures, older age, and delay to surgery. Neglected acetabular fractures, however, are

**Table 1**  
Characteristic of participants.

Sex, Age (years)	Diagnosis	Letournel Classification Type	Neglect Period (months)	First Surgery	Second Surgery	Harris Hip Score	Complications
Female, 35	<ul style="list-style-type: none"> <li>Non-union of left midshaft femur</li> <li>Malunion of left distal femur</li> <li>Neglected malunited left posterior wall fracture of the acetabulum</li> </ul>	Elementary	36	ORIF	THA	79.7	–
Male, 48	Neglected malunited left posterior wall and posterior column fracture of the acetabulum	Associated	18	ORIF	THA	72.1	Infection and recurrent dislocation of the femoral component
Male, 58	Neglected non-union of left posterior wall fracture of the acetabulum	Elementary	9	ORIF	THA	76	–
Female, 35	<ul style="list-style-type: none"> <li>Neglected posterior dislocation of the left hip</li> <li>Neglected non-union of left anterior column posterior hemitransverse fracture of the acetabulum</li> </ul>	Associated	12	ORIF and THA	N/A	73.9	Peroneal nerve palsy
Male, 40	Neglected malunited left transverse posterior wall fracture of the acetabulum with central dislocation of the hip	Associated	9	THA	N/A	62.8	–
Male, 39	<ul style="list-style-type: none"> <li>Neglected non-union of right transverse fracture of the acetabulum</li> <li>Neglected non-union of right sacral fracture Denis zone I</li> </ul>	Elementary	24	ORIF	N/A	92.8	–





**Fig. 7.** Six months x-ray follow up: (A) First subject; (B) Second subject; (C) Third subject; (D) Fourth subject; (E) Fifth subject; and (F) Sixth subject.

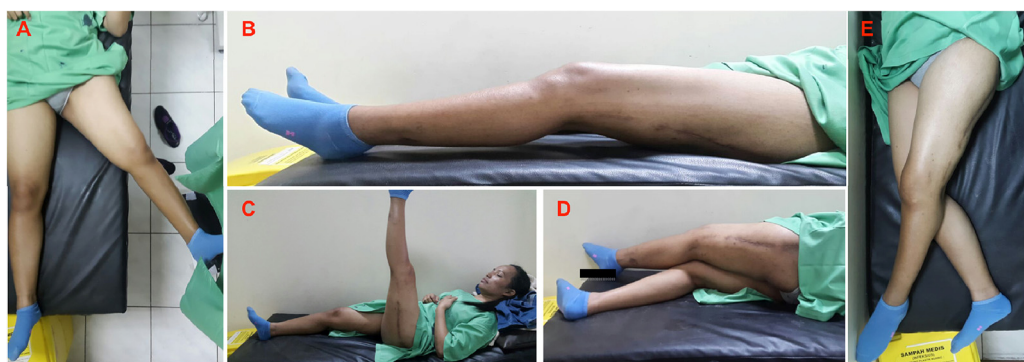often non-united or malunited, rendering visual recognition of the fracture pattern and reduction difficult intraoperatively.<sup>4</sup> It must be recalled that a delay of more than 11 days in presentation of acetabular fracture itself is associated with poor reduction.<sup>3</sup> Therefore it can be established that surgeons are already in an impediment when faced with neglected acetabular fractures.

In one of our six cases, we performed open reduction and internal fixation on an Elementary type, non-united fracture and have not yet done the total hip arthroplasty because the patient was still young and had no complaint regarding the affected hip (post operative HHS 92.8), and there was no sign of secondary osteoarthritis on the follow-up x-ray. In simple fracture patterns, it is advisable that reduction and internal fixation are attempted first before choosing arthroplasty (Fig. 10). The reason is because if a total hip arthroplasty is done in the future, in order for the acetabular component to fit perfectly, an acceptable articular surface of the acetabulum is needed, and previous reduction and internal fixation will greatly ease the arthroplasty procedure. Wolinsky et al. proposed that the need of total hip arthroplasty after fixation of the acetabulum relates to factors such as marginal impaction, posterior wall fracture, intraarticular fragments, and older age.<sup>7</sup> Nevertheless, the assessment of fracture union in neglected acetabular fracture must not be overlooked. If non-union occurs, open reduction and internal fixation might still be an

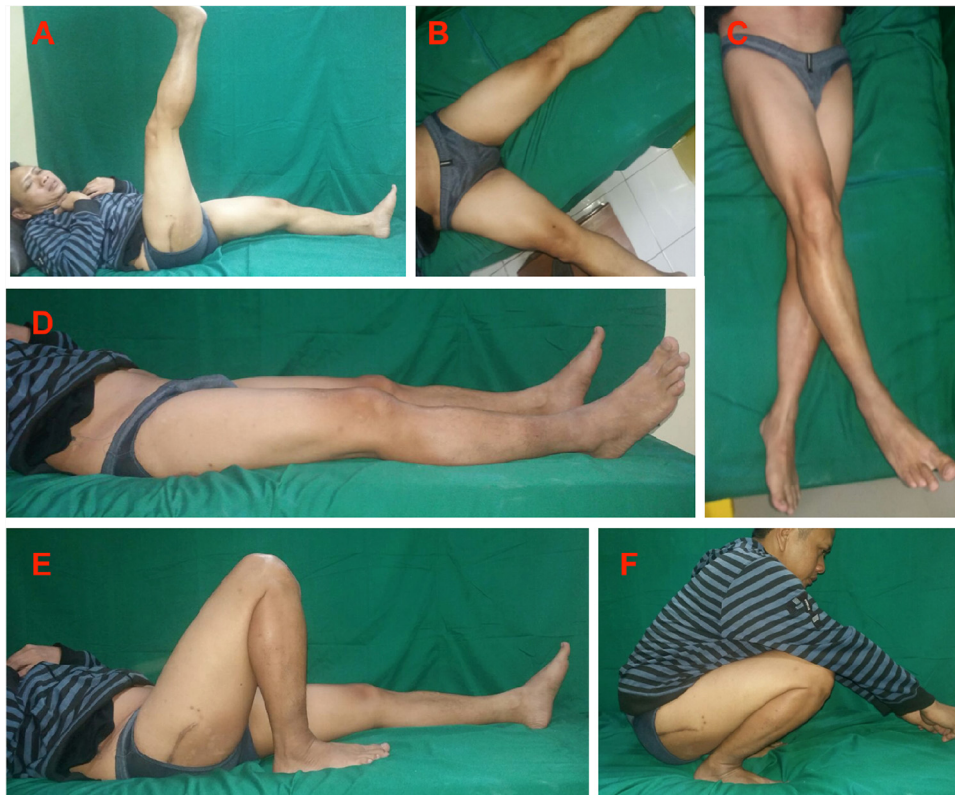option. If the fracture pattern is complex and already united, on the other hand, an attempt to reach anatomical reduction using internal fixation commonly leads to poor outcome. This suggests the possibility that in such case, a direct to arthroplasty method may yield better results (Fig. 10).

Mears et al.<sup>3</sup> had suggested that fracture reduction is harder to achieve in Associated fractures. Therefore, it is of utmost importance that the initial acetabular fracture pattern is recognized first before proceeding to any treatment plan (Fig. 10). The more complex the fracture pattern is, the more difficult the reduction will be. Before the era of computed tomography, fixation of an acetabular fracture is relatively contraindicated if there is an unrecognisable fracture line from the x-rays.<sup>4</sup> Nowadays, the 3-dimensional CT reconstruction of the fracture pattern in acetabular fracture is readily available and undoubtedly gives more information regarding the fracture lines, especially in neglected cases to see whether fracture union has occurred.<sup>8</sup>

In three of our six cases where sufficient reductions were expected during the pre-operative assessment, we decided to perform open reduction and internal fixation first. However, in all of these cases signs and symptoms of secondary osteoarthritis (OA) was apparent twelve months post-operatively. Even though we did not succeed in delaying the need of total hip arthroplasty, our previous reduction and fixation greatly eased the total hip



**Fig. 8.** Three months clinical follow up of the first subject: (A) Hip abduction, (B) Knee extension, (C) Hip flexion, (D) Knee flexion, (E) Hip adduction.



**Fig. 9.** Fifteen months clinical follow up of the sixth subject: (A) Hip flexion; (B) Hip abduction; (C) Hip adduction; (D) Knee extension; (E) Knee flexion; and (F) Squatting position.

arthroplasty process, especially during the placement of the acetabular cup. After total hip arthroplasty the functional outcomes were only fair in all cases according to the HHS, which might be due to the secondary degenerative changes that were already apparent by the time the HHS was obtained.

We attempted a simultaneous open reduction and internal fixation along with a total hip arthroplasty in one of the cases in our series due to the inadequate coverage of the acetabulum after reduction. However, due to the 4 cm leg-length discrepancy pre-operatively, heavy traction was needed to pull the affected lower extremity before the hip was reduced and this caused a complication of a peroneal nerve palsy. Based on this experience, we suggest that if internal fixation was to be done simultaneously with a total hip arthroplasty, less pre-operative leg-length discrepancy might lead to a more favorable outcome. The long-term outcome for acetabular fracture treated with heavy traction itself was reported to be good in 56% of cases.<sup>9</sup>

In one of our subjects who had an Associated, malunited fracture, a decision to perform immediate total hip arthroplasty was made after the intraoperative assessment suggested that an attempt to reconstruct the malunited fracture fragments might lead to further damage (due to ligaments release, possible injury to adjacent structures). The functional outcome was poor compared to the other cases where the acetabulum was fixated first. However, because this was an Associated type accompanied with a central hip dislocation, we assumed that this was due to the complex initial fracture pattern and dislocation and not due to the choice of treatment. Whenever an immediate total hip arthroplasty is selected as the treatment option, restoration of equal leg-length and the hip's center of rotation remain as the main treatment goals.

Mears et al.<sup>10</sup> were the first to define a clear distinction of which one might prefer arthroplasty than open reduction in acute acetabular fracture. The selected few cases were those with extensive impaction or erosion of the acetabular or femoral articular surface, marked comminution, and signs of poor bone stock. These characteristics often are found in the older age groups. Neglected acetabular fractures, however, often happens in the younger age groups, which means faster rate of fracture union and good bone stock. The author also suggested that deliberate placement of an oversized acetabular component may help in achieving a more stable acetabular cup.<sup>10</sup> A study on 128 subjects with posterior wall fracture of the acetabulum showed that more than half the subjects aged >50 years with marginal impaction and wall comminution had earlier need for hip arthroplasty, to which the authors suggested immediate total hip arthroplasty in these age group.<sup>11</sup> In the elderly, there have been reports on the predictors of failure after reduction and internal fixation such as impaction on the superomedial dome or posterior wall, hip dislocation, comminutive fractures on the posterior wall, and femoral head injury.<sup>10–14</sup> Although these factors might suggest the need of early arthroplasty, the operating surgeon must first be sure that the condition of the acetabular fragments is stable enough in order for the acetabular component to fit perfectly.<sup>15</sup>

In a long-term study of 53 patients who had undergone total hip arthroplasty after acetabular fractures, it was reported that both implant loosening and failure in these cases is much higher than that of primary arthroplasties.<sup>16</sup> We have not yet found such case in our experience due to the follow-ups being short term and still merit further observation. Though acetabular reinforcement cages and ceramic-on-ceramic bearing surfaces might be the better options for the longevity of the implants for neglected acetabular fracture, standard acetabular cup and ceramic-on-polyethylene

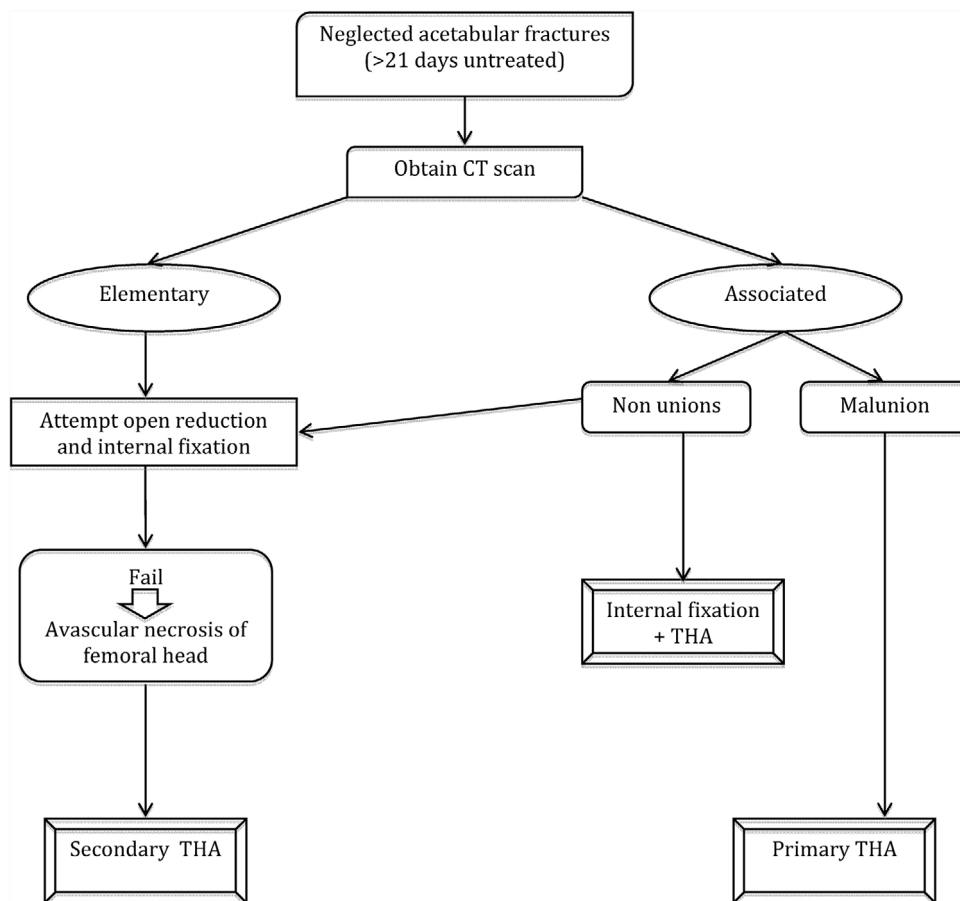

Fig. 10. Recommendation of treatment approaches for neglected acetabular fractures.

bearing surfaces were used in all of our arthroplasty cases due to unaffordability.

Post-traumatic nerve palsies associated with acetabular fractures happened in 16.4% cases, and higher if is associated with posterior hip dislocation.<sup>17</sup> In this series, we had one subject that had foot drop due to iatrogenic peroneal nerve injury. Another complication that value further observation in the subjects is heterotopic ossificans (HO), which happens in 1 of 4 cases, and is linked to the iliofemoral approach that we did not utilize in treating our subjects. Fixation delay as found in neglected acetabular fracture, however, was shown to be more likely to be complicated by HO, and must be evaluated periodically.<sup>18</sup>

The functional outcome of most of our subjects was fair according to the HHS, and this might be related to the fact that most of our subjects had posterior wall involvement, which had been associated with poor outcome independent of the quality of the reduction.<sup>19</sup>

## 5. Conclusion

As a general rule, even in neglected acetabular fracture, open reduction and internal fixation where possible should be attempted to restore the anatomical relationship to facilitate immediate or late total hip arthroplasty as situation demands, as well as to eliminate leg length discrepancy as much as possible. However, surgical treatment of such fractures should be based on individual case characteristics, which includes age, associated comorbidity, neglect period, as well as the type and union state of

the fracture for a better outcome. Neglected Associated acetabular fracture types are more difficult to reduce and have poorer outcome compared to Elementary types. Likewise, malunited acetabular fractures are more difficult to operate on than non-united neglected acetabular fracture, where reduction is relatively easier.

## Conflict of interest

The authors have none to declare.

## References

1. Letournel E. Acetabulum fractures: classification and management. *Orthop Trauma Dir.* 2007;5(05):27–33.
2. Kebaish AS, Roy A, Rennie W. Displaced acetabular fractures: long-term follow-up. *J Trauma Acute Care Surg.* 1991;31(11):1539–1542.
3. Mears DC, Velyvis JH, Chang C-P. Displaced acetabular fractures managed operatively: indicators of outcome. *Clin Orthop Relat Res.* 2003;407:173–186.
4. Letournel E. Surgical repair of acetabular fractures more than three weeks after injury, apart from total hip replacement. *Int Orthop.* 1978;2(4):305–313.
5. Harris WH. Traumatic arthritis of the hip after dislocation and acetabular fractures: treatment by mold arthroplasty. *J Bone Jt Surg Am Vol.* 1969;51(4):737–755.
6. Bastian J, Tannast M, Siebenrock K, Keel M. Mid-term results in relation to age and analysis of predictive factors after fixation of acetabular fractures using the modified Stoppa approach. *Injury.* 2013;44(12):1793–1798.
7. Predictors of total hip arthroplasty in patients following open reduction and internal fixation of acetabular fractures. In: Wolinsky P, Davison B, Shyr Y, Talwalker V, Johnson K, eds. .
8. Moed BR, Carr SEW, Gruson KI, Watson JT, Craig JG. Computed tomographic assessment of fractures of the posterior wall of the acetabulum after operative treatment. *J Bone Jt Surg Am Vol.* 2003;85(3):512–522.

9. Sen RK, Veerappa LA. Long-term outcome of conservatively managed displaced acetabular fractures. *J Trauma Acute Care Surg.* 2009;67(1):155–159.
10. Mears DC, Velyvis JH. Acute total hip arthroplasty for selected displaced acetabular fractures. *J Bone Jt Surg Am Vol.* 2002;84(1):1–9.
11. Kreder H, Rozen N, Borkhoff C, et al. Determinants of functional outcome after simple and complex acetabular fractures involving the posterior wall. *Bone Jt J.* 2006;88(6):776–782.
12. Anglen JO, Burd TA, Hendricks KJ, Harrison P. The Gull Sign: a harbinger of failure for internal fixation of geriatric acetabular fractures. *J Orthop Trauma.* 2003;17(9):625–634.
13. Bhandari M, Matta J, Ferguson T, Matthys G. Predictors of clinical and radiological outcome in patients with fractures of the acetabulum and concomitant posterior dislocation of the hip. *Bone Jt J.* 2006;88(12):1618–1624.
14. Matta JM. Fractures of the acetabulum: accuracy of reduction and clinical results in patients managed operatively within three weeks after the injury. *J Bone Jt Surg Am Vol.* 1996;78(11):1632–1645.
15. Ferguson TA, Patel R, Bhandari M, Matta J. Fractures of the acetabulum in patients aged 60 years and older. *Bone Jt J.* 2010;92(2):250–257.
16. Romness DW, Lewallen DG. Total hip arthroplasty after fracture of the acetabulum. Long-term results. *Bone Jt J.* 1990;72(5):761–764.
17. Giannoudis P, Grotz M, Papakostidis C, Dinopoulos H. Operative treatment of displaced fractures of the acetabulum. *Bone Jt J.* 2005;87(1):2–9.
18. Daum WJ, Scarborough MT, Gordon W, Uchida T. Heterotopic ossification and other perioperative complications of acetabular fractures. *J Orthop Trauma.* 1992;6(4):427–432.
19. Moed BR, Carr SEW, Watson JT. Open reduction and internal fixation of posterior wall fractures of the acetabulum. *Clin Orthop Relat Res.* 2000;377:57–67.