

## CASE REPORT

# Critical illness myopathy in a cervical spine-injured patient

Franz K Pencle<sup>1</sup>, Nelofar Kureshi<sup>2</sup>, Timothy Benstead<sup>3</sup> and Sean D Christie<sup>2</sup>

Neuromuscular weakness acquired in the intensive care unit (ICU) causes significant impairment in critically ill patients. The spectrum of critical illness neuromuscular disease includes critical illness myopathy, critical illness polyneuropathy or both, and occurs in approximately one-third of patients admitted to the ICU and those who are ventilated for at least 7 days. Recognized risk factors include sepsis, systemic inflammatory response syndrome, multi-organ failure, neuromuscular blocking agents and corticosteroids, however the absence of predisposing factors should not preclude critical illness neuromuscular disease. A 23-year-old male suffered a cervical spine injury and was admitted to the ICU. Two weeks post admission, he lost all power in his upper limbs, neck and face. Nerve conduction studies and needle electromyography were performed 4 weeks and 3 months after the injury, suggesting that myopathy was the likely cause of weakness. The definitive diagnosis of critical illness myopathy was based on muscle biopsy demonstrating myosin filament loss. Evaluation of new-onset weakness in ICU patients is essential to distinguish neurological causes from complications of critical illness. Signs and symptoms of critical illness neuromuscular disease must be identified early to encourage recovery, promote rehabilitation, and reduce morbidity and mortality.

*Spinal Cord Series and Cases* (2016) **2**, 16017; doi:10.1038/scsandc.2016.17; published online 14 July 2016

## INTRODUCTION

In critically ill patients, various factors including infection, trauma, surgery and multi-organ failure may lead to a syndrome of neuromuscular weakness, often referred to as critical illness neuromuscular disease. Risk factors in contracting critical illness neuromuscular disease include prolonged length of intensive care unit (ICU) stay, severity of illness, exposure to intravenous corticosteroids, neuromuscular blockers, sepsis and systemic inflammatory response syndrome (SIRS).<sup>1</sup> Recent studies suggest that strict glycaemic control in the critically ill neurological patient can decrease the risk of developing this syndrome.

Critical illness myopathy (CIM) and critical illness polyneuropathy (CIP) are common types of acquired generalized weakness within the spectrum of critical illness neuromuscular disease. CIM or ICU myopathy is the most frequent myopathy affecting critically ill patients and is defined by atrophy of type II muscle fibres and loss of thick filament myosin.<sup>2</sup> It was first described in 1977,<sup>3</sup> primarily in critically ill asthmatics,<sup>4</sup> but since then has become increasingly recognized through a wide gamut of admissions to the ICU.

CIM often shows significant overlap with CIP, which primarily affects both motor and sensory fibres.<sup>5</sup> The reported incidence rates of CIM vary according to the ICU patient population studied risk factors, and timing of diagnostic evaluation and are often reported as combined CIM and CIP. It has been suggested that over 60% of patients who are in the ICU for at least 7 days will develop critical illness neuromuscular disease;<sup>6</sup> the incidence rises to 75% in patients with sepsis or SIRS and occurs in nearly all individuals with multiple organ failure.<sup>7</sup>

Patients with critical illness neuromuscular disease generally develop a flaccid paralysis, commonly with symmetric weakness

both proximally and distally, with sparing of sensations and normal or decreased deep tendon reflexes. The International Standards for Neurological Classification of Spinal Cord Injury (ISNCSCI) examination can be used to determine the motor and sensory impairment and severity of a spinal cord injury in such patients.<sup>8</sup> Further investigations may be challenging in critically ill patients, but provide reliable diagnostic information. Electrophysiological studies showing normal or minimally reduced nerve conduction velocity, reduced muscle excitability on direct stimulation, reduced compound muscle action potential, amplitude, fibrillation and small motor unit potentials identify patients with CIM. The definitive diagnosis of CIM is made by a muscle biopsy. Electromyography (EMG) and nerve conduction studies (NCS) are the gold standard for diagnosis of CIP in which there is a decline in the amplitude of sensory and compound muscle action potentials.

To our knowledge, there are no previous reports of CIM following spinal cord injury. This case report describes the clinical course, features, diagnosis and treatment of CIM in a 23-year-old male with cervical spine injury admitted to the ICU.

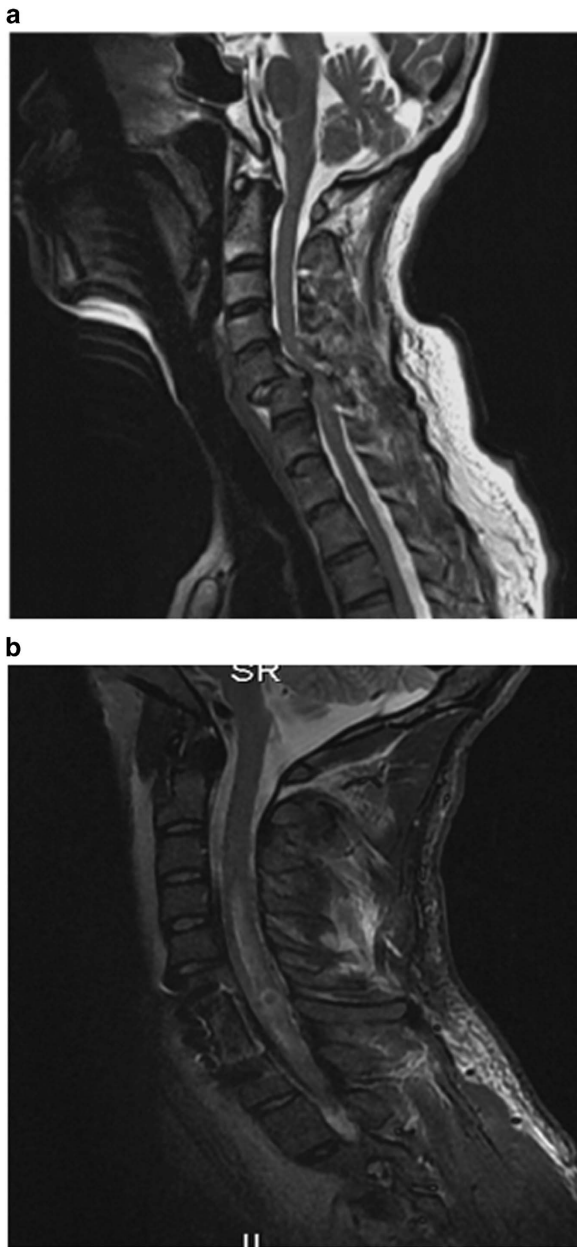
## CASE REPORT

The patient was a 23-year-old male with no chronic illnesses who dove into shallow water from a pier after reportedly consuming alcohol. After stabilization, he was transferred to the tertiary trauma centre for definitive management. Upon arrival to our site, he was found to be alert, oriented and co-operative. His blood pressure was 130/80 mm Hg and an electrocardiogram showed sinus rhythm with a heart rate of 65 beats per minute. A detailed clinical evaluation revealed that the patient had an upper extremity motor score of 32/50 and lower extremity

<sup>1</sup>Department of Surgery, Radiology, Anaesthetics and Intensive Care, University of the West Indies, Mona, Jamaica; <sup>2</sup>Department of Surgery, Division of Neurosurgery, Dalhousie University/QEII Health Sciences Centre, Halifax, Nova Scotia, Canada and <sup>3</sup>Department of Medicine, Division of Neurology, Dalhousie University/QEII Health Sciences Centre, Halifax, Nova Scotia, Canada.

Correspondence: SD Christie (sean.christie@dal.ca)

Received 7 March 2016; revised 18 March 2016; accepted 28 May 2016



**Figure 1.** (a) Pre-operative MRI of cervical spine. (b) Post-operative MRI of cervical spine.

motor score of 0/50. There was preservation of neurological function at S4–S5 as determined by examination of sensory and motor functions; rectal examination demonstrated the presence of deep anal pressure. The patient's injury was classified as ASIA Impairment Scale Grade B. Chest examination was clear with normal expansion and breath sounds. His abdomen was flat, soft and no organomegaly detected. There was no abnormal discoloration or bruising over the limbs.

Imaging of the cervical spine (Figure 1a) revealed a flexion-compression injury resulting in a C6 vertebral body fracture and a C7 burst fracture with spinal cord compression and contusion. A C7 corpectomy was performed within 24 h of injury; the patient also underwent anterior fusion with allograft and plate at C6–T1. The patient was subsequently admitted to the ICU for acute spine care with maintenance of mean arterial pressure

above 85 mm Hg and glycaemic control (7.8–10.0 mmol l<sup>-1</sup>). Post-operative neurological evaluation did not detect the presence of early surgical complications or changes in the patient's neurologic function.

He had a bradycardic event followed by asystolic arrest on day 11 post admission and followed by a second asystolic arrest on day 18. A dual mode, dual chamber, dual sensing permanent pacemaker was inserted on day 23 at the recommendation of cardiology. The patient also had a single blood culture positive for *Staph epidermidis* on day 18. At day 12 post admission, the patient was noted to be poorly interactive, which correlated with the timing of the family and patient discussion of his illness and prognosis the day before. A psychiatric consult was sought as patient noted to be more withdrawn and unable to comply with nursing or physiotherapy requests. After day 15, he lost all power in his upper limbs, neck and face. This warranted urgent repeat imaging. MRI of cervical spine (Figure 1b) did not demonstrate new spinal cord compression, rather just the expected post-traumatic oedema. A neurology consult was obtained and nerve conduction and EMG studies were performed. NCS and needle electromyography were performed 4 weeks and 3 months after the injury. The early study demonstrated almost completely normal sensory NCS. Motor NCS demonstrated mainly absent compound muscle action potential (CMAP) in the upper and lower extremities, with a very small CMAP seen only in the median nerve (Figure 2). Needle EMG demonstrated fibrillations and absent activation of motor unit potentials in upper and lower extremity muscles. The study suggested that myopathy was the likely cause of the weakness. The same study performed at 3 months demonstrated minimal improvement in upper extremity muscles.

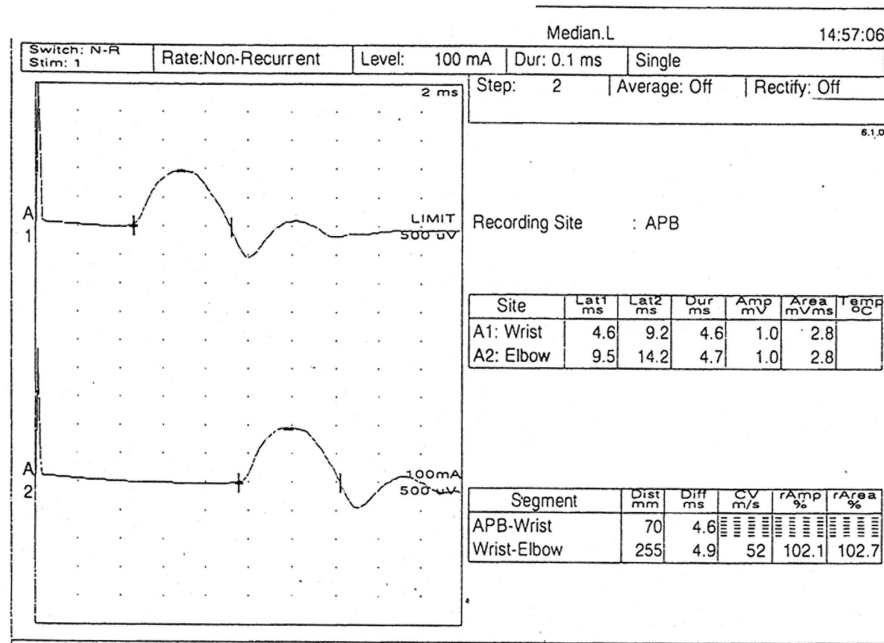
After weaning from tracheostomy, the patient was transferred to the neurosurgical floor. Based on the electrophysiological testing, a muscle biopsy was requested and obtained at day 45 post admission. A definitive diagnosis of CIM was made based on myosin filament loss (Figure 3). He required a prolonged admission to the neurosurgical floor. The patient showed progressive yet minimal neurological recovery with return of face and neck movement regained grade 1–2 power over a period of 4 months.

## DISCUSSION

Although critical illness neuromuscular disease is a common complication in ICU patients,<sup>5,6</sup> no previous reports of CIM following spinal cord injury have been documented. We report a unique case of CIM in a young patient with no predisposing risk factors for this neuromuscular disorder.

The incidence of CIM varies in subsets of critically ill patients; this neuromuscular condition develops in at least one-third of ICU patients treated for status asthmaticus and occurs in 25–63% of patients mechanically ventilated for more than a week.<sup>9</sup> Subpopulations of critically ill patients with sepsis and multi-organ failure are thought to have a 100% incidence of CIM/CIP.<sup>10</sup>

Sepsis, systemic inflammatory response syndrome, multi-organ failure, neuromuscular blocking agents and corticosteroids have been identified as independent risk factors for CIM.<sup>11,12</sup> Systemic inflammation during early critical illness is one of the main risk factors for developing CIM with significantly raised interleukin-6 levels present in patients with abnormal muscle membrane excitability.<sup>13,14</sup> Clinical features of CIM include diffuse flaccid and symmetrical weakness as well as reduced or absent deep tendon reflexes with preservation of sensory function. CIM is suspected when there is difficulty weaning the patient from mechanical ventilation after sedation is discontinued.<sup>15</sup> Rates of reintubation are twice as



**Figure 2.** Nerve conduction study of left median nerve demonstrates small compound muscle action potential amplitude with normal conduction velocity.

high in patients with CIM/CIP compared with patients without neuromuscular disorders.<sup>16</sup>

A thorough review of our patient's medications while admitted to the ICU included trazadone, vancomycin, heparin, magnesium sulphate, bisacodyl, clotrimazole, propofol, fentanyl, clonazepam, atropine, gabapentin, docusate and dalteparin. Corticosteroids were not prescribed, as this is not a part of our treatment protocol for spinal cord-injured patients; neither was he managed with pharmacologic paralytic agents. There was no evidence of overwhelming sepsis documented and no features of a systemic response to sepsis.

De Jonghe *et al.*<sup>17</sup> have suggested that CIP/CIM is arbitrarily diagnosed if the Medical Research Council sum score is <48. Alert and cooperative ICU patients with spinal cord injury can be accurately assessed using ISNCSCI to classify and describe the extent of motor and sensory dysfunction due to SCI. Electrophysiological studies have an important role in differentiating between CIM and CIP; the presence of normal sensory nerve action potentials, small CMAP and inexcitability of muscle to direct electrical stimulation are highly suggestive of CIM. With limited distinguishing features, the clinical diagnosis of CIM is challenging and a muscle biopsy is required for definitive diagnosis.<sup>1</sup> The key histopathological finding in CIM is characterized by the absence of myosin filaments;<sup>18,19</sup> the breakdown of the thick filament myosin may be in an effort to generate increased amino acids to meet the demand during critical illnesses.<sup>20</sup>

In the absence of currently defined risk factors, clinical suspicion and diagnostic studies may be delayed. Testing of proximal and deep muscles is often challenging in spinal cord injury patients due to sedation and generalized weakness. Evaluation of new-onset weakness in spinal cord injury ICU patients with prolonged stay should include the coordination of imaging, electrophysiological investigation and histological examination of muscle biopsy.

Widely recognized preventative strategies for CIM and CIP include aggressive treatment of sepsis and strict control of hyperglycaemia.<sup>21</sup> Electrical stimulation may be helpful, but

requires further study.<sup>22</sup> Although there are no established therapeutic interventions for the CIM and CIP, supportive measures such as nutritional, antioxidant and hormonal therapies have been suggested.<sup>23</sup> Intensive insulin therapy reduces the collective incidence of CIM and CIP from 49 to 25% in surgical ICU patients, and from 51% to 39% in medical ICU patients.<sup>24</sup>


The prognosis of CIM depends on patient age and severity of illness. In mild cases, spontaneous recovery occurs within weeks, whereas severe cases may have longer or incomplete recovery.<sup>25</sup> In CIM associated with acute respiratory distress syndrome, persistent functional limitation secondary to muscle weakness has been noted even after a year of discharge.<sup>26</sup> Earlier reports have suggested that CIM and CIP have similar functional outcomes after ICU discharge, but more recently, Guarneri *et al.*<sup>27</sup> demonstrated that CIM may have a better prognosis than CIP. This underlies the importance of an accurate clinical and pathological differentiation of these similar entities in predicting long-term outcomes after prolonged ICU stay.

Critical care management has a crucial role in the treatment of patients with spinal cord injury. Although multiple stressors such as sepsis, SIRS, neuromuscular blocking agents and corticosteroids are recognized predisposing factors for ICU-acquired neuromuscular abnormalities, the presence of flaccid muscle weakness and difficulty in weaning warrants further investigation.

## CONCLUSION

Evaluation of new-onset weakness in ICU patients is essential to distinguish neurological causes from complications of critical illness. Signs and symptoms of critical illness neuromuscular disease must be identified early to encourage recovery, promote rehabilitation, and reduce morbidity and mortality. Established risk factors such as sepsis, systemic inflammatory response syndrome, multi-organ failure, neuromuscular blocking agents and corticosteroids should raise clinical suspicion; however the absence of predisposing factors does not preclude critical illness neuromuscular disease.





**Figure 3.** (a) Thick (myosin) filament loss under electron microscopy. (b) Closer view of Z disc with actin filaments but no myosin band. (c) Same patient with normal sarcomeres in part of the muscle—note the darker strip of myosin filaments next to the paler strip of actin filaments anchored to a dark Z disc.

## COMPETING INTERESTS

The authors declare no conflict of interest.

## REFERENCES

- Friedrich O. Critical illness myopathy: sepsis-mediated failure of the peripheral nervous system. *Eur J Anaesthesiol Suppl* 2008; **42**: 73–82.
- Stevens RD, Marshall SA, Cornblath DR, Hoke A, Needham DM, de Jonghe B *et al*. A framework for diagnosing and classifying intensive care unit-acquired weakness. *Crit Care Med* 2009; **37**: S299–S308.
- Macfarlane IA, Rosenthal FD. Severe myopathy after status asthmaticus. *Lancet* 2016; **310**: 615.
- Douglass JA, Tuxen DV, Horne M, Scheinkestel CD, Weinmann M, Czarny D *et al*. Myopathy in severe asthma. *Am Rev Respir Dis* 1992; **146**: 517–519.
- Bolton CF. Neuromuscular manifestations of critical illness. *Muscle Nerve* 2005; **32**: 140–163.
- Manno EM. Neurological complications of medical illness: critical illness neuropathy and myopathy. In: Manno EM (ed.). *Emergency Management in Neurocritical Care*. Wiley-Blackwell: Oxford, 2012, pp 182–187.
- Tennilä A, Salmi T, Pettilä V, Roine RO, Varpula T, Takkunen O. Early signs of critical illness polyneuropathy in ICU patients with systemic inflammatory response syndrome or sepsis. *Intensive Care Med* 2000; **26**: 1360–1363.
- Kirschblum SC, Waring W, Biering-Sorensen F, Burns SP, Johansen M, Schmidt-Read M *et al*. Reference for the 2011 revision of the international standards for neurological classification of spinal cord injury. *J Spinal Cord Med* 2011; **34**: 547–554.
- Deem S. Intensive-care-unit-acquired muscle weakness. *Respir Care* 2006; **51**: 1042–1052.
- Eikermann M, Koch G, Gerwig M, Ochterbeck C, Beiderlinden M, Koeppen S *et al*. Muscle force and fatigue in patients with sepsis and multiorgan failure. *Intensive Care Med* 2006; **32**: 251–259.
- Stevens RD, Dowdy DW, Michaels RK, Mendez-Tellez PA, Pronovost PJ, Needham DM. Neuromuscular dysfunction acquired in critical illness: a systematic review. *Intensive Care Med* 2007; **33**: 1876–1891.
- Latronico N, Shehu I, Seghelini E. Neuromuscular sequelae of critical illness. *Curr Opin Crit Care* 2005; **11**: 381–390.
- Weber-Carstens S, Deja M, Koch S, Spranger J, Bubser F, Wernecke KD *et al*. Risk factors in critical illness myopathy during the early course of critical illness: a prospective observational study. *Crit Care* 2010; **14**: R119.
- Kwon BK, Stammers AMT, Belanger LM, Bernardo A, Chan D, Bishop CM *et al*. Cerebrospinal fluid inflammatory cytokines and biomarkers of injury severity in acute human spinal cord injury. *J Neurotrauma* 2010; **27**: 669–682.
- Hermans G, De Jonghe B, Bruyninckx F, Van den Berghe G. Clinical review: critical illness polyneuropathy and myopathy. *Crit Care* 2008; **12**: 238.
- De Jonghe B, Bastuji-Garin S, Sharshar T, Outin H, Brochard L. Does ICU-acquired paresis lengthen weaning from mechanical ventilation? *Intensive Care Med* 2004; **30**: 1117–1121.
- De Jonghe B, Sharshar T, Lefaucheur J-P, Authier F-J, Durand-Zaleski I, Boussarsar M *et al*. Paresis acquired in the intensive care unit: a prospective multicenter study. *JAMA* 2002; **288**: 2859–2867.
- Danon MJCS. Myopathy with thick filament (myosin) loss following prolonged paralysis with vecuronium during steroid treatment. *Muscle Nerve* 1991; **14**: 1131–1139.
- Hasselgren PO, Fischer JE. Sepsis: stimulation of energy-dependent protein breakdown resulting in protein loss in skeletal muscle. *World J Surg* 1998; **22**: 203–208.
- Friedrich O. Critical illness myopathy: what is happening? *Curr Opin Clin Nutr Metab Care* 2006; **9**: 403–409.
- Van den Berghe G, Schoonheydt K, Bexx P, Bruyninckx F, Wouters PJ. Insulin therapy protects the central and peripheral nervous system of intensive care patients. *Neurology* 2005; **64**: 1348–1353.
- Hermans G, De Jonghe B, Bruyninckx F, Van den Berghe G. Interventions for preventing critical illness polyneuropathy and critical illness myopathy. *Cochrane Database Syst Rev* 2014; **1**: CD006832.
- Garnacho-Montero J, Madrazo-Osuna J, García-Garmendia JL, Ortiz-Leyba C, Jiménez-Jiménez FJ, Barrero-Almodóvar A *et al*. Critical illness polyneuropathy: risk factors and clinical consequences. A cohort study in septic patients. *Intensive Care Med* 2001; **27**: 1288–1296.
- Hermans G, Wilmer A, Meersseman W, Milants I, Wouters PJ, Bobbaers H *et al*. Impact of intensive insulin therapy on neuromuscular complications and ventilator dependency in the medical intensive care unit. *Am J Respir Crit Care Med* 2007; **175**: 480–489.
- de Seze M, Petit H, Wiart L, Cardinaud JP, Gaujard E, Joseph PA *et al*. Critical illness polyneuropathy. A 2-year follow-up study in 19 severe cases. *Eur Neurol* 2000; **43**: 61–69.
- Herridge MS, Cheung AM, Tansey CM, Matte-Martyn A, Diaz-Granados N, Al-Saidi F *et al*. One-year outcomes in survivors of the acute respiratory distress syndrome. *N Engl J Med* 2003; **348**: 683–693.
- Guarneri B, Bertolini G, Latronico N. Long-term outcome in patients with critical illness myopathy or neuropathy: the Italian multicentre CRIMYNE study. *J Neurol Neurosurg Psychiatry* 2008; **79**: 838–841.