

CASE REPORT

Leydig cell tumour and mature ovarian teratoma: rare androgen-secreting ovarian tumours in postmenopausal women

Ana Palha,¹ Luísa Cortez,¹ Ana Paula Tavares,² Ana Agapito¹

¹Department of Endocrinology, Centro Hospitalar de Lisboa Central, Lisbon, Portugal

²Department of Surgery, Centro Hospitalar de Lisboa Central, Lisboa, Portugal

Correspondence to
Dr Ana Palha
anamfpalha@gmail.com

Accepted 17 October 2016

SUMMARY

Androgen-secreting ovarian tumours are extremely rare accounting for <5% of all ovarian neoplasms. They are more frequent in postmenopausal women and should be suspected in the case of a rapid onset of androgenic symptoms. We report 4 cases of postmenopausal women who presented with signs of virilisation. All patients revealed increased serum levels of testosterone, normal dehydroepiandrosterone-sulfate and negative pelvic ultrasound for adnexal masses. An androgen-secreting ovarian tumour was suspected and all of them were submitted to bilateral oophorectomy. Histology confirmed the diagnosis of Leydig cell tumours in 3 patients and mature teratoma in 1. A successful response to surgery, which includes a decline in serum androgen levels and signs of hyperandrogenism, was observed in our patients. This case series demonstrates that androgen-secreting ovarian neoplasms may not be detectable by imaging studies, but should be considered in the differential diagnosis of all postmenopausal women with signs of hyperandrogenism.

BACKGROUND

Androgen-secreting neoplasms of the ovary are a rare cause of hyperandrogenism in women and account for <5% of all ovarian neoplasms.¹ Hyperandrogenism can result in a virilisation syndrome, which is characterised by clitoral hypertrophy, deepening of the voice, increased libido, breast atrophy, severe hirsutism and male-pattern baldness.^{1 2} These tumours should be suspected when the onset of androgenic symptoms is sudden and rapidly progressive,³ especially if associated with signs of virilisation or defeminisation. In most cases, hormonal abnormalities include increased serum testosterone levels in the presence of normal dehydroepiandrosterone-sulfate (DHEA-S).³

Among functional ovarian neoplasms, sex-cord stromal tumours are the ones most commonly associated with hyperandrogenism.³ According to the WHO, Leydig cell tumours are classified in this group and account for 0.1% of all ovarian tumours.^{1 4}

They are usually benign, small, solid and predominantly seen in postmenopausal women.⁴

Mature teratoma is the most frequent germ cell tumour and a rare cause of androgen-secreting ovarian neoplasm.² It consists in tissues that recapitulate the ectoderm, endoderm and mesoderm. In most cases, this tumour contains non-secreting

tissues, however very rarely can produce testosterone leading to a virilisation syndrome.⁵

In postmenopausal women, bilateral oophorectomy is the preferred treatment, while in young women in whom fertility is an issue, a unilateral oophorectomy should be performed.

The prognosis for androgen-secreting neoplasms of the ovary is generally good with completely reversion of symptoms after surgery, although some cases have been reported to be malignant.³

CASE PRESENTATION

We report four cases of postmenopausal women presenting with several months' history of progressive facial and body hirsutism. Furthermore, patients 2–4 presented with androgenic alopecia and patient 3 with increased libido. No other virilisation signs, like enlarged muscle mass, deepening of voice or clitoromegaly, were seen in all presented cases.

Clinical, biochemical, radiological and histological features are presented in [tables 1–3](#).

The virilising manifestations were rapidly progressive (1 year or less), except in patient 1, who reported of progressive hirsutism for the last 3 years.

Appearance of a round and plethoric face coincident with the beginning of hirsutism was also referred in patient 1 and a long history of central obesity was observed in patients 2 and 4. Other symptoms suggestive of hypercortisolism, including lethargy, weakness, proximal myopathy, easy bruisability and purplish skin striae, were absent in all cases.

Menarche and menopause had occurred at proper ages and all patients referred regular menstrual cycles and normal fertility. Personal medical histories included hypertension, dyslipidaemia and cervix-sparing hysterectomy for uterine fibroids at 43 years (patient 1); hypertension, type 2 diabetes and thyroid lobectomy for benign thyroid nodule (patient 2); renal transplant due to polycystic kidney disease and new-onset diabetes after transplant (patient 3); and hypertension, ischaemic cardiomyopathy and asthma (patient 4).

Only patient 2 was taking drugs with androgenic effects (tacrolimus) for 5 years before the beginning of hirsutism. Their families' medical histories were unremarkable.

Physical examination confirmed signs of virilisation with facial and body hirsutism in all patients and androgenic alopecia in all except patient 1.



CrossMark

To cite: Palha A, Cortez L, Tavares AP, et al. *BMJ Case Rep* Published online: [please include Day Month Year] doi:10.1136/bcr-2016-215985

Table 1 Clinical features

	Patient 1	Patient 2	Patient 3	Patient 4
Age (years)	71	78	66	78
Clinical features	Hirsutism Facial plethora	Hirsutism Alopecia Central obesity	Hirsutism Alopecia Increased libido	Hirsutism Alopecia Central obesity
Time of onset to presentation (months)	36	12	8	12
Ferriman-Gallwey score	16	20	18	8

The severity of hirsutism was evaluated by a modified Ferriman-Gallwey score, with patient 4 showing a mild and the rest a moderate to severe hirsutism. A cervical polyp was found during pelvic examination in patient 3. A round and plethoric face was observed in patient 1. Patients 2 and 4 had central obesity with a body mass index of 34.5 and 32.5 kg/m², respectively. No other features of Cushing syndrome, signs of enlargement of clitoris and palpable adnexal masses were observed.

INVESTIGATIONS

Endocrine evaluation revealed increased serum testosterone and normal DHEA-S in all women (table 2). Gonadotropin concentration was within the menopausal range, but oestradiol was slightly elevated for postmenopause. The 17-hydroxyprogesterone (17 OHP) concentration was mildly elevated in patients 1–3. An ACTH stimulation test was performed in these patients with an appropriate 17 OHP response in all.

Cushing's syndrome was reliably ruled out by the finding of normal free urinary cortisol levels (patients 1, 2 and 4) and suppression of morning plasma cortisol concentrations after overnight dexamethasone test—serum cortisol 1.51 µg/dL (patient 2).

Serum tumour marker CA125 was evaluated in patients 1, 2 and 4 and was negative in all of them.

Pelvic ultrasound revealed no abnormal findings in all patients except in patient 2 (table 3). In this woman, a computerised

axial tomography (CT) demonstrated homogeneous masses on both ovaries and no other pathological findings were detected. In patient 1, pelvic CT and MRI were performed, but no ovarian or adrenal abnormalities were found.

TREATMENT

All patients underwent laparoscopic bilateral oophorectomy. A simultaneous hysterectomy and removal of the uterine cervix were also performed in patients 3 and 1, respectively.

Histological results revealed unilateral ovarian Leydig cell tumours (figure 1) in patients 1–3, and a mature ovarian calcified teratoma containing bone tissue but no Leydig cells in patient 4 (figure 2). No histological signs of malignancy were identified.

OUTCOME AND FOLLOW-UP

During follow-up, all patients had an excellent response to surgery with postoperative declines of serum androgens (1–4 months) and significant improvement of signs of hyperandrogenism (6–12 months). In patient 4, although androgen levels had dropped to normal levels 1 month after surgery, hirsutism did not regress until 3 years later.

DISCUSSION

Rapid onset of androgenic symptoms must raise the suspicion of androgen-secreting tumours. There is still a limitation in understanding natural history, management and prognosis of these tumours due to their rarity. Our case series introduces interesting aspects for a better understanding of this kind of neoplasms. First, we report a very rare aetiology for hyperandrogenism, especially a testosterone-producing ovarian mature teratoma, with only few published cases. Second, in all our patients, the tumours were very small and imaging modalities were not able to identify ovarian lesions, demonstrating that the diagnosis can be challenging. In spite of its low incidence, androgen-secreting tumours must be considered in postmenopausal women with signs of virilisation.

Table 2 Biochemical parameters determined before and after surgery

Test (units/reference range)	Result							
	Patient 1		Patient 2		Patient 3		Patient 4	
	Before surgery	After surgery	Before surgery	After surgery	Before surgery	After surgery	Before surgery	After surgery
LH (mIU/mL) (11.3–40.0)	10.8	ND	25.3	ND	57	184	23	ND
FSH (mIU/mL) (9.7–111.0)	43.7	ND	55.8	ND	121	158	79	ND
Total testosterone (ng/mL) (0.04–0.6)	6.4	0.09	1.7	0.08	5.9	0.10	1.43	0.23
Free testosterone (pg/mL) (0.03–1.55)	12.3	0.69	3.9	0.18	10.8	1.27	1.79	0.63
Oestradiol (pg/mL) (<30)	60	ND	35	ND	40	26	30	ND
Androstenedione (ng/mL) (0.3–3.3)	2.26	1.42	2.4	1.01	>10	1.13	2.23	1.07
DHEAS (µg/dL)	204 (9–246)	108 (9–246)	45 (9–246)	42 (9–246)	109 (35–430)	20 (35–430)	20 (35–430)	<15 (35–430)
17 OHP (ng/mL) (0.2–1.7)	2.3	0.51	2.9	0.5	4.2	0.35	1.17	1.01
17 OHP (ng/mL) 60' after ACTH stimulation test	6.2	ND	5.8	ND	6.4	ND	ND	ND

17 OHP, 17 hydroxyprogesterone; ACTH, Adrenocorticotrophic hormone; DHEA-S, dehydroepiandrosterone-sulfate; FSH, follicle-stimulating hormone; LH, luteinizing hormone; ND, not done.

Table 3 Radiological and histological features

	Patient 1	Patient 2	Patient 3	Patient 4
Pelvic ultrasound	No abnormalities	Endometrial thickening; enlargement of both ovaries	No abnormalities	No abnormalities
Pelvic CT	Normal	Homogeneous masses of LO (26 mm) and RO (28 mm)	ND	ND
Pelvic MRI	Polypoid lesion of uterine cervix	ND	ND	ND
Treatment	Bilateral oophorectomy+removal of the uterine cervix	Bilateral oophorectomy	Bilateral oophorectomy+hysterectomy	Bilateral oophorectomy
Histology	Leydig cell tumour RO (17 mm)	Leydig cell tumour LO (10 mm)	Leydig cell tumour RO (15 mm)	Mature teratoma tumour LO (15 mm)

LO, left ovary; ND, not done; RO, right ovary.

After menopause, ovarian causes of virilisation are more common than adrenal ones.⁶

Systematic investigation (hormonal and radiological) is essential to establish the right diagnosis.⁷ The measurement of serum androgens is important to differentiate between ovarian or adrenal source.⁸ Marked elevation of testosterone levels, especially above 200 ng/dL (2 ng/mL), should raise the suspicion of an androgen-producing tumour (adrenal or ovary).³ A normal serum level of DHEA-S typically excludes an adrenal cause, while a value <600 µg/dL makes an adrenal neoplasm the most probable diagnosis.⁹

Ultrasound is generally the initial imaging choice for evaluating ovarian tumours in the presence of hyperandrogenaemia. CT and MRI scanning can also be used for the diagnosis of adnexal or adrenal masses.¹⁰

Similar to other cases reported in the literature, symptoms of hyperandrogenism were the main initial clinical features in our patients. The postmenopausal onset and progressive virilisation had raised suspicion for an androgen-secreting tumour. The hormonal tests suggested an ovarian source, since serum hormone assay showed high levels of testosterone with normal levels of DHEA-S.⁹ Circulating levels of androstenedione and 17 OHP can also be elevated in androgen-secreting neoplasms, because some tumours may predominantly secrete these testosterone precursors.⁹ Morning serum 17 OHP concentration was increased in all patients, except patient 4, who presented a mature teratoma. Increased 17 OHP serum levels may also be suggestive of non-classical congenital adrenal hyperplasia due to 21-hydroxylase deficiency and some cases have been reported in patients with Leydig cell tumours.⁹ Therefore, ACTH stimulation tests (17 OHP measured 1 hour after 250 mg intravenous

synthetic ACTH) were performed in patients 1–3, which excluded this diagnosis. In the presence of clinical features of Cushing's syndrome, a focused investigation should be included in the evaluation of hypercortisolism as a possible cause of virilisation. The occurrence of facial plethora and hypertension in patient 1 and central obesity in patients 2 and 4 raised that suspicion. Twenty-four-hour urinary cortisol and overnight dexamethasone suppression tests were performed, which ruled out this diagnosis.

A Leydig stromal cell tumour is a rare ovarian tumour that belongs to the group of sex-cord stromal tumours and accounts for <0.1% of all ovarian tumours.^{1–3} More than 75% of patients show signs of virilisation, resulting from autonomous androgen secretion. These tumours are usually benign, unilateral, characterised by steroid cell proliferation and located within the ovarian stroma.^{3–9} The small size (usually <3 cm) contributes for the poor visualisation on ultrasound and CT scanning.² This tumour is distinguished from the Sertoli-Leydig cell tumour by the absence of a sex-cord component.

Patients 1–3 were diagnosed with Leydig cell tumours. The absence of radiological signs of ovarian tumours (patients 1 and 3) and a lack of diagnostic concordance between radiology and histology (patient 2) probably reflect the small size of these tumours.

Oestradiol levels were slightly increased in all patients, which were eventually explained by peripheral conversion of androgens to oestrogens through aromatase activity. The endometrial thickening observed in patient 2 could have the same explanation. Although rare, in the literature, these tumours have been associated with a hyperestrogenic state and can present with vaginal bleeding, endometrial hyperplasia and carcinoma.¹

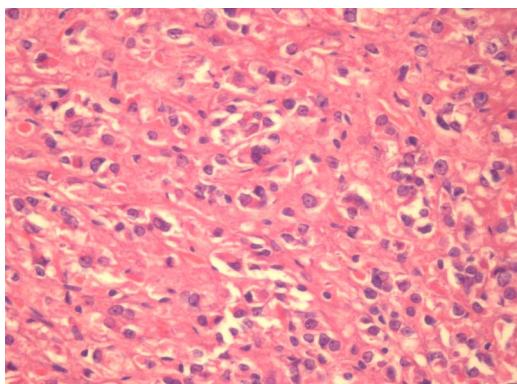


Figure 1 An ovarian Leydig cell tumour (Patient 1). Section shows groups of Leydig cells. H&E, ×100.

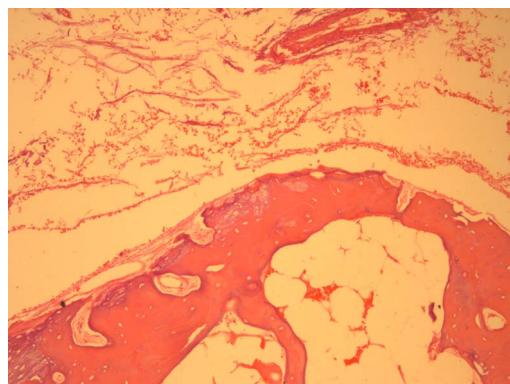


Figure 2 Mature ovarian calcified teratoma containing bone tissue (patient 4). H&E, ×400.

Mature teratomas account for more than 95% of all ovarian teratomas and are almost invariably benign.⁵ Although testosterone-producing mature teratomas with isolated virilisation have been described, they are extremely rare with only few cases published.² The presenting case of patient 4 was diagnosed with mature teratoma with no Leydig cells found on histology examination. However, a normalisation of androgen levels soon after surgery confirmed it was the source of hyperandrogenism. Teratomas can present as a solid or cystic mass and usually have a characteristic ultrasound appearance (areas of fat and calcification), which allow reasonably accurate diagnosis in many cases.⁵ In our patient, the small size and low fat content could explain why the tumour was not detected by image techniques.

According to National Comprehensive Cancer Network (NCCN) guidelines, germ cell and sex-cord stromal tumours are rare ovarian cancer histologies, which can be either benign or malignant, being stage and degree of differentiation their most important prognostic factors.¹¹

Definitive treatment of androgen-secreting ovarian tumours depends on histology subtype, stage of the disease and desiring to preserve the fertility. Once Leydig cell tumours and mature teratoma of the ovary are almost invariably benign, surgery is the first-line treatment suggested in NCCN guidelines and adjuvant therapy is not considered in the majority of these tumours.¹¹ In postmenopausal women, bilateral oophorectomy is the preferred treatment. In younger women whose fertility preservation is an issue and when imaging studies are negative or inconclusive, selective ovarian vein catheterisation should be performed in order to establish the ovarian androgen-secreting source. Given that all our patients were in menopause, bilateral oophorectomy was performed without further presurgical examination.

Histology and postoperative declines in serum androgens provided a definite diagnosis in all patients. Pure Leydig cells are

well-differentiated tumours and to the best of our knowledge, all the reported cases had an excellent prognosis. Although a rare malign transformation can occur in 0.2–2% of patients with mature teratomas, these tumours are usually benign and have a good prognosis, with regression of virilisation after surgery.^{12–13} All our patients had a very good response to surgery with no signs of recurrence after 5 years of follow-up.

CONCLUSION

Androgen-secreting ovarian tumours are extremely rare, but should be considered in all postmenopausal women with signs of hyperandrogenism, even when imaging studies are negative. The diagnosis is usually challenging and surgery is recommended as a diagnostic test and definitive treatment.

Contributors All authors have substantially contributed to the conception and the design of this manuscript. AP has collected all the data, performed the required analysis and drafted the article. AAF, LC and APT performed a critical revision of the article. All authors approved the final version to be published.

Competing interests None declared.

Patient consent Obtained.

Provenance and peer review Not commissioned; externally peer reviewed.

REFERENCES

- 1 Souto SB, Baptista PV, Braga DC, *et al.* Ovarian Leydig cell tumor in a post-menopausal patient with severe hyperandrogenism. *Arq Bras Endocrinol Metab* 2014;58:68–70.
- 2 Shanbhogue AKP, Shanbhogue DKP, Prasad SR, *et al.* Clinical syndromes associated with ovarian neoplasms: a comprehensive review. *Radiographics* 2010;30:903–19.
- 3 Swain J, Sharma S, Prakash V, *et al.* Steroid cell tumor: a rare cause of hirsutism in a female. *Endocrinol Diabetes Metab Case Rep* 2013;2013:130030.
- 4 Freitas ACL, Lima J, Pessoa J, *et al.* Leydig cell tumour of the ovary—a case report. *Revista da Faculdade de Ciências Médicas de Sorocaba* 2014;16:152–4.
- 5 Hoffman JG, Strickland JL, Yin J. Virilizing ovarian dermoid cyst with leydig cells. *J Pediatr Adolesc Gynecol* 2009;22:e39–40.
- 6 Alpañés M, González-Casbas JM, Sánchez J, *et al.* Management of postmenopausal virilization. *J Clin Endocrinol Metab* 2012;97:2584–8.
- 7 Juniarto AZ, Setyawati BA, Ediati A, *et al.* Virilization due to androgen hypersecretion in a patient with ovarian leydig cell tumor: diagnostic and psychosocial implications. *Acta Med Indones* 2013;45:130–5.
- 8 Dolinko AV, Ginsburg ES. Hyperandrogenism in menopause: a case report and literature review. *Fertil Res Pract* 2015;1:7.
- 9 Haji AG, Sharma S, Babu M, *et al.* Androgen secreting steroid cell tumor of the ovary in a young lactating women with acute onset of severe hyperandrogenism: a case report and review of literature. *J Med Case Rep* 2007;1:182.
- 10 Denny MC, Smith D, O'Shea D, *et al.* Investigation of patients with atypical or severe hyperandrogenaemia including androgen-secreting ovarian teratoma. *Eur J Endocrinol* 2010;162:213–20.
- 11 National Comprehensive Cancer Network. Ovarian Cancer (Version 1.2016). https://www.nccn.org/professionals/physician_gls/pdf/ovarian.pdf (accessed 30 Aug 2016)
- 12 Westhoff C, Pike M, Vessey M. Benign ovarian teratomas: a population-based case-control study. *Br J Cancer* 1988;58:93.
- 13 Comerici JT Jr, Licciardi F, Bergh PA, *et al.* Mature cystic teratoma: a clinicopathologic evaluation of 517 cases and review of the literature. *Obstet Gynecol* 1994;84:22.

Learning points

- Rapid onset of androgenic symptoms, especially if associated with signs of virilisation or defeminisation, must raise the suspicion of an androgen-secreting tumour.
- High levels of testosterone with normal levels of the DHEA-S suggest an ovarian source.
- Androgen-secreting neoplasms of the ovary should be considered in all postmenopausal women with signs of hyperandrogenism, even when imaging studies are negative.
- Oophorectomy is recommended as a diagnostic test and definitive treatment.

Copyright 2016 BMJ Publishing Group. All rights reserved. For permission to reuse any of this content visit <http://group.bmj.com/group/rights-licensing/permissions>.
BMJ Case Report Fellows may re-use this article for personal use and teaching without any further permission.

Become a Fellow of BMJ Case Reports today and you can:

- Submit as many cases as you like
- Enjoy fast sympathetic peer review and rapid publication of accepted articles
- Access all the published articles
- Re-use any of the published material for personal use and teaching without further permission

For information on Institutional Fellowships contact consortiasales@bmjgroup.com

Visit casereports.bmj.com for more articles like this and to become a Fellow