J Parasit Dis (July-Sept 2016) 40(3):1091–1093
DOI 10.1007/s12639-014-0631-3

SHORT COMMUNICATION

Concurrent infestation of Notoedres, Sarcoptic and Psoroptic acariosis in rabbit and its management

P. N. Panigrahi · B. N. Mohanty · A. R. Gupta · R. C. Patra · S. Dey

Received: 1 October 2014 / Accepted: 3 December 2014 / Published online: 20 December 2014
© Indian Society for Parasitology 2014

Abstract Acariotic mange in rabbits is one of the important constraints in rabbit husbandry. *Sarcoptes scabies* var. *cuniculi* and *Psoroptes cuniculi* are most common mites prevailed in rabbits, but *Notoedres cati*, is the rarest mite ever been reported in rabbit. Two New Zealand white rabbits were presented with clinical signs of pruritus, alopecia, scab and crust formation and lichenification on the upper lip, ear pinnae, eyelids, lower jaw and limbs. Deep skin scraping was taken separately from 4 to 5 different skin lesions from each rabbit, revealed mixed infestations of *N. cati, S. cuniculi* and *P. cuniculi.* Subcutaneous injection of ivermectin at weekly intervals for four weeks resulted in remission of clinical signs and improvement of health condition in rabbits. This is the first report of *N. cati* infestation of rabbit in Odisha.

Keywords *Notoedres cati* · Rabbit · Ivermectin · Hemato-biochemistry

P. N. Panigrahi (✉) · S. Dey
Division of Veterinary Medicine, Indian Veterinary Research Institute, Izatnagar 243122, Uttar Pradesh, India
e-mail: pnpvetmed@gmail.com

P. N. Panigrahi · A. R. Gupta · R. C. Patra
Department of Veterinary Medicine, College of Veterinary Science and Animal Husbandry, Orissa University of Agriculture and Technology, Bhubaneswar 751 003, Odisha, India

B. N. Mohanty
Department of Parasitology, College of Veterinary Science and Animal Husbandry, Orissa University of Agriculture and Technology, Bhubaneswar 751 003, Odisha, India

Introduction

Mite infestation is one of the most common and major constraint in both pet and commercial rabbit population in India (Darzi et al. 2007; Panigahi and Gupta 2013). *Sarcoptes scabies* var. *cuniculi* and *Psoroptes cuniculi,* the burrowing and non-burrowing mites respectively, are most common mites prevailed in rabbits (Singh Singla Singla Aulakh 2003; Saha and Mukherjee 1998), but *Notoedres cati*, is the rarest mite ever been reported in rabbit (Darzi et al. 2007). Being a contagious parasitic skin disease, mites are generally spread from rabbit to rabbit by direct skin contact between infected and non-infected rabbits or through contact with the environment. *Psoroptes infestation* is characterized by extreme crusting, formation of scales and scab and itchiness of the external ear canal and pinnae, but the same clinical signs can be seen in lips, nose, neck, legs and sometimes around genitalia in case of *Sarcoptes* and *Notoedres* infestations. Various acaricides have been used to control the disease of which ivermectin given orally or by injection has been reported to be effective in treatment of acariosis (Singh Singla Singla Aulakh 2003; Eraslan et al. 2010). The present study describes the degree of parasitemia in two mite infested rabbits, along with their successful therapeutic management with subcutaneous administration of ivermectin.

Case history and observations

Two New Zealand white rabbits were presented to Teaching Veterinary Clinical Complex with history of inappetance, itching, alopecia and rough hair coat. Physical examination revealed dullness and depression with presence of diffused erythema, crust, scale and scab formation

in lips, nose, ear pinna and inter-digital space and patchy alopecia over face, around eyes and margin of ear pinna (Fig. 1). Both deep and superficial skin scrapings scraping was taken separately from 4 to 5 different skin lesions for detection of mites and for fungal culture (Miller and Michael 1999), respectively.

Blood sample was collected on day 0 (before treatment) and day 28 (after treatment), from the marginal ear vein in two separate vials i.e. one with disodium EDTA as anti-coagulant for conducting the haematological parameters and other vial without anticoagulant for harvesting serum to perform biochemical assay (Ozkan et al. 2012). Haematology was done by haematological auto analyser and biochemical analysis by semi auto analyser (Merck) using commercial reagent kits as per manufacturer's instruction.

Result

The deep skin scraping revealed severe infestation of *Sarcoptes scabies var cuniculi*, *Psoroptes cuniculi* and *Notoedres cati* mites in both the rabbits (Figs. 2, 3). There was absence of any fungal mycelli in superficial scraping in culture media.

The average haematological parameters (Table 1) and biochemical parameters (Table 2) did not revealed any significant change before and after treatment and were within normal range except the average Eosinophil percentage is little higher than untreated rabbits.

On the basis of skin scraping examination and clinical signs these cases were diagnosed as mixed infestations of *Sarcoptes, Psoroptes* and *Notoedres* mites.

Fig. 1 Rabbits having skin lesion presented to TVCC

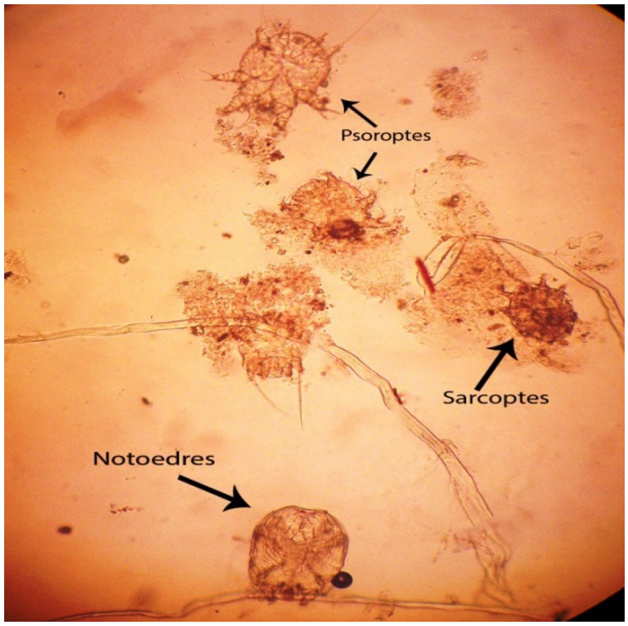

Fig. 2 Skin scrapping showing mixed infestation of *Sarcoptes, Psoroptes* and *Notoedres* mite

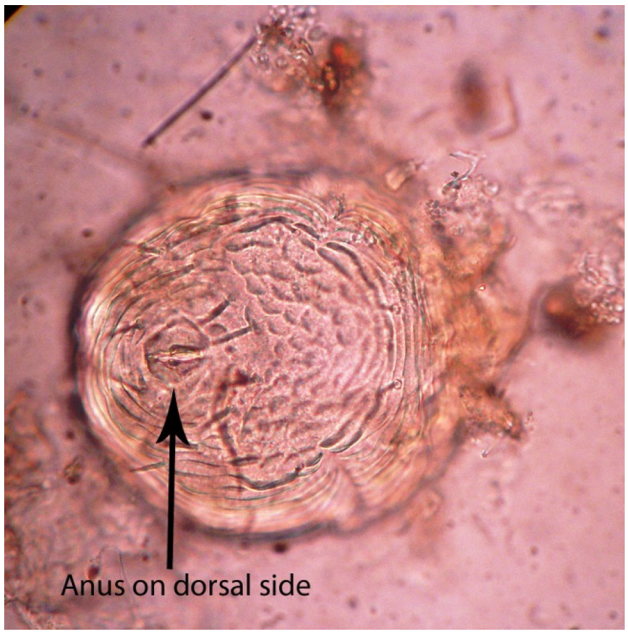

Fig. 3 Skin scrapping showing *Notoedres cati mite*

Treatment and discussion

The rabbits were treated with ivermectin @ 400 µg/kg body weight, subcutaneously at weekly intervals for four weeks. Zincovit* was administered orally as five drops per animal twice daily. The therapy was assessed 2 weeks after the start of the treatment and thereafter fortnightly. No adverse reactions were recorded at any stage of the treatment.

Table 1 Average haematological parameters in rabbits before and after treatment

Parameters	Before treatment (day 0)	After treatment (day 28)
Hb (%)	10.8	11.6
TLC (10^3/mm^3)	7.2	6.8
TEC (10^6/mm^3)	5.2	5.4
PCV (%)	32.4	34.8
MCV (fl)	45	51.4
MCH (pg)	15	17.2
MCHC (g/dl)	33.2	33.6
N (%)	64	62
E (%)	5	2
L (%)	28	34
B (%)	–	–
M (%)	3	2

Table 2 Average serum biochemical parameters before and after treatment

Parameters	Before treatment (day 0)	After treatment (day 28)
ALT (U/L)	11.8	8.2
AST (U/L)	24	18.6
BUN(mmol/L)	17.7	15.3
Creatnine(mmol/L)	1.2	0.9
Total Protein (g/L)	68.4	69.2

The epidemiological study sighted that *Sarcoptes scabies var cuniculi* is mostly found in Indian rabbits, *Psoroptes cuniculi* infestation is also not uncommon, but infestation of *Notoedres cati* is very rare (Darzi et al. 2007; Ravindran and Subramanian 2000). *Sarcoptes* and *Notoedres* are burrowing fur mites; produce their pathogenic effects by burrowing activity and mechanical damage caused by the parasites during excavation, irritant action of their secretions and excretions, allergic reactions to some of their extracellular products and especially the release of IL-1 (Henry 1996; Wall and Shearer 1997). On the other hand *Psoroptes cuniculi,* the non burrowing ear mites, does not burrow into the epidermis but pierce their mouth parts into the skin to feed upon the lymphatic fluid and their excretory and secretary products produce inflammatory reaction resulting in clinical signs.

In the present study, demonstration of mites with microscopic examination along with characteristic skin lesions in most of the body parts confirms the mixed acariotic mange in rabbits. Ivermectin given subcutaneously at a dose of 400 µg/kg selectively binds to glutamate-gated and gamma-aminobutyric acid (GABA) gated chloride channels in the nervous system of mites, resulting in hyperpolarization of cell, paralysis and finally death of mites, which was in accordance with Singh Singla Singla Aulakh (2003) and Quesenberry and Carpenter (2004).

Summary

In the present case, deep skin scraping was taken from 4 to 5 different skin regions of the affected rabbit's revealed concurrent infestation of Sarcoptes, Psoroptes and Notoedres acarosis. After 2 week post treatment with ivermectin, there were absence of mites in the skin scraping examination. At the same time, general condition improved and skin lesions resolved, and clinical signs of pruritus disappeared. Lesions due to scratching rapidly resolved over the whole body surface including face, resulting in hair growth and resolution of alopecic areas, suggesting that subcutaneous administration of Ivermectin is effective in mixed mange infestation in rabbit.

References

Darzi MM, Mir MS, Shahardar RA, Pandit BA (2007) Clinicopathological, histochemical and therapeutic studies on concurrent sarcoptic and notoedric acariosis in rabbits (*Oryctolagus cuniculus*). Vet Arhiv 77(2):167–175

Eraslan G, Kanbur M, Liman BC, Cam Y, Karabacak M, Altınordulu S (2010) Comparative pharmacokinetics of some injectable preparations containing ivermectin in dogs. Food Chem Toxicol 48:2181–2185

Henry JB (1996) Clinical diagnosis and management by laboratory methods, 9th edn. WB Saunders Company, Philadelphia

Miller J, Michael A (1999) Guide to specimen management in clinical microbiology, 2nd edn. ASM Press, Washington, pp 123–124

Ozkan C, Kaya A, Akgul Y (2012) Normal values of haematological and some biochemical parameters in serum and urine of New Zealand white rabbits. World Rabbit Sci 20:253–259

Panigahi PN, Gupta AR (2013) Therapeutic management of concurrent Sarcoptic and Psoroptic acariosis in Rabbits. Intas Polivet 14(2):319–321

Quesenberry K, Carpenter J (2004) Ferrets, rabbits, and rodents clinical medicine and surgery, 2nd edn. Elsevier, St.Louis

Ravindran R, Subramanian H (2000) Effect of seasonal and climatic variations on the prevalence of mite infestation in rabbits. Indian Vet J 77:991–992

Saha SB, Mukherjee S (1998) Sarcoptic mange in domestic rabbits. Indian J Anim Hlth 37:73

Singh N, Singla S, Singla LD, Aulakh GS (2003) Pathology and therapy of natural notoedric acariosis in rabbits. J Vet Parasitol 17:127–129

Wall R, Shearer D (1997) Veterinary Entomology, 1st edn. Chapman and Hall, London