Osteopetrosis

Wg Cdr V Venkateshwar[*], Wg Cdr Ashima Vaidya[+], Lt Col Partho Roy[#], Sqn Ldr Sangeeta Sampat[**], Air Vice Marshal JK De, VSM [++]

MJAFI 2003; 59 : 344-346

Introduction

Osteopetrosis, also known as marble bone disease belongs to a group of disorders in children associated with increase in skeletal density. The other such disorders are pyknodysostosis, dysosteosclerosis and cortical hyperostosis. Mode of inheritance, age of onset and pattern of skeletal involvement distinguish these conditions. Osteopetrosis is caused by defect in bone resorption by osteoclasts leading to hyperostosis. At least 9 types of Osteopetrosis have been described, with variations in clinical and radiological features [1]. The autosomal dominant form is usually asymptomatic and diagnosed incidentally in late childhood/adulthood. We report a case of osteopetrosis manifesting in early infancy, also known as malignant osteopetrosis, autosomal recessive osteopetrosis or osteopetrosis with precocious manifestations.

Case Report

A seven month old male infant, son of an ex-serviceman hailing from Assam, presented with history of failure to thrive, delayed developmental milestones and recurrent upper respiratory tract infections since early infancy. When he presented to this hospital for the first time he had an episode of upper respiratory tract infection (URTI).

The infant was born full term by normal vaginal delivery at home. Birth weight was not recorded. There was no known antenatal illness in mother. There were no immediate postnatal complications and breast feeding was established. At 2 months of age, he was noted to have lack of visual fixation. Social smile had also not developed. From 3 months of age he had frequent episodes of fever, nasal discharge and breathing difficulty and was treated for the same in the village by a private practitioner. At about 5 months, he stopped breast-feeding and was on cup and spoon feeds, swallowing of which was difficult and prolonged. Parents noted that motor milestones like head holding and rolling over from supine to prone had not developed. Paucity of movements of limbs and generalized stiffness were noticed. There was no response to sound/calling out name. The infant was a product of non-consanguinous marriage and elder siblings aged 10 years and 7 years respectively were healthy. There was no family history of neurological illness.

At admission the infant weighed 4.75 kg (expected 6.2-8.6 kg). Head circumference was 39.5 cm. Marked nasal catarrh was present. He had respiratory distress, high fever and bilateral crepitations in chest. X-ray chest showed non-homogenous opacities in right lung, confirming a clinical diagnosis of aspiration pneumonia. Mild pallor was present. No dysmorphic features or neurocutaneous markers were present. Neurological examination revealed an infant with a vacant stare who was not following light/objects, not recognizing mother's voice and not responding to rattle/bell. Ocular fundi showed early optic atrophy. There were features of pseudobulbar palsy such as nasal regurgitation of feeds and weak cry. Motor system examination showed spastic quadriparesis. Intermittent tonic extensor spasms were present on handling, feeding, coughing etc. Cardio-vascular examination was normal. On abdominal examination, spleen was palpable 6 cm, firm, non-tender and liver was palpable 4 cm, firm, non tender.

Investigations revealed : Hb 11.5 gm%, TLC 18000/cu mm, platelet count 120000/cu mm. Peripheral blood smear showed normocytic normochromic anaemia with shift to left in both RBC series and WBC series. RBCs showed 3-4 late normoblasts per 100 WBCs. Leucocytosis was seen with shift to left in the form of myelocytes, metamyleocytes and band forms. Blood sugar, liver function tests, urea, creatinine, sodium and potassium were within normal limits. Serum calcium was 8.2 mg%. Blood culture was sterile. HIV spot test was negative. Radiographs of limbs showed generalized increase in bone density and 'bone within bone' appearance (Fig 1). Radiograph of spine showed 'rugger jersey' appearance (Fig 2). Radiographs of skull showed sclerosis and thickening of orbital rims (Fig 3) and anterior cranial fossa. Sella was small. Ultrasonography abdomen showed hepatosplenomegaly with no other abnormality. Ultrasonography skull showed no evidence of intracranial calcification or hydrocephalus.

The infant was treated with antibiotics for aspiration pneumonia and recovered. Repeat peripheral blood smear after treatment of infection showed persistence of shift to left in both RBC series and WBC series corresponding to a picture of myelophthisic anaemia. Attempts at bone marrow aspiration yielded only scanty marrow. Parents refused bone marrow biopsy. Based on the clinical presentation, classical radiological findings and haematological picture a diagnosis

[*]Classified Specialist (Paediatrics),5 Air Force Hospital, C/o 99 APO, [+]Classified Specialist (Paediatrics),7 Air Force Hospital, Kanpur, [#]Graded Specialist (Pathology), Eastern Command Transfusion Centre, Calcutta, [**]Reader, Department of Biochemistry, Armed Forces Medical College, Pune - 411 040, [++]PMO, Head Quarter, Western Air Command, Subroto Park, New Delhi- 110 010.

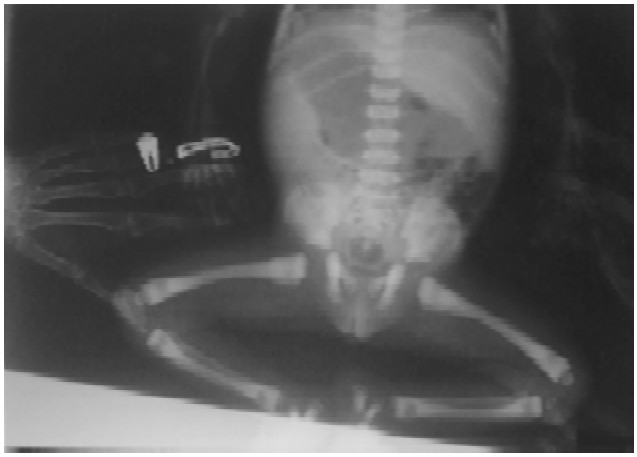

Fig. 1 : Radiograph of lower limbs and pelvis showing generalised increase in bone density and 'bone within bone' appearance

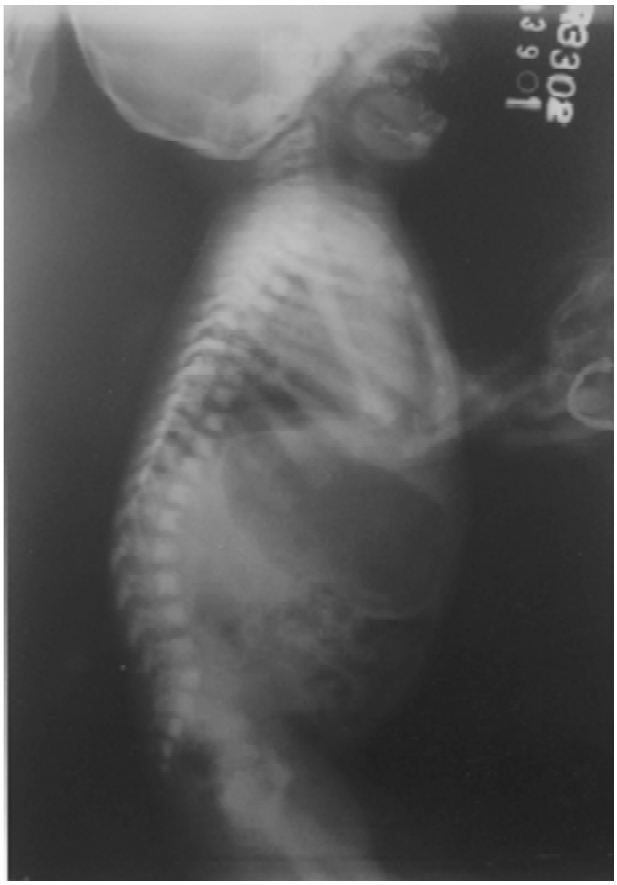

Fig. 2 : Radiograph of spine (lateral view) showing 'rugger jersey' appearance.

of osteopetrosis was arrived at. In view of early age of onset and severity of symptoms and signs, malignant recessive osteopetrosis was the most likely diagnosis.

Discussion

Malignant recessive osteopetrosis or osteopetrosis with precocious manifestations is a rare disorder occurring with an incidence of 1:200000 population [2]. It is an autosomal recessive condition presenting in neonatal period or early infancy. Its various

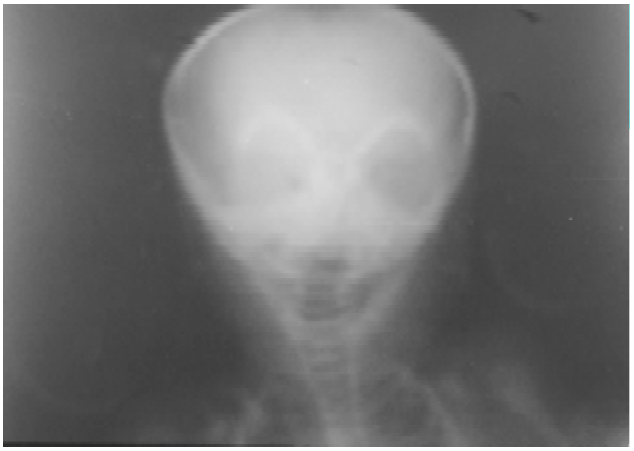

Fig. 3 : Radiograph of skull (AP view) showing sclerosis and thickening of orbital rims

manifestations are a result of hyperostosis. The initial presentation of these patients may be with pallor, failure to thrive, nasal obstruction or visual impairment. Lorea Cortes et al found nasal obstruction as an early symptom in their series of 26 patients over a period of 10 years [3], whereas Gerritsen EJ et al reported ocular manifestations as an early symptom in their series of 33 patients over 16 years [4]. Our patient was brought with symptoms of nasal obstruction aggravated by recurrent upper respiratory infection. He was also noted to have impaired vision.

Haematological findings are due to obliteration of bone marrow cavity by bone, causing myelophthisic anaemia, which manifests as a leukoerythroblastic picture on peripheral blood smear (neutrophilia, immature granulocytes, nucleated RBCs). Hepatosplenomegaly is due to extra medullary haematopoiesis. Thrombocytopenia, leukopenia and haemolytic anaemia may occur due to hypersplenism [5]. In our case, haemoglobin level was relatively preserved as a result of compensatory haematopoiesis. However, many patients of malignant recessive osteopetrosis become transfusion dependant [6].

The radiological findings are increase in bone density with defective metaphyseal remodelling. A ‘bone within bone’ appearance is characteristic and diagnostic and was seen in the above case. The finding differentiates osteopetrosis from other sclerosing dysplasias. This is due to the cyclical nature of the disease, so that the dense shadow of bone at the time of formation of abnormal bone is seen within the outline of the current normal or abnormal shadow. Irregular condensation of bone at metaphysis may produce parallel plates of dense bone at the end of long bones, a finding that is normally seen in older children. Base of skull is dense, with or without involvement of vault and sella is small. Orbital margins are markedly increased in density. Sphenoid, mastoid and frontal sinuses are under or non-

pneumatised [7].

Visual impairment is seen due to bony encroachment on optic foramina. It is a common initial symptom as reported by Gerritsen et al [4]. Optic atrophy is present in a significant number of cases. In the series reported by Phadke et al [8], optic atrophy was present in 3 out of 6 cases. Visual impairment is responsible for lack of acquisition of certain early development milestones like social smile, as seen in our case. Early visual impairment in combination with haematological impairment is associated with a poor outcome [4]. Hearing impairment may be due to bony encroachment on auditory nerve, sclerosis of middle ear ossicles and/or middle ear effusion [6]. Various other cranial nerve palsies can similarly be present due to bony encroachment on foramina [6]. Our patient had clinical evidence of hearing impairment.

Spastic quadriparesis and pseudobulbar palsy were present in our case. This may be due to associated neurodegenerative disorder, which has been reported to occur in osteopetrosis [6]. Other neurological manifestations described in osteopetrosis are macrocephaly, seizures, hydrocephalus, psychomotor retardation and strabismus [3].

Hypocalcemia, low serum phosphorous levels and elevated serum alkaline phosphatase levels are known to occur in osteopetrosis [1] Serum calcium was marginally lower in our case. In the series of cases reported by Phadke et al, serum calcium levels were normal [8]. Hypocalcemia is related to decrease in osteoclastic activity and can be the cause of seizures occasionally.

Infants with malignant osteopetrosis also suffer from recurrent infections as a result of defect in macrophage function [1]. Chronic anaemia, recurrent infections, feeding problems due to bulbar nerve involvement and nasal congestion lead to failure to thrive in these children. Fractures are common and one of the classical features of osteopetrosis. They are usually transverse and heal with normal callus. They occur after moderate trauma and are thus rare in infancy. Skeletal maturation is normal.

The course of illness in autosomal recessive osteopetrosis is progressive and these children do not survive long. Survival at 6 years is about 30% [4]. The cause of death is usually severe anaemia, bleeding or overwhelming infection. Mortality is higher in first two years of life. Children who are not transfusion dependent and alive at 2 years have a relatively favourable prognosis.

The definitive treatment is bone marrow transplantation. Recipients of HLA identical bone marrow transplant have 79% 5-year survival [9]. Supportive treatment includes treatment of anaemia, thrombocytopenia and infections. Prednisolone may arrest progress of anaemia and thrombocytopenia. Oral cellulose phosphate, low calcium diet, recombinant human interferon gamma may also be beneficial [1]. Neurosurgical unroofing of optic foramina has been tried.

Genetically, recessive osteopetrosis is a heterogenous disease and a number of genetic loci are likely. Recently mutations in the gene coding for an osteoclast specific vacuolar pump have been found in a subset of affected children. The near future will see other genes being mapped, cloned and mutational analysis hopefully made available [6]. Appropriate genetic counselling could then be offered,

References

1. Hall BD. Genetic skeletal dysplasia (Osteopetrosis, Pyknodysostosis, dysosteoscelerosis and cortical hyperostosis). In : Richard E Behrman, Robert M Kleigman, AnnM Arvin, editors, Nelson Textbook of Paediatrics. 15th ed. Prism Books. WB Saunders, Philadelphia 1996;1980-1.
2. Johnson CC, Lavy N, Lord T, Vellios G, Merritt AD, Deiss WP. Osteopetrosis : A clinical, genetic, metabolic, morphological study of the dominantly inherited benign form. Medicine 1968;47:149-67.
3. Loria Cortes R, Quesada-Calvo E, Cordero-Chavveri C. Osteopetrosis in children : A report of 26 cases. J Paediatrics 1977;91:37-43.
4. Gerritsen EJA, Vossen JM, Van Loo IHG, Hermans J, Helfrich MH, Griscelli C. Autosomal recessive osteopetrosis. Variability of findings at diagnosis and during the natural course. Paediatrics 1994;93:247-53.
5. Alter BP, Young NS. Bone marrow failure syndromes. In:Nathan DG, Oski FA, editors. Haematology of infancy and childhood. 4th ed. Pennsylvania, WB Saunders Co 1993;216-316.
6. Wilson CJ, Vellodi A. Autosomal recessive osteopetrosis : diagnosis, management and outcome. Arch Dis Child 2000;83:449-52.
7. Jacobs P, Renton P. Congenital skeletal anomalies : Skeletal dysplasias : chromosomal disorders. In : David Sutton, editor. A textbook of radiology and imaging. 4th ed, Churchill Livingstone 1987;22-3.
8. Phadke SR, Gupta A, Pahi J, Pandey A, Gautam P, Agarwal SS. Malignant recessive osteopetrosis. Indian Paediatr 1999;36:69-74.
9. Gerritsen EJA, Vossen JM, Fasth A, Freiedrich W, Morgan G, Padmos A. Bone marrow transplantation for osteopetrosis. A report from the Working Party on Inborn Errors of the European Bone Marrow Transplantation Group. J Pediatr 1994;125:896-902.