



Published in final edited form as:

J Cataract Refract Surg. 2015 August ; 41(8): 1784–1786. doi:10.1016/j.jcrs.2015.07.001.

Structural Changes of the Anterior Chamber Following Cataract Surgery during Infancy

Matthew Nguyen, M.D.^{1,2}, Marla Shainberg, C.O.¹, Allen D. Beck, M.D.¹, and Scott R. Lambert, M.D.¹

¹Department of Ophthalmology, School of Medicine, Emory University, Atlanta, GA

²Department of Ophthalmology, Weill Cornell Medical College, New York, NY

INTRODUCTION

Anterior segment optical coherence tomography (OCT) has been shown to provide images comparable to biomicroscopy. It has the advantage over gonioscopy and biomicroscopy of being non-contact. While it has been used to image the anterior segment of adult eyes after cataract surgery,^{1,2} we are unaware of any studies that have used OCT to examine the anterior segment of children after cataract surgery. In this study we used anterior segment OCT to image the anterior angle of the eyes of children who underwent cataract surgery during infancy.

METHODS

This study was approved by the Institutional Review Board of Emory University School of Medicine and was in compliance with the Health Insurance Portability and Accountability Act. The off-label research use of the Acrysof SN60AT and MA60AC IOLs (Alcon Laboratories, Fort Worth, Texas) was covered by US Food and Drug Administration investigational device exemption # G020021. Patients who had undergone unilateral cataract extraction with or without primary intraocular lens placement when <7 months of age were invited to participate in the study when they returned for their routine eye care between the ages of 6 and 12 years. In addition, patients who had previously been enrolled in the Infant Aphakia Treatment Study who were being followed at the Emory Eye Center were invited to participate in the study.

A complete ophthalmologic examination was performed including an assessment of Snellen visual acuity, intraocular pressure, biomicroscopy, and indirect ophthalmoscopy. Axial length was measured using an IOLMaster (Carl Zeiss Meditec, Germany). The SPECTRALIS OCT (Heidelberg, Germany) anterior segment module and software package was used to measure the angle opening distance (AOD) and anterior chamber angle (ACA), as seen in Figure 1. The angle opening distance was measured by drawing a perpendicular line from the cornea to the iris 500um from the scleral spur using the Spectralis anterior

segment software package. The anterior chamber angle, the angle between the corneal and iris vectors used to calculate the angle opening distance, was calculated by the software package. In some cases, only one angle could be visualized well enough to perform the calculations. When both nasal and temporal angles could be visualized, the two measurements were averaged and the mean measurement was used.

RESULTS

Seven children were assessed with anterior segment OCT. They had undergone unilateral cataract surgery at a mean age of 2.2 (range, 0.9 to 4.2) months. Of the seven treated eyes, five were aphakic and two were pseudophakic. Patients were examined at a mean age of 9.2 (range, 6.6 to 12.5) years. No eyes had glaucoma. The mean IOP was 17 ± 5 mmHg (range, 8 – 22) in treated eyes and 16 ± 4 mmHg (range, 11 – 21) in fellow eyes.

Mean angle opening distance was greater in treated eyes (830 ± 205 μ m) than in fellow eyes (775 ± 108 μ m)(Figures 1a, 1b). Mean angle opening distance was greater in pseudophakic eyes (861 ± 25 μ m) compared to aphakic eyes (817 ± 249 μ m).

Mean anterior chamber angle was greater in treated eyes ($39 \pm 6^\circ$) than in fellow eyes ($36 \pm 4^\circ$)(Figure 1a, 1b). Mean anterior chamber angle was greater in pseudophakic eyes ($42 \pm 1^\circ$) compared to aphakic eyes ($38 \pm 7^\circ$).

The mean axial length of the treated eyes (21.39 ± 2.09 mm) was shorter than their fellow eyes (22.62 ± 1.75 mm). The mean axial length of pseudophakic eyes was 23.78 ± 1.21 mm compared to 20.44 ± 1.48 mm for aphakic eyes.

DISCUSSION

Our study demonstrates the feasibility of using anterior segment OCT to assess structural changes in the anterior chamber of pediatric eyes after infantile cataract surgery. We found the angle opening distance was greater in pseudophakic than aphakic eyes. We also found that treated eyes had increased mean angle opening distances and anterior chamber angles compared to fellow untreated eyes. Leung and coworkers³ found high reproducibility of Heidelberg anterior segment OCT measurements and agreement with gonioscopy findings. Anterior OCT has also been used to assess anterior chamber characteristics in children with ROP and corneal opacities.^{4, 5} Limitations of our study include a small sample size and some variation in patient age at the time of assessment.

Acknowledgments

Supported by National Institutes of Health Grants U10 EY13272 and U10 EY013287 and in part by NIH Departmental Core Grant EY006360 and Research to Prevent Blindness, Inc, New York, New York

References

1. Nolan W, See J, Aung T, et al. Changes in angle configuration after phacoemulsification measured by anterior segment optical coherence tomography. *J Glaucoma*. 2008; 17(6):455–459. [PubMed: 18794679]

2. Dawczynski J, Koenigsdoerffer E, Augsten R, Strobel J. Anterior segment optical coherence tomography for evaluation of changes in anterior chamber angle and depth after intraocular lens implantation in eyes with glaucoma. *Eur J Ophthalmol.* 2007; 17(3):363–367. [PubMed: 17534817]
3. Leung C, Li H, Weinreb R, et al. Anterior chamber angle measurement with anterior segment optical coherence tomography: a comparison between slit lamp OCT and Visante OCT. *Invest Ophthalmol Vis Sci.* 2008; 49(8):3469–3474. [PubMed: 18408181]
4. Cernichiaro-Espinosa L, Garcia-Huerta M, Giordano V, et al. Comparison of iridocorneal angle in infants with retinopathy of prematurity and healthy infants using spectral domain optical coherence tomography. *J AAPOS.* 2014; 18(4):344–346. [PubMed: 25173896]
5. Majander A, Lindahl P, Vasara L, Krootila K. Anterior segment optical coherence tomography in congenital corneal opacities. *Ophthalmology.* 2012; 119(12):2450–2457. [PubMed: 22959105]

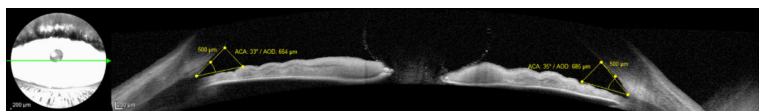


Figure 1a.
Anterior segment OCT images from an aphakic eye showing the built in measuring software for the angle opening distance (AOD) and the anterior chamber angle (ACA).

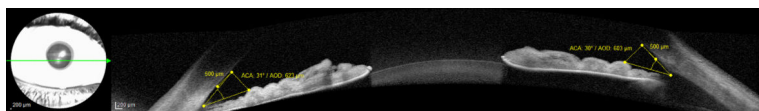


Figure 1b.
Anterior segment OCT images for the fellow eye.