

Reversible cerebral vasoconstriction syndrome (RCVS): a transient condition being underdiagnosed?

Alexander F Nath,¹ Avinash Kumar Kanodia,¹ Priya Nair,² Prasad Guntur Ramkumar¹

¹Department of Radiology, Ninewells Hospital, Dundee, UK

²Ninewells Hospital, Dundee, UK

Correspondence to

Dr Avinash Kumar Kanodia, avinash.kanodia@nhs.net

Accepted 21 February 2016

DESCRIPTION

A 68-year-old woman was admitted with a 6-day history of sudden onset, throbbing headache associated with transient visual disturbance. On examination, she exhibited right facial numbness and right arm heaviness. Her blood pressure was 207/88 mm Hg. Of note, she had a history of migraines and was taking sumatriptan. She was treated with antihypertensives and her symptoms improved. Initial brain CT was unremarkable. No angiogram was performed at the time.

She further presented 12 days later with another episode of severe headache. Brain CT performed at

the time demonstrated a focus of low attenuation in the left occipital lobe (figure 1A). No evidence of subarachnoid haemorrhage (SAH) was present. She subsequently had a brain MRI with MR angiogram (MRA). MRI confirmed left occipital subacute infarct (figure 1B). On MRA, there was definite focal narrowing of the left posterior cerebral artery (PCA) (figure 2A, B), although there was some further doubtful vascular narrowing present. The PCA narrowing was present at a non-branch point and thought to represent either vasculitis or vasospasm. The patient was treated with calcium channel blockers (CCB). She underwent follow-up MRI and MRA after 6 weeks, which demonstrated that the left PCA narrowing had resolved (figure 2C, D), while no new findings were present. A diagnosis of reversible cerebral vasoconstriction syndrome (RCVS) was made.

During this admission the patient underwent a lumbar puncture (LP), which was normal. Her platelet count was noted to be raised at $826 \times 10^9/L$ and she was found to be JAK-2 positive. Following review with the haematology team, she is now being treated for essential thrombocythaemia with hydroxycarbamide and clopidogrel.

At discharge, her symptoms resolved except for a minor right visual field deficit.

RCVS is a well-described entity that results in areas of vasospasm in one or more intracranial

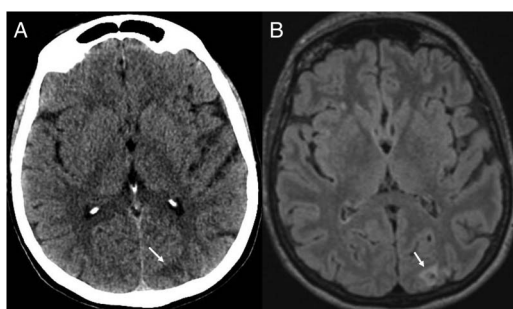


Figure 1 Non-contrast CT (A) and MRI fluid-attenuated inversion recovery (B) showing an infarct in left occipital lobe (white arrow).

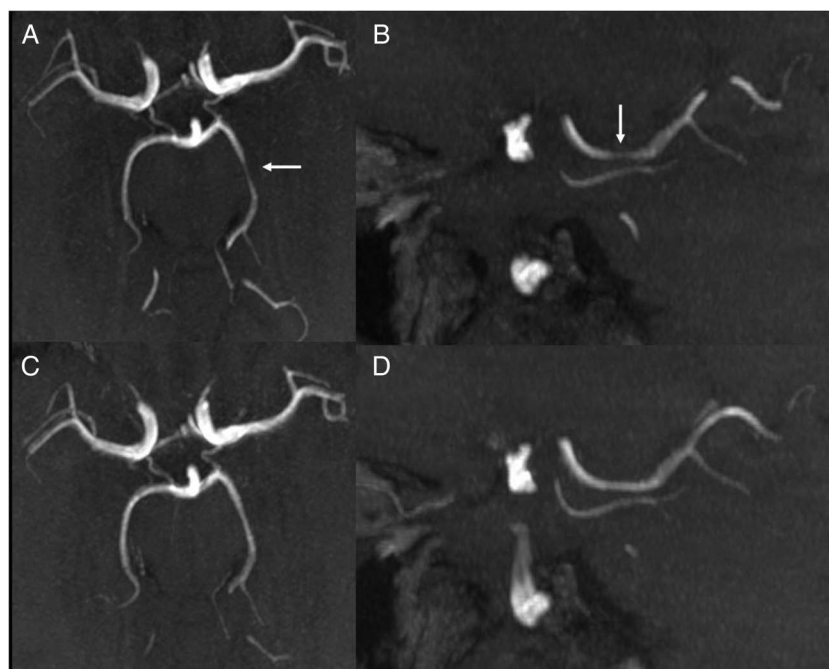


Figure 2 Initial CT angiogram ((A) axial, (B) sagittal) showing focal narrowing of left posterior cerebral artery (white arrow). Subsequent CT angiogram 6 weeks later ((C) axial and (D) sagittal) showing that changes have resolved.



CrossMark

To cite: Nath AF, Kanodia AK, Nair P, et al. *BMJ Case Rep* Published online: [please include Day Month Year] doi:10.1136/bcr-2016-214641

arteries, which usually resolve spontaneously.^{1 2} There are a range of causes described, including idiopathic causes, such as migraine due to certain drugs such as sumatriptan, which this patient was also taking. RCVS is an important differential in patients with sudden severe headaches, typically thunderclap headaches. Usually, such patients are primarily investigated for SAH and sinus thrombosis, after exclusion of which they tend to be treated conservatively.^{1 2} Some of these patients can develop complications such as infarcts or haemorrhage; these can happen even if headaches improve on symptomatic treatment. RCVS is specifically treated with CCB. Cerebral angiograms (CT/MR/digital subtraction angiography) if performed, can pick up several such patients and result in appropriate treatment, potentially preventing complications. It is important that more such patients have angiograms, even if SAH has been excluded, to reach the correct diagnosis. The usual differential on angiograms is vasculitis, with the usual helpful differentiating criteria being the reversible nature of RCVS on follow-up. The current case has been presented to emphasise that it is important to consider angiograms in more patients presenting with sudden onset headaches, even when SAH has been excluded, as they can potentially be treated appropriately, possibly preventing complications.

Learning points

- ▶ Reversible cerebral vasoconstriction syndrome (RCVS) is a recognised but infrequently made diagnosis in patients presenting with sudden severe headache.
- ▶ RCVS can be diagnosed if angiogram (CT/MR/digital subtraction angiography) is performed during the course of investigations.
- ▶ With suitable early treatment of RCVS, it is likely that some of the complications such as infarcts could be prevented.

Competing interests None declared.

Patient consent Obtained.

Provenance and peer review Not commissioned; externally peer reviewed.

REFERENCES

- 1 Sattar A, Manousakis G, Jansen MB. Systematic review of reversible cerebral vasoconstriction syndrome. *Expert Rev Cardiovasc Ther* 2010;8:1417–21.
- 2 Katz BS, Fugate JE, Ameriso SF, et al. Clinical worsening in reversible cerebral vasoconstriction syndrome. *JAMA Neurol* 2014;71:68–73.

Copyright 2016 BMJ Publishing Group. All rights reserved. For permission to reuse any of this content visit <http://group.bmj.com/group/rights-licensing/permissions>.
BMJ Case Report Fellows may re-use this article for personal use and teaching without any further permission.

Become a Fellow of BMJ Case Reports today and you can:

- ▶ Submit as many cases as you like
- ▶ Enjoy fast sympathetic peer review and rapid publication of accepted articles
- ▶ Access all the published articles
- ▶ Re-use any of the published material for personal use and teaching without further permission

For information on Institutional Fellowships contact consortiasales@bmjgroup.com

Visit casereports.bmj.com for more articles like this and to become a Fellow