Author Manuscript

Author Manuscript

Author Manuscript

Author Manuscript

HHS Public Access

Author manuscript

Arthritis Care Res (Hoboken). Author manuscript; available in PMC 2017 February 01.

Published in final edited form as:

Arthritis Care Res (Hoboken). 2016 February ; 68(2): 187–194. doi:10.1002/acr.22665.

Sacroiliitis at diagnosis of juvenile spondyloarthritis assessed by radiography, magnetic resonance imaging, and clinical examination

Pamela F Weiss, MD MSCE,

Division of Rheumatology, Department of Pediatrics, Center for Pediatric Clinical Effectiveness, Children's Hospital of Philadelphia, Philadelphia, PA

Rui Xiao, PhD,

Department of Biostatistics, Children's Hospital of Philadelphia and Department of Biostatistics and Epidemiology, Perelman School of Medicine, University of Pennsylvania, Philadelphia, PA

David M Biko, MD, and

Department of Radiology, Children's Hospital of Philadelphia, Philadelphia, PA

Nancy A Chauvin, MD

Department of Radiology, Children's Hospital of Philadelphia, Philadelphia, PA

Abstract

Objective—We evaluated the prevalence of sacroiliitis at diagnosis of juvenile spondyloarthritis (JSpA) and the accuracy of physical examination and back pain to detect sacroiliitis, using imaging as the reference standard.

Methods—We performed a prospective cross-sectional study of 40 children with newly diagnosed JSpA and 14 healthy controls. Subjects were assessed using physical examination, anteroposterior pelvic radiograph, and pelvic MRI. Differences in clinical features between those children with and without sacroiliitis were assessed by Fisher's exact test for categorical variables and Wilcoxon rank sum test for continuous variables. Accuracy of physical examination and back pain for detection of sacroiliitis was determined using MRI as the reference standard. Predicted probability of sacroiliitis was determined using exact multivariate logistic regression.

Results—Eight (20%) children with JSpA had active sacroiliitis. Of those subjects with active changes on MRI, 7/8 (88%) also had evidence of erosions or sclerosis. Five (13%) children with JSpA and 1 (7%) control had non-periarticular bone marrow edema. Of the subjects with active sacroiliitis only 3 (38%) reported a history of back pain or tenderness on palpation of the sacroiliac joints. The positive and negative predictive values of clinical exam features and back pain for detection of sacroiliitis were low. The estimated probability of having sacroiliitis was 0.84 (95% CI: 0.40–1.00) in HLA-B27+ patients with an elevated CRP.

Address for correspondence: Pamela F. Weiss, 3535 Market Street Room 1526, Philadelphia, PA 19104. Tel: 215-590-2547, weisspa@email.chop.edu, fax: 267-426-0380.

Author Manuscript Author Manuscript Author Manuscript Author Manuscript

Conclusion—Active sacroiliitis by MRI is common at diagnosis in JSpA and is frequently asymptomatic. Children who are HLA-B27+ and have elevated CRP levels have the highest probability of sacroiliitis.

INTRODUCTION

JSpA describes a heterogeneous group of children with varying degrees of enthesitis and arthritis. Under the International League of Associations for Rheumatology (ILAR) classification criteria for juvenile arthritis,(1) most children with JSpA are classified as enthesitis related arthritis (ERA), psoriatic arthritis (PsA), or undifferentiated arthritis. The presence of axial disease in spondyloarthritis (SpA) has major implications for treatment decisions since axial disease in adults does not respond to first-line agents for peripheral arthritis such as methotrexate.(2)

Prior studies have demonstrated that one-third of children with JSpA develop sacroiliitis within several years of diagnosis.(3–5) In one study 80% of ERA patients with back pain 0–68 months after diagnosis had abnormal magnetic resonance imaging (MRI).(5) However, sacroiliitis can also be clinically silent in JSpA.(3, 6) In a retrospective study of children with established disease one-third of patients with an abnormal pelvic imaging had no history of back pain or stiffness and had a normal examination.(3) From these studies it is established that children with JSpA are at risk of developing sacroiliitis, yet it remains unclear if rheumatologists should be concerned about sacroiliitis prior to the development of pain. In adults inflammatory back pain typically heralds the onset of sacroiliitis.(7, 8) However, in children inflammatory back pain is less common.(9–11)

If the accuracy of examination and inflammatory back pain are poor in children, then we may be missing a significant amount of sacroiliitis and an opportunity to treat before damage occurs. This study aimed to evaluate the prevalence of sacroiliitis in children with newly diagnosed JSpA (defined in this study as enthesitis-related arthritis or psoriatic arthritis by International League of Associations for Rheumatology) and to evaluate the accuracy of physical examination findings and the presence of inflammatory back pain in identifying sacroiliitis, using MRI with STIR as the reference standard.

PATIENTS AND METHODS

The protocol for this study was performed in accordance with the Declaration of Helsinki and approved by the local ethics committee. Written informed assent and consent were obtained from study participants and parents, respectively, before study inclusion.

Study design

Prospective cross-sectional study.

Subjects

The source population was children 8–18 years of age evaluated in a single tertiary care rheumatology clinic between April 2012 and September 2014. All children diagnosed with ERA or PsA according the ILAR criteria within the prior 6 months were eligible. All

Author Manuscript Author Manuscript Author Manuscript Author Manuscript

children had symptom onset prior to age 16 years and all also met the European Spondylarthropathy Study Group criteria for spondyloarthritis(12). Exclusion criteria were a prior diagnosis of an alternate JIA category, pregnancy, or contraindication for MRI. Forty-two of 48 (88%) of eligible children agreed to participate. Two children did not complete their study visits, leaving 40 children for analysis. A convenience sample of healthy children was recruited from a primary care practice associated with our hospital. Exclusion criteria for this group were a history, or current diagnosis of an underlying health condition that would deem participant not healthy (including but not limited to documented back or joint complaints or chronic medication use).

Clinical data

Each subject self-reported demographics and family history of rheumatic disease. Laboratory values, medication use, and diagnosis date were abstracted from the medical record.

Measures

The Childhood Health Assessment Questionnaire (CHAQ) (13), Pediatric Rheumatology Quality of Life (PRQL) (14), the global and pain visual analogue scales (VAS), Bath Ankylosing Spondylitis Functional Index (BASFI) (15), Bath Ankylosing Spondylitis Disease Activity Index (BASDAI) (16), and back pain questions were administered. Numeric response scales (0–10) were used for the BASFI and BASDAI. The JSpA Disease Activity (JSpADA) index score was determined for all cases.(17) For this study the definition of inflammatory back pain was adapted from the Assessment of SpondyloArthritis international Society (ASAS) criteria (18) for adults and was defined as present when 3 criteria were present: 1) insidious onset, 2) improvement with exercise, 3) no improvement with rest, 4) pain at night (with improvement upon arising). Questionnaires were completed by a parent/guardian for subjects 12 years of age or younger.

MRI

A dedicated MRI of the pelvis was performed on all subjects. Images acquired included a coronal oblique (parallel to the long axis of the sacrum) with STIR, a coronal oblique T1-weighted turbo spin echo, and an axial T2-weighted turbo spin echo with fat saturation (FS). Contrast enhanced images were not obtained since fluid sensitive sequences are sufficient to detect inflammatory sacroiliitis in children.(19) Large field of view coronal T2-weighted turbo spin echo FS imaging included images of both hips. Two pediatric radiologists (NAC, DMB), blinded to subjects' clinical details, reviewed all images. In cases of disagreement, a decision on the presence or absence of findings was reached by consensus on a later date.

Bone marrow edema (BME) was defined as present if there was hyperintense signal on both T2-weighted FS and STIR images.(20) In skeletally immature children, caution was taken to avoid calling relatively hyperintense apophyseal cartilage adjacent to the sacroiliac joints BME. In these patients, BME was diagnosed when STIR signal was hyperintense relative to the signal in the visualized metaphyseal equivalents (ie iliac crest apophyses), which were used as internal reference standards. Using T2-weighted FS and STIR images (fluid-sensitive sequences), capsulitis was defined as hyperintense signal adjacent to the anterior or

Author Manuscript Author Manuscript Author Manuscript Author Manuscript

posterior capsule. Enthesitis was defined as increased signal where ligaments and tendons attach to bone using T2-weighted FS and STIR imaging. Active sacroiliitis was defined as BME within the sacrum or adjacent ilium.(20) Sclerosis was defined as low subchondral signal intensity extending at least 5 mm from the joints. Erosions were defined as bony defects along the joint margin with low and high signals on T1-weighted and fluid-sensitive sequences, respectively.

Radiographs

An AP pelvic radiograph was performed in upright position on cases but not controls. Radiographic findings were scored using modified New York criteria.(21)

Examination

On the same day as imaging a pediatric rheumatologist (PFW) conducted an unblinded complete joint and entheses examination, hip Flexion ABduction External Rotation (FABER) test. Lumbar and sacroiliac flexion was evaluated using the modified Schober's test;(22) a result less than 6 cm was considered abnormal.(23, 24) Lateral spinal flexion of less than 20 cm was considered abnormal.(25)

Statistical analysis

Demographics and clinical characteristics were summarized by frequencies and percentages for categorical variables and by mean, standard deviation, median, and interquartile range for continuous or count variables. Fisher's exact test for categorical variables and Wilcoxon rank sum test for continuous variables were applied to test for differences in clinical features between those children with and without MRI findings of sacroiliitis. The sensitivity, specificity, positive and negative predictive values (PPV and NPV) of physical examination findings for detection of active sacroiliitis in cases were calculated, using MRI as the reference standard. Predicted probability of having active sacroiliitis was determined using exact multivariate logistic regression with HLA-B27 and CRP as predictors.

Interrater reliability of MRI evaluations was measured with kappa coefficients. A kappa less than 0.40 indicated poor agreement; 0.40–0.59, fair agreement; 0.60–0.74, moderate agreement; and 0.75–1.00, excellent.(26) Degree of agreement calculated as the ratio of the number of cases in which both raters documented abnormal findings and the sum of the numerator and the number of cases where there was disagreement was measured (27). Unlike kappa, this statistic excludes cases for which there was uniform agreement on normal/negative findings and focuses on how often cases in which other or all raters identify abnormalities. Statistical analyses were performed using Stata (Version 13, StataCorp, College Station, TX).

RESULTS

Subjects

During the study period 40 children with newly diagnosed JSpA (ERA (N=36) or PsA (N=4)) and 14 age- and sex-matched healthy controls were evaluated. Demographics of cases and controls are listed in Table 1. In comparison to the healthy controls, children with

Author Manuscript Author Manuscript Author Manuscript Author Manuscript

JSpA had significantly poorer scores on all disease activity measures and significantly higher intensity of pain. The median duration of symptoms prior to diagnosis and median time from diagnosis of JSpA to date of imaging were 6 months (IQR: 2.8–18.0) and 28 days (IQR: 20–49), respectively. At the time of imaging 7 (18%), 7 (18%), and 2 (5%) of subjects had started methotrexate monotherapy, anti-tumor necrosis factor (TNF) agent monotherapy, or both, respectively. Median duration of anti-TNF therapy at the time of imaging was 28 days (IQR: 6–110).

MRI Imaging

Eight (20%) of the cases had BME within the sacrum or adjacent ilium (Figure 1). Seven (20%; 7/36) and one (25%; 1/4) subject(s) with BME met ILAR criteria for ERA or PsA, respectively. In 4 cases the BME was bilateral. Of those cases with BME seven (88%) also had detectable erosions or sclerosis, 1 (14%) had sacroiliac joint enthesitis, 2 (25%) had capsulitis, 6 (75%) had hip enthesitis, and 1 (14%) had hip arthritis. Of the 32 cases without BME 1 (3%) subject had hip enthesitis and none had capsulitis or hip arthritis. None of the cases without BME had sclerosis but 1 (3%) case had unilateral erosion. One (7%) control subject had a small area of unilateral peri-articular BME and none of the controls had enthesitis, capsulitis, or hip arthritis. There were no joints with detectable fat metaplasia or ankylosis.

Five (13%) cases and 1 (7%) control had non-periarticular BME. This BME was in the following locations: Left S3 and S4 bodies (n=1), right iliac wing (n=1), lateral aspects of both femoral heads (n=2), along both sides of the triradiate cartilage (n=1), and adjacent to the left iliac crest apophysis (n=1).

Radiographs

Of those 8 subjects with active changes on MRI, 5 (63%) also had evidence of erosions or sclerosis on radiographs (Figure 2). One subject each had unilateral grade 1, unilateral grade 2, and unilateral grade 3 modified NY criteria changes on radiographs. One subject had bilateral modified NY criteria grade 3 changes. Therefore, 2 cases (5%) met modified NY criteria for Ankylosing Spondylitis at diagnosis, defined as bilateral grade 2 or unilateral grade 3 disease. None of the subjects without BME on MRI had sclerosis or erosions on radiographs.

Association of symptoms, exam findings, and laboratories with imaging results

Demographic, medication use, laboratory findings, axial symptoms, and physical examination findings in those cases who did and did not have active findings on MRI are presented in Table 2. There were no significant differences in age, sex, prevalence of hip arthritis, medication use, axial symptoms or physical exam findings between the two groups. Those with positive findings on MRI were more likely to be HLA-B27 positive (p=0.01). There was also no significant difference between those with and without MRI findings regarding the presence of inflammatory back pain (25% versus 22%, MRI + and MRI −, respectively). Of those with MRI findings indicative of active inflammatory sacroiliitis, 5 (62%) subjects reported neither back pain (current or history of) nor tenderness of the sacroiliac joints on examination. The positive and negative predictive values (PPV and

Author Manuscript Author Manuscript Author Manuscript Author Manuscript

NPV), sensitivity and specificity of inflammatory back pain, sacroiliac tenderness on examination, decreased lateral or forward flexion, and elevated CRP and HLA-B27 positivity, using BME on MRI as the reference standard, are presented in Table 3. The PPV for each symptom, laboratory value, or physical exam findings were low (range 0.16–0.44).

In those children with ERA or PsA, the estimated probability of having sacroiliitis from exact logistic regression was only 0.01 (95%CI: 0–0.11) if the children were HLAB27 negative and had a normal CRP. This probability increases to 0.08 (95%CI: 0–0.37) or 0.33 (95%CI: 0.07–0.70) for children with HLAB27− and elevated CRP or with HLAB27+ and normal CRP, and becomes as high as 0.84 (95%CI: 0.40–1.00), for children with HLAB27+ and elevated CRP.

Reliability of MRI findings

There was greater than 91% agreement between the two radiologists for all active and chronic sacroiliac lesions indicative of sacroiliitis (Table 4). The interrater reliability for the evaluation of BME was moderate as evaluated by kappa statistic (k= 0.66, 95% CI: 0.43–0.89). At 6% of the joints (7 of 108 joints), one rater identified BME while the other did not. Rater 1 rated 11% (12 of 108) of the joints as abnormal BME and rater 2 rated 10% (11 of 108) of the joints as abnormal. For 53% of the joints at which one rater identified BME, both raters had this finding (k=0.67, 95%CI: 0.35–0.90).

Sensitivity analyses

Some consider classification of PsA under the ILAR classification criteria problematic, particularly those with axial disease. We therefore restricted our analyses to those children with ERA (N=36) to see if our findings were robust. 7 of 36 (20%) of children with ERA had had BME within the sacrum or adjacent ilium, the same prevalence as the full sample. As with the full study population, there were no significant differences in age, prevalence of hip arthritis, medication use, axial symptoms or physical exam findings between those with and without periarticular BME. Those children with positive findings on MRI were more likely to be male (p=0.04) and HLA-B27 positive (p=0.01). The positive and negative predictive values (PPV and NPV) of inflammatory back pain, physical exam findings, and laboratories using BME on MRI as the reference standard remained low. The estimated probabilities of having sacroiliitis from exact logistic regression based on CRP and HLA-B27 status were the same as for the full study sample.

DISCUSSION

This is the first study to systematically evaluate the prevalence of sacroiliitis using MRI in children and adolescents in an unselected population of children with newly diagnosed JSpA. In this study we demonstrate 20% of children with JSpA have sacroiliitis on MRI at disease onset. Of those subjects with active sacroiliitis, all but 1 also had evidence of structural damage. One of the subjects met modified NY radiographic criteria for Ankylosing Spondylitis. None of the physical examination features traditionally thought to be indicative of sacroiliitis (sacroiliac tenderness, FABER sign, decreased lateral or forward flexion) had a significantly different prevalence between those with and without sacroiliitis.

Author Manuscript Author Manuscript Author Manuscript Author Manuscript

There was a significantly higher prevalence of HLA-B27 positivity in those children with active sacroiliitis. Elevated CRP modified the probability of having sacroiliitis in HLA-B27 positive children; the probabilities of having sacroiliitis in HLA-B27+ children with and without elevated CRP were 0.84 and 0.33, respectively. Two-thirds of children with active sacroiliitis on imaging did not have current or a history of back pain, or tenderness with direct palpation of the sacroiliac joints. Conversely, of the 9 subjects who reported inflammatory back pain, only 2 (22%) had sacroiliitis.

Several findings warrant additional discussion. First, both the PPV and NPV of sacroiliac joint tenderness for sacroiliitis on MRI were low- 0.11 and 0.74, respectively. This raises the question of whether the current definition of sacroiliac joint arthritis used in the ILAR criteria (tenderness on direct palpation) should be revisited. In this study, fifteen children with JSpA had sacroiliac arthritis according to the ILAR sacroiliac joint arthritis definition, (1) but not by MRI. The low PPV and potential over-diagnosis of sacroiliitis may lead to unnecessary treatment with anti-TNF agents or other systemic agents, especially if there are no other involved joints. It also raises the question of whether imaging should to be performed to confirm sacroiliitis if tenderness on exam is elicited, particularly if systemic inflammatory treatment will be initiated based upon this exam finding.

Second, five of the 8 subjects in our study with positive findings on MRI did not have current or a history of back pain. Further, only 2 subjects (25%) had inflammatory back pain, using a modified definition of inflammatory back pain adapted from the ASAS criteria. (18) In adults, spondyloarthritis (SpA) classification has shifted toward the use of criteria identifying adults with inflammatory back pain who have “axial SpA” (AxSpA) versus those with peripheral disease only.(7, 28) There are no criteria make a similar distinction in children. Our results raise the issue that the adult definition of AxSpA, which mandates the presence of inflammatory back pain, is unlikely to perform well in JSpA given the low sensitivity of IBP for sacroiliitis in this study. Indeed, other studies have suggested that the most important manifestation of early disease in children is peripheral arthritis and enthesitis, not IBP.(11)

Third, approximately one-third of the children with early sacroiliitis would have been missed if radiographs were the only utilized imaging modality. Although radiographs are still the gold standard by which to diagnose Ankylosing spondylitis, MRI has become an accepted method by which to identify early sacroiliitis. Insurances often will not pay for an MRI until a radiograph has been performed. This practice by insurance companies may cause unnecessary radiation exposure to the JSpA population, and may result in early cases of sacroiliitis going undetected if MRI is not subsequently performed.

Lastly, we found evidence of active sacroiliitis in 20% of our study population. The majority of these subjects also had evidence of structural damage, portending continued disease progression.(29) However, the importance of asymptomatic BME in the absence of structural change is unclear. One (7%) healthy control subject had a small, rounded area of increased signal on fluid sensitive sequences within the right ilium, adjacent to the sacroiliac joint. This control did not have any other symptoms or signs of JSpA. The cause of focal increased signal intensity in this control subject is unclear; this control was a 14-year-old

Author Manuscript Author Manuscript Author Manuscript Author Manuscript

male and the abnormal signal could have been secondary to any number of factors including a small fibrous or cartilaginous lesion or bone marrow edema perhaps from physical activity. The abnormal focus of signal intensity in the control appeared different than the BME pattern in JSpA patients as the abnormality in the control patient was rounded and the BME in JSpA patients was typically seen as a periarticular linear finding with edema paralleling the joint space. Nevertheless, the finding of BME in a control subject raises the possibility that some cases of BME in children and adolescents with JSpA, particularly those that are asymptomatic and without evidence of structural damage, may not represent true inflammatory sacroiliitis.

These results should be interpreted in the context of a few limitations. First, this study was limited to children who fulfilled ILAR criteria for ERA or PsA. Although children with ERA and PsA comprise a large percentage of children with JSpA, our results may not be generalizable to children with JSpA who do not fulfill the ILAR criteria such as inflammatory bowel disease associated arthropathy. The rationale for including both ERA and PsA in this study is supported by recent literature that demonstrates that older children with PsA are phenotypically similar to children with ERA and/or SpA and carry a risk of sacroiliitis. (30, 31) Our limited sample size precluded analyzing children with ERA and PsA separately. However, the prevalence of sacroiliitis in both categories was similar in this study. Second, the sample size is somewhat limited, with only 40 cases and 15 controls. The limited sample size may have also impacted our ability to detect significant differences between clinical factors in those children with and without sacroiliitis. With the exception of nighttime back pain, all axial symptoms had a higher prevalence in the children with findings of sacroiliitis on imaging, but not to a statistically significant extent. Third, not all of the children with JSpA were treatment naïve at the time of imaging. Since anti-TNF agents may reduce or suppress BME, it is possible that there was an even higher prevalence of sacroiliitis in our cohort than we were able to demonstrate.

In summary, this is the first study to evaluate for sacroiliitis using MRI at diagnosis in an unselected group of children with JSpA. Although two-thirds of the children with sacroiliitis were asymptomatic, almost all had detectable structural damage. Our results suggest that screening for sacroiliitis with MRI should be considered in all children with JSpA who are HLA-B27+, in particular those who have an elevated CRP. Additional work will need to address the long-term impacts of earlier diagnosis and initiation of biologics in this HLA-B27+ population, as well as risk factors for sacroiliitis in those children with JSpA who are HLA-B27 negative. The long-term efficacy of biologics for sacroiliitis in children is unclear. (32) Recent studies in adults suggest that earlier initiation of biologics (anti-TNFs) may slow radiographic progression;(33, 34) the impact of biologics seemed to be more pronounced in younger patients with shorter disease duration.(33, 34) Therefore identification and diagnosis of those children at highest risk of subsequent progression to AS is important as early screening and/or treatment may significantly impact the disease course and other clinically important outcomes.

Author Manuscript Author Manuscript Author Manuscript Author Manuscript

Acknowledgments

We thank the network of primary care clinicians and their patients and families for their contribution to this project and clinical research facilitated through the Pediatric Research Consortium at the Children's Hospital of Philadelphia. We also thank the Rheumatology clinicians, nurses, and patients and their families for their contribution to this project. We thank Andrew Klink, MPH and Keshia Maughn, MPH for their assistance with recruitment of subjects and data management. Lastly, we thank Colden Broderick for her assistance with data entry.

Grant Support: Research reported in this publication was supported by the National Institute of Arthritis and Musculoskeletal and Skin Diseases of the National Institutes of Health under Award Number R03-AR062665 and also in part by the National Center for Research Resources and the National Center for Advancing Translational Sciences through Grant UL1-RR-024134. The content is solely the responsibility of the authors and dose not necessarily represent the official views of the National Institutes of Health.

References

1. Petty RE, Southwood TR, Manners P, Baum J, Glass DN, Goldenberg J, et al. International League of Associations for Rheumatology classification of juvenile idiopathic arthritis: second revision, Edmonton, 2001. J Rheumatol. 2004; 31(2):390–2. [PubMed: 14760812]
2. Haibel H, Brandt HC, Song IH, Brandt A, Listing J, Rudwaleit M, et al. No efficacy of subcutaneous methotrexate in active ankylosing spondylitis: a 16-week open-label trial. Ann Rheum Dis. 2007; 66(3):419–21. [PubMed: 16901959]
3. Stoll ML, Bhore R, Dempsey-Robertson M, Punaro M. Spondyloarthritis in a pediatric population: risk factors for sacroiliitis. J Rheumatol. 2010; 37(11):2402–8. [PubMed: 20682668]
4. Flato B, Hoffmann-Vold AM, Reiff A, Forre O, Lien G, Vinje O. Long-term outcome and prognostic factors in enthesitis-related arthritis: a case-control study. Arthritis Rheum. 2006; 54(11): 3573–82. [PubMed: 17075863]
5. Pagnini I, Savelli S, Matucci-Cerinic M, Fonda C, Cimaz R, Simonini G. Early predictors of juvenile sacroiliitis in enthesitis-related arthritis. The Journal of rheumatology. 2010; 37(11):2395–401. [PubMed: 20810515]
6. Bollow M, Biedermann T, Kannenberg J, Paris S, Schauer-Petrowski C, Minden K, et al. Use of dynamic magnetic resonance imaging to detect sacroiliitis in HLA-B27 positive and negative children with juvenile arthritides. J Rheumatol. 1998; 25(3):556–64. [PubMed: 9517781]
7. Rudwaleit M, van der Heijde D, Landewe R, Listing J, Akkoc N, Brandt J, et al. The development of Assessment of SpondyloArthritis international Society classification criteria for axial spondyloarthritis (part II): validation and final selection. Annals of the rheumatic diseases. 2009; 68(6):777–83. [PubMed: 19297344]
8. Rudwaleit M, Metter A, Listing J, Sieper J, Braun J. Inflammatory back pain in ankylosing spondylitis: a reassessment of the clinical history for application as classification and diagnostic criteria. Arthritis Rheum. 2006; 54(2):569–78. [PubMed: 16447233]
9. Chen HA, Chen CH, Liao HT, Lin YJ, Chen PC, Chen WS, et al. Clinical, functional, and radiographic differences among juvenile-onset, adult-onset, and late-onset ankylosing spondylitis. J Rheumatol. 2012; 39(5):1013–8. [PubMed: 22422495]
10. Olivieri I, Cutro MS, D'Angelo S, Leccese P, Mennillo GA, Scarano E, et al. Low frequency of axial involvement in southern Italian Caucasian children with HLA-B27 positive juvenile onset undifferentiated spondyloarthritis. Clinical and experimental rheumatology. 2012; 30(2):290–6. [PubMed: 22325303]
11. Burgos-Vargas R. The assessment of the spondyloarthritis international society concept and criteria for the classification of axial spondyloarthritis and peripheral spondyloarthritis: A critical appraisal for the pediatric rheumatologist. Pediatric rheumatology online journal. 2012; 10(1):14. [PubMed: 22650358]
12. Dougados M, van der Linden S, Juhlin R, Huitfeldt B, Amor B, Calin A, et al. The European Spondylarthropathy Study Group preliminary criteria for the classification of spondylarthropathy. Arthritis Rheum. 1991; 34(10):1218–27. [PubMed: 1930310]
13. Singh G, Athreya BH, Fries JF, Goldsmith DP. Measurement of health status in children with juvenile rheumatoid arthritis. Arthritis Rheum. 1994; 37(12):1761–9. [PubMed: 7986222]

Author Manuscript Author Manuscript Author Manuscript Author Manuscript

14. Filocamo G, Schiappapietra B, Bertamino M, Pistorio A, Ruperto N, Magni-Manzoni S, et al. A new short and simple health-related quality of life measurement for paediatric rheumatic diseases: initial validation in juvenile idiopathic arthritis. Rheumatology (Oxford). 2010; 49(7):1272–80. [PubMed: 20338888]
15. Calin A, Garrett S, Whitelock H, Kennedy LG, O'Hea J, Mallorie P, et al. A new approach to defining functional ability in ankylosing spondylitis: the development of the Bath Ankylosing Spondylitis Functional Index. J Rheumatol. 1994; 21(12):2281–5. [PubMed: 7699629]
16. Garrett S, Jenkinson T, Kennedy LG, Whitelock H, Gaisford P, Calin A. A new approach to defining disease status in ankylosing spondylitis: the Bath Ankylosing Spondylitis Disease Activity Index. J Rheumatol. 1994; 21(12):2286–91. [PubMed: 7699630]
17. Weiss PF, Colbert RA, Xiao R, Feudtner C, Beukelman T, DeWitt EM, et al. Development and retrospective validation of the juvenile spondyloarthritis disease activity index. Arthritis care & research. 2014; 66(12):1775–82. [PubMed: 25047959]
18. Sieper J, van der Heijde D, Landewe R, Brandt J, Burgos-Vagas R, Collantes-Estevez E, et al. New criteria for inflammatory back pain in patients with chronic back pain: a real patient exercise by experts from the Assessment of SpondyloArthritis international Society (ASAS). Annals of the Rheumatic Diseases. 2009; 68(6):784–8. [PubMed: 19147614]
19. Weiss PF, Xiao R, Biko DM, Johnson AM, Chauvin NA. Detection of inflammatory sacroiliitis in children with magnetic resonance imaging: is gadolinium-contrast enhancement necessary? Arthritis & Rheumatology. 2015 Accepted.
20. Sieper J, Rudwaleit M, Baraliakos X, Brandt J, Braun J, Burgos-Vargas R, et al. The Assessment of SpondyloArthritis international Society (ASAS) handbook: a guide to assess spondyloarthritis. Ann Rheum Dis. 2009; 68(Suppl 2):ii1–44. [PubMed: 19433414]
21. Goie The HS, Steven MM, van der Linden SM, Cats A. Evaluation of diagnostic criteria for ankylosing spondylitis: a comparison of the Rome, New York and modified New York criteria in patients with a positive clinical history screening test for ankylosing spondylitis. Br J Rheumatol. 1985; 24(3):242–9. [PubMed: 3160423]
22. Macrae IF, Wright V. Measurement of back movement. Annals of the rheumatic diseases. 1969; 28(6):584–9. [PubMed: 5363241]
23. Cassidy, JT.; Petty, R.; Laxer, RM.; Lindsley, C. Textbook of Pediatric Rheumatology. 6th. Philadelphia: Elvesier; 2011.
24. Woolston SL, Beukelman T, Sherry DD. Back mobility and interincisor distance ranges in racially diverse North American healthy children and relationship to generalized hypermobility. Pediatric rheumatology online journal. 2012; 10(1):17. [PubMed: 22716216]
25. Jones SD, Porter J, Garrett SL, Kennedy LG, Whitelock H, Calin A. A new scoring system for the Bath Ankylosing Spondylitis Metrology Index (BASMI). The Journal of rheumatology. 1995; 22(8):1609. [PubMed: 7473496]
26. Landis JR, Koch GG. The measurement of observer agreement for categorical data. Biometrics. 1977; 33(1):159–74. [PubMed: 843571]
27. Localio AR, Weaver SL, Landis JR, Lawthers AG, Brenhan TA, Hebert L, et al. Identifying adverse events caused by medical care: degree of physician agreement in a retrospective chart review. Ann Intern Med. 1996; 125(6):457–64. [PubMed: 8779457]
28. Rudwaleit M, van der Heijde D, Landewe R, Akkoc N, Brandt J, Chou CT, et al. The Assessment of SpondyloArthritis International Society classification criteria for peripheral spondyloarthritis and for spondyloarthritis in general. Annals of the Rheumatic Diseases. 2011; 70(1):25–31. [PubMed: 21109520]
29. Poddubnyy D, Haibel H, Listing J, Marker-Hermann E, Zeidler H, Braun J, et al. Baseline radiographic damage, elevated acute-phase reactant levels, and cigarette smoking status predict spinal radiographic progression in early axial spondylarthritis. Arthritis Rheum. 2012; 64(5):1388–98. [PubMed: 22127957]
30. Butbul Aviel Y, Tyrrell P, Schneider R, Dhillon S, Feldman BM, Laxer R, et al. Juvenile Psoriatic Arthritis (JPsA): juvenile arthritis with psoriasis? Pediatric rheumatology online journal. 2013; 11(1):11. [PubMed: 23497068]

Author Manuscript Author Manuscript Author Manuscript Author Manuscript

31. Stoll ML, Punaro M. Psoriatic juvenile idiopathic arthritis: a tale of two subgroups. Current opinion in rheumatology. 2011; 23(5):437–43. [PubMed: 21709556]
32. Hugle B, Burgos-Vargas R, Inman RD, O'Shea F, Laxer RM, Stimec J, et al. Long-term outcome of anti-tumor necrosis factor alpha blockade in the treatment of juvenile spondyloarthritis. Clinical and experimental rheumatology. 2014; 32(3):424–31. [PubMed: 24387974]
33. Baraliakos X, Haibel H, Listing J, Sieper J, Braun J. Continuous long-term anti-TNF therapy does not lead to an increase in the rate of new bone formation over 8 years in patients with ankylosing spondylitis. Ann Rheum Dis. 2014; 73(4):710–5. [PubMed: 23505240]
34. Haroon N, Inman RD, Learch TJ, Weisman MH, Lee M, Rahbar MH, et al. The impact of tumor necrosis factor alpha inhibitors on radiographic progression in ankylosing spondylitis. Arthritis Rheum. 2013; 65(10):2645–54. [PubMed: 23818109]

Author Manuscript Author Manuscript Author Manuscript Author Manuscript

SIGNIFICANCE AND INNOVATION

- This is the first study to evaluate the prevalence of sacroiliitis by MRI at the time of JSpA diagnosis
- Sacroiliitis is common at diagnosis in children with JSpA and is frequently asymptomatic
- Screening for sacroiliitis should be considered in all children with JSpA who are HLA-B27+, in particular those who have an elevated CRP

Author Manuscript Author Manuscript Author Manuscript Author Manuscript

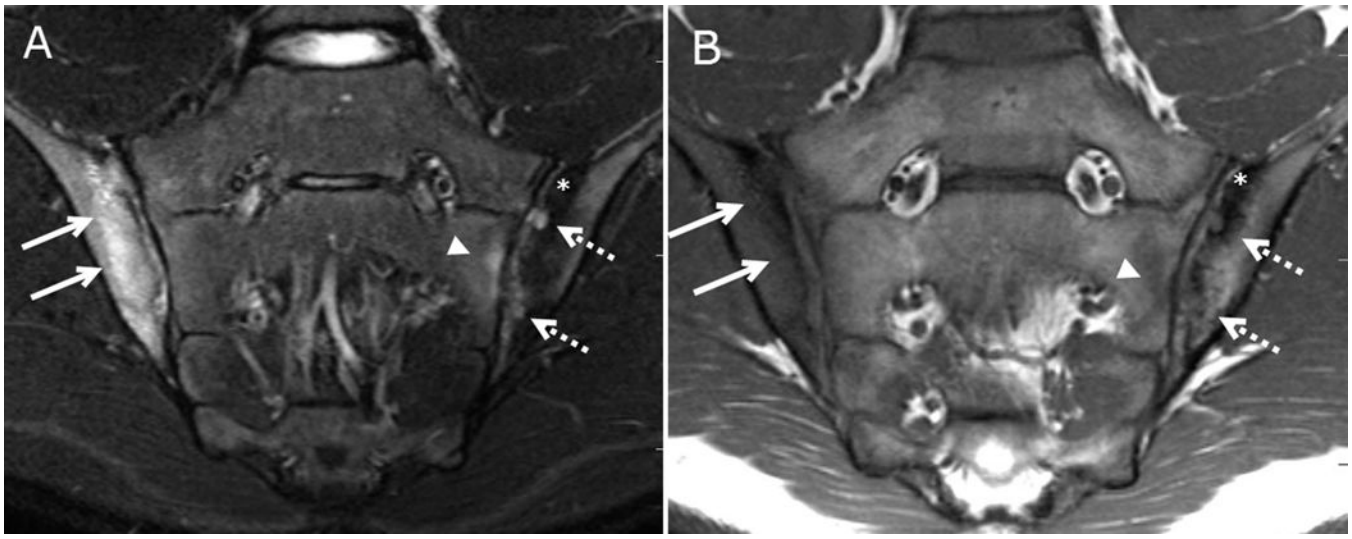

Figure 1. Sacroiliitis on MRI imaging

Coronal oblique STIR (A) and coronal oblique T1-weighted (B) images of the sacroiliac joints of an 18-year old HLA-B27+ male with over 2 years of symptoms at diagnosis. There is active sacroiliitis with periarticular bone marrow edema within the right iliac bone as demonstrated by increased signal intensity on STIR (A) imaging (arrows) and decreased signal intensity on T1-weighted (B) imaging (arrows). The left sacroiliac joint demonstrates active on chronic sacroiliitis with mild periarticular bone marrow edema within the sacrum (arrowheads) along with periarticular sclerosis of the iliac bone with decreased signal intensity on both STIR (A) and T1-weighted (B) imaging (*) with erosive changes (dashed arrows).

Author Manuscript Author Manuscript Author Manuscript Author Manuscript

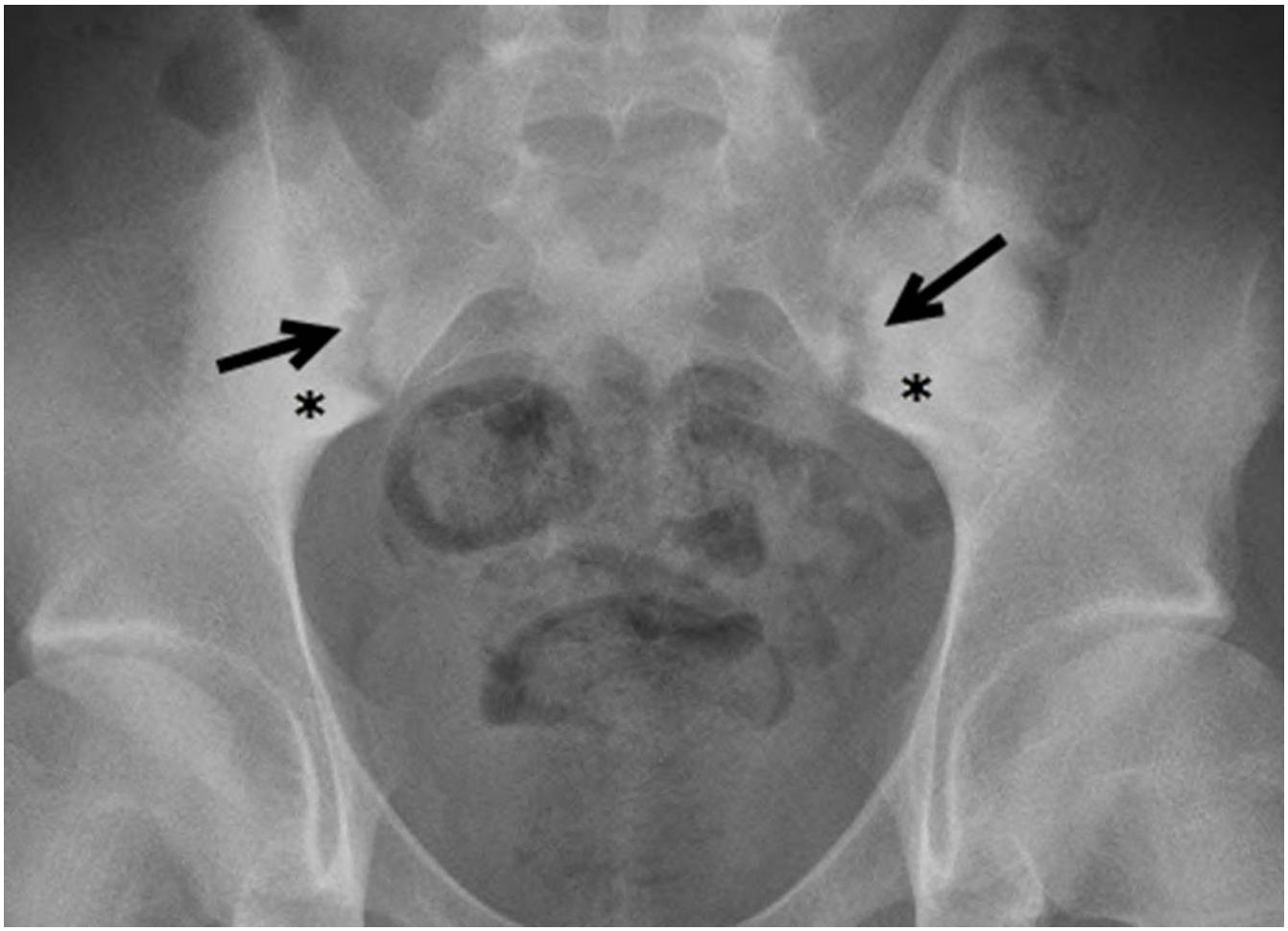

Figure 2. Radiographic changes of chronic sacroiliitis

Frontal radiograph of the pelvis of 15-year old male (HLA-B27 positive) showing bilateral chronic erosive sacroiliitis. There is bilateral periarticular osseous sclerosis (*) and erosions (arrows) along both iliac bones with consequent widening of the sacroiliac joint space, more prominent on the right.

Author Manuscript Author Manuscript Author Manuscript Author Manuscript

Table 1

Subjects

Demographic and clinical features of cases and controls at the time of study participation. P-value represents the comparison between children with ERA or PsA and healthy controls.

	ERA and PsA N=40	Controls N=14	p-value
Age, years (mean, SD)	14.1 (2.7)	13.9 (2.4)	0.86
Disease duration, days (median, IQR)	28 (20, 49)	–	–
Male, N (%)	20 (50)	7 (50)	1.00
HLA-B27+*	16 (43)	–	–
Family history of HLA-B27 disease	10 (25)	2 (14)	0.71
Active joint count, median (IQR)	0 (0, 2)	0 (0, 0)	0.07
Tender entheses count, median (IQR)	9 (19)	1 (1)	<0.01
JSpADA, mean (SD)	2.2 (1.2)	0.1 (0.4)	<0.01
BASFI, mean (SD)	2.4 (2.4)	0.0 (0.0)	<0.01
BASDAI, mean (SD)	3.9 (2.8)	0.1 (0.2)	<0.01
Pain over past week, mean (SD)	3.6 (2.5)	0.0 (0.0)	<0.01

*HLA-B27 missing for 3 subjects.

Author Manuscript Author Manuscript Author Manuscript Author Manuscript

Table 2

MRI+ versus MRI− cases

Comparison of subjects with and without active sacroiliitis, defined as periarticular BME on MRI. Bone marrow edema (BME) was present if hyperintense signal was visible on both T2-weighted FS and STIR images.(20)

	MRI+ N=8	MRI− N=32	p-value
Age (years), mean ± SD	15.2±1.8	13.8±2.8	0.19
Male, N (%)	6 (75)	14 (43)	0.24
Hip arthritis, N (%)	0 (0)	5(16)	0.56
Morning stiffness > 30 minutes	2 (25)	14 (44)	0.44
MEDICATIONS, N (%)			
Disease modifying anti-rheumatic agents (MTX or SSZ)	1 (13)	8 (25)	0.66
Anti-TNF α	4 (50)	5 (16)	0.06
NSAIDs	4 (50)	18 (58)	0.71
LABORATORY FINDINGS*			
CRP (mg/dL), median (IQR)	1.2 (0, 36.1)	0.3 (0, 1.0)	0.46
ESR (mm/h), median (IQR)	6 (1, 19)	4 (0, 20)	0.50
HLA-B27+, N (%)	7 (88)	9 (28)	0.01
AXIAL SYMPTOMS, N (%)			
Back pain	3 (38)	19 (59)	0.43
Duration ≥ 3 months	3 (100)	9 (47)	0.22
Insidious onset	3 (100)	10 (53)	0.24
Improves with activity	2 (67)	7 (37)	0.54
Nighttime back pain	1 (33)	11(69)	0.52
Alternating buttock pain	3 (38)	6 (19)	0.35
PHYSICAL EXAMINATION, N (%)			
Decreased lateral flexion	3 (38)	16 (50)	0.70
Loss of lumbar lordosis	4 (50)	16 (50)	1.00
Positive FABER test	0 (0)	6 (19)	0.32
Decreased forward flexion	1 (13)	0 (0)	0.20
Sacroiliac tenderness	2 (25)	15 (47)	0.43

*HLA-B27 status missing for 3 cases in the MRI- group; CRP and ESR values missing for 7 and 10 subjects, respectively.

Author Manuscript Author Manuscript Author Manuscript Author Manuscript

Table 3

Accuracy of symptoms, laboratory values, and examination for detection of sacroiliitis on MRI

PPV, NPV, sensitivity and specificity of symptoms, lab values, and exam features for the detection of sacroiliitis using BME on MRI as the reference standard.

	PPV (95% CI)	NPV (95% CI)	Sensitivity (95% CI)	Specificity (95% CI)
Inflammatory back pain*	0.22 (0, 0.49)	0.81 (0.67, 0.95)	0.25 (0, 0.55)	0.78 (0.63, 0.92)
Elevated CRP#	0.33 (0.07, 0.60)	0.85 (0.71, 1.00)	0.57 (0.20, 0.94)	0.69 (0.51, 0.87)
HLA-B27+	0.44 (0.19, 0.68)	0.96 (0.86, 1.00)	0.88 (0.65, 1.00)	0.69 (0.52, 0.86)
Sacroiliac tenderness	0.11 (0, 0.27)	0.74 (0.56, 0.92)	0.25 (0, 0.55)	0.53 (0.36, 0.71)
Decreased lateral flexion	0.16 (0, 0.32)	0.76 (0.58, 0.94)	0.38 (0.04, 0.71)	0.50 (0.33, 0.67)

*For this study the definition of inflammatory back pain was adapted from the ASAS criteria (18) for adults and was defined as present when 3 of the following criteria were met: 1) insidious onset, 2) improvement with exercise, 3) no improvement with rest, 4) pain at night (with improvement upon getting up).

Author Manuscript

Author Manuscript

Author Manuscript

Author Manuscript

Table 4

Reliability of MRI findings indicative of active and chronic sacroiliitis

Kappa value < 0.40 indicates poor, 0.40–0.59 fair, 0.60–0.74 moderate, and 0.75–1.00, excellent agreement(26).

	Intra-rater reliability		Inter-rater reliability	
	Kappa (95% CI)	% Agreement	Kappa (95% CI)	% Agreement
Bone marrow edema	1.00 (1.00, 1.00)	100	0.66 (0.43, 0.89)	94
Erosions	0.94 (0.83, 1.00)	97	0.40 (0.09, 0.70)	91
Sclerosis	0.76 (0.50, 1.00)	97	0.21 (0, 0.56)	94
SIJ enthesitis	0.74 (0.40, 1.00)	98	0.27 (0, 0.71)	95
Hip enthesitis	0.71 (0.47, 0.95)	95	0.68 (0.42, 0.94)	95
Capsulitis	0.49 (0, 1.00)	98	0.49 (0, 1.00)	98