

# Addition of transversus abdominis plane block to patient controlled analgesia for laparoscopic high anterior resection improves analgesia, reduces opioid requirement and expedites recovery of bowel function

F Ris, JM Findlay, R Hompes, A Rashid, J Warwick, C Cunningham, O Jones,  
N Crabtree, I Lindsey

Oxford University Hospitals NHS Trust, UK

## ABSTRACT

**INTRODUCTION** Opioid sparing in postoperative pain management appears key in colorectal enhanced recovery. Transversus abdominis plane (TAP) blocks offer such an effect. This study aimed to quantify this effect on pain, opioid use and recovery of bowel function after laparoscopic high anterior resection.

**METHODS** This was a retrospective analysis of prospective data on 68 patients. Patients received an epidural ( $n=24$ ), intravenous morphine patient controlled analgesia (PCA,  $n=22$ ) or TAP blocks plus PCA ( $n=22$ ) determined by anaesthetist preference. Outcome measures were numerical pain scores (0–3), cumulative intravenous morphine dose and time to recovery of bowel function (passage of flatus or stool).

**RESULTS** There were no differences in patient characteristics, complications or extraction site. The TAP block group had lower pain scores (0.7 vs 1.36,  $p<0.001$ ) and morphine requirements (8mg vs 15mg,  $p=0.01$ ) than the group receiving PCA alone at 12 hours and 24 hours. Earlier passage of flatus (2.0 vs 2.7 vs 3.4 days,  $p=0.002$ ), stool (3.1 vs 4.1 vs 5.5 days,  $p=0.04$ ) and earlier discharge (4 vs 5 vs 6 days,  $p=0.02$ ) were also seen.

**CONCLUSIONS** Use of TAP blocks was found to reduce pain and morphine use compared with PCA, expedite recovery of bowel function compared with PCA and epidural, and expedite hospital discharge compared with epidural.

## KEYWORDS

Nerve blockade – Laparoscopy – Analgesia – Pain – Colorectal surgery

Accepted 5 December 2013

## CORRESPONDENCE TO

Ian Lindsey, E: lindseyilnz@yahoo.com

Pain is an important physiological mediator of the surgical stress response and a predictor of worse postoperative outcome.<sup>1–5</sup> In abdominal surgery, the majority of pain stimuli derive from the anterior abdominal wall<sup>4</sup> and are commonly ameliorated with multimodal analgesic regimes (eg paracetamol and non-steroidal anti-inflammatory drugs complemented with parenteral opioids). The latter are commonly delivered as patient controlled analgesia (PCA).<sup>5</sup> However, their utility may be limited by side effects including nausea, vomiting, sedation, urinary retention, and suppression of respiratory and gastrointestinal function.<sup>6,7</sup> Minimising these side effects via judicious use of opioids is an important component of enhanced or accelerated recovery programmes.<sup>8</sup>

Local anaesthetic blockade (either centrally or peripherally) is a common alternative or supplementary measure. Epidural analgesia has a prominent role following major abdominal surgery although it may be contraindicated in

some.<sup>9,10</sup> Nevertheless, while reducing pain and the incidence of respiratory failure,<sup>11</sup> the ultimate effect on mortality, although clinically significant, is small (an estimated number needed to treat of 477)<sup>12</sup> and may be limited to certain patient cohorts.<sup>13,14</sup> Unfortunately, these benefits may come at a cost: cardiovascular (vasoparesis, hypotension and splanchnic hypoperfusion),<sup>15</sup> functional (motor block and restricted mobility, conflicting with a contemporary drive to expedite mobility)<sup>16</sup> and resource consumption (time, equipment, monitoring and nursing input).<sup>12</sup> Ultimately, it has been suggested that epidurals may sometimes contribute to a worse outcome.<sup>17</sup>

Consequently, peripheral blockade may have utility although in many anatomical areas, individual nerve blockade or wound infiltration may not suffice. However, the transversus abdominis plane (TAP) possesses a number of anatomical characteristics that have made it an appealing and topical

target for blockade. The TAP is a neurofascial plane of the anterior abdominal wall lying between the internal oblique and transversus abdominis. It contains the somatic innervation of the anterolateral abdominal wall: the terminal branches of the anterior roots of the lower six thoracic and first lumbar nerves. These nerves ramify and communicate (particularly T9 to L1) extensively to constitute the so-called TAP plexus, which runs with the deep circumflex iliac artery.<sup>18</sup>

The TAP has become a popular target for blockade, following description of the technique in 2001.<sup>19</sup> Subsequently, a number of modifications to the original landmark-based or 'blind' technique have been made. That most commonly used is the ultrasonography guided approach.<sup>20</sup> Opioid sparing effects and variable reductions in pain scores and side effects have been demonstrated in the majority of (although not all) studies.<sup>21</sup>

In colorectal surgery, however, the evidence is so far restricted to just three studies: one randomised controlled trial (RCT) of open resections (demonstrating improvements in the above endpoints when compared with PCA alone)<sup>22</sup> and two non-randomised trials in pooled laparoscopic resections.<sup>23,24</sup> These demonstrated a lower 24-hour morphine consumption with TAP block as opposed to PCA alone,<sup>23</sup> and earlier discharge and return to diet with TAP block and simple analgesia as opposed to PCA and epidural.<sup>24</sup> We conducted a retrospective study to clarify the effect of TAP blockade on postoperative analgesia, return of bowel function and hospital discharge in laparoscopic high anterior resection. These outcomes were compared for patients receiving either epidural, PCA or TAP block.

## Methods

This was a retrospective analysis of a prospectively maintained and secured electronic departmental database of analgesia after laparoscopic high anterior resections performed between January 2009 and March 2011. As a retrospective analysis of existing differences in departmental practice, ethical approval was not required but this study was attributed an audit authorisation number by Oxford University Hospitals NHS Trust (number 1755).

### Operative protocol

Standardised laparoscopic high anterior resection without bowel preparation was performed with a five-port technique: two 12mm umbilical and right iliac fossa ports and three 5mm ports (paraumbilical right/right upper quadrant, left, epigastric/suprapubic). Direction of dissection (either medial to lateral or lateral to medial) was according to surgical preference. A standard sequence was otherwise used, with routine mobilisation of the splenic flexure and high ligation of the inferior mesenteric pedicle close to its origin. The colon was then divided intra-abdominally above the peritoneal reflection. A more distal division was defined as a low anterior resection and the patient was not included in the series. Specimen extraction was via a transverse extended transumbilical ( $n=32$ ), Pfannenstiel ( $n=17$ ), right iliac fossa ( $n=16$ ) or left iliac fossa ( $n=3$ ) incision according to the surgeon's preference.

### Anaesthetic protocol

All patients underwent general anaesthesia performed by consultant anaesthetists. Intraoperative analgesia was provided with intravenous morphine and paracetamol; typically, boluses were given 30 minutes before the end of the procedure.

### Postoperative analgesia

The modality used was determined by the responsible anaesthetist. Epidural insertion was performed with a standard technique using an 18G Tuohy needle and loss of resistance for saline. Epidural analgesia was provided with 0.1% bupivacaine plus 5µg/ml of fentanyl. The background infusion rate was 4–6ml per hour, with a 3ml bolus available every 30 minutes. PCA (for both the PCA alone and TAP block plus PCA groups) comprised 1mg morphine boluses with a five-minute lockout.

Bilateral TAP blocks were performed under ultrasonography guidance by the responsible anaesthetist before surgery. The three musculoaponeurotic layers of the lateral abdominal wall were visualised by an ultrasonography probe (SonoSite, Bothell, WA, US) placed in the midlateral line halfway between the most cephalad iliac crest margin and the most caudal costal margin. A 100mm Stimuplex® needle (B Braun, Melsungen, Germany) or a 22G Whitacre spinal needle without stylette (Becton Dickinson, Franklin Lakes, NJ, US) was advanced under ultrasonography guidance to lie between the transversus abdominis (innermost) and internal oblique (middle) layers. Confirmation of position in the TAP was by visualisation of expansion of injectate separating the middle and inner layers. This was correlated with two 'pops' of the needle with passage through the fascial layers. Up to 20ml of 0.375% bupivacaine was infiltrated on each side and titrated against the patient's weight (maximum dose 1mg/kg).

Postoperative analgesia (PCA and epidural catheter) was supervised by the pain team. All patients received regular oral paracetamol 1g every four hours unless contraindicated. Following removal of the PCA/epidural catheter, oral opioids were made available (either tramadol 50–100mg, codeine phosphate 30–60mg or morphine).

### Postoperative protocol

All patients were discharged to the ward after fulfilling the recovery room criteria. Intravenous fluids were tailored to the needs of the patients. Clear fluids were allowed on the day of operation and free fluids from the first postoperative day. Oral fluid and nutrition intake were built up according to patient tolerance. Mobilisation was encouraged on day 1 and the urinary catheter removed when the patient was mobile or following removal of the epidural catheter. Patients were discharged when safely mobile, comfortable on oral analgesia and tolerating a normal diet.

### Data collection and analysis

Data were collected retrospectively from patient notes and charts. Analgesic outcome measures were cumulative morphine in the recovery unit, at 12 hours and every 24 hours until discharge, and numerical pain scores at the same

**Table 1** Patient characteristics

	Epidural (n=24)	PCA (n=22)	TAP block (n=22)	p-value		
				E vs PCA	E vs TAP	PCA vs TAP
Male-to-female ratio	13:11	10:12	11:11	0.858*	0.533	0.867
Mean age (years)	71.1 ±2.3	66.8 ±2.3	67.3 ±2.6	0.138**	0.207	0.877
Mean BMI (kg/m <sup>2</sup> )	28.1 ±1.1	27.2 ±1.7	27.6 ±1.7	0.182**	0.521	0.055
Mean ASA grade	2.3 ±0.1	1.9 ±0.2	2.2 ±0.1	0.420**	0.387	0.923
Mean operative time (mins)	188.0 ±10.7	186.8 ±9.5	194.4 ±10.3	0.292**	0.698	0.385
Midline incision	12	9	11	0.853*		
Pfannenstiel incision	6	7	4			
Right iliac fossa incision	5	5	6			
Left iliac fossa incision	1	1	1			

PCA = patient controlled analgesia; TAP = transversus abdominis plane; E = epidural; BMI = body mass index;  
ASA = American Society of Anesthesiologists  
\*Pearson's chi-squared test; \*\*independent t-test

time points. The latter were graded 0–3, (0 = no pain, 1 = mild pain, 2 = moderate pain, 3 = severe pain). Bowel function outcomes were time to first passage of flatus and stool. The independent t-test and Pearson's chi-squared test were used as appropriate. Statistical significance was defined as  $p < 0.05$  (95% confidence limits).

## Results

A total of 68 patients were included between January 2009 and March 2011. Of these, 24 received an epidural, 22 received PCA alone and 22 received TAP blocks (with PCA). Operations were performed for either colorectal cancer (21/18/17,  $p > 0.05$ ) or diverticular disease (3/4/5,  $p > 0.05$ ). No procedures were converted to open operations. There were no significant differences between the three groups in terms of sex, age, body mass index (BMI), ASA (American Society of Anesthesiologists) grade, operative time or extraction incision used (Table 1).

### Opioid usage

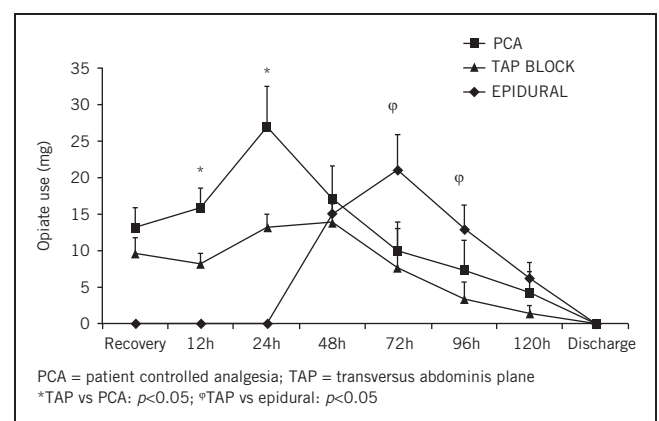
Use of TAP blocks was associated with significant reductions in mean morphine usage at 12 hours (51%, 8.2mg vs 16.0mg,  $p = 0.005$ ) and 24 hours (48%, 13.2mg vs 27.0mg,  $p = 0.01$ ) postoperatively (Figs 1 and 2). Non-significant trends to reductions were seen at all other time points. A significant difference was seen on days 4 and 5 between the TAP block group and the epidural group (3.4mg vs 13.0mg,  $p = 0.02$ ; and 1.5mg vs 6.3mg,  $p = 0.04$ ), after most of the epidural catheters were removed.

Cumulative opioid use (Fig 2) was significantly lower for the epidural group at all time points up to discharge than for the PCA group and it was significantly lower up to 72 hours than for the TAP block patients. There was no significant difference in time of PCA takedown in the PCA group

(mean: 2.4 ±0.2 days, median: 2 days) versus the TAP block group (mean: 2.1 ±0.2 days, median: 2 days) ( $p = 0.37$ ). After epidural catheter removal (mean: 3 ±0.20 days, median: 3 days), the use of opiates increased compared with PCA and TAP block patients (Figs 1 and 2).

### Numerical pain scores

In addition to lower morphine requirements, mean pain scores were also lower with TAP block than with PCA at both 12 hours (0.72 vs 1.36,  $p = 0.001$ ) and 24 hours postoperatively (0.72 vs 1.00,  $p = 0.03$ ) (Fig 3). Improvements were not significant at any other time points (with the exception of 96 hours). Use of epidural provided superior analgesia to PCA and TAP block immediately after surgery as well as superior analgesia to PCA up to 12 hours postoperatively. Pain scores for TAP block patients were lower than for the



**Figure 1** Mean postoperative opiate use

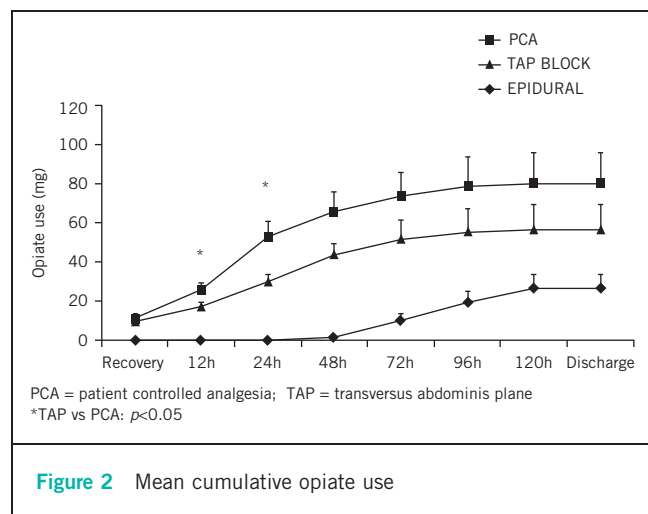


Figure 2 Mean cumulative opiate use

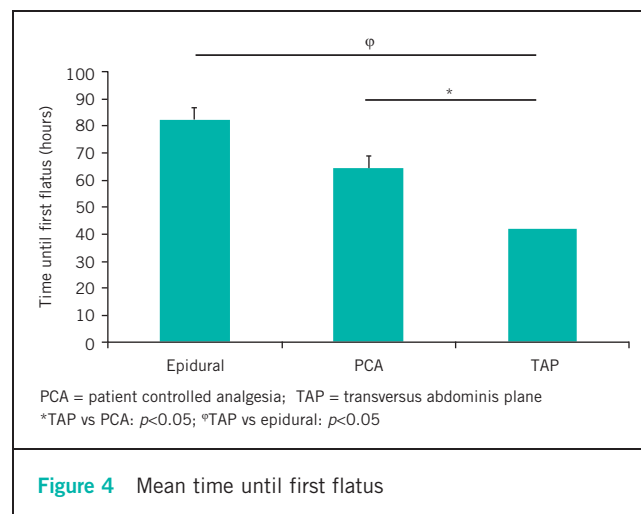


Figure 4 Mean time until first flatus

epidural group but this difference was not significant until 96 hours with epidural catheter removal.

### Recovery of bowel function

The mean time to first passage of flatus was significantly shorter with TAP block than with epidural (2.0 vs 3.4 days,  $p = 0.002$ ) and with PCA (2.0 vs 2.7 days) ( $p = 0.002$ ) (Fig 4). The mean time to first stool was also significantly shorter with TAP block than with epidural (3.2 vs 5.5 days,  $p < 0.001$ ) and PCA (3.2 vs 4.4 days,  $p = 0.003$ ). Patients with PCA had a significantly quicker bowel movement than the epidural patients (4.4 vs 5.5 days,  $p = 0.04$ ) (Fig 5). There were significant differences between the TAP block patients and the epidural group in time to resumption of free fluids or normal diet (Table 2), the TAP block patients having a quicker fluid and diet allowance over epidural and PCA alone.

### Hospital stay and complications

There was a significant difference in the mean length of hospital stay between the TAP block group and the

epidural patients (Fig 6). There were no significant differences in postoperative complications.

### Discussion

In this study in laparoscopic high anterior resection, TAP block was associated with superior analgesia and less opioid use in the first 24 hours following surgery when compared with PCA. Improvements seen thereafter were non-significant. These findings are in line with previous studies appraising both laparoscopic<sup>25,25</sup> and open procedures.<sup>26</sup> Significant differences were noted between the TAP block and epidural groups after removal of the epidural catheter. This reflects the very good initial pain control with an epidural, followed by poor pain control after removal of the epidural catheter. While the side effects of opioids were not assessed (such as nausea, vomiting and pruritus), earlier restoration of bowel function was observed with TAP block. This did not ultimately

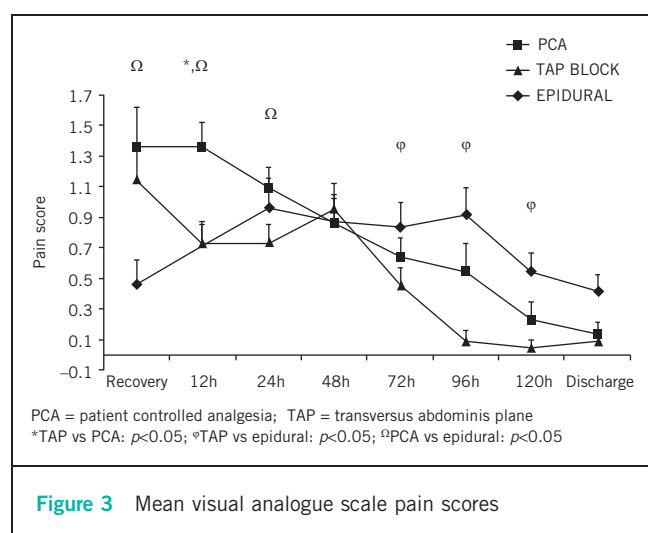


Figure 3 Mean visual analogue scale pain scores

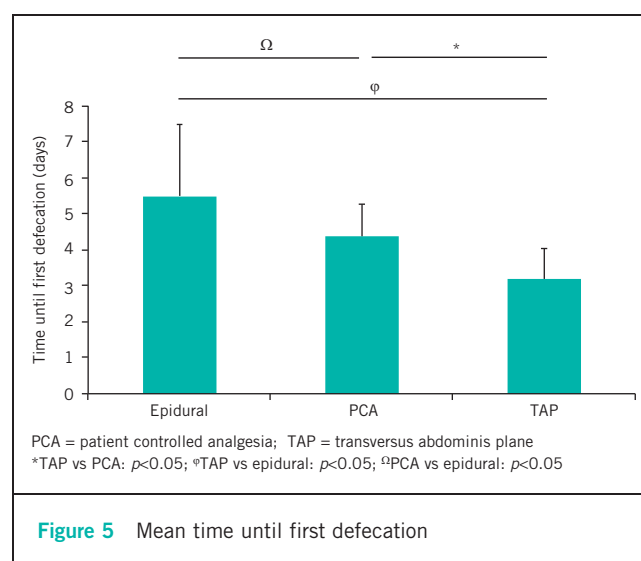


Figure 5 Mean time until first defecation

**Table 2** Mean time to oral intake and normal diet

	Epidural	PCA	TAP block	<i>p</i> -value		
				E vs PCA	E vs TAP	PCA vs TAP
Time to oral fluids (days)	1.6 ±0.1	1.4 ±0.2	1.0 ±0.1	0.41	<0.001	0.07
Time to normal diet (days)	3.2 ±0.3	2.8 ±0.3	2.2 ±0.1	0.41	0.01	0.02

PCA = patient controlled analgesia; TAP = transversus abdominis plane

correlate with earlier discharge; again, the non-significant trends noted might represent a lack of study power or other unmeasured factors.

The decade following the inception of TAP blockade has seen a growing body of evidence appraise its efficacy in a large range of patients and procedures, its methods of action and variants of technique. Fourteen clinical studies have assessed its analgesic effect in major abdominal surgery,<sup>22,27–32</sup> laparoscopic cholecystectomy and open appendectomy,<sup>25,33,34</sup> and abdominoplasty.<sup>35,36</sup> Furthermore, it has been used in neonates,<sup>37</sup> renal transplantation,<sup>38</sup> major abdominal flaps<sup>39</sup> and open prostatectomy.<sup>40</sup>

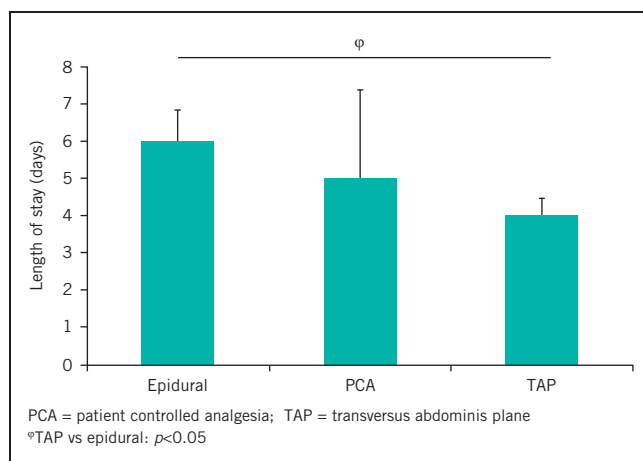
Three RCTs in obstetric and gynaecological surgery found no benefit with TAP block.<sup>27–29</sup> However, two used supplementary intrathecal morphine.<sup>28,29</sup> This is of particular interest as this modality has been shown to reduce postoperative pain and opioid requirements although not secondary functional outcomes such as mobility, gut function and opioid side effects.<sup>41</sup> By contrast, seven other RCTs found significant opioid sparing effects (ranging from 33% to 77%).<sup>22,25,25,31–34</sup> Two meta-analyses have been performed.<sup>21,26</sup> Siddiqui *et al* included four RCTs,<sup>22,25,31,32</sup> and demonstrated that TAP blocks conferred an opioid sparing effect and that opioids were required later.<sup>21</sup> Petersen *et al* included seven RCTs<sup>22,25,30–34</sup> and demonstrated overall opioid reduction of 22%.<sup>26</sup> While not all studies have assessed opioid side effects, reductions in

postoperative nausea and vomiting,<sup>42,43</sup> antiemetic requirement<sup>30,34</sup> and sedation<sup>22,31,32</sup> have been demonstrated. Nausea alone was appraised by Siddiqui *et al* but no significant reduction was found.<sup>21</sup>

This period has also seen an evidence base advocating enhanced or accelerated recovery programmes. These programmes seek to minimise the surgical stress response and expedite functional return.<sup>8,43–46</sup> Pain control is an integral facet of such programmes, not only facilitating mobility and return to diet but also minimising the metabolic and neuro-endocrine response to surgery, and its impact on organ function and recovery. Despite the thoracic epidural having enjoyed the status of ‘gold standard’, both in and outside of enhanced recovery programmes, the specific role in colorectal surgery has been questioned. Epidural analgesia inevitably incurs additional costs in patient management and this, combined with the perceived small clinical benefits, means that many units routinely use opioid analgesia in preference. Nevertheless, since both epidural and opioid analgesia may impede the progression of patients through enhanced recovery programmes, an opioid or epidural sparing role for TAP blocks would be valuable.

Two studies assessing such a role have provided encouragement. Zafar *et al* showed that TAP block for laparoscopic left and right-sided colonic resections was associated with earlier return to diet and discharge than PCA or epidural.<sup>24</sup> Conaghan *et al* demonstrated that the opioid sparing effect seen in open resections were replicated in laparoscopic surgery.<sup>25</sup> Interestingly, subgroup analysis showed less effect for right-sided resections, perhaps owing to the higher port site straying outside the territory of the TAP block. Our findings corroborate these benefits, suggesting that routine consideration of TAP blockade in laparoscopic and enhanced colorectal practice may become commonplace, certainly in those patients treated previously with PCA alone. Such routine use will most likely also be practical, efficacious and efficient; TAP blocks carry minimal time, resource and financial costs. The evolving evidence base demonstrating clinically significant effects is also reinforced by an excellent safety profile.

The original technique involved a tactile landmark-based procedure via the lumbar triangle of Petit (bounded by the iliac crest, the anterior border of latissimus dorsi and the posterior edge of external oblique). However, the triangle is highly variable in site and presence.<sup>19,47,48</sup> Consequently, the ultrasonography guided technique was described.<sup>49</sup> Other technical variants include a ‘multiple injection’



**Figure 6** Mean length of hospital stay



technique and continuous infusion via a subcutaneous catheter.<sup>50–52</sup> The landmark technique, albeit running a marginally higher risk of significant visceral injury,<sup>53,54</sup> blocks the T7 and T8 dermatomes more reliably than ultrasonography guided blocks,<sup>22,49</sup> perhaps reflecting sites of injection.<sup>55</sup> Posteromedial spread outside the TAP has also been hypothesised to possibly affect visceral afferents, a property that might prove particularly useful in colorectal surgery.<sup>22</sup> A further potential mechanism of action relates to significant rises in serum local anaesthetic agent concentration.<sup>42,46</sup>

While the TAP block is often restricted by its one-off use at the end of a procedure, these most recent developments show promise. The permutations of initial TAP block technique may potentially be tailored to individual procedures and port placements. Moreover, the role of continuous TAP infusion merits further exploration.

Our study does have a number of limitations, in addition to its retrospective observational nature and small population size. There are a number of factors that we were unable to compare, including the use of oral opioid analgesia alone and other variables associated with enhanced and accelerated recovery programmes (such as time to removal of urinary catheter, mobilisation and return to diet). Furthermore, although there were no differences in extraction site between the groups, this is a potential confounding factor. Different port/extraction sites have been shown to respond differently to TAP blockade<sup>25</sup> and those sites best suited have yet to be determined. However, despite the small sample size, a statistically significant difference was still seen across a number of parameters.

## Conclusions

Our study has demonstrated that the use of perioperative bilateral TAP blockade in laparoscopic high anterior resection is associated with superior pain control and a reduction in postoperative morphine usage when compared with PCA alone. An earlier return of bowel function was also demonstrated for TAP block patients, compared with both PCA and epidural groups, and TAP block patients had a shorter hospital stay than the epidural group. While we acknowledge the inherent limitations of this study, these results add to the growing suggestion that TAP blocks may have an important role in augmenting enhanced colorectal recovery programmes. The question regarding the nature of this role shall be answered more completely by those RCTs recruiting currently.

## Acknowledgement

The authors wish to thank Elaine Small for help in data collection.

## References

- Capdevila X, Barthelet Y, Biboulet P *et al.* Effects of perioperative analgesic technique on the surgical outcome and duration of rehabilitation after major knee surgery. *Anesthesiology* 1999; **91**: 8–15.
- Kehlet H. Surgical stress: the role of pain and analgesia. *Br J Anaesth* 1989; **63**: 189–195.

- Kehlet H. Anesthetic technique and surgical convalescence. *Acta Chir Scand Suppl* 1989; **550**: 182–188.
- Melzack R, Katz J. Pain Measurements in Persons in Pain. In: Wall PD, Melzack R. *Textbook of Pain*. 4th edn. Edinburgh: Churchill Livingstone; 1999.
- Warfield CA, Kahn CH. Acute pain management. Programs in US hospitals and experiences and attitudes among US adults. *Anesthesiology* 1995; **83**: 1,090–1,094.
- Walder B, Schafer M, Henzi I, Tramèr MR. Efficacy and safety of patient-controlled opioid analgesia for acute postoperative pain. A quantitative systematic review. *Acta Anaesthesiol Scand* 2001; **45**: 795–804.
- Jørgensen H, Wetterslev J, Møiniche S, Dahl JB. Epidural local anaesthetics versus opioid-based analgesic regimens on postoperative gastrointestinal paralysis, PONV and pain after abdominal surgery. *Cochrane Database Syst Rev* 2000; **4**: CD001893.
- Kehlet H, Wilmore DW. Evidence-based surgical care and the evolution of fast-track surgery. *Ann Surg* 2008; **248**: 189–198.
- Finnerty O, Carney J, McDonnell JG. Trunk blocks for abdominal surgery. *Anaesthesia* 2010; **65**(Suppl 1): 76–83.
- Werawatganon T, Charuluxanun S. Patient controlled intravenous opioid analgesia versus continuous epidural analgesia for pain after intra-abdominal surgery. *Cochrane Database Syst Rev* 2005; **1**: CD004088.
- Rigg JR, Jamrozik K, Myles PS *et al.* Epidural anaesthesia and analgesia and outcome of major surgery: a randomised trial. *Lancet* 2002; **359**: 1,276–1,282.
- Wijesundera DN, Beattie WS, Austin PC *et al.* Epidural anaesthesia and survival after intermediate-to-high risk non-cardiac surgery: a population-based cohort study. *Lancet* 2008; **372**: 562–569.
- Peyton PJ, Myles PS, Silbert BS *et al.* Perioperative epidural analgesia and outcome after major abdominal surgery in high-risk patients. *Anesth Analg* 2003; **96**: 548.
- Park WY, Thompson JS, Lee KK. Effect of epidural anesthesia and analgesia on perioperative outcome: a randomized, controlled Veterans Affairs cooperative study. *Ann Surg* 2001; **234**: 560–569.
- Gould TH, Grace K, Thorne G, Thomas M. Effect of thoracic epidural anaesthesia on colonic blood flow. *Br J Anaesth* 2002; **89**: 446–451.
- Lassen K, Soop M, Nygren J *et al.* Consensus review of optimal perioperative care in colorectal surgery. *Arch Surg* 2009; **144**: 961–969.
- Bode RH, Lewis KP, Zarich SW *et al.* Cardiac outcome after peripheral vascular surgery. *Anesthesiology* 1996; **84**: 3–13.
- Rozen WM, Tran TM, Ashton MW *et al.* Refining the course of the thoracolumbar nerves: a new understanding of the innervation of the anterior abdominal wall. *Clin Anat* 2008; **21**: 325–333.
- Rafi AN. Abdominal field block: a new approach via the lumbar triangle. *Anaesthesia* 2001; **56**: 1,024–1,026.
- Barrington MJ, Watts SA, Gledhill SR *et al.* Preliminary results of the Australasian Regional Anaesthesia Collaboration: a prospective audit of more than 7000 peripheral nerve and plexus blocks for neurologic and other complications. *Reg Anesth Pain Med* 2009; **34**: 534–541.
- Siddiqui MR, Sajid MS, Uncles DR *et al.* A meta-analysis on the clinical effectiveness of transversus abdominis plane block. *J Clin Anesth* 2011; **23**: 7–14.
- McDonnell JG, O'Donnell B, Curley G *et al.* The analgesic efficacy of transversus abdominis plane block after abdominal surgery: a prospective randomized controlled trial. *Anesth Analg* 2007; **104**: 193–197.
- Conaghan P, Maxwell-Armstrong C, Bedford N *et al.* Efficacy of transversus abdominis plane blocks in laparoscopic colorectal resections. *Surg Endosc* 2010; **24**: 2,480–2,484.
- Zafar N, Davies R, Greenslade GL, Dixon AR. The evolution of analgesia in an 'accelerated' recovery programme for resectional laparoscopic colorectal surgery with anastomosis. *Colorectal Dis* 2008; **12**: 119–124.
- El-Dawlatly AA, Turkistani A, Kettner SC *et al.* Ultrasound-guided transversus abdominis plane block: description of a new technique and comparison with conventional systemic analgesia during laparoscopic cholecystectomy. *Br J Anaesth* 2009; **102**: 763–767.
- Petersen PL, Mathiesen O, Torup H, Dahl JB. The transversus abdominis plane block: a valuable option for postoperative analgesia? A topical review. *Acta Anaesthesiol Scand* 2010; **54**: 529–535.
- Griffiths JD, Middle JV, Barron FA *et al.* Transversus abdominis plane block does not provide additional benefit to multimodal analgesia in gynecological cancer surgery. *Anesth Analg* 2010; **111**: 797–801.
- Kanazi GE, Aouad MT, Abdallah FW *et al.* The analgesic efficacy of subarachnoid morphine in comparison with ultrasound-guided transversus

- abdominis plane block after cesarean delivery: a randomized controlled trial. *Anesth Analg* 2010; **111**: 475–481.
29. Costello JF, Moore AR, Wiecek PM *et al.* The transversus abdominis plane block, when used as part of a multimodal regimen inclusive of intrathecal morphine, does not improve analgesia after cesarean delivery. *Reg Anesth Pain Med* 2009; **34**: 586–589.
30. Belavy D, Cowlishaw PJ, Howes M, Phillips F. Ultrasound-guided transversus abdominis plane block for analgesia after Caesarean delivery. *Br J Anaesth* 2009; **103**: 726–730.
31. McDonnell JG, Curley G, Carney J *et al.* The analgesic efficacy of transversus abdominis plane block after cesarean delivery: a randomized controlled trial. *Anesth Analg* 2008; **106**: 186–191.
32. Carney J, McDonnell JG, O'hana A *et al.* The transversus abdominis plane block provides effective postoperative analgesia in patients undergoing total abdominal hysterectomy. *Anesth Analg* 2008; **107**: 2,056–2,060.
33. Carney J, Finnerty O, Rauf J *et al.* Ipsilateral transversus abdominis plane block provides effective analgesia after appendectomy in children: a randomized controlled trial. *Anesth Analg* 2010; **111**: 998–1,003.
34. Niraj G, Searle A, Mathews M *et al.* Analgesic efficacy of ultrasound-guided transversus abdominis plane block in patients undergoing open appendectomy. *Br J Anaesth* 2009; **103**: 601–605.
35. Gravante G, Castri F, Araco F, Araco A. A comparative study of the transversus abdominis plane (TAP) block efficacy on post-bariatric vs aesthetic abdominoplasty with flank liposuction. *Obes Surg* 2011; **21**: 278–282.
36. Araco A, Pooney J, Araco F, Gravante G. Transversus abdominis plane block reduces the analgesic requirements after abdominoplasty with flank liposuction. *Ann Plast Surg* 2010; **65**: 385–388.
37. Bielsky A, Efrat R, Suresh S. Postoperative analgesia in neonates after major abdominal surgery: 'TAP' our way to success! *Paediatr Anaesth* 2009; **19**: 541–542.
38. Mukhtar K, Khattak I. Transversus abdominis plane block for renal transplant recipients. *Br J Anaesth* 2010; **104**: 663–664.
39. West C, Milner CS. A simple modification to the transversus abdominis plane block provides safe and effective analgesia in TRAM/DIEP flap patients. *Plast Reconstr Surg* 2010; **126**: 146e–147e.
40. O'Donnell BD, McDonnell JG, McShane AJ. The transversus abdominis plane (TAP) block in open retropubic prostatectomy. *Reg Anesth Pain Med* 2006; **31**: 91.
41. Virlos I, Clements D, Beynon J *et al.* Short-term outcomes with intrathecal versus epidural analgesia in laparoscopic colorectal surgery. *Br J Surg* 2010; **97**: 1,401–1,406.
42. Kato N, Fujiwara Y, Harato M *et al.* Serum concentration of lidocaine after transversus abdominis plane block. *J Anesth* 2009; **23**: 298–300.
43. King PM, Blazeby JM, Ewings P *et al.* Randomized clinical trial comparing laparoscopic and open surgery for colorectal cancer within an enhanced recovery programme. *Br J Surg* 2006; **93**: 300–308.
44. Wille-Jørgensen P, Guenaga KF, Castro AA, Matos D. Clinical value of preoperative mechanical bowel cleansing in elective colorectal surgery: a systematic review. *Dis Colon Rectum* 2003; **46**: 1,013–1,020.
45. Brandstrup B, Tønnesen H, Beier-Holgersen R *et al.* Effects of intravenous fluid restriction on postoperative complications: comparison of two perioperative fluid regimens. *Ann Surg* 2003; **238**: 641–648.
46. Lewis SJ, Egger M, Sylvester PA, Thomas S. Early enteral feeding versus 'nil by mouth' after gastrointestinal surgery: systematic review and meta-analysis of controlled trials. *BMJ* 2001; **323**: 773–776.
47. Jankovic ZB, du Feu FM, McConnell P. An anatomical study of the transversus abdominis plane block: location of the lumbar triangle of Petit and adjacent nerves. *Anesth Analg* 2009; **109**: 981–985.
48. Loukas M, Tubbs RS, El-Sedfy A *et al.* The clinical anatomy of the triangle of Petit. *Hernia* 2007; **11**: 441–444.
49. Hebbard P, Fujiwara Y, Shibata Y, Royse C. Ultrasound-guided transversus abdominis plane (TAP) block. *Anaesth Intensive Care* 2007; **35**: 616–617.
50. Hebbard PD, Barrington MJ, Vasey C. Ultrasound-guided continuous oblique subcostal transversus abdominis plane blockade: description of anatomy and clinical technique. *Reg Anesth Pain Med* 2010; **35**: 436–441.
51. Taylor LJ, Birmingham P, Yerkes E, Suresh S. Children with spinal dysraphism: transversus abdominis plane (TAP) catheters to the rescue! *Paediatr Anaesth* 2010; **20**: 951–954.
52. Barrington MJ, Ivanusic JJ, Rozen WM, Hebbard P. Spread of injectate after ultrasound-guided subcostal transversus abdominis plane block: a cadaveric study. *Anaesthesia* 2009; **64**: 745–750.
53. Lancaster P, Chadwick M. Liver trauma secondary to ultrasound-guided transversus abdominis plane block. *Br J Anaesth* 2010; **104**: 509–510.
54. Farooq M, Carey M. A case of liver trauma with a blunt regional anesthesia needle while performing transversus abdominis plane block. *Reg Anesth Pain Med* 2008; **33**: 274–275.
55. Tran TM, Ivanusic JJ, Hebbard P, Barrington MJ. Determination of spread of injectate after ultrasound-guided transversus abdominis plane block: a cadaveric study. *Br J Anaesth* 2009; **102**: 123–127.