CASE REPORT

Characteristics of 22q 11.2 deletion syndrome undiagnosed until adulthood: an example suggesting the importance of psychiatric manifestations

Kenta Furuya, Yosuke Sasaki, Taizo Takeuchi, Yoshihisa Urita

Department of General Medicine and Emergency Care, Toho University School of Medicine, Ota-Ku, Tokyo, Japan

Correspondence to
Dr Yosuke Sasaki, pqrstbb@yahoo.co.jp

Accepted 26 May 2015

SUMMARY

Patients with chromosome 22q11.2 deletion syndrome (22q11.2DS) exhibit various combinations of signs and symptoms including facial dysmorphism, thymus absence, hypoparathyroidism, cellular immunodeficiency and cardiac abnormalities caused by microdeletion of chromosome 22q11.2. Most cases are diagnosed during post-natal cardiac evaluation, though some are diagnosed at later stages. We report the case of a 39-year-old man with 22q11.2DS presenting with seizure due to tardily manifested hypocalcaemia and anxiety disorder. Our experience suggests that 22q11.2DS patients lacking fatal or well-recognised manifestations such as cardiac defects, immunodeficiency and facial dysmorphism tend to survive without medical attention, and are therefore overlooked. Recognition of the age-related variance of the manifestations, and specifically of tardily manifested hypocalcaemia and psychiatric or developmental disorders as manifestations of 22q11.2DS in adulthood, is important for diagnosis and can also help us provide appropriate medical and psychosocial support for newly diagnosed 22q11.2DS patients in adolescence or adulthood and their families.

BACKGROUND

Chromosome 22q11.2 deletion syndrome (22q11.2DS) is the most common of the microdeletion disorders characterised by various combinations of facial dysmorphism, thymus absence, hypoparathyroidism, mental impairment, cellular immunodeficiency and cardiac abnormalities. It is caused by hemizygous deletion of chromosome 22q11.2, which reportedly occurs in 1 in 4000 live births.[1] The clinical manifestations of 22q11.2DS are subject to wide interindividual variance and age-related changes. Since most cases are diagnosed by paediatricians during postnatal cardiac evaluation, the syndrome's most common manifestations in adolescence and adulthood, which include psychiatric and developmental disorders, are underrecognised by internists. Thus, cases lacking fatal or well-known symptoms such as cardiac defects or immunodeficiency can be overlooked until middle age.[2 3] We report the case of a 39-year-old man with 22q11.2DS presenting with seizure due to 'tardily manifested hypocalcaemia' and anxiety disorder. The patient had also manifested mild mental retardation and chronic hypocalcaemia many years prior to the diagnosis, but he was not diagnosed with 22q11.2DS until he developed generalised seizure, a potentially fatal sequel. Our experience suggests that patients with 22q11.2DS lacking fatal or well-recognised manifestations tend to survive without medical attention and are therefore overlooked. Recognition of the age-related variance of the manifestations, and specifically of tardily manifested hypocalcaemia and psychiatric disorders as manifestations of 22q11.2DS, is important for diagnosis and can also help us provide appropriate medical and psychosocial support for newly diagnosed 22q11.2DS patients in adolescence or adulthood.

CASE PRESENTATION

A 39-year-old man arrived at the emergency department of Toho University Omori Medical Centre by ambulance because of his first episode of generalised seizure, which had lasted for a few minutes. His present illness had started with a few episodes of painful muscle cramp of the extremities a few days prior to admission. He visited another clinic and was given intravenous fluid as a treatment for 'heat cramp'. Although the painful muscle cramps subsided after hydration, later that night, while he was carrying dishes to the table for supper at home, he suddenly fell to the floor and developed generalised clonic seizure. His mother and sister witnessed that the seizure was symmetric and spontaneously stopped after a few minutes of jerking. After the episode, he resumed responding to his family and could move all extremities, but looked apathetic and did not appear to track his mother's face. His family immediately called the ambulance and the patient was brought to our department. He gradually became more alert during the transfer. The patient was already being followed up at the Department of Psychosomatic Medicine for an anxiety disorder and at the Department of Nephrology for chronic kidney disease, probably due to nephrosclerosis, which had been ongoing for the past 4 years. His medical history was also remarkable for cerebellar development disorder and for chronic asymptomatic hypocalcaemia, with calcium levels as low as 5 mg/dL, which had not been evaluated or medically treated prior to his admission to our emergency department. He regularly took ethyl loflazepate 2.0 mg, lorazepam 0.5 mg and paroxetine 12.5 mg. His family history was unremarkable. As regards

To cite: Furuya K, Sasaki Y, Takeuchi T, *et al*. *BMJ Case Rep* Published online: [*please include* Day Month Year] doi:10.1136/bcr-2014-208903

developmental and psychiatric history, the patient had delayed speech in infancy and was diagnosed with cerebellar development disorder between the ages of three and four. Although his paediatricians noted the possibility of a learning disability at that time, he was able to receive general education from nursery school through middle school. After graduation, he started working for a laundry company and got married. He maintained his occupational and marital status without any trouble. He started to complain of hoarseness, dyspnoea and chest discomfort 10 years earlier, and was diagnosed with anxiety disorder 8 years earlier.

INVESTIGATIONS

On arrival, the patient was alert and cooperative. His blood pressure was 154/76 mm Hg, heart rate was 73 bpm and regular, respiration rate was 21 breaths per minute and body temperature was 36.6°C. His face was remarkable for ocular hypertelorism and a button-shaped nose, but there was no evidence of trauma, bleeding, burns or bite wounds (figure 1). Cardiopulmonary, abdominal and extremity examinations were all unremarkable. Neurological examinations were normal except for dysarthria and hoarseness, which had been observed previously, and poor coordination of the right lower limb. Both Chvostek sign and Trousseau sign were negative.

Laboratory analysis (table 1) was remarkable for hypocalcaemia (corrected serum calcium 4.4 mg/dL), elevated serum lactate (3.6 mmol/L) and elevated creatinine kinase (1263 IU/L). Electrocardiogram showed normal sinus rhythm with prolonged QT interval (QTc 473 ms). Continuous electrocardiogram monitoring recorded no arrhythmia. Although a CT scan of the head revealed no signs of cerebrovascular disease, it did reveal a characteristic symmetric calcification at the bilateral basal ganglia and atrophy of the cerebellar vermis (figure 2). We determined that both the first episode of provoked generalised seizure and the muscle cramps had developed due to hypocalcaemia, and immediately started treatment to correct it. Additional laboratory data revealed low serum intact-PTH (5.0 pg/mL) and 1,25-$(OH)_2$ vitamin D (88 pg/mL), which suggested primary hypoparathyroidism. Serum TSH was 0.58 μIU/L. Transthoracic echocardiogram showed no sings of congenital cardiac anomalies such as ventricular septal defect. Despite the lack of any congenital cardiac anomaly or hypothyroidism, we submitted a blood sample for fluorescence in situ hybridisation (FISH) with suspicion of 22q11.2 deletion syndrome because of the combination of primary hypoparathyroidism, characteristic dysmorphic face, cerebellar development disorder and psychiatric disease. FISH of the patient's blood sample showed microdeletion of chromosome 22q11.2, which confirmed the diagnosis of 22q11.2 deletion syndrome. Further evaluations revealed comorbid cataract and otosclerosis.

Figure 1 Ocular hypertelorism (double arrow) and a button-shaped nose (circle) were detected on facial examination.

TREATMENT

After intravenous correction of hypocalcaemia, serum calcium increased to around 9–10 mg/dL and remained above 9 mg/dL after discontinuation of intravenous correction with concurrent oral administration of calcium lactate 4 g two times a day and 0.5 μg of calcitoriol.

OUTCOME AND FOLLOW-UP

The patient was discharged after 2 weeks of hospitalisation and has been successfully treated at our outpatient clinic, maintaining serum calcium around 8–10 mg/dL. His chronic hoarseness improved. He has developed no further seizures or muscle cramps. He is also under active ophthalmological and otological follow-up.

Table 1 Laboratory data

WCC (μL)	12 600
Hb (g/dL)	13.3
Ht (%)	39.3
Platelet (10^4/μL)	18.4
Sodium (mM)	143
Potassium (mM)	3.7
Chloride (mM)	101
Calcium (mg/dL)	4.0
Phosphorus (mg/dL)	7.1
Magnesium (mg/dL)	1.5
BUN (mg/dL)	20
Creatinine (mg/dL)	1.41
Glucose (mg/dL)	108
Alb (g/dL)	3.6
AST (U/L)	30
ALT (U/L)	17
LDH (U/L)	562
ALP (U/L)	208
γ-GTP (U/L)	17
CK (U/L)	1263
1,25(OH)2・VD(pg/mL)	88
25-(OH)・VD (ng/mL)	21
PTH-intact (pg/mL)	5
PTH-whole (pg/mL)	<4.0
TSH (μg/mL)	0.58

Alb, albumin; ALP, alkaline phosphatase; ALT, alanine aminotransferase; AST, aspartate aminotransferase; BUN, blood urea nitrogen; CK, creatine kinase; γ-GTP, γ-glutamyl transpeptidase; Hb, haemoglobin; Ht, haematocrit; LDH, lactate dehydrogenase, PTH, parathyroid hormone; TSH, thyroid-stimulating hormone; WCC, white cell count.

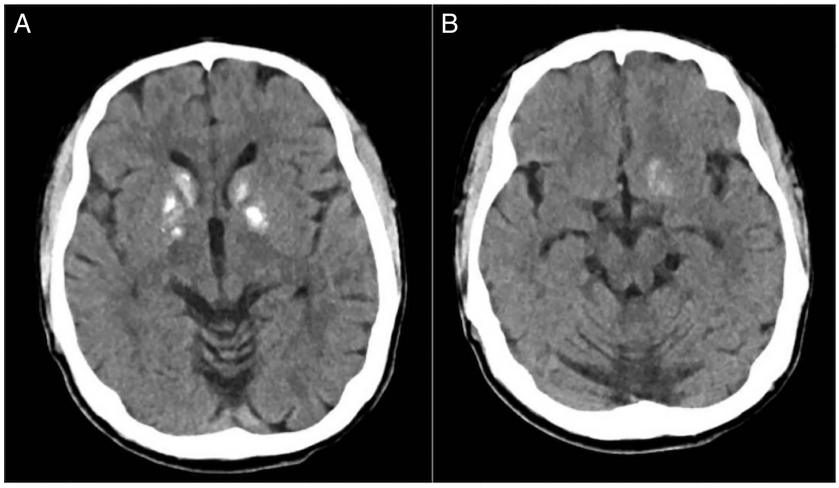

Figure 2 Brain CT scan on admission showed basal ganglia calcification (A) and atrophy of the cerebellar vermis (B).

DISCUSSION

The microdeletion of 22q11.2, the aetiology of 22q11.2DS, causes the loss of 35 genes and may result in more than 180 symptoms.[3] Once suspected, the diagnosis is rather straightforward, as FISH analysis enables genetic confirmation of the diagnosis.[4] In some cases, however, interindividual variance and age-related changes in signs and symptoms make diagnosis difficult. Here, we will discuss various classic symptoms (cardiac defects; hypocalcaemia; neuropsychiatric symptoms), age-related changes of prominent symptoms and the psychiatric manifestations associated with 22q11.2DS in order to promote the correct diagnosis of 22q11.2DS patients who have remained undiagnosed until adulthood.

The existence of variation in the nomenclature used to describe 22q11.2DS may be explained by the wide variation in the signs and symptoms of the syndrome. DiGeorge syndrome, velocardiofacial syndrome, CHARGE syndrome and conotruncal abnormal face syndrome, all indicate different patterns of signs and symptoms that are caused by 22q11.2DS.[5 6]

Congenital heart defects, including tetralogy of Fallot, aortic arch anomalies, atrial septal defects and ventricular septum defects, are the major causes of mortality in this syndrome and have been reported in 70% of all cases of 22q11.2DS; their prevalence, however, decreases with the patient's age and is reported in less than 30% of adult cases.[7] The existence of these congenital cardiac defects may itself explain their lower prevalence in adult patients, as patients with potentially fatal cardiac defects seldom survive until adulthood.

Hypoparathyroidism in 22q11.2DS is caused by aplasia and hypoplasia of the parathyroid glands,[8] and occurs in 65% of patients.[9] Hypocalcaemia frequently manifests during the neonatal period; in adults, in contrast, hypocalcaemia is a rare finding.[8 10 11] As with cardiac defects, the potential fatality of hypocalcaemia, especially with regard to its link with generalised seizure, may explain its lower prevalence in adults, as patients with severe hypocalcaemia tend to develop fatal seizures early in life.

Tardily manifested hypocalcaemia, which occurs due to the loss of compensation through reactive parathyroidal hypertrophy, may explain the late onset of seizure provoked by hypocalcaemia in the present case.[12] The onset and severity of hypocalcaemia is apparently affected by a complicated network of mechanisms, including hypocalcaemic stresses (surgery, infection or trauma[13 14]), autoantibodies against calcium-sensing receptors[15] and compensatory parathyroidal hypertrophy. Neonatal hypocalcaemia in 22q11.2DS generally improves over the first year of life as the parathyroid glands hypertrophy; accordingly, older patients have survived this stressful period and rarely require ongoing calcium supplementation. However, increased demand for PTH due to adolescence, pregnancy or external stresses can exceed the capacity for compensation through parathyroidal hypertrophy, causing symptomatic hypocalcaemia.

Hypocalcaemia can cause various neuropsychiatric symptoms including seizures, altered mental status, delusions, hallucinations, psychosis, depression, dementia and parkinsonism.[16] Seizure is seen in 20–25% of patients with acute hypocalcaemia, and in 30–70% of patients with symptomatic hypoparathyroidism, respectively.[17] Given that anticonvulsants can aggravate hypocalcaemia,[18] diagnosis of hypocalcaemia as a cause of seizure is critical.

The central nervous system manifestations of 22q11.2DS include structural defects such as microcephaly, functional aspects such as impulsivity and bland affects. Our patient presented both structural defects and functional manifestations, namely, cerebellar hypoplasia, cerebral calcification and anxiety disorder. Cerebral calcifications are relatively common in hypoparathyroidism and their aetiology has not been completely elucidated. They may be related to the duration of hypocalcaemia and hyperphosphataemia.[19]

It is important to recognise the changes in the prominent symptoms that are associated with different ages and life stages. Most patients are diagnosed with the syndrome shortly after birth because of congenital cardiac defects. As patients grow older without being diagnosed, however, cellular immunodeficiency, intestinal malrotation and hypocalcaemia can lead to severe morbidity. In school-age patients, learning disabilities and feeding difficulties become problematic. Behavioural issues are more likely to emerge with increasing age, and frank psychiatric disorders are seen in teenagers and adults: 10–30% of older patients experience bipolar disorder or schizophrenia/schizoaffective disorder. The risk of psychiatric disturbances is significantly elevated in this syndrome.[5]

As stated above, once 22q11.2DS is suspected, genetic confirmation is rather straightforward. 22q11.2 microdeletion is conventionally confirmed by FISH. However, most institutes currently use array comparative genomic hybridisation (CGH) to detect all chromosome imbalances. As concurrent chromosome imbalance is a real possibility, array CGH as a method of confirming 22q11.2DS is recommended for all cases, though we did not use it for the present patient.

Considering 22q11.2DS as a differential diagnosis whenever it is possible is the key to successful diagnosis. Yet although psychiatric and developmental disorders are common in 22q11.2DS, as mentioned above, our report and previous reports suggest that

patients with 22q11.2DS without fatal or well-recognised manifestations tend to survive without medical attention and are therefore overlooked, remaining undiagnosed until fatal consequences develop.[2 3] Although these patients can be regarded as mildly manifesting cases, appropriate detection and diagnosis is important, not only to prevent potentially fatal sequels such as seizures and chronic sequels due to hypoparathyroidism, but also to make medical and psychosocial support available to patients. Furthermore, given the familial predisposition, early diagnosis benefits patients' families.[5 20] In addition to the classic manifestations such as cardiac defects and facial dysmorphism, recognition of age-related changes in manifestations, and especially the predominance of tardily manifested hypocalcaemia and psychiatric disorders as manifestations of 22q11.2DS in adulthood, is important to diagnose 22q11.2DS at all ages.

Patient's perspective

"Because I had no idea that I was suffering from a rare congenital disorder, I am very happy that the physicians diagnosed my disease. I am feeling much better after the treatment. For example, my hoarseness was improved after taking the prescription." The patient's mother added that she was pleased that the aetiology of his delayed speech in infancy and cerebellar development disorder was revealed and that now he would obtain appropriate medical support based on the diagnosis (Translated by the first author).

Learning points

- Chromosome 22q11.2 deletion syndrome (22q11.2DS) individuals without fatal or well-known symptoms such as cardiac defects, facial dysmorphism or immunodeficiency can be overlooked until adulthood because prominent manifestation in adolescence and adulthood are under-recognised.
- It is important to diagnose mildly manifesting cases of 22q11.2DS because accurate diagnosis provides medical and psychosocial benefits to the patients and their families.
- Recognising age-related changes in prominent manifestations may be the clue to detecting 22q11.2DS in patients who have remained undiagnosed until adulthood.
- Psychiatric disorders can be prominent manifestations of 22q11.2DS in cases diagnosed in adulthood.
- Tardily manifested hypocalcaemia due to 22q11.2DS should be considered in adult patients with hypocalcaemia.

Contributors KF and YS managed the patient and wrote the manuscript. TT managed the patient with KF and YS, and contributed to the manuscript by searching for and reviewing some of the articles we cited. YU reviewed the manuscript and gave some important advice on discussion. All authors substantially contributed to the article.

Competing interests None declared.

Patient consent Obtained.

Provenance and peer review Not commissioned; externally peer reviewed.

REFERENCES

1 Scrambler P. The 22q 11.2 deletion syndromes. *Hum Med Genet* 2000;9:2421–6.
2 Hirotani A, Moromoto S, Koe E, *et al*. Partial DiGeorge syndrome at the age of thirty-four. *Intern Med* 1994;33:418–21.
3 Sasaki Y, Obara H, Shimabukuro A. A 32-year-old woman diagnosed with 22q 11.2 deletion syndrome and complicated by hypothyroidism. *Gen Med* 2014;15:72–5.
4 Ryan A, Goodship J, Wilson D, *et al*. Spectrum of clinical features associated with interstitial chromosome 22q 11.2 deletions: a European collaborative study. *J Med Genet* 1997;34:798–804.
5 Sullivan KE. Chromosome 22q 11.2 deletion syndrome: DiGeorge syndrome/velocardiofacial syndrome. *Immunol Allergy Clin N Am* 2008;28:353–66.
6 McDonald-McGinn D, Sullivan K. Chromosome 22q 11.2 deletion syndrome (Digeorge syndrome/velocardiofacial syndrome). *Medicine (Baltimore)* 2011;90:1–18.
7 Bassett AS, Chow EWC, Husted J, *et al*. Clinical features of 78 adults with 22q11 deletion syndrome. *Am J Med Genet A* 2005;138:307–13.
8 Greig F, Paul E, DiMartino-Nardi J, *et al*. Transient congenital hypoparathyroidism: resolution and recurrence in Chromosome 22q 11.2 deletion. *J Pediatr* 1996;128:563–7.
9 Driscoll D. Prenatal diagnosis of the 22q 11.2 deletion syndrome. *Genet Med* 2001;3:14–18.
10 Van Den Berg K, Diderich K, Poddighe P, *et al*. A symptomatic hypoparathyroidism based on a 22q 11.2 deletion first diagnosed in a 43-year old woman. *Neth J Med* 2009;67:102–4.
11 Shea Y, Lee C, Gill H, *et al*. Delayed diagnosis of 22q11.2 deletion syndrome in an adult Chinese lady. *Chin Med J (Engl)* 2012;125:2945–7.
12 Brown E. Anti-parathyroid and anti-calcium sensing receptor antibodies in autoimmune hypoparathyroidism. *Endocrinol Metab Clin North Am* 2009;38:437–45.
13 Garabedian M. Hypocalcemia and Chromosome 22q 11.2 microdeletion. *Genet Couns* 1999;10:389–94.
14 Cuneo B, Langman C, Ilbawi M, *et al*. Latent hypoparathyroidism in children with conotruncal cardiac defects. *Circulation* 1996;93:1702–8.
15 Fujita T. Mechanism of intracerebral calcification in hypoparathyroidism. *Clin Calcium* 2004;15:55–7.
16 Riggs J. Neurological manifestations of electrolyte disturbances. In: Aminoff MJ ed. *Neurology and general medicine*. 3rd edn. Philadelphia: Churchill Livingstone, 2011:307–16.
17 Castilla-Guerra L, Del Carmen Fernandez-Moreno M, Lopez-Chozas J, *et al*. Electrolytes disturbances and seizures. *Epilepsia* 2006;47:1900–8.
18 Valsamis H, Arora S, Labban B, *et al*. Antiepileptic drugs and bone metabolism. *Nutr Metab (London)* 2006;3:36.
19 Bilezikian J, Khan A, Potts J, *et al*. Hypoparathyroidism in the adult: epidemiology, diagnosis, pathophysiology, target organ involvement, treatment, and challenges for future research. *J Bone Miner Res* 2011;10:2317–37.
20 Kar PS, Ogoe B, Poole R, *et al*. Di-George syndrome presenting with hypocalcaemia in adulthood: two case reports and a review. *J Clin Pathol* 2005;58:655–7.

Copyright 2015 BMJ Publishing Group. All rights reserved. For permission to reuse any of this content visit http://group.bmj.com/group/rights-licensing/permissions.
BMJ Case Report Fellows may re-use this article for personal use and teaching without any further permission.

Become a Fellow of BMJ Case Reports today and you can:
- Submit as many cases as you like
- Enjoy fast sympathetic peer review and rapid publication of accepted articles
- Access all the published articles
- Re-use any of the published material for personal use and teaching without further permission

For information on Institutional Fellowships contact consortiasales@bmjgroup.com

Visit casereports.bmj.com for more articles like this and to become a Fellow