CASE REPORT

ECG artefacts mimicking atrial flutter in posterior fossa surgery

Priya Rudigwa, Lenin Babu Elakkumanan, Sakthi Rajan P, M V Satya Prakash

Department of Anaesthesiology and Critical Care, JIPMER, Puducherry, India

Correspondence to
Dr Munaganuri Satya Prakash, munaganuri1975@yahoo.co.in

Accepted 26 February 2015

SUMMARY

ECG artefacts are defined as abnormalities in the monitored ECG, which result from measurement of cardiac potentials on the body surface and are not related to the electrical activity of the heart. In the operation theatre, the use of various types of electrical equipment may interfere with ECG interpretation. We describe our experience with artefacts resembling atrial fibrillation when a nerve integrity monitoring device was used on a patient undergoing posterior fossa surgery for epidermoid tumour. These artefacts resemble serious arrhythmias and may result in unwanted interventions. To enable better identification of such artefacts, a 12-lead ECG should be considered as it will display rhythm in all the leads; while artefacts will present in only a few leads, true arrhythmia will be present in all the 12 leads. Our case report aims to increase awareness regarding ECG artefacts and to explain how to distinguish them from actual arrhythmias.

BACKGROUND

Intraoperative nerve monitoring systems are commonly used in neurosurgical procedures to locate various nerves and to confirm and preserve their integrity in the operative field. This type of monitoring involves placement of multiple electromyography (EMG) needle electrodes in the muscles of interest and continuous recording of muscle fasciculation on stimulating the corresponding nerve. The EMG recordings are indirect markers of the integrity of the innervating nerve. These recordings are displayed visually and also in the form of auditory signals. A stimulating probe is used to localise the nerve intraoperatively. We report an incident where intraoperative nerve monitoring stimulator probe resulted in ECG artefacts even when not in use. The knowledge that such ECG changes can occur with usage of this monitoring device can be especially helpful for anaesthesiologists in the intraoperative period. The nerve monitor used was a MedtronicNIM (nerve integrity monitor) 3 Neuro system. The device manufacturer's manual has warnings regarding the occurrence of artefacts in the ECG trace due to stimulus current delivery or impedance monitoring.

CASE PRESENTATION

A 34-year-old woman, American Society of Anesthesiologists class 1, was undergoing surgery for excision of left cerebellopontine angle epidermoid tumour under general anaesthesia. Her preoperative ECG strip showed normal sinus rhythm and there was no history of cardiac disease or arrhythmia. An ECG was monitored through lead II and V5 on a Datex-Ohmeda S/5 monitor. Neither of the leads showed abnormal ECG findings while the site was being prepared and draped for surgery. On the start of surgery, the patient's chest lead V5 showed an ECG pattern similar to that of an atrial flutter (figure 1). Similar artefacts were seen in all except lead II (figure 2). An atrial flutter is a supraventricular arrhythmia caused by re-entry circuit within the right atrium. It is characterised by a typical sawtooth pattern of flutter waves at a rate of 240–440 bpm and ventricular rate depending on the degree of conduction block. A typical atrial flutter involves inferior vena cava and tricuspid isthmus in the circuit with flutter waves best seen in leads II, III and aVF, but an atypical flutter may not fulfil criteria for a typical flutter. The pattern observed in our case did not have the characteristic sawtooth wave appearance, thus it resembled an atypical atrial flutter. The ventricular rate and morphology remained the same during this event, indicative of some atrial rhythm disturbance. During this event, hemodynamic parameters were stable and no correlating changes were observed in arterial waveform and plethysmographic trace. After ruling out other causes of artefacts, such as improper lead attachment, cable breakage and electromagnetic interference, the artefact still persisted. As all other causes were excluded, we requested the surgeon to remove the stimulating probe placed on the chest drapes. Once the stimulating needle was removed, the ECG rhythm reverted to normal and reappeared on replacing the needle. A 12-lead ECG could not be taken at the time as the patient had sterile surgical drapes.

DISCUSSION

ECG remains the basic standard of care in the operating room.[1] In today's era of ever increasing modalities of monitoring, ECG signals are more susceptible to interference. With the improvement in technology, better devices with minimal distortion of readings are available but interference with ECG tracing remains an issue. Various external causes of ECG artefacts are poor skin contact of electrodes, dried gel, damaged cables and electromagnetic interference.[2] Internal causes can be due to tremors, muscle shivering, hiccups and implanted electrostimulation devices.[3] As the ECG records micropotentials generated by the heart it also detects electrical activity generated or induced by skeletal muscle, cardiac pacemakers, MRI and improperly earthed electrical equipment and

To cite: Rudigwa P, Babu Elakkumanan L, Rajan P S, *et al*. *BMJ Case Rep* Published online: [*please include* Day Month Year] doi:10.1136/bcr-2014-208617

Figure 1 ECG with artefact but no changes in arterial wave form.

devices.[4 5] There have been reports of artefacts resulting from a whole gamut of devices, such as transcutaneous electrical nerve stimulators (TENS), internal electrostimulators, infusion rate controllers, somatosensory evoked potential monitoring units, sinus microdebriders and various other instruments.[6–10] Thus, while interpreting ECGs in patients, awareness of artefacts mimicking genuine changes should be maintained. If these artefacts are not identified early, they may result in unnecessary panic and subject the patient to diagnostic and therapeutic interventions that may be detrimental to the patient. There have been instances where patients were administered antiarrhythmic drugs and even synchronised direct current shocks due to misinterpretation of these artefacts as arrhythmias.[11 12] In order to avoid such mishaps, one should always consider artefacts as a differential diagnosis of arrhythmias. There are various characteristics of artefacts that can be used to distinguish them from actual arrhythmias. First, occurrence of a new arrhythmia in an asymptomatic patient without any change in hemodynamic parameters and when peripheral pulse rate correlates with apical pulse should raise suspicion of an artefact.[9 13] Second, no evidence of arrhythmia in plethysmographic waveform or direct arterial pressure trace can exclude the presence of actual arrhythmia. Third, the temporal association of appearance of the artefact with usage of monitoring device and disappearance with its removal points to the presence of an artefact.[14] Fourth presence of synchronous and visible notching consistent with underlying ventricular rhythm through the pseudoarrhythmia favours the presence of an artefact over true arrhythmia.[15]

Various measures should be taken to ensure that all monitors and other electrical equipment undergo periodic maintenance for operational and electrical safety. Steps should be taken to avoid using broken leads and loose or mal positioned electrodes, and adequate skin preparation should be undertaken before placing electrodes. In procedures involving usage of somatosensory evoked potential monitoring, ECG electrodes should be positioned away from the site of stimulating electrodes.[7]

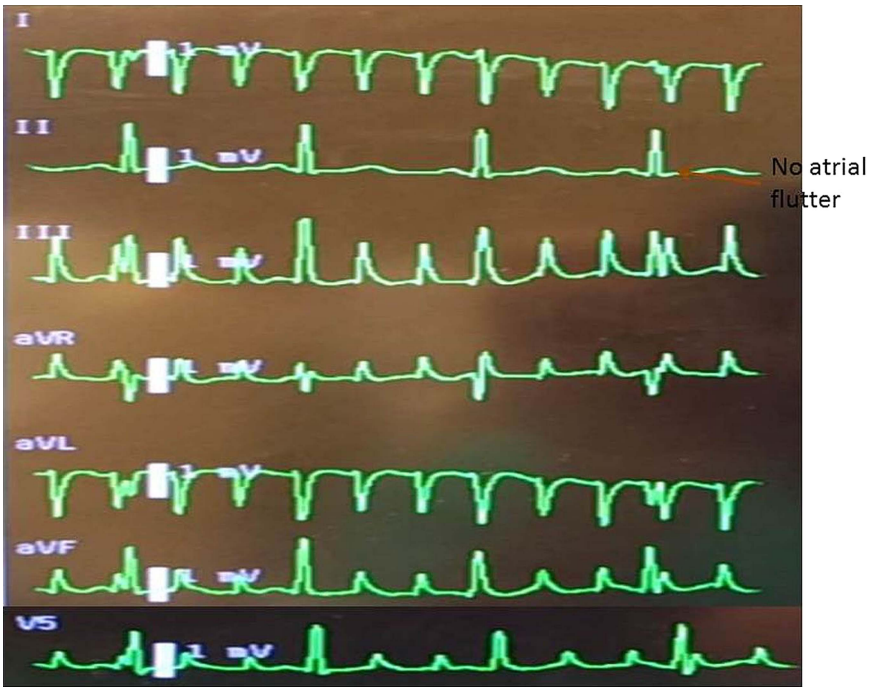

Figure 2 ECG artefact in all except lead II.

Similarly, in patients with implanted electrostimulators, pre-operative consultation with the programmer should be carried out.[16] Appropriate grounding of machines to prevent charge accumulation should be tested. Various electrical systems should be checked for compatibility before using them together.[17] In the near future, we might have sophisticated monitors without the problem of ECG interference; until then, artefacts should also be taken into consideration and ruled out before managing arrhythmias.

Learning points

- ECG artefacts should always be considered in the differential diagnosis of sudden onset arrhythmias.
- Always rule out artefacts as a cause of arrhythmia using other clinical parameters before taking any therapeutic intervention that could be detrimental to the patient.
- ECG monitors and other electrical equipments should be checked for compatibility before usage.

Contributors LB and PR conceived the report. SR assisted during the operation. MSP helped in writing and uploading the case.

Competing interests None.

Patient consent Obtained.

Provenance and peer review Not commissioned; externally peer reviewed.

REFERENCES

1 Klingfield P, Gettes LS, Bailey JJ, *et al*. Recommendations for the standardization and interpretation of the electrocardiogram: part 1. *Circulation* 2007;115:1306–24.
2 Dash PK. Electrocardiogram monitoring. *IJA* 2002;46:251–60.
3 Greutmann M, Horlick EM. Uncommon cause for a common electrocardiographic artefact. *Can J Cardiol* 2010;26:e30.
4 Laudon MK, Webster JG, Frayne R, *et al*. Minimizing interference from magnetic resonance imagers during electrocardiography. *IEEE Trans Biomed Eng* 1998;44:160–4.
5 Travis KW, Rose RJ, Quill JM, *et al*. An unusual cause of electrocardiogram "pacemaker artefact": faulty electrical grounding of equipment. *Anaesthesiology* 1994;80:232.
6 Marples IL. Transcutaneous electrical nerve stimulation (TENS): an unusual source of electrocardiogram artefact. *Anaesthesia* 2000;55:719–20.
7 Choudhry DK, Stayer SA, Rehman MA, Schwartz RE. Electrocardiographic artefact with SSEP monitoring unit during scoliosis surgery. *Pediatric Anaesth* 1998;8:341–3.
8 Martin WA, Camenzind E, Burkhard PR. ECG artefact due to deep brain stimulation (clinical picture). *Lancet* 2003;361:1431.
9 Marco AP, Rice K. Pseudoarrythmia from evoked potential monitoring. *J Neurosurg Anesthesiol* 2001;13:143–5.
10 Gaiser RR, Demetry DJ, Schlosser R. Ventricular tachycardia as an electrocardiography artefact during functional endoscopic sinus surgery. *Am J Rhinol* 2003;17:83–5.
11 Mc Grath B, Columb M. Renal replacement therapy causing ECG artifacts mimicking atrial flutter. *Br J Intensive Care* 2004;14:49–52.
12 Meharg JG Jr. Pseudoarrhythmias secondry to intravenous infusion device. *N Engl J Med* 1979;301:165–6.
13 Toyoyama H, Kariya N, Toyoda Y. Electrocardiographic artifacts during shoulder arthroscopy using a pressure controlled irrigation pump. *Anesth Analg* 2000;90:856–7.
14 Patel SI, Souter MJ. Equipment related electrocardiographic artifacts. *Anesthesiology* 2008;108:138–48.
15 Lin SL, Wang SP, Kong CW, *et al*. Artifact simulating ventricular and atrial arrhythmias. *Jpn Heart J* 1991;32:847–51.
16 Constantoyannis C, Heilborn B, Honey CR. Electrocardiogram artifacts caused by deep brain stimulation. *Can J Neurol Sci* 2004;31:343–6.
17 Sakiewicz PG, Wright E, Robinsn O, *et al*. Abnormal electrical stimulus of with concurrent support with continuous veno venous hemodialysis. *ASAIO J* 2000;46:142–5.

Copyright 2015 BMJ Publishing Group. All rights reserved. For permission to reuse any of this content visit http://group.bmj.com/group/rights-licensing/permissions.
BMJ Case Report Fellows may re-use this article for personal use and teaching without any further permission.

Become a Fellow of BMJ Case Reports today and you can:
- Submit as many cases as you like
- Enjoy fast sympathetic peer review and rapid publication of accepted articles
- Access all the published articles
- Re-use any of the published material for personal use and teaching without further permission

For information on Institutional Fellowships contact consortiasales@bmjgroup.com

Visit casereports.bmj.com for more articles like this and to become a Fellow