Neuro-Oncology Practice

Neuro-Oncology Practice 1(4), 178–183, 2014
doi:10.1093/nop/npu023
Advance Access date 12 September 2014

The management of lomustine overdose in malignant glioma patients

Hans-Georg Wirsching, Isabel Tritschler, Antonella Palla, Christoph Renner, Michael Weller, and Ghazaleh Tabatabai

Department of Neurology, University Hospital Zurich, Zurich, Switzerland (H.-G.W., I.T., A.P., M.W., G.T.); Department of Medical Oncology, University Hospital Zurich, Zurich, Switzerland (C.R.); Neuroscience Center Zurich, University of Zurich and ETH Zurich, Zurich, Switzerland (H.-G.W., I.T., A.P., M.W., G.T.)

Corresponding Author: Hans-Georg Wirsching, MD, Department of Neurology, University Hospital Zurich, Frauenklinikstrasse 26, 8091 Zurich, Switzerland (hans-georg.wirsching@usz.ch).

Lomustine is an oral alkylating drug commonly used for brain tumor patients. Recently, the lomustine-containing PCV polychemotherapy regime (procarbazine, CCNU/lomustine, and vincristine) in combination with radiotherapy has become the standard of care for anaplastic oligodendroglioma with 1p/19q codeletion and high-risk low-grade glioma. Here, we review the literature of all reported cases of lomustine overdose, highlight complications by exemplifying a case of inadvertent lomustine overdose, and outline the management of this potential complication of outpatient PCV therapy.

Keywords: CCNU, glioma, lomustine, myelosuppression, overdose, PCV.

Background

Therapeutic options for recurrent glioblastoma are limited and comprise second surgery, alkylating chemotherapy, and antiangiogenic therapy.[1] The alkylating agent lomustine is commonly employed as the standard control drug for clinical trials in recurrent glioblastoma. Examples include the REGAL trial investigating cediranib versus cediranib plus lomustine versus lomustine alone (Clinical Trials.gov identifier NCT00777153), a phase III study of enzastaurin versus lomustine in recurrent glioblastoma,[2] or the ongoing phase II EORTC 26101 study that explores the sequence of bevacizumab and lomustine upon first recurrence in glioblastoma (ClinicalTrials.gov identifier NCT01290939). Lomustine is also being investigated for primary glioblastoma in combination with temozolomide in the phase III CeTeG trial (ClinicalTrials.gov identifier NCT01149109). Recent long-term follow-up reports of the RTOG 9402 and the EORTC 26951 trials suggested that PCV chemotherapy (consisting of procarbazine, CCNU/lomustine, and vincristine) in combination with radiotherapy (RT) prolongs overall survival of patients with anaplastic oligodendrogliomas and oligoastrocytomas harboring 1p/19q codeletions.[3,4] Median survival of patients with codeleted tumors who were treated with RT plus PCV was twice that of patients receiving RT alone (14.7 vs 7.3 y; HR = 0.59; 95% CI, 0.37–0.95; $P = .03$).[4] Furthermore, addition of PCV to RT improved progression-free survival for patients with high-risk low-grade gliomas.[5] Thus, lomustine is a drug that is commonly and probably even increasingly applied in the treatment of gliomas. The drug is given orally on an outpatient basis at a dose of 80–110 mg/m^2 every 6 weeks.

Report of a Case

We report the case of a 71-year-old male patient with glioblastoma of the right insula and temporal lobe. The methylguanine methyl transferase (*MGMT*) gene promoter was not methylated, and IDH-1 or IDH-2 mutations were not detected. Twenty-eight days after partial resection of the tumor, the patient received involved-field RT (6 MV photons, 5 × 2 Gy per week, 60.0 Gy) with concomitant temozolomide (75 mg/m^2, 140 mg per day). Next, the patient received 2 cycles of adjuvant temozolomide (5 of 28 days; first cycle at 150 mg/m^2, 345 mg; second cycle at 200 mg/m^2, 460 mg). Upon disease progression after the second cycle of temozolomide (Fig. 1A and B), the patient gave consent for enrollment into the phase I RO-BP25389 trial (ClinicalTrials.gov identifier NCT01308684) and received combined therapy of bevacizumab and a humanized antibody against placental growth factor (PlGF), RO-5323441. After initial radiological partial response, the tumor recurred multifocally in the temporopolar area and in the basal ganglia of the right hemisphere after 22 weeks. Thereafter, therapy with lomustine was planned (110 mg/m^2, 200 mg every 6 weeks). Despite detailed written and oral instructions, a 30/30 score in the mini-mental status exam, and minimal neuropsychological deficits, the patient contacted us a few days later and reported that he had taken 200 mg daily for 4 days. He was also taking antiemetic prophylaxis with ondansetron and experienced no nausea or vomiting.

The patient was admitted for close monitoring on day 11 after the first lomustine dose with a considerably reduced KPS as compared with his previous consultation on day zero (60% vs 80%).

Received 18 July 2014, Advance Access publication 12 September 2014
© The Author(s) 2014. Published by Oxford University Press on behalf of the Society for Neuro-Oncology. All rights reserved.
For permissions, please e-mail: journals.permissions@oup.com.

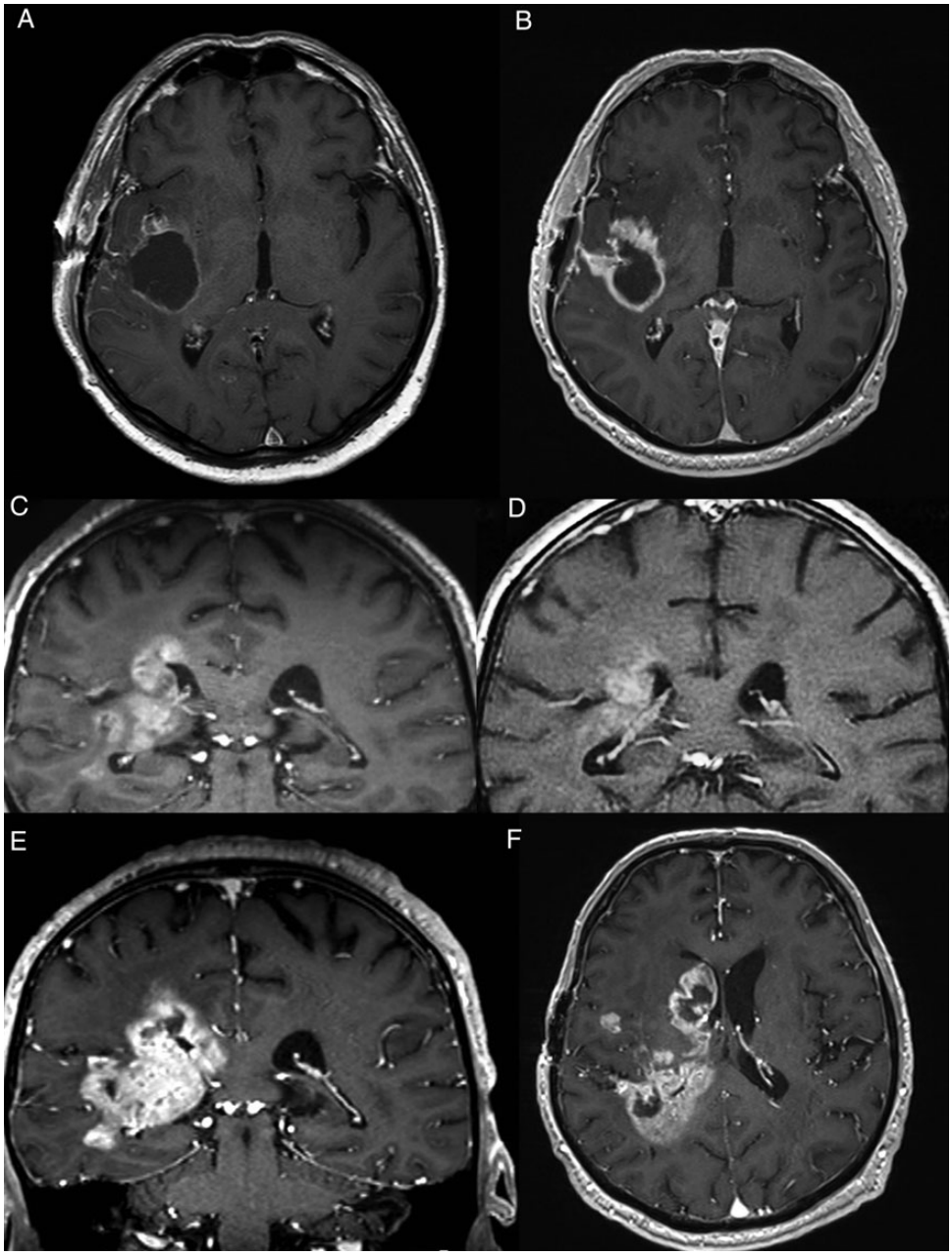

Fig. 1. T1-weighted gadolinium-enhanced MRI sections. (A and B) Tumor progression after 2 cycles of adjuvant temozolomide (5/28 schedule). Transverse sections postoperatively (A) and 155 days postoperatively (B). (C and D) Tumor stabilization upon lomustine overdose. Coronary sections on day 3 (C) and on day 18 (D) relative to the first day of intake of 4 days times 200 mg lomustine. (E and F) Tumor progression on day 80 relative to the first day of intake of 4 days times 200 mg lomustine. Coronary (E) and transverse (F) sections.

The patient reported abdominal pain and cramps, which lasted until day 13. Glutamic pyruvic transaminase (GPT), glutamine-oxaloacetic transaminase (GOT), γ-glutamyl transferase, and lactic dehydrogenase were not elevated and remained normal thereafter. An ultrasound of the abdomen on day 12 showed no pathology except for previously known liver cysts that had been stable in size and morphology over the past year. From day 10 after starting lomustine, his hemoglobin, white blood cell, and platelet counts dropped and did not recover for 25 days (Fig. 2). The patient was put on granulocyte colony-stimulating factor (G-CSF; 48 Mio IU) and systemic antibiotic prophylaxis with sulfamethoxazol p.o. (800 mg/d), trimethoprim p.o. (160 mg/d), and levofloxacin p.o. (1000 mg/d). Because of the risk for intestinal necrosis and/or microlesions with lomustine overdose, the patient's gastrointestinal symptoms prompted us to add metronidazole p.o. (1500 mg/d), gentamycin p.o. (80 mg/d), and amphotericin B p.o. (200 mg/d) for intestinal decontamination from days 11–25. We did not obtain autologous stem cells because impaired performance status and poor prognosis precluded stem cell transplantation. From day 11 on,

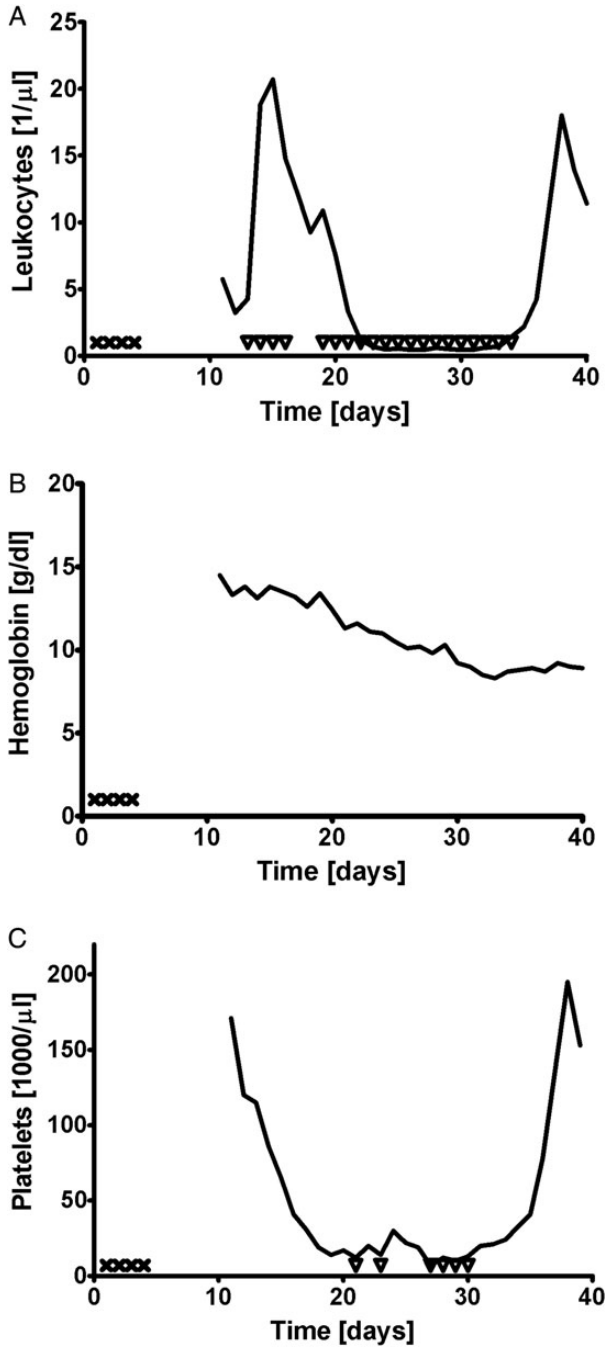

Fig. 2. (A–C) Time course of myelosuppression and supportive treatment after lomustine overdose. The levels of leukocytes (A), hemoglobin (B), and platelets (C) are shown. The days of lomustine intake are labeled by crosses. The days of G-CSF administration (A) or platelet transfusions (C) are indicated by arrowheads. The patient left the hospital on day 41.

the patient was put on N-acetylcystein p.o. (600 mg/d), which we considered to have cytoprotective effects against lomustine-induced organ toxicity.

On day 27, coagulase-negative staphylococci were detected in the stool; thus, we put the patient on oral vancomycin (750 mg/d). There was no increased body temperature or increase in the frequency of bowel movements at any time, and C-reactive protein (CRP) was only slightly increased to 16.0 mg/L on day 27. The patient remained stable, although severely myelosuppressed. He received 6 thrombocyte transfusions in total on day 21, day 23, and days 27–30, respectively, when thrombocyte counts dropped below 20 000/µL. Metronidazole, levofloxacine, vancomycin, and amphotericine B were stopped on day 37, and the patient was discharged in reduced general condition and KPS 60% on day 41.

MRI performed on day 18 showed no tumor progression (Fig. 1C and D), although the patient's general condition had declined clinically. No further chemotherapy was given. Until the next visit on day 80, the KPS had dropped to 40%–50%, and the patient developed a severe left sensorimotor hemisyndrome and severe neuropsychological deficits with predominant hemineglect, perseveration, and near-complete loss of short-term memory. An MRI on day 80 showed severe multifocal tumor progression (Fig. 1E and F). Palliative care was implemented, and the patient died on day 137.

Review of the Literature

A literature review revealed 6 cases of inadvertent lomustine overdose, one of which was fatal (Table 1).[6–10] All patients suffered prolonged myelosuppression, as defined by thrombocyte counts <100 000/µL, leukocyte counts <2500/µL, absolute neutrophil counts <1500/µL, or hemoglobin <90 g/L. Myelosuppression occured as early as day 10–20. Severe abdominal pain was observed in our patient and was reported in 2 other cases, one of whom suffered inflammatory ileal necrosis.[9] The cause of death of one patient with lethal lomustine overdose was not determined, but central nervous system toxicity was suggested as a possibility.[8] In our patient, no unexpected or severe complications beside prolonged and early myelosuppression occurred. While severe complications, including ileal necrosis and pulmonary toxicity, have been reported from other patients with lomustine overdose,[8,9] management of patients with lomustine overdose is determined by diagnosis and prevention of infectious complications.

The underlying reason for lomustine overdosing has been reported for one case in which a prescription error by the general practitioner occurred.[9] In all reported cases, patients were supplied with lomustine for more than one dose. Although the reasons for this practice remain elusive, prescription errors by physicians or pharmacists are the most likely had causes. For the present case, lomustine was exclusively available in boxes of 20 pills of 40 mg, and the patient stated that he had confused dosing with temozolomide in the 5/28 regimen. The overrepresentation of brain tumor patients among reported cases of inadvertent lomustine intake suggests that impaired cognitive functioning may have contributed to overdosing, although our patient had minimal neurocognitive deficits. Neither putative underlying suicidal nor self-medicating intentions have been reported.

Recommendations for Clinical Practice

Paramount in preventing harm of patients from lomustine overdose is to avoid supplying patients with more than the dose for a single cycle at a time. Physicians prescribing lomustine should be trained respectively, including reconfirming the single-dose supply with the pharmacy and thorough providing patient

Table 1. Lomustine overdose: An overview[a]

Reference	Age (years)/Sex	Diagnosis	Lomustine Intake[b]	Myelo-suppression[c]	Complications	Outcome
Foon and Haskell 1982	59/m	Colorectal carcinoma	1120 mg 7 days × 160 mg (550 mg/m^2)	Days 20–35	None	Alive at 22 months
Hornstein et al 1983	62/m	Hodgkin's disease	600 mg 15 days × 40 mg (300 mg/m^2)	Days 30–45	None	Survival at 4 years
Trent et al 1995	28/f	Anaplastic astrocytoma	1400 mg 7 days × 200 mg (825 mg/m^2)	Up to day 50	Laparotomy, mental changes, pulmonary toxicity	Death at day 59, autopsy denied
Abele et al 1998	35/f	Anaplastic astrocytoma	1120 mg 7 days × 160 (805 mg/m^2)	Days 10–45	Ileal necrosis (day 48)	Alive at 11 months
Büyükçelik et al 2004	38/m	Glioblastoma	4 days × 200 (400 mg/m^2)	Days 16–35	Febrile neutropenia (days 16–31)	Death at 9 months
Büyükçelik et al 2004	48/m	Glioblastoma	4 days × 200 (330 mg/m^2)	Days 14–42		Alive and progression free at 30 months
Our case	71/m	Glioblastoma	800 mg 4 days × 200 mg (350 mg/m^2)	Days 10–37		Death at day 137

Abbreviations: f, female; m, male.
[a]Adapted from [8].
[b]Total lomustine dose and lomustine dosing schedule.
[c]Platelets <100 000/μL, leukocytes <3000/μL, absolute neutrophil count <1500/μL or hemoglobin <90 mg/L, from first lomustine intake.

education. Electronic medical records that alert physicians in case of prescription errors should also be standard in centers supplying chemotherapy.

In cases of lomustine overdose, an initial assessment of the risk of serious infectious complications according to the Infectious Diseases Society of America (IDSA) criteria for patients with neutropenia[11] should guide the approach to therapy including the need for inpatient admission and antibiotic therapy. Patients with an absolute neutrophil count (ANC) that is expected to drop <100/μL for >7 days (eg, patients with lomustine intake of 800 mg or previous myelosuppression), or patients with significant comorbidities are at a high risk for infectious complications. Patients with severe neurological symptoms including epileptic seizures should be admitted to hospital for close monitoring. Patients at low risk for infectious complications with no signs of infection may be managed as outpatients if their general condition, mental status, neurological symptoms, and social situation allow for close monitoring and implementation of hygienic precautions, as outlined below.

Hygienic precautions include initial dental examination and treatment of putative intraoral foci, avoidance of crowds or public transportation, removal of flowers or plants from the patient's rooms, no handshakes, disinfection of hands before and after any contact with the patient, and avoidance of raw food. High-risk patients should be treated with special precautions, including isolation and use of single-use gowns, gloves, and masks, upon drop of ANC <100/μL or development of symptoms,.

Recommendations for monitoring include daily assessment of vital parameters, physical examination including auscultation of the lungs and oral and abdominal examination, laboratory investigations including blood counts and CRP, and sampling of body material upon development of fever or other clinical symptoms. X-rays of the chest should be performed at the initial assessment and upon development of pulmonary signs or symptoms. An ultrasound or CT scan of the abdomen should be performed upon development of gastrointestinal symptoms, but rectal contrast application or colonoscopy should be omitted because of the increased risk of intestinal perforation after lomustine overdose.

High-risk patients should generally receive broad-spectrum antibiotic prophylaxis that covers *Pseudomonas* species at least until ANC has resolved to >500/μL or until infection-related symptoms resolve and CRP is dropping (eg, with oral levofloxacin). Antibiotic prophylaxis in neutropenic patients without fever is associated with lower all-cause mortality, reduced occurrence of fever and infections, and lower risk of infection-related death but increased gastrointestinal toxicities.[12] Given lomustine-associated intestinal toxicity and a possibly cumulative risk with antibiotic-related gastrointestinal toxicity, the indication for antibiotic prophylaxis should be evaluated carefully in low-risk patients with lomustine overdose, but it should be implemented if the expected duration of neutropenia <500/μL exceeds 7 days.[11]

Upon development of neutropenic fever, low-risk outpatients should receive oral ciprofloxacin and oral amoxicillin/clavulanate, or oral levofloxacin, whereas all high-risk patients and low-risk patients developing symptoms as inpatients (>2 days after admission) should receive i.v. therapy with piperacillin/tazobactam, carbapeneme, ceftazidime, or cefepime followed by specific adjustments depending on persistence of symptoms, culture tests, and infectious focus.[11]

Table 2. Overview of recommendations for the management of patients with lomustine overdose

Initial Risk Assessment	High Risk Group: ANC <100/μL Expected >7 Days; Comorbidities	Low Risk Group: ANC <100/μL Expected <7 Days; No Comorbidities
Hospitalization	All high-risk patients	Low-risk patients with 1 of the following features: ANC <500/μL expected >7 days Signs of infection KPS <80% MMSE <27 Severe neurological symptoms Epileptic seizures Social situation not allowing monitoring and hygienic precautions
Hygienic precautions	Initial dental examination and treatment of putative intraoral foci Avoidance of crowds (eg, public transportation), shaking hands, and raw food Removal of flowers from patient's rooms Disinfection of hands	
Monitoring	Daily vital signs, physical examination, blood counts, CRP, liver, and kidney parameters Sampling of body fluids upon development of fever or organ-specific symptoms Initial chest x-ray and repeated chest x-ray upon development of fever or pulmonary symptoms CT or sonography of the abdomen upon development of gastrointestinal symptoms; avoid rectal contrast and colonoscopy	
Broad-spectrum antibiotic prophylaxis	Levofloxacine p.o. for all high-risk patients	Levofloxacine p.o. for low-risk patients if ANC <500/μL Expected >7 days
Treatment of neutropenic fever	High-risk patients: piperacillin/tazobactam i.v., carbapeneme i.v., ceftazidime i.v., or cefepime i.v., followed by specific adjustments depending on clinical course, culture tests and infectious focus	Low-risk outpatients or inpatients <2 days: ciprofloxacin p.o. and amoxicillin/clavulanate p.o. Inpatients >2 days: treat as high-risk patients
Pneumocystis jirovecii prophylaxis	Lymphocyte counts <1000/μL or pulmonary comorbidity: sulfamethoxazol p.o., trimethoprim p.o. 3 times per week	
Intestinal decontamination	Only if gastrointestinal symptoms or comorbidities are present: decontamination with metronidazole p.o., gentamycin p.o., and amphotericin B p.o.	
N-acetylcystein	Optional	

Abbreviations: ANC, absolute neutrophil count: CRP, C-reactive protein.

Antibiotic prophylaxis should include prophylaxis against *Pneumocystis jirovecii* with oral trimethoprim/sulfamethoxazole in all patients if lymphocyte counts drop below 1000/μL, but no antifungal or antiviral prophylaxis needs to be initiated in asymptomatic patients. Intestinal decontamination with oral metronidazole, gentamycin, and amphotericin B should only be performed in patients with gastrointestinal pain or gastrointestinal comorbidities.

The use of G-CSF for patients with chemotherapy-induced myelosuppresion is under debate, mainly because no overall survival benefit has been shown for using G-CSF in the primary prophylaxis of chemotherapy-induced neutropenic fever. However, a meta-analysis that included 3493 patients treated in 17 randomized controlled trials demonstrated a 45% decrease in infection-related mortality upon chemotherapy-induced leukopenia (relative risk, 0.55; 95% CI, 0.33–0.90).[13]

We further recommend administration of N-acetylcysteine to patients with lomustine overdose because N-acetylcystein may limit organ toxicity by scavenging oxygen-derived free radicals and restoring hepatic glutathione.[14,15]

We have concluded that lomustine overdose requires careful evaluation and treatment of aplasia-related infectious complications and organ toxicity. We therefore recommend the measures outlined in Table 2 to manage this potential life-threatening condition.

Funding

This publication was not funded.

Conflict of interest statement. The authors declare no conflict of interest.

References

1. Weller M, Cloughesy T, Perry JR, et al. Standards of care for treatment of recurrent glioblastoma--are we there yet? *Neuro Oncol*. 2013; 15(1):4–27.

2. Wick W, Puduvalli VK, Chamberlain MC, et al. Phase III study of enzastaurin compared with lomustine in the treatment of recurrent intracranial glioblastoma. *J Clin Oncol*. 2010;28(7):1168–1174.
3. van den Bent MJ, Brandes AA, Taphoorn MJ, et al. Adjuvant procarbazine, lomustine, and vincristine chemotherapy in newly diagnosed anaplastic oligodendroglioma: long-term follow-up of EORTC brain tumor group study 26951. *J Clin Oncol*. 2013;31(3): 344–350.
4. Cairncross G, Wang M, Shaw E, et al. Phase III trial of chemoradiotherapy for anaplastic oligodendroglioma: long-term results of RTOG 9402. *J Clin Oncol*. 2013;31(3):337–343.
5. Shaw EG, Wang M, Coons SW, et al. Randomized trial of radiation therapy plus procarbazine, lomustine, and vincristine chemotherapy for supratentorial adult low-grade glioma: initial results of RTOG 9802. *J Clin Oncol*. 2012;30(25):3065–3070.
6. Foon KA, Haskell CM. Inadvertent overdose with lomustine (CCNU) followed by hematologic recovery. *Cancer Treat Rep*. 1982;66(5): 1241–1242.
7. Hornsten P, Sundman-Engberg B, Gahrton G, et al. CCNU toxicity after an overdose in a patient with Hodgkin's disease. Effects on colony-forming cells (CFU-C) and colony-stimulating activity (CSA). *Scand J Haematol*. 1983;31(1):9–14.
8. Trent KC, Myers L, Moreb J. Multiorgan failure associated with lomustine overdose. *Ann Pharmacother*. 1995;29(4):384–386.
9. Abele M, Leonhardt M, Dichgans J, et al. CCNU overdose during PCV chemotherapy for anaplastic astrocytoma. *J Neurol*. 1998;245(4): 236–238.
10. Buyukcelik A, Akbulut H, Yalcin B, et al. Overdose of lomustine: report of two cases. *Tumori*. 2004;90(6):628–629.
11. Freifeld AG, Bow EJ, Sepkowitz KA, et al. Clinical practice guideline for the use of antimicrobial agents in neutropenic patients with cancer: 2010 Update by the Infectious Diseases Society of America. *Clin Infect Dis*. 2011;52(4):427–431.
12. Gafter-Gvili A, Fraser A, Paul M, et al. Antibiotic prophylaxis for bacterial infections in afebrile neutropenic patients following chemotherapy. *Cochrane Database Syst Rev*. 2012;1:CD004386.
13. Kuderer NM, Dale DC, Crawford J, et al. Impact of primary prophylaxis with granulocyte colony-stimulating factor on febrile neutropenia and mortality in adult cancer patients receiving chemotherapy: a systematic review. *J Clin Oncol*. 2007;25(21):3158–3167.
14. Cascinu S, Catalano V, Cordella L, et al. Neuroprotective effect of reduced glutathione on oxaliplatin-based chemotherapy in advanced colorectal cancer: a randomized, double-blind, placebo-controlled trial. *J Clin Oncol*. 2002;20(16):3478–3483.
15. Smilkstein MJ, Knapp GL, Kulig KW, et al. Efficacy of oral N-acetylcysteine in the treatment of acetaminophen overdose. *Analysis of the national multicenter study (1976 to 1985)*. *New Engl J Med*. 1988;319(24):1557–1562.