

Colonic gas explosion during therapeutic colonoscopy with electrocautery

Spiros D Ladas, George Karamanolis, Emmanuel Ben-Soussan

Spiros D Ladas, George Karamanolis, Hepatogastroenterology Unit, 2nd Department of Internal Medicine-Propaedeutic, Medical School, Athens University, "Attikon" University General Hospital, Athens, Greece

Emmanuel Ben-Soussan, Clinique de l'Alma 166, rue de l'université 750007, Paris, France

Correspondence to: Spiros D Ladas MD, PhD, Hepatogastroenterology Unit, 2nd Propedeutic Internal Medicine Department, "ATTIKON" General Hospital, Rimini 1, Athens 12462, Greece. sdladas@otenet.gr

Telephone: +30-210-5832087 Fax: +30-210-5326422

Revised: June 26, 2007 Revised: August 10, 2007

Abstract

Therapeutic colonoscopy with electrocautery is widely used around the world. Adequate colonic cleansing is considered a crucial factor for the safety of this procedure. Colonic gas explosion, although rare, is one of the most frightening iatrogenic complications during colonoscopy with electrocautery. This complication is the result of an accumulation of colonic gases to explosive concentrations, but may be prevented by meticulous bowel preparation. The purpose of this review is to discuss the indications and the types of bowel preparations for therapeutic colonoscopy, and to contribute recommendations for the adequate bowel preparation for colonoscopy with electrocautery.

© 2007 WJG. All rights reserved.

Key words: Colonic gas explosion; Electrocautery; Therapeutic polypectomy; Argon plasma coagulation; Polypectomy

Ladas SD, Karamanolis G, Ben-Soussan E. Colonic gas explosion during therapeutic colonoscopy with electrocautery. *World J Gastroenterol* 2007; 13(40): 5295-5298

<http://www.wjgnet.com/1007-9327/13/5295.asp>

INTRODUCTION

Endoscopic polypectomy and argon plasma coagulation for hemostasis of colonic vascular lesions are considered relatively safe procedures. Among complications that have been reported, gas explosion is rare, but its nature could be dramatic, as perforation could complicate colonic explosion and urgent surgery is needed.

Three factors are necessary to trigger an explosion of colonic gases: presence of combustible gases (hydrogen, methane) produced by the fermentation of non-absorbable carbohydrates in the colon by the colonic bacteria, presence of combustive gas (oxygen), and application of a heat source (electrocautery or argon plasma coagulation)^[1-3]. Five major components of gases have been identified in colon: nitrogen (23%-80%), oxygen (0.1%-2.3%), hydrogen (0.06%-47%), methane (0%-26%), and carbon dioxide (5.1%-29%). Only hydrogen and methane are combustible^[4]. They are produced in the colonic lumen from fermentation of non absorbable (e.g, lactulose, mannitol) or incompletely absorbed (lactose, fructose, sorbitol) carbohydrates by the colonic flora^[4-6]. Concentrations of hydrogen more than 4% and/or methane more than 5% are considered potentially explosive^[7]. Almost half of the patients (42.8%) with unprepared colon have potentially explosive concentrations of hydrogen and methane^[8]. Nevertheless, an explosion with these two gases can occur only if the oxygen concentration is over 5%^[9].

Following bowel preparation with a combination of clear liquids, cathartics, and enemas, mean concentration of hydrogen (0.024% ± 0.007%) and methane (0.0023% ± 0.001%) were below of their minimal explosive concentration^[4]. Thus, safety of therapeutic colonoscopy could be in part related to the quality of preparation before the procedure. An accumulation of colonic gas to potentially explosive concentrations due to poor colon preparation is considered an initiating factor in the complication of colonic gas explosion. Therefore, quality of bowel preparation as well as type of preparation and dietary restrictions are all essential for an uneventful therapeutic colonoscopy.

INDICATIONS FOR COLONOSCOPY WITH ELECTROCAUTERY

The main indication for application of electrosurgical energy is snare colonoscopic polypectomy with blended or pure coagulation current^[10]. Argon plasma has been successfully used for hemostasis of vascular ectasias, for ablation of intestinal polyps or residual adenomatous tissue after colonic polypectomy, and for the endoscopic therapy of postradiation colitis^[11].

Electrosurgical generators

Electrosurgical generators are used to supply electrical energy to endoscopic accessories. When electrical energy is introduced to tissue, it produces excitation of molecules,

which results in generation of heat^[12]. Electrosurgical generators may supply two types of circuits, monopolar and bipolar. Electrosurgical cutting is achieved by a high voltage (> 200 V) continuous current^[10].

Argon plasma coagulation

Argon plasma coagulation is a noncontact electrocoagulation device that uses high-frequency monopolar current conducted to target tissues through ionized argon gas^[10]. Argon plasma delivered through a flexible probe passed through the accessory channel and allows treatment of a large area quickly^[13]. In general, low power and low argon flow rates are used for hemostasis with settings of 40-50 W and 0.8 to 1.2 L/mn, whereas higher settings (70-90 W and over 1.2 L/mn) are used for tissue ablation^[14].

BOWEL PREPARATION

Bowel preparation with purgatives

The selection of purgative used for colon preparation is an important factor that makes the bowel safe for therapeutic procedures. Earlier than 1980's, mannitol was considered as the reference agent for colonic preparation. Explosions during therapeutic colonoscopy have been reported after mannitol preparation and its use is now avoided as cleansing colonic solution^[1-3,5,15-17]. Use of oral mannitol increased hydrogen and methane excretion^[3,5,9,18-19]. Aspiration of colonic gas at the time of colonoscopy showed that mean intracolonic hydrogen concentration was significantly higher after mannitol than after castor oil. Moreover, potentially explosive concentrations were present in 60% of patients given mannitol compared to 0%-20% of patients given castor oil^[3,19]. Fermentation of mannitol by *E.coli* is thought to be responsible for the production of potentially explosive gas mixture after oral mannitol preparation^[20-21]. Significantly higher counts of gas-producing *E.coli* were recovered from patients prepared with mannitol alone compared with mannitol preceded by oral antimicrobials^[20]. Therefore, the use of antibiotics prior to therapeutic colonoscopy could be a measure that would lower the load of intracolonic bacteria. An alternative approach to reduce the risk of explosion of colonic gases if mannitol preparation is used before electrocautery is insufflation of an inert gas such as carbon dioxide instead of air^[3,22].

Since 1990, a major progress occurred with new agents, such as polyethylene glycol electrolyte lavage solution (PEG-ELS) and oral sodium phosphate (NaP) solutions. Several studies agree that these agents provide a climate safe for electrocautery during colonoscopy by decreasing the concentrations of combustible gases^[14,23-26]. The highest hydrogen and methane concentrations after a PEG-ELS preparation are well below the combustible level^[26]. A recent report described a case of colonic gas explosion in a patient that underwent bowel preparation with a polyethylene glycol solution containing sorbitol^[27]. Sorbitol is an important carbohydrate that is daily included in humans diet. Studies have shown that the frequency of sorbitol malabsorption may be as high as 60% in healthy subjects^[3,28]. Thus, fermentation of this malabsorbed carbohydrate by colonic bacteria could result in raised combustible gas concentrations in the colon and explain the explosion that occurred in the above mentioned case report^[27].

Partial bowel preparation by enemas

For lesions that need electrocautery and are located up to the level of sigmoid colon, a flexible sigmoidoscopy with enema preparation is the procedure of choice by the majority of gastroenterologists. However, studies have reported cases of gas explosion in patients prepared by enemas^[29-31]. In these cases, the used enema did not contain any fermentable agents and the extension of colonic preparation was thought to be the initiating factor in this complications. Due to the partial colonic preparation, presence of residual stools above the lesions could enhance gas production and explain gas explosion.

In a prospective study, sixty patients were evaluated to compare the presence of the combustible gases hydrogen and methane during colonoscopy after a PEG-ELS preparation and flexible sigmoidoscopy after phosphosoda enemas alone^[32]. During colonoscopy, the concentrations of hydrogen and methane remained below combustible levels in all patients, whereas 10% of patients had combustible levels of either hydrogen or methane during flexible sigmoidoscopy. Patients had combustible levels even after air insufflation during sigmoidoscopy and the possibility of explosion was clinically significant. Another important observation of this elegant study was that even segments of colon with excess retained stools did not have combustible levels of these two gases. It seems that insufflation of air during colonoscopy equalizes the distribution of combustible gases, overcoming the compartmentation of the colon.

In a more recent study using argon plasma coagulation for hemorrhagic radiation proctitis, incidence of gas explosion was higher after local colon preparation (3/19 sessions) compared with oral preparation (0/53 sessions)^[31]. All three explosions after enema preparation occurred in patients with persistent solid stool above the coagulated lesions. Thus, the presence of stools could constitute the main risk for the colonic explosion.

REVIEW OF PUBLISHED STUDIES

A systematic review of the medical research published in English language from 1952 to October 2006 was performed, by using MEDLINE, SCOPUS, SCIRUS, and EMBASE to obtain studies published on colonic gas explosion. The search terms included were combinations of "colonic explosion" or "gas explosion" with "surgery", "electrocautery", "polypectomy", and "argon plasma coagulation".

A total of 20 cases of colonic gas explosion were identified (Figure 1). Eleven cases of gas explosion during surgery^[2,16,33-39] and 9 cases during colonoscopic procedures have been published. Argon plasma coagulation provided the initiating heat source in five of the nine colonoscopic cases^[29-31], whereas the remaining four cases were associated with endoscopic polypectomy^[1,15,17,27]. Recently, we also experienced a case of colonic explosion during an argon plasma coagulation procedure for postradiation colitis. Although seven successive, uneventful sessions of argon plasma coagulation were performed with enema preparation, gas explosion without colonic perforation occurred upon finishing the last procedure.

Nine of the 20 published cases (45%) of gas explosion

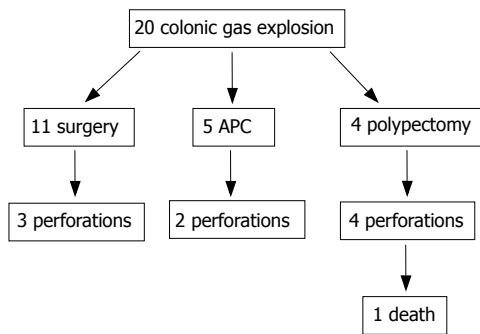


Figure 1 Flow chart of published cases with colonic gas explosion.

were complicated with colon perforation. Perforation was observed in all of the four polypectomy cases^[1,15,17,27], in two cases using argon plasma coagulation^[29,31], and in three cases during electrosurgery^[2,33-34]. One of the four perforations during polypectomy was fatal^[1].

Bowel preparation by ingestion of a mannitol solution was used in 14 cases and of a cleansing solution containing sorbitol in one case^[27]. Preparation by enemas containing no fermentable agent was used in all five cases treated with argon plasma coagulation for post-radiation colitis^[29-31].

CONCLUSION

Colonic gas explosion is a rare, but potentially serious complication during colonoscopy with electrocautery. Accumulation of colonic combustible gases at potentially explosive concentrations due to poor colon preparation is the cause of gas explosion. Cleansing purgatives (PEG, NaP) that make the bowel safe for electrocautery by decreasing the concentrations of the combustible gases are adequate for colon preparation. Argon plasma coagulation carries an increased risk of explosion during sigmoidoscopy following enemas, and it should only be performed after full bowel preparation.

In conclusion, we recommend the following to avoid colonic gas explosion during colonoscopy with electrocautery:

(1) Cleansing solution containing mannitol^[3,8,19] or other malabsorbed carbohydrates (e.g., sorbitol)^[6] should be avoided in the preparation of the colon since intracolonic concentrations of H₂ or/and CH₄ could be at combustible levels.

(2) During flexible sigmoidoscopy after standard enema preparation, concentrations of H₂ or/and CH₄ could be at explosive levels^[32].

(3) Argon plasma coagulation for post-radiation colitis should be performed only after complete bowel preparation with PEG or NaP, to avoid the risk of explosion^[31].

(4) Polypectomy with electrocautery should only be performed after full bowel preparation with PEG or NaP to prevent colonic explosion^[1,15,17,27].

REFERENCES

- Bigard MA, Gaucher P, Lassalle C. Fatal colonic explosion during colonoscopic polypectomy. *Gastroenterology* 1979; **77**: 1307-1310
- Raillat A, de Saint-Julien J, Abgrall J. Colonic explosion during an endoscopic electrocoagulation after preparation with mannitol. *Gastroenterol Clin Biol* 1982; **6**: 301-302
- Avgerinos A, Kalantzis N, Rekoumis G, Pallikaris G, Arapakis G, Kanaghinis T. Bowel preparation and the risk of explosion during colonoscopic polypectomy. *Gut* 1984; **25**: 361-364
- Levitt MD, Bond JH. Volume, composition, and source of intestinal gas. *Gastroenterology* 1970; **59**: 921-929
- Bond JH, Levitt MD. Colonic gas explosion--is a fire extinguisher necessary? *Gastroenterology* 1979; **77**: 1349-1350
- Ladas SD, Grammenos I, Tassios PS, Raptis SA. Coincidental malabsorption of lactose, fructose, and sorbitol ingested at low doses is not common in normal adults. *Dig Dis Sci* 2000; **45**: 2357-2362
- Levy EI. Explosions during lower bowel electrosurgery. *Am J Surg* 1954; **88**: 754-758
- Ragins H, Shinya H, Wolff WI. The explosive potential of colonic gas during colonoscopic electrosurgical polypectomy. *Surg Gynecol Obstet* 1974; **138**: 554-556
- Taylor EW, Bentley S, Youngs D, Keighley MR. Bowel preparation and the safety of colonoscopic polypectomy. *Gastroenterology* 1981; **81**: 1-4
- Slivka A, Bosco JJ, Barkun AN, Isenberg GA, Nguyen CC, Petersen BT, Silverman WB, Taitelbaum G, Ginsberg GG. Electrosurgical generators: MAY 2003. *Gastrointest Endosc* 2003; **58**: 656-660
- Ginsberg GG, Barkun AN, Bosco JJ, Burdick JS, Isenberg GA, Nakao NL, Petersen BT, Silverman WB, Slivka A, Kelsey PB. The argon plasma coagulator: February 2002. *Gastrointest Endosc* 2002; **55**: 807-810
- Tucker RD. Principles of electrosurgery. In: Sivak MV, editor. *Gastroenterologic endoscopy*. 2nd ed. Philadelphia: WB Saunders, 2000: 125
- Farin G, Grund KE. Technology of argon plasma coagulation with particular regard to endoscopic applications. *Endosc Surg Allied Technol* 1994; **2**: 71-77
- Waye J. How I use the argon plasma coagulation. *Clin Perspect Gastroenterol* 1999; **2**: 249-252
- Bisson B. Methane gas explosion during colonoscopy. *Gastroenterol Nurs* 1997; **20**: 136-137
- Shinagawa N, Mizuno H, Shibata Y, Yura J, Katsumi K, Ito M, Takeuchi T. Gas explosion during diathermy colotomy. *Br J Surg* 1985; **72**: 306
- Bond JH, Levy M, Levitt MD. Explosion of hydrogen gas in the colon during proctosigmoidoscopy. *Gastrointest Endosc* 1976; **23**: 41-42
- Beck DE, Fazio VW, Jagelman DG. Comparison of oral lavage methods for preoperative colonic cleansing. *Dis Colon Rectum* 1986; **29**: 699-703
- La Brooy SJ, Avgerinos A, Fendick CL, Williams CB, Misiewicz JJ. Potentially explosive colonic concentrations of hydrogen after bowel preparation with mannitol. *Lancet* 1981; **1**: 634-636
- Keighley MR, Taylor EW, Hares MM, Arabi Y, Youngs D, Bentley S, Burdon DW. Influence of oral mannitol bowel preparation on colonic microflora and the risk of explosion during endoscopic diathermy. *Br J Surg* 1981; **68**: 554-556
- Keighley MR, Lee JR, Ambrose NS. Indications and techniques for bowel preparation in colorectal cancer. *Int Adv Surg Oncol* 1983; **6**: 257-270
- Rogers BH. Carbon dioxide for colonoscopy. *Gastroenterology* 1980; **78**: 1659-1660
- Ambrose NS, Johnson M, Burdon DW, Keighley MR. A physiological appraisal of polyethylene glycol and a balanced electrolyte solution as bowel preparation. *Br J Surg* 1983; **70**: 428-430
- DiPalma JA, Brady CE, Stewart DL, Karlin DA, McKinney MK, Clement DJ, Coleman TW, Pierson WP. Comparison of colon cleansing methods in preparation for colonoscopy. *Gastroenterology* 1984; **86**: 856-860
- DiPalma JA, Brady CE. Colon cleansing for diagnostic and surgical procedures: polyethylene glycol-electrolyte lavage solution. *Am J Gastroenterol* 1989; **84**: 1008-1016
- Strocchi A, Bond JH, Ellis C, Levitt MD. Colonic concentrations

- of hydrogen and methane following colonoscopic preparation with an oral lavage solution. *Gastrointest Endosc* 1990; **36**: 580-582
- 27 **Joseminders DF**, Spillenaar Bilgen EJ, van Sorge AA, Wahab PJ, de Vries RA. Colonic explosion during endoscopic polypectomy: avoidable complication or bad luck? *Endoscopy* 2006; **38**: 943-944
- 28 **Nelis GF**, Vermeeren MA, Jansen W. Role of fructose-sorbitol malabsorption in the irritable bowel syndrome. *Gastroenterology* 1990; **99**: 1016-1020
- 29 **Zinsser E**, Will U, Gottschalk P, Bosseckert H. Bowel gas explosion during argon plasma coagulation. *Endoscopy* 1999; **31**: S26
- 30 **Pichon N**, Maisonneuve F, Cessot F, Sodji M, Sautereau D. Colonic perforations after gas explosion induced by argon plasma coagulation. *Endoscopy* 2004; **36**: 573
- 31 **Ben-Soussan E**, Antonietti M, Savoye G, Herve S, Ducrotté P, Lerebours E. Argon plasma coagulation in the treatment of hemorrhagic radiation proctitis is efficient but requires a perfect colonic cleansing to be safe. *Eur J Gastroenterol Hepatol* 2004; **16**: 1315-1318
- 32 **Monahan DW**, Peluso FE, Goldner F. Combustible colonic gas levels during flexible sigmoidoscopy and colonoscopy. *Gastrointest Endosc* 1992; **38**: 40-43
- 33 **Zanoni CE**, Bergamini C, Bertoncini M, Bertoncini L, Garbini A. Whole-gut lavage for surgery. A case of intraoperative colonic explosion after administration of mannitol. *Dis Colon Rectum* 1982; **25**: 580-581
- 34 **Freund PR**, Radke HM. Intraoperative explosion: methane gas and diet. *Anesthesiology* 1981; **55**: 700-701
- 35 **De Wilt JH**, Borel Rinkes IH, Brouwer KJ. Gas explosion during colonic surgery. *J R Coll Surg Edinb* 1996; **41**: 419
- 36 **Altomare DF**, Memeo V. Colonic explosion during diathermy colotomy. Report of a case. *Dis Colon Rectum* 1993; **36**: 291-292
- 37 **Sadanaga M**, Kano T, Morioka T. A case of colonic gas explosion caused by electrocautery. *J Anesth* 1992; **6**: 117-119
- 38 **Carter HG**. Explosion in the colon during electrodesiccation of polyps. *Am J Surg* 1952; **84**: 514-517
- 39 **Becker GL**. The prevention of gas explosions in the large bowel during electrosurgery. *Surg Gynecol Obstet* 1953; **97**: 463-467

S- Editor Liu Y L- Editor Kremer M E- Editor Li JL