

## GBM's multifaceted landscape: highlighting regional and microenvironmental heterogeneity

**Alenoush Vartanian, Sanjay K. Singh, Sameer Agnihotri, Shahrzad Jalali, Kelly Burrell, Kenneth D. Aldape, and Gelareh Zadeh**

*The Arthur and Sonia Labatt Brain Tumor Research Centre, Hospital for Sick Children, University of Toronto, Toronto, Ontario, Canada (A.V., S.K.S., S.A., S.J., K.B., G.Z.); Division of Neurosurgery, Toronto Western Hospital, University of Toronto, Toronto, Ontario, Canada (G.Z.); Department of Pathology, The University of Texas MD Anderson Cancer Center, Houston, Texas (K.D.A.)*

**Corresponding Author:** Gelareh Zadeh, MD, PhD, Division of Neurosurgery, Toronto Western Hospital, 4-439 West Wing, TWH399 Bathurst Street, Toronto, ON, M5T2S8 (gelareh.zadeh@uhn.ca).

Gliomas are a heterogeneous group of tumors that show variable proliferative potential, invasiveness, aggressiveness, histological grading, and clinical behavior. In this review, we focus on glioblastoma multiforme (GBM), a grade IV glioma, which is the most common and malignant of primary adult brain tumors. Research over the past several decades has revealed the existence of extensive cellular, molecular, genetic, epigenetic, and metabolic heterogeneity among tumors of the same grade and even within individual tumors. Evaluation of different tumor types has shown that tumors with advanced grade and clinical aggressiveness also display enhanced molecular, cellular, and microenvironmental heterogeneity. From a therapeutic standpoint, this heterogeneity is a major clinical hurdle for devising effective therapeutic strategies for patients and challenges personalized medicine.

In this review, we will highlight key aspects of GBM heterogeneity, directing special attention to regional heterogeneity, hypoxia, genomic heterogeneity, tumor-specific metabolic reprogramming, neovascularization or angiogenesis, and stromal immune cells. We will further discuss the clinical implications of GBM heterogeneity in the context of therapy.

**Keywords:** angiogenesis, glioblastoma, hypoxia, metabolism.

Despite years of research and numerous clinical trials, primary human brain tumors continue to be among the top 10 causes of cancer-related deaths, accounting for ~2.3% in Europe and North America.<sup>1</sup> Human brain tumors are a particularly diverse group of neoplasms comprising more than 120 clinicopathological entities (<http://www.brainumor.org>). The majority of the intrinsic neuroepithelial tumors in adults are classified as gliomas, encompassing a broad category of tumors with different growth rates, aggressiveness, and clinical outcomes.<sup>2,3</sup> Gliomas are divided into circumscribed tumors, the most common of which are the pilocytic astrocytomas, and diffuse gliomas. Diffuse gliomas are further classified according to presumed cell type (astrocytoma and oligodendroglioma) as well as tumor grade according to the World Health Organization (WHO)-derived guidelines. In order of increasing malignancy, these are: low-grade astrocytomas (LGAs)/oligodendroglioma, anaplastic astrocytoma/anaplastic oligodendroglioma, and glioblastoma multiforme (GBM), representing grades II, III, and IV, respectively.<sup>2,3</sup> While in the past GBM was presumed based on morphologic criteria, to be an “astrocytic” tumor the recent WHO guidelines call that assumption into question and point to the importance of molecular pathogenesis, rather than strict morphology, for

tumor classification. The present review focuses on GBM, which is the most common and aggressive of all adult primary brain neoplasms.<sup>2,3</sup> In Europe and North America, the incidence of GBM is ~3 new cases per 100 000 annually.<sup>2</sup> Similar to other types of cancers, increasing age correlates with higher incidence of GBM, with the median age of diagnosis being 64 years.<sup>4</sup> Despite the continual growth in the wealth of knowledge of GBM pathogenesis and therapeutic advancements, patient outcome is dismal for newly diagnosed GBM, with a median survival of 12–15 months postdiagnosis.<sup>5,6</sup> Relative to lower-grade diffuse gliomas, GBM exhibits more advanced histopathological features of malignancies, including tumor necrosis, microvascular proliferation, and elevated tumor cell proliferation.<sup>7,8</sup>

The unique histopathological features of GBM include intratumoral regional heterogeneity, comprising necrotic foci that are often surrounded by a hypercellular zone of “pseudopalisading” cells.<sup>8</sup> Pseudopalisades are known to be hypoxic and show induction of hypoxia-inducible factor 1 (HIF-1), as well as proangiogenic factors such as vascular endothelial growth factor (VEGF).<sup>9</sup> Variations in the extent and degree of hypoxia/necrosis in combination with variable angiogenic patterns represent a considerable problem in radiotherapeutics and antiangiogenic

Received 3 November 2013; accepted 16 February 2014

© The Author(s) 2014. Published by Oxford University Press on behalf of the Society for Neuro-Oncology. All rights reserved.

For permissions, please e-mail: [journals.permissions@oup.com](mailto:journals.permissions@oup.com).

management of GBM. These factors in combination with reprogramming of energy metabolism<sup>10</sup>—an essential metabolic hallmark of tumor cells—confer an additional layer of complexity onto the heterogeneous landscape of GBM.

In this review, we discuss advances in our understanding of GBM heterogeneity, with a focus on intratumoral regional heterogeneity, hypoxia, tumor-specific metabolic reprogramming, and neovascularization/angiogenesis. Also, we discuss the clinical implications of the microenvironmental heterogeneity of GBM with respect to future therapeutic opportunities.

## Regional Heterogeneity and Hypoxia

Histological evaluation of GBM tumors reveals the presence of anaplastic glial cells, marked mitotic activity, nuclear pleomorphism, and dense cellularity, as well as marked increase in microvascular proliferation.<sup>8</sup> However, the defining feature of grade IV GBM is the presence of hypoxic necrotic foci, often surrounded by a wave of pseudopalisading cells and the presence of highly vascular stroma.<sup>5</sup> More recent reports state that elevated tumor necrosis and vascular proliferation, although paradoxical, are interconnected phenomena such that either feature within a malignant tissue is a key determinant of GBM diagnosis and outcome.<sup>11</sup> Although pseudopalisades are frequently observed with high cellularity, they show decreased proliferation, increased level of apoptosis, and enhanced expression of hypoxic and proangiogenic markers compared with adjacent tumor tissue.<sup>12</sup> The prevailing hypothesis states that the central hypoxia drives the pseudopalisading cells away from the center (facilitated by elevated expression of matrix metalloproteinases 2 and 9) due to inadequate regional blood and nutrient supply.<sup>12</sup>

GBM is known to be one of the most highly vascularized tumors, with marked vascular density and angiogenesis. However, the newly formed vessels are highly tortuous and dysfunctional and commonly show intravascular thrombosis near the necrotic foci.<sup>9,13</sup> The compromised vascular integrity (regardless of vascular abundance) limits oxygen diffusion through the tissue, triggering formation of areas with low oxygen supply away from the main arterial supply. Investigations to understand the extent of hypoxia in GBM have shown that the disorganized and chaotic vascular network results in microenvironmental heterogeneity with a dynamic oxygen gradient (in terms of both level and pattern). Experimental models support increased level of hypoxia in high-grade gliomas. In turn, GBM is dominated by moderate to severely hypoxic cells, as well as a subpopulation of nonhypoxic cells.<sup>14,15</sup> Evans et al<sup>15</sup> investigated hypoxic regions *in vivo* in GBM and have shown that GBM cells contain dynamic oxygenation, with oxygen-concentration ranges of 2.5%–0.5% for mild hypoxia and 0.5%–0.1% for moderate to severe hypoxia. Variable levels and patterns of hypoxia likely promote clinical aggressiveness by promoting a malignant phenotype and negatively affecting treatment response and tumor recurrence.<sup>16</sup>

## Clinical Relevance of Hypoxia in GBM

Tissue necrosis and hypoxia have been shown to be correlated with enhanced tumor cell invasion and an aggressive tumor behavior.<sup>16,17</sup> Intratumoral heterogeneity in oxygenation in combination with molecular, mutational, and epigenetic variation is

considered to have a profound effect on the emergence of resistance to traditional treatment and ultimately tumor recurrence. It has been well documented that tumor tissue comprises diverse populations of cells with different radiosensitivity, and at least some of this has been linked to the dynamic level of oxygenation in the tumor. Hypoxia presents an obstacle for radiotherapy, which is the mainstay of adjuvant therapy for GBM (in combination with chemotherapy).<sup>18</sup> Under normoxic conditions, ionizing radiation produces DNA breaks and base damage.<sup>19</sup> The DNA damage is due to ionization of H<sub>2</sub>O in or very close to the DNA, which can produce free radicals that can attach to the DNA. Free radicals can interact with available oxygen to form highly reactive superoxide radicals, which in turn can produce DNA damage and chemically modify the DNA upon reaction. In the absence of oxygen, DNA lesions produced by free radicals may be reduced by sulfhydryl-containing compounds, restoring the DNA to its original composition.<sup>19,20</sup> Thus in hypoxia, potentially lethal DNA breaks produced by free radicals become less permanent following exposure to ionizing radiation.<sup>18</sup>

Moreover, limited circulation due to dysfunctional vascularization can impact drug delivery to the site of the tumor and result in chemotherapy resistance.<sup>21</sup> It has been suggested that hypoxic cells have a lower proliferative capacity, which would allow them to be specifically resistant to cytotoxic chemotherapeutic agents, as chemotherapeutics preferentially target cells with higher proliferative potential.<sup>21</sup>

Although hypoxia is detrimental to normal cells, cancer cells have undergone extensive genetic and adaptive changes that have allowed them to survive and even flourish in a hypoxic microenvironment. The emergence of evidence of hypoxia-related radioresistance has led to the development of strategies to resensitize tumors, such as the implementation of fractionated radiation and the use of hypoxia sensitizers that mimic oxygen.<sup>18</sup> Several hypoxia radiosensitizers, such as doranidazole, 2-nitroimidazoles, and efaproxiral, have also been identified and tested in many cancer types.<sup>18,22</sup> Preclinical findings have shown increased tumor cell death and improvements in overall local control.<sup>18,22,23</sup> However, clinical trials to date have failed to show an advantage of the use of radiosensitizers in brain tumors.<sup>24</sup>

## Genomic Heterogeneity

The use of comprehensive genome-wide approaches to analyze genetic and epigenetic alterations in GBM, as is done by The Cancer Genome Atlas, has strengthened our understanding of GBM's genetic and molecular landscape and revealed additional insights, such as the presence of unique prognostic or diagnostic biomarkers.<sup>25,26</sup> The nonuniform intratumoral pattern of genomic and epigenomic alterations in GBM, such as TP53 mutation, isocitrate dehydrogenase 1 mutation, epidermal growth factor receptor amplification/mutation, and O<sup>6</sup>-methylguanine-DNA methyltransferase promoter methylation, suggests the presence and coexistence of different clonal populations of cells that harbor heterogeneous and distinct growth advantage in the same tumor system.<sup>27</sup> Intratumoral molecular heterogeneity is clinically and therapeutically challenging, since only a subpopulation of tumor cells would be responsive to radiochemotherapy or targeted treatments such as epidermal growth factor receptor or

VEGF inhibitors. In such cases, treatment may lead to selective elimination or expansion of subpopulations of cells within the tumor tissue, setting in motion tumor recurrence or invasive tendencies of tumors.<sup>28</sup>

Most recently, expression profiling has provided new data recognizing the distinct molecular subgroups of GBM, each harboring unique molecular and genetic aberrations that drive tumorigenesis.<sup>29–32</sup> These subclassifications have acknowledged GBM patient profiles, with different prognoses and/or responsiveness to specific therapies. Verhaak and coworkers<sup>31</sup> proposed 4 distinct molecular patterns for primary GBM: proneural, neural, classical, and mesenchymal. Phillips and colleagues<sup>29</sup> recognized the proneural and mesenchymal subtypes as being the 2 principal categories in gliomas among other subclasses prior to the subgrouping by The Cancer Genome Atlas with distinct prognostic implications. Subtyping based on epigenetic criteria has further identified a glioma cytosine–phosphate–guanine island methylator phenotype (G-CIMP), where tumors contain a high percentage of common hypermethylation at a large number of loci.<sup>30,32</sup> GBM positive for G-CIMP clusters closely with secondary GBM and strongly correlates with patient age (younger patients) as well as mutations of isocitrate dehydrogenase 1. Patients positive for G-CIMP exhibit improved outcome compared with G-CIMP–negative subjects, but only under conditions of classification with exclusive prognostic value.<sup>32</sup>

These classifications substantiate GBM's complex landscape and bring hope for future personalized therapies for patients with distinct molecular signatures. The successful treatment of GBM requires thorough investigation of factors that underlie GBM pathogenesis, with the ultimate goal of translating laboratory-found genomic data to the clinic to distinguish the real drivers behind gliomagenesis.<sup>32</sup>

## Metabolic Reprogramming

In brain tumors—specifically GBM—heterogeneity in oxygen concentration can act as a catalyst for expression of factors regulating aerobic glycolysis or lactate production or signaling pathways that regulate aerobic glycolysis.<sup>14</sup> Tumor cells exhibit various metabolic anomalies; however, preferential metabolism of glucose to lactate, regardless of oxygen availability, is perhaps the most studied and principal to tumor cell proliferation and aggressiveness.<sup>10</sup> This phenomenon is commonly known as aerobic glycolysis, or the Warburg effect, since it was first discovered by Otto Warburg in the 1920s, for which he was awarded the Nobel prize.<sup>33,34</sup> The Warburg phenomenon is often accompanied by increased glucose uptake, high rate of glycolysis, partial mitochondrial suppression/underactivation, and reduced oxygen consumption.<sup>33–35</sup> With an increased understanding of metabolic reprogramming in cancer and its mechanistic and therapeutic implications, there has been increased interest in this phenomenon since the first observations by Warburg that glucose metabolism is fundamentally different in cancer cells compared with normal tissue.<sup>33</sup> The Warburg effect is a well-known metabolic hallmark of many tumor cells<sup>35</sup> and has been documented in several types of cancers, including GBM. Metabolic adaptation can be influenced by environmental factors such as hypoxia and the status of oncogenes and tumor suppressors. Under

hypoxic conditions, the reliance on aerobic glycolysis can become fundamental for proliferating cells.<sup>35</sup>

Solid tumors such as GBM frequently harbor populations of cancer cells with dynamic oxygen gradients, and as alluded to above, one of the major players in hypoxia adaptation is activation and stabilization of HIF-1 $\alpha$  and -2 $\alpha$ .<sup>36</sup> HIF induction leads to activation of a cascade of downstream targets with a broad functional consequence in various cancers.<sup>37–39</sup> The most fundamental result of HIF-1 $\alpha$  activation is a shift in energy status associated with activation of pathways involved in cellular metabolism and angiogenesis, ultimately resulting in regulation of oxygen delivery and consumption.<sup>40</sup> Hypoxia orchestrates an adaptation of tumor cells to metabolic stress by induction of nearly all known genes that encode glycolytic enzymes and glucose transporters (GLUT1 and GLUT3) as well as lactate exporters and pH regulators (monocarboxylate transporters [MCTs], carbonic anhydrases).<sup>37,41</sup> Stability of HIF-1 transcription factors can promote the expression of multiple metabolic proteins, such as hexokinase 2 (HK2), phosphofructokinase 1, aldolase, glyceraldehyde-3-phosphate dehydrogenase, lactate dehydrogenase, plasma membrane MCT1 or MCT4, and carbonic anhydrases 9 and 12, which could in turn stimulate the glycolytic flux and facilitate lactate shuttling into the extracellular space.<sup>37,38,41</sup> Simultaneously, HIF-1 $\alpha$  can limit mitochondrial oxidative metabolism and suppress pyruvate entry to the tricarboxylic acid (TCA) cycle.<sup>37,38,41</sup> HIF-1 transcription factors can upregulate the expression of pyruvate dehydrogenase kinase 1 (PDK1), which inhibits mitochondrial pyruvate dehydrogenase activity, thus attenuating pyruvate oxidation in the TCA cycle and in turn increasing lactate buildup in the cytosol.<sup>37,38,41</sup> HIF-1 $\alpha$  also augments angiogenesis and endothelial cell proliferation by increasing the expression of angiogenic factors such as VEGF-A and angiopoietins.<sup>42</sup>

Other molecular mechanisms involving known oncogenes and tumor suppressors have been implicated to converge and regulate different steps of the metabolic pathways.<sup>43</sup> The close interplay between metabolic enzymes and transcriptional regulators may establish a heterogeneous metabolic microenvironment within a tumor. For instance, *PI3K/Akt*, *TP53*, and *Myc* are 3 key genes that are often altered in cancers and can drive and promote changes in metabolism.<sup>43</sup> Prior work has indicated that these networks of regulation orchestrate a state of high glucose uptake/flux and activate genes involved in the glycolysis (*PI3K/Akt/TP53*),<sup>43–45</sup> glutaminolysis (*TP53/Myc*), and lipid synthesis (*PI3K/Akt*)<sup>46,47</sup> pathways.<sup>48,49</sup> Thus, it is suggested that oncogenic and tumor suppressive mutations may foster tumor growth by means of metabolic reprogramming to meet the bioenergetic demand of the cell.<sup>50</sup>

GBM is highly glycolytic in nature, with a propensity to metabolize glucose to lactate even when ample oxygen is present, a feature common in most malignant or proliferating tumors.<sup>51,52</sup> Tumor-specific enzyme modification such as isoform switching (pyruvate kinase M2, lactate dehydrogenase) or metabolic enzyme overexpression (HK2, PDK1, or GLUT1/4) has been documented in GBM cells.<sup>53–56</sup> These metabolic anomalies are in contrast to nonneoplastic brain tissue, where glycolysis primarily occurs under anaerobic conditions.

Prior studies by our group have shown that preferential expression of HK2, which is the first enzyme of glycolysis, is a critical mediator of metabolic reprogramming in GBM compared with LGAs and normal brain tissue.<sup>56</sup> In vitro HK2 depletion was shown to

inhibit aerobic glycolysis, increase normal oxidative respiration, and induce apoptosis (especially under hypoxia) and in turn conferred a survival advantage in GBM xenograft models.<sup>56</sup> PDK1 is another perpetrator of aerobic glycolysis, which is upregulated in most cancer cells, including GBM. Inhibitors of PDK1 such as dichloroacetate have been shown to have an anticancer effect by shifting metabolism from glycolysis to glucose oxidation and inducing apoptosis in GBM cells.<sup>53,57</sup>

It is becoming apparent that metabolic needs of tumor cells are dynamic. Several reports have shown variability in GBM with respect to glucose reliance and mitochondrial oxidative respiration.<sup>58,59</sup> Temporal and regional fluctuation in oxygen consumption,<sup>60</sup> hypoxia sensitivity, and in turn the Warburg effect are reported in GBM cell lines derived from GBM patients and established GBM xenografts.<sup>61–63</sup> More recently, metabolic symbiosis between hypoxic and aerobic tumor cells was demonstrated where lactate produced in hypoxic cells could be taken up by cancer cells and used as a fuel in a region where oxygen is adequate.<sup>64–66</sup> A similar symbiotic relationship has also been shown between cancer cells and cancer-associated fibroblastic cells, where different populations share energy resources to maximize metabolic efficiency.<sup>67</sup> A recent paper by Marin-Valencia et al.<sup>68</sup> presents a different paradigm regarding metabolic behavior of GBM in vivo. By using carbon-13 nuclear magnetic resonance spectroscopy of tumor tissue and normal brain extracts, they show that GBM cells in their native microenvironment demonstrate mitochondrial glucose oxidation via pyruvate dehydrogenase and the TCA cycle.<sup>68</sup>

Although now recognized as one of the major players in cancer pathogenesis, the significance of metabolic heterogeneity in GBM treatment and prognosis is still in its infancy and requires further evaluation. Understanding and decoding the interconnected microenvironmental network of genes involved in metabolic, hypoxic, and angiogenic reprogramming of cells can potentially provide insights into clinically relevant avenues for tumor classification and therapy.

## Clinical Relevance of Metabolic Reprogramming in GBM

Most cancer cells show alterations in their metabolic signature compared with normal tissue. Noninvasive imaging techniques have been successful in providing unique information and identifying variability of tumors on a range of biological processes, such as oxygen consumption, glucose/glutamine metabolism, and protein synthesis, as well as lactate levels in brain tumors.<sup>69</sup>

A number of groups have investigated the possibility of testing global inhibitors of glycolysis either singularly or in combination with other anticancer agents such as radiotherapy and chemotherapy in various cancer types, including gliomas. There are several lines of evidence showing increased efficacy of pharmacological inhibitors of glycolysis such as 2-deoxyglucose,<sup>70</sup> 3-bromopyruvate,<sup>71,72</sup> lonidamine,<sup>73–75</sup> and dichloroacetate<sup>53,57</sup> by combining these agents with cytotoxic therapies through promotion of apoptotic cell death.

Targeting key metabolic enzymes involved in modulating the Warburg effect would provide a unique paradigm for the management of brain tumors; however, results from clinical trials have not been very promising to date.<sup>53,74–77</sup> The major

challenges are in obtaining high selectivity and eliminating unwanted toxicity caused by off-target effects.

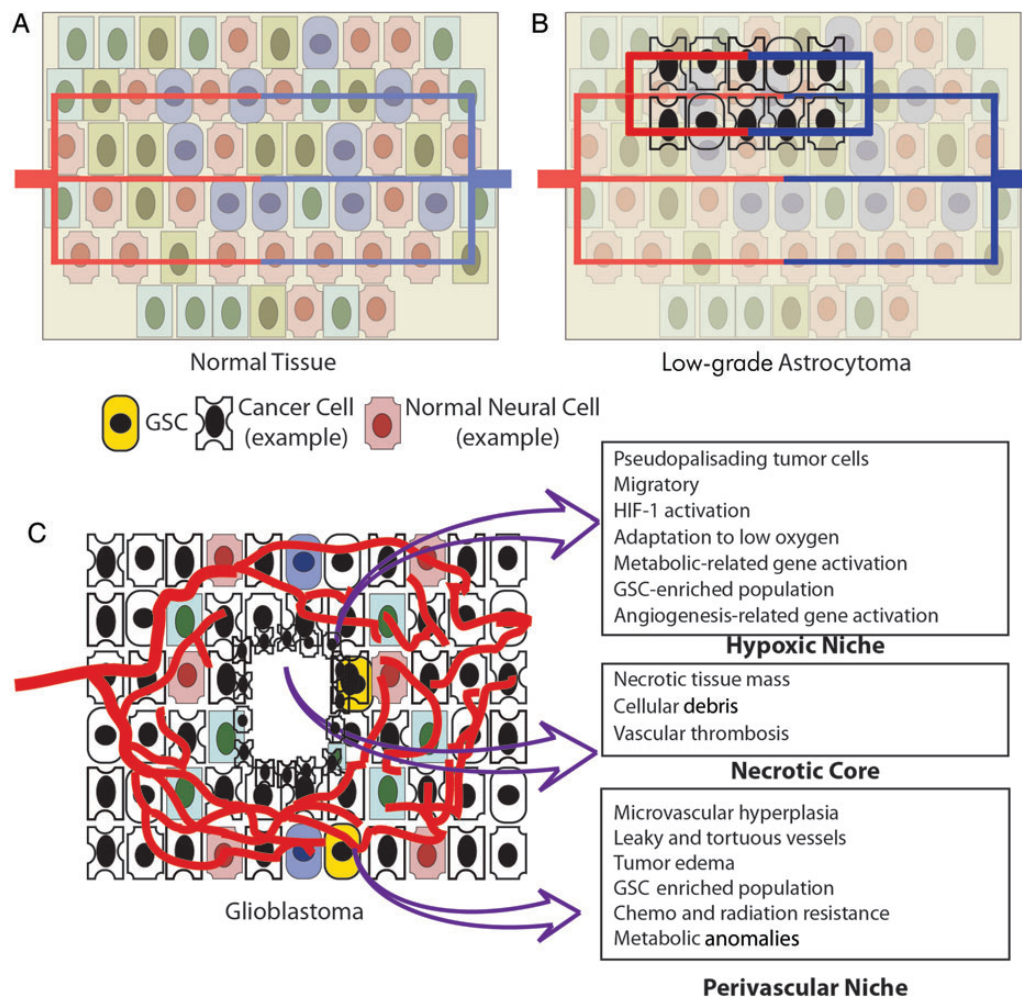
A recent report illustrates how genetic alterations in GBM can potentially be exploited as therapeutic options. Enolase 1 (ENO1) is located at the 1p36 tumor-suppressor locus. ENO1 deletion makes GBM specifically dependent on ENO2. Thus, blockade of ENO2 activity in ENO1-null GBM will have significant lethality in GBM cells with minimal side effects in normal cells where both ENO1 and 2 are expressed.<sup>78</sup>

A key to understanding metabolic reprogramming and taking advantage of it therapeutically lies in the determination of not only critical enzymatic players but also in the integration of genomic, epigenetic, and metabolomic profiles of GBM tumors in different stages of tumor growth or recurrence.

## Neovascularization and Angiogenesis

One aspect of the microenvironment that differs in normal versus tumor tissue is the pattern and the extent of vascularization.<sup>8,79</sup> As neoplastic cells grow in size, their metabolic and nutritional demands also expand.<sup>80</sup> Adaptation to a microenvironmental stressor such as hypoxia or metabolic scarcity necessitates incorporation of exogenous processes such as formation and implementation of new vascular supply in areas most deprived of oxygen or nutrients.<sup>80,81</sup> As discussed above, astrocytic neoplasms are considered to be among the most vascularized of human neoplasms.<sup>8</sup> Transformation of gliomas from LGAs to high-grade GBM is accompanied by robust alterations in microvessel morphology and the overall vascular network.<sup>82</sup> Astrocytic microvascular architecture is tumor stage dependent and grade specific and differs even among tumors within the same grade.<sup>82</sup> Vascular density is slightly larger in LGAs compared with normal brain vessels. However, malignant transformation to high-grade GBM is accompanied by marked increase in the vessel density and striking changes in microvascular morphology and in turn its functionality.<sup>83,84</sup> (Fig. 1). This so-called angiogenic switch is considered to be a critical tipping point during tumor growth that is partly induced by upregulation of proangiogenic factors, cytokines, and receptors principal to establishment of new blood vessels.<sup>80,81</sup> A cascade of events such as hypoxia, adaptation of tumor cells to rapid growth, alteration of the microvasculature architecture, and synthesis of proangiogenic growth factors and cytokines triggers the onset of pathogenic vessel formation. Microvasculature heterogeneity dictated by regional and temporal differences in hypoxia and nutrition supply is a well-known phenomenon in GBM. It is postulated that the initial stages of tumor growth are associated with co-option of preexisting vessels by neoplastic cells.<sup>42,85</sup> This process is independent of angiogenesis and results in a failure to supply adequate nutrients despite the metabolic demand.<sup>42</sup> In the next phase of neoplastic progression, when metabolic demand of the tumor mass has exceeded the supply, the interior co-opted vessels regress and cellular hypoxia occurs.<sup>42</sup> The result is generation of new vessels from preexisting vasculature through sprouting of new capillaries, a process known as angiogenesis.<sup>42,86,87</sup> Angiogenesis is a complex process that involves proteolytic degradation of extracellular matrix to open the path for new vessels to arise, as well as accelerated endothelial cell proliferation and migration and establishment of new basement membrane.<sup>42</sup> It has been argued that





**Fig. 1.** Schematic representation of events with respect to vasculature, metabolism, and cellular heterogeneity in GBM. GSC, glioma stem cell. (A) Normal tissue displaying regular blood supply. (B) In LGAs, the slight increase in hyperproliferation of cancer cells is associated with increased microvessel proliferation. (C) In GBM, there is a marked increase in abnormal vasculature that further dictates regional heterogeneity. The texts in boxes display salient features of each of the regions commonly reported in GBM.

angiogenesis by itself is insufficient to explain the complex re-modeling of the vascular network. It is imperative to implement an additional mode of vascular adaptation to meet the metabolic demand of growing tumor, so-called *de novo* vasculogenesis, the formation of vessels from hematopoietic precursor cells.<sup>88</sup> In the process of vascularization, several angiogenic factors, such as VEGF-A, matrix metalloproteinase 2, and/or angiopoietin-1 work alongside to stimulate and maintain endothelial cell proliferation, migration, survival, permeability, and lumen formation.<sup>88,89</sup> As mentioned, tumor tissue incorporates new vasculature; however, the vessel microarchitecture is often anarchic and functionally aberrant. Imaging techniques have shown that GBM contains microvasculature that is tortuous, irregular, and dilated.<sup>83,84</sup> Consequently the blood perfusion is nonuniform and can further lead to hypoxia, ischemia, and thrombosis.

GBM exhibits vascular clusterings called glomeruloid bodies or vascular tufts due to their resemblance to renal glomeruli.<sup>79,90</sup> These structures are composed of small vascular channels lined by heterogeneous hyperplastic endothelial cells, pericytes, and

smooth muscle cells.<sup>47,48</sup> Although their functional relevance is not well understood in astrocytomas, they are ominous prognostic markers in other forms of cancer.<sup>11</sup> Moreover, immature angiogenic vessel walls and incompetent blood-brain barrier (BBB) have been linked to leaky vessels with increased permeability that may have a contributing effect on tumor edema and associated morbidity in GBM patients. Pericytes, which have a perivascular supporting function for endothelial cells, are atypical and show reduced coverage, which may further contribute to increased vascular permeability and hemorrhage. It is important to mention that GBM harbors partially disrupted BBB.<sup>91</sup> The extent of BBB disruption may well vary among patients or within different regions of a single tumor.<sup>92</sup> Therefore, intact BBB could pose a significant obstacle for the delivery of molecular targets or chemotherapeutics to brain tumors.<sup>92</sup>

Heterogeneity in the GBM microvasculature can impact distribution of chemotherapy drugs within the tumor or result in a variable response to antiangiogenic therapies.<sup>13</sup> Also, intratumoral variability in regions of hypoxia, necrosis, and cellular proliferation

can critically influence the angiogenic response within the tumor.<sup>13</sup> Dynamic hypoxia leads to variable expression of molecular markers of hypoxia, including HIF-1 $\alpha$  and its downstream targets, such as VEGF, in turn giving rise to tumors with multifaceted angiogenic gene expression.<sup>18</sup> A recent study incorporated differential expression of angiogenesis-related transcripts to generate a molecular signature capable of discriminating varying grades and subtypes of astrocytomas.<sup>93</sup> Another study investigated changes in vasculoarchitecture in different phases of tumor growth in GBM xenografts. Regional differences in tumor hypoxia as well as intratumoral heterogeneity in the architecture of the tumor vasculature were shown to develop with increasing tumor size.<sup>94</sup> Recently, fractal analysis of human GBM specimens showed considerable heterogeneity in the microvascular architecture, including the density, shape, magnitude, and pattern of distribution of microvessels among different histological specimens of similar grade.<sup>95,96</sup> These results suggest that human brain tumors exhibit variable angiogenic/vasculogenic patterns,<sup>93</sup> and individual tumors within the same histological grade may show a highly heterogeneous angioarchitecture.<sup>97,98</sup> Vascular heterogeneity adds another layer of complexity to microenvironmental or metabolic variability in GBM. Understanding and decoding the interconnected microenvironmental network of players involved in metabolic, hypoxic, and angiogenic reprogramming of the cells could prove valuable and provide new insights for diagnosis and therapy.

## Clinical Relevance of Neovascularization and Angiogenesis

Inhibiting blood vessel formation has been shown to be a promising strategy for GBM treatment in the recurrent setting. Antiangiogenic therapies have been extensively tested in preclinical and clinical settings in North America and Europe.<sup>68,99–102</sup> Bevacizumab (Avastin), a humanized monoclonal antibody against VEGF, has been approved by the FDA for the treatment of recurrent GBM in the United States.<sup>101,103</sup> Bevacizumab therapy has been shown to prolong progression-free survival in a subset of newly diagnosed GBM patients; however, unfortunately no improvement in overall survival is seen and patients invariably relapse.<sup>103</sup> The use of antiangiogenic therapies has been controversial due to concerns regarding infiltrative and a more aggressive pattern of recurrence following treatment.<sup>104,105</sup> Currently 2 large international randomized phase III clinical trials (AVAglio and RTOG 0825) with bevacizumab in combination with radiochemotherapy have been completed for newly diagnosed GBM, and preliminary indications are that the addition of bevacizumab does not improve overall survival in the newly diagnosed setting.<sup>106</sup> Full reporting of these studies will be instrumental in determining the efficacy of combining bevacizumab with standard therapies in GBM.

## Conclusion and Future Outlook

In the last 20 years, concurrent use of temozolomide with radiation therapy has been the only major advancement in the management of newly diagnosed GBM patients, providing only a 16% increase in patient survival up to 2 years postdiagnosis (from 10% to 26%).<sup>107</sup> This incremental improvement in patient survival

suggests that new therapeutic approaches that integrate and combine novel targeted therapies with standard treatments such as radiochemotherapy are warranted. Extensive genomic and microenvironmental complexities among patients with the same histopathological tumor subtype as well as within a single tumor have become apparent in GBM, which increases the challenge. Heterogeneity in GBM's genetics, metabolomics, or epigenetics may explain the failure of identification of robust predictive markers that could improve therapeutic outcome and minimize drug resistance.<sup>108</sup>

There is an evolving recognition of the important role of metabolic heterogeneity and regional hypoxia in regulating neoplastic transformation and therapeutic responsiveness. The specific role of microenvironmental factors and their interactions with inherent molecular and genetic variability in GBM should be taken into consideration during treatment and therapy stratification. Rational treatment strategies in which therapies are individually tailored based on metabolic and regional heterogeneity represent an important step required to tackle the heterogeneous nature of GBM.

## Funding

This work was supported by funding from the Canadian Institutes of Health Research to G.Z.

*Conflict of interest statement.* None declared.

## References

1. Central Brain Tumor Registry of the United States. Primary brain and central nervous system tumors diagnosed in the United States in 2004–2006. *J Neurooncol.* 2013;15:ii1–ii56.
2. Fuller GN, Scheithauer BW. The 2007 revised World Health Organization (WHO) classification of tumours of the central nervous system: newly codified entities. *Brain Pathol.* 2007;17(3):304–307.
3. Louis DNOH, Wiestler OD, Cavenee WK. *WHO Classification of Tumours of the Central Nervous System.* Lyon, France: International Agency for Research; 2007.
4. Adamson C, Kanu OO, Mehta AI, et al. Glioblastoma multiforme: a review of where we have been and where we are going. *Expert Opin Investig Drugs.* 2009;18(8):1061–1083.
5. Bai RY, Staedtke V, Riggins GJ. Molecular targeting of glioblastoma: drug discovery and therapies. *Trends Mol Med.* 2011;17(6):301–312.
6. Nobusawa S, Lachuer J, Wierinckx A, et al. Intratumoral patterns of genomic imbalance in glioblastomas. *Brain Pathol.* 2010;20(5):936–944.
7. Kleihues P, Cavenee WK, eds. *Pathology and Genetics of Tumours of the Nervous System. World Health Organization Classification of Tumours.* Lyon, France: IARC Press; 2000.
8. Wen PY, Kesari S. Malignant gliomas in adults. *N Engl J Med.* 2008;359(5):492–507.
9. Rong Y, Durden DL, Van Meir EG, et al. 'Pseudopalisading' necrosis in glioblastoma: a familiar morphologic feature that links vascular pathology, hypoxia, and angiogenesis. *J Neuropathol Exp Neurol.* 2006;65(6):529–539.

10. Vander Heiden MG, Cantley LC, Thompson CB. Understanding the Warburg effect: the metabolic requirements of cell proliferation. *Science*. 2009;324(5930):1029–1033.
11. Tehrani M, Friedman TM, Olson JJ, et al. Intravascular thrombosis in central nervous system malignancies: a potential role in astrocytoma progression to glioblastoma. *Brain Pathol*. 2008; 18(2):164–171.
12. Brat DJ, Castellano-Sanchez AA, Hunter SB, et al. Pseudopalisades in glioblastoma are hypoxic, express extracellular matrix proteases, and are formed by an actively migrating cell population. *Cancer Res*. 2004;64(3):920–927.
13. Jain RK. Molecular regulation of vessel maturation. *Nat Med*. 2003; 9(6):685–693.
14. Brat DJ, Evans SM. Molecular heterogeneity and tumor microenvironment. In: Mehta MPed. *Principles and Practice of Neuro-Oncology: A Multidisciplinary Approach*. New York: Demos Medical Publishing; 2010:100–111.
15. Evans SM, Judy KD, Dunphy I, et al. Comparative measurements of hypoxia in human brain tumors using needle electrodes and EF5 binding. *Cancer Res*. 2004;64(5):1886–1892.
16. Yang L, Lin C, Wang L, et al. Hypoxia and hypoxia-inducible factors in glioblastoma multiforme progression and therapeutic implications. *Exp Cell Res*. 2012;318(19):2417–2426.
17. Evans SM, Judy KD, Dunphy I, et al. Hypoxia is important in the biology and aggression of human glial brain tumors. *Clin Cancer Res*. 2004;10(24):8177–8184.
18. Bristow RG, Hill RP. Hypoxia and metabolism. Hypoxia, DNA repair and genetic instability. *Nat Rev Cancer*. 2008;8(3):180–192.
19. Brown JM, Wilson WR. Exploiting tumour hypoxia in cancer treatment. *Nat Rev Cancer*. 2004;4(6):437–447.
20. Hall EJ, Giaccia AJ. Oxygen Effect and Reoxygenation. In: Hall EJ, Giaccia AJ, eds. *Radiobiology for the radiologist*. 6th ed. Lippincott Williams & Wilkins; 2006:85–105.
21. Brown JM. Exploiting the hypoxic cancer cell: mechanisms and therapeutic strategies. *Mol Med Today*. 2000;6(4):157–162.
22. Yasui H, Asanuma T, Kino J, et al. The prospective application of a hypoxic radiosensitizer, doranidazole to rat intracranial glioblastoma with blood brain barrier disruption. *BMC Cancer*. 2013;13:106.
23. Nagasawa H, Uto Y, Kirk KL, et al. Design of hypoxia-targeting drugs as new cancer chemotherapeutics. *Biol Pharm Bull*. 2006;29(12): 2335–2342.
24. Engel RH, Kaklamani VG. Role of efaproxiral in metastatic brain tumors. *Expert Rev Anticancer Ther*. 2006;6(4):477–485.
25. Ohgaki H, Dessen P, Jourde B, et al. Genetic pathways to glioblastoma: a population-based study. *Cancer Res*. 2004;64(19): 6892–6899.
26. The Cancer Genome Atlas Research Network. Comprehensive genomic characterization defines human glioblastoma genes and core pathways. *Nature*. 2008;455(7216):1061–1068.
27. Sottoriva A, Spiteri I, Piccirillo SG, et al. Intratumor heterogeneity in human glioblastoma reflects cancer evolutionary dynamics. *Proc Natl Acad Sci U S A*. 2013;110(10):4009–4014.
28. Bonavia R, Inda MM, Cavenee WK, et al. Heterogeneity maintenance in glioblastoma: a social network. *Cancer Res*. 2011; 71(12):4055–4060.
29. Phillips HS, Kharbanda S, Chen R, et al. Molecular subclasses of high-grade glioma predict prognosis, delineate a pattern of disease progression, and resemble stages in neurogenesis. *Cancer Cell*. 2006;9(3):157–173.
30. Noshmehr H, Weisenberger DJ, Diefes K, et al. Identification of a CpG island methylator phenotype that defines a distinct subgroup of glioma. *Cancer Cell*. 2010;17(5):510–522.
31. Verhaak RG, Hoadley KA, Purdom E, et al. Integrated genomic analysis identifies clinically relevant subtypes of glioblastoma characterized by abnormalities in PDGFRA, IDH1, EGFR, and NF1. *Cancer Cell*. 2010;17(1):98–110.
32. Zheng S, Chheda MG, Verhaak RG. Studying a complex tumor: potential and pitfalls. *Cancer J*. 2012;18(1):107–114.
33. Warburg O. On the origin of cancer cells. *Science*. 1956;123: 309–314.
34. Warburg O. On respiratory impairment in cancer cells. *Science*. 1956;124(3215):269–270.
35. Hanahan D, Weinberg RA. Hallmarks of cancer: the next generation. *Cell*. 2011;144(5):646–674.
36. Brat DJ, Mapstone TB. Malignant glioma physiology: cellular response to hypoxia and its role in tumor progression. *Ann Intern Med*. 2003;138(8):659–668.
37. Semenza GL. HIF-1: upstream and downstream of cancer metabolism. *Curr Opin Genet Dev*. 2010;20(1):51–56.
38. Said HM, Hagemann C, Staab A, et al. Expression patterns of the hypoxia-related genes osteopontin, CA9, erythropoietin, VEGF and HIF-1alpha in human glioma in vitro and in vivo. *Radiother Oncol*. 2007;83(3):398–405.
39. Harris AL. Hypoxia—a key regulatory factor in tumour growth. *Nat Rev Cancer*. 2002;2(1):38–47.
40. Wang GL, Jiang BH, Rue EA, et al. Hypoxia-inducible factor 1 is a basic-helix-loop-helix-PAS heterodimer regulated by cellular O2 tension. *Proc Natl Acad Sci U S A*. 1995;92(12):5510–5514.
41. Semenza GL. Targeting HIF-1 for cancer therapy. *Nat Rev Cancer*. 2003;3(10):721–732.
42. Bulnes S, Bengoetxea H, Ortuzar N, et al. Angiogenic signalling pathways altered in gliomas: selection mechanisms for more aggressive neoplastic subpopulations with invasive phenotype. *J Signal Transduct*. 2012;2012:Article ID 597915.
43. Ward PS, Thompson CB. Metabolic reprogramming: a cancer hallmark even Warburg did not anticipate. *Cancer Cell*. 2012; 21(3):297–308.
44. DeBerardinis RJ, Lum JJ, Hatzivassiliou G, et al. The biology of cancer: metabolic reprogramming fuels cell growth and proliferation. *Cell Metab*. 2008;7(1):11–20.
45. Fang M, Shen Z, Huang S, et al. The ER UDPase ENTPD5 promotes protein N-glycosylation, the Warburg effect, and proliferation in the PTEN pathway. *Cell*. 2010;143(5):711–724.
46. Bauer DE, Hatzivassiliou G, Zhao F, et al. ATP citrate lyase is an important component of cell growth and transformation. *Oncogene*. 2005;24(41):6314–6322.
47. Berwick DC, Hers I, Heesom KJ, et al. The identification of ATP-citrate lyase as a protein kinase B (Akt) substrate in primary adipocytes. *J Biol Chem*. 2002;277(37):33895–33900.
48. Green DR, Chipuk JE. p53 and metabolism: inside the TIGAR. *Cell*. 2006;126(1):30–32.
49. Bensaad K, Tsuruta A, Selak MA, et al. TIGAR, a p53-inducible regulator of glycolysis and apoptosis. *Cell*. 2006;126(1):107–120.
50. Cantor JR, Sabatini DM. Cancer cell metabolism: one hallmark, many faces. *Cancer Discov*. 2012;2(10):881–898.

51. Walenta S, Schroeder T, Mueller-Klieser W. Lactate in solid malignant tumors: potential basis of a metabolic classification in clinical oncology. *Curr Med Chem*. 2004;11(16):2195–2204.
52. Walenta S, Mueller-Klieser WF. Lactate: mirror and motor of tumor malignancy. *Semin Radiat Oncol*. 2004;14(3):267–274.
53. Michelakis ED, Sutendra G, Dromparis P, et al. Metabolic modulation of glioblastoma with dichloroacetate. *Sci Transl Med*. 2010;2(31):31–34.
54. Marie SK, Shinjo SM. Metabolism and brain cancer. *Clinics (Sao Paulo)*. 2011;66(Suppl 1):33–43.
55. Colen CB, Shen Y, Ghoddoussi F, et al. Metabolic targeting of lactate efflux by malignant glioma inhibits invasiveness and induces necrosis: an in vivo study. *Neoplasia*. 2011;13(7):620–632.
56. Wolf A, Agnihotri S, Micallef J, et al. Hexokinase 2 is a key mediator of aerobic glycolysis and promotes tumor growth in human glioblastoma multiforme. *J Exp Med*. 2010;208:313–326.
57. Michelakis ED, Webster L, Mackey JR. Dichloroacetate (DCA) as a potential metabolic-targeting therapy for cancer. *Br J Cancer*. 2008;99(7):989–994.
58. Lichtor T, Dohrmann GJ. Respiratory patterns in human brain tumors. *Neurosurgery*. 1986;19(6):896–899.
59. Griguer CE, Oliva CR, Gillespie GY. Glucose metabolism heterogeneity in human and mouse malignant glioma cell lines. *J Neurooncol*. 2005;74(2):123–133.
60. Hardee ME, Dewhirst MW, Agarwal N, et al. Novel imaging provides new insights into mechanisms of oxygen transport in tumors. *Curr Mol Med*. 2009;9(4):435–441.
61. Allalunis-Turner MJ, Franko AJ, Parliament MB. Modulation of oxygen consumption rate and vascular endothelial growth factor mRNA expression in human malignant glioma cells by hypoxia. *Br J Cancer*. 1999;80(1–2):104–109.
62. Parliament MB, Franko AJ, Allalunis-Turner MJ, et al. Anomalous patterns of nitroimidazole binding adjacent to necrosis in human glioma xenografts: possible role of decreased oxygen consumption. *Br J Cancer*. 1997;75(3):311–318.
63. Turcotte ML, Parliament M, Franko A, et al. Variation in mitochondrial function in hypoxia-sensitive and hypoxia-tolerant human glioma cells. *Br J Cancer*. 2002;86(4):619–624.
64. Bonuccelli G, Whitaker-Menezes D, Castello-Cros R, et al. The reverse Warburg effect: glycolysis inhibitors prevent the tumor promoting effects of caveolin-1 deficient cancer associated fibroblasts. *Cell Cycle*. 2010;9(10):1960–1971.
65. Martinez-Outschoorn UE, Pavlides S, Howell A, et al. Stromal-epithelial metabolic coupling in cancer: integrating autophagy and metabolism in the tumor microenvironment. *Int J Biochem Cell Biol*. 2011;43(7):1045–1051.
66. Pavlides S, Whitaker-Menezes D, Castello-Cros R, et al. The reverse Warburg effect: aerobic glycolysis in cancer associated fibroblasts and the tumor stroma. *Cell Cycle*. 2009;8(23):3984–4001.
67. Hanahan D, Coussens LM. Accessories to the crime: functions of cells recruited to the tumor microenvironment. *Cancer Cell*. 2012;21(3):309–322.
68. Marin-Valencia I, Yang C, Mashimo T, et al. Analysis of tumor metabolism reveals mitochondrial glucose oxidation in genetically diverse human glioblastomas in the mouse brain in vivo. *Cell Metab*. 2012;15(6):827–837.
69. Dhermain FG, Hau P, Lanfermann H, et al. Advanced MRI and PET imaging for assessment of treatment response in patients with gliomas. *Lancet Neurol*. 2010;9(9):906–920.
70. Yang C, Sudderth J, Dang T, et al. Glioblastoma cells require glutamate dehydrogenase to survive impairments of glucose metabolism or Akt signaling. *Cancer Res*. 2009;69(20):7986–7993.
71. Ko YH, Smith BL, Wang Y, et al. Advanced cancers: eradication in all cases using 3-bromopyruvate therapy to deplete ATP. *Biochem Biophys Res Commun*. 2004;324(1):269–275.
72. Ganapathy-Kanniappan S, Vali M, Kunjithapatham R, et al. 3-bromopyruvate: a new targeted antiglycolytic agent and a promise for cancer therapy. *Curr Pharm Biotechnol*. 2010;11(5):510–517.
73. Rosbe KW, Brann TW, Holden SA, et al. Effect of lonidamine on the cytotoxicity of four alkylating agents in vitro. *Cancer Chemother Pharmacol*. 1989;25(1):32–36.
74. Carapella CM, Paggi MG, Cattani F, et al. The potential role of lonidamine (LND) in the treatment of malignant glioma. Phase II study. *J Neurooncol*. 1989;7(1):103–108.
75. Oudard S, Carpentier A, Banu E, et al. Phase II study of lonidamine and diazepam in the treatment of recurrent glioblastoma multiforme. *J Neurooncol*. 2003;63(1):81–86.
76. Prasanna VK, Venkataramana NK, Dwarakanath BS, et al. Differential responses of tumors and normal brain to the combined treatment of 2-DG and radiation in glioblastoma. *J Cancer Res Ther*. 2009;5(Suppl 1):S44–S47.
77. Simons AL, Ahmad IM, Mattson DM, et al. 2-Deoxy-D-glucose combined with cisplatin enhances cytotoxicity via metabolic oxidative stress in human head and neck cancer cells. *Cancer Res*. 2007;67(7):3364–3370.
78. Muller FL, Colla S, Aquilanti E, et al. Passenger deletions generate therapeutic vulnerabilities in cancer. *Nature*. 2012;488(7411):337–342.
79. Zadeh G, Guha A. Angiogenesis in nervous system disorders. *Neurosurgery*. 2003;53(6):1362–1374; discussion 1374–1376.
80. Bergers G, Benjamin LE. Tumorigenesis and the angiogenic switch. *Nat Rev Cancer*. 2003;3(6):401–410.
81. Hanahan D, Folkman J. Patterns and emerging mechanisms of the angiogenic switch during tumorigenesis. *Cell*. 1996;86(3):353–364.
82. Louis DN, Ohgaki H, Wiestler OD, et al. The 2007 WHO classification of tumours of the central nervous system. *Acta Neuropathol*. 2007;114(2):97–109.
83. Bulnes S, Bilbao J, Lafuente JV. Microvascular adaptive changes in experimental endogenous brain gliomas. *Histol Histopathol*. 2009;24(6):693–706.
84. Korkolopoulou P, Patsouris E, Kavantzias N, et al. Prognostic implications of microvessel morphometry in diffuse astrocytic neoplasms. *Neuropathol Appl Neurobiol*. 2002;28(1):57–66.
85. Leenders WP, Kusters B, de Waal RM. Vessel co-option: how tumors obtain blood supply in the absence of sprouting angiogenesis. *Endothelium*. 2002;9(2):83–87.
86. Harrigan MR. Angiogenic factors in the central nervous system. *Neurosurgery*. 2003;53(3):639–660; discussion 660–661.
87. Hillen F, Griffioen AW. Tumour vascularization: sprouting angiogenesis and beyond. *Cancer Metastasis Rev*. 2007;26(3–4):489–502.
88. Kioi M, Vogel H, Schultz G, et al. Inhibition of vasculogenesis, but not angiogenesis, prevents the recurrence of glioblastoma after irradiation in mice. *J Clin Invest*. 2010;120(3):694–705.
89. Burrell K, Hill RP, Zadeh G. High-resolution in-vivo analysis of normal brain response to cranial irradiation. *PLoS One*. 2012;7(6):e38366.
90. Zadeh G, Koushan K, Baoping Q, et al. Role of angiopoietin-2 in regulating growth and vascularity of astrocytomas. *J Oncol*. 2010;2010:Article ID 659231.



91. Coomber BL, Stewart PA, Hayakawa K, et al. Quantitative morphology of human glioblastoma multiforme microvessels: structural basis of blood–brain barrier defect. *J Neurooncol.* 1987; 5(4):299–307.
92. Nathanson D, Mischel PS. Charting the course across the blood–brain barrier. *J Clin Invest.* 2011;121(1):31–33.
93. Godard S, Getz G, Delorenzi M, et al. Classification of human astrocytic gliomas on the basis of gene expression: a correlated group of genes with angiogenic activity emerges as a strong predictor of subtypes. *Cancer Res.* 2003;63(20): 6613–6625.
94. Hendriksen EM, Span PN, Schuurin J, et al. Angiogenesis, hypoxia and VEGF expression during tumour growth in a human xenograft tumour model. *Microvasc Res.* 2009;77(2):96–103.
95. Di Ieva A. Angioarchitectural morphometrics of brain tumors: are there any potential histopathological biomarkers? *Microvasc Res.* 2010;80(3):522–533.
96. Di Ieva A, Grizzi F, Sherif C, et al. Angioarchitectural heterogeneity in human glioblastoma multiforme: a fractal-based histopathological assessment. *Microvasc Res.* 2011;81(2):222–230.
97. Sharma S, Sharma MC, Gupta DK, et al. Angiogenic patterns and their quantitation in high grade astrocytic tumors. *J Neurooncol.* 2006;79(1):19–30.
98. Birner P, Piribauer M, Fischer I, et al. Vascular patterns in glioblastoma influence clinical outcome and associate with variable expression of angiogenic proteins: evidence for distinct angiogenic subtypes. *Brain Pathol.* 2003;13(2):133–143.
99. Chamberlain MC. Bevacizumab plus irinotecan in recurrent glioblastoma. *J Clin Oncol.* 2008;26(6):1012–1013; author reply 1013.
100. Zuniga RM, Torcuator R, Jain R, et al. Efficacy, safety and patterns of response and recurrence in patients with recurrent high-grade gliomas treated with bevacizumab plus irinotecan. *J Neurooncol.* 2009;91(3):329–336.
101. Norden AD, Young GS, Setayesh K, et al. Bevacizumab for recurrent malignant gliomas: efficacy, toxicity, and patterns of recurrence. *Neurology.* 2008;70(10):779–787.
102. Raizer JJ, Grimm S, Chamberlain MC, et al. A phase 2 trial of single-agent bevacizumab given in an every-3-week schedule for patients with recurrent high-grade gliomas. *Cancer.* 2010; 116(22):5297–5305.
103. Gil-Gil MJ, Mesia C, Rey M, et al. Bevacizumab for the treatment of glioblastoma. *Clin Med Insights Oncol.* 2013;7:123–135.
104. Paez-Ribes M, Allen E, Hudock J, et al. Antiangiogenic therapy elicits malignant progression of tumors to increased local invasion and distant metastasis. *Cancer Cell.* 2009;15(3):220–231.
105. de Groot JF, Fuller G, Kumar AJ, et al. Tumor invasion after treatment of glioblastoma with bevacizumab: radiographic and pathologic correlation in humans and mice. *Neuro Oncol.* 2010; 12(3):233–242.
106. Chinot OL, de La Motte Rouge T, Moore N, et al. AVAglio: phase 3 trial of bevacizumab plus temozolomide and radiotherapy in newly diagnosed glioblastoma multiforme. *Adv Ther.* 2011;28(4): 334–340.
107. Stupp R, Mason WP, van den Bent MJ, et al. Radiotherapy plus concomitant and adjuvant temozolomide for glioblastoma. *N Engl J Med.* 2005;352(10):987–996.
108. Yap TA, Workman P. Exploiting the cancer genome: strategies for the discovery and clinical development of targeted molecular therapeutics. *Annu Rev Pharmacol Toxicol.* 2012;52:549–573.