NIH Public Access
Author Manuscript
Semin Arthritis Rheum. Author manuscript; available in PMC 2014 June 18.

Published in final edited form as:
Semin Arthritis Rheum. 2012 June ; 41(6): 859–865. doi:10.1016/j.semarthrit.2011.10.006.

Patients with Retinal Vasculitis Rarely Suffer from Systemic Vasculitis

James T. Rosenbaum, M.D.[1,2], **Jennifer Ku, M.Ph.**[3], **Amro Ali, M.D.**[1], **Dongseok Choi, Ph.D.**[3], and **Eric B. Suhler, M.D., M.Ph.**[1,4]

[1]Department of Ophthalmology, Oregon Health & Science University

[2]Department of Medicine, Oregon Health & Science University

[3]Department of Public Health, Oregon Health & Science University

[4]Portland VA Medical Center

Abstract

Objectives—Systemic vasculitis is often mistakenly assumed to be a common cause of retinal vasculitis. We sought to determine the relationship between retinal vasculitis and systemic vasculitis.

Methods—A selected review was performed on 1390 charts of patients attending the uveitis clinic at the Oregon Health & Science University between 1985 and 2010. Included in the review were all patients with diagnoses commonly associated with retinal vasculitis and all patients who were diagnosed with a systemic vasculitis. Retinal vasculitis was identified by perivascular exudates, intraretinal hemorrhage, or cotton wool spots as seen on clinical examination or by vascular occlusion or leakage as identified by fluorescein angiogram.

Results—207 or 14.9% of patients with uveitis had retinal vasculitis as a component of the intraocular inflammation. Thirty-five patients had retinal vasculitis which was primary, i.e. not associated with a systemic disease, and the dominant manifestation of the uveitis. Fourteen of the patients with retinal vasculitis had Behcet's disease. Only 11 of the 1390 patients with uveitis had a systemic vasculitis. Of these 11, four had retinal vasculitis including one secondary to a CMV retinitis. Thus, systemic vasculitis was directly responsible for 1.4% or 3 of 207 cases of retinal vasculitis. No-vasculitic systemic diseases such as sarcoidosis (n=13), syndromes confined to the eye such as pars planitis (n=36), and intraocular infections (n=29) were far more common causes of retinal vasculitis.

Conclusion—Retinal vasculitis is a relatively common feature of uveitis. Patients with retinal vasculitis, however, rarely suffer from one of the classical systemic vasculitides.

Keywords

Retinal vasculitis; vasculitis; Behcet's; Granulomatosis with polyangiitis; polyarteritis nodosa

Corresponding author: James T. Rosenbaum, Oregon Health & Science University, 3181 S Sam Jackson Park Rd., L467Ad, Portland, Oregon 97239, Phone 503 494 5023, Fax 503 494 6875, rosenbaj@ohsu.edu.

Commercial relationships: NONE

NIH-PA Author Manuscript
NIH-PA Author Manuscript
NIH-PA Author Manuscript

NIH-PA Author Manuscript

NIH-PA Author Manuscript

NIH-PA Author Manuscript

INTRODUCTION

The term, retinal vasculitis, tends to connote very different meanings to rheumatologists and ophthalmologists. In most instances, vasculitis in the lexicon of a rheumatologist means vessel wall destruction. It is usually diagnosed histologically, although in some instances like polyarteritis nodosa, angiographic evidence alone can suffice. Forms of systemic vasculitis include polyarteritis nodosa (PAN), polyangiitis with granulomatosis microscopic PAN, eosinophilic granulomatosis with polyangiitis, giant cell arteritis, and leukocytoclastic vasculitis. Often these diseases require treatment with aggressive immunosuppression, sometimes with an alkylating agent.

Retinal vasculitis, on the other hand, is rarely diagnosed by means of histology. The microvasculature of the retina is unique in its accessibility to observation. Ophthalmologists routinely diagnose retinal vasculitis in an eye with inflammation if a fluorescein angiogram shows that a vessel wall leaks this dye, if an exam suggests an area of local ischemia or hemorrhage, or if exudate is present along a vessel wall. None of these clinical findings require vessel wall destruction. Some patients with retinal vasculitis have a vision threatening disease that might respond to immunosuppression, but many patients with retinal vasculitis have a more benign process that can be treated with just local corticosteroids or even by observation.

Another major difference between retinal vasculitis and systemic vasculitis is the relative importance of infection. Rarely, an infectious process can mimic a systemic vasculitis. For example, herpes zoster can cause a focal inflammation of central nervous system vessels leading to stroke (1). On the other hand, many infections of the retina, including cytomegalovirus, herpes simplex, herpes zoster, tuberculosis, and syphilis, are notorious for causing a retinal vasculitis. Treating any of these with immunosuppression can have disastrous clinical consequences.

In discussions on the differential diagnosis of retinal vasculitis, authoritative sources (2, 3) typically include systemic forms of vasculitis such as polyarteritis nodosa without providing a frame of reference, i.e. among all patients with retinal vasculitis, how many suffer from a systemic vasculitis? The uveitis service at the Casey Eye Institute, Oregon Health & Science University, is unique in that the senior consultant is a rheumatologist. As a uveitis service is generally a practice which is dependent on referrals, this service is especially equipped to deal with systemic inflammatory diseases that affect the uveal tract and likely to receive such referrals. Because of the confusion that almost invariably arises between ophthalmologists and rheumatologists a patient is diagnosed with vasculitis, we have reviewed diagnoses of retinal vasculitis at this clinic over nearly a 25 year period. Our goal was to clarify the relationship between systemic vasculitis and retinal vasculitis.

METHODS

A retrospective chart review was performed on 1,390 charts of patients attending the uveitis clinic at the Oregon Health & Science University, Casey Eye Institute, between 1985 and 2010. An additional 185 charts were missing or unavailable. All locatable charts from

NIH-PA Author Manuscript

NIH-PA Author Manuscript

NIH-PA Author Manuscript

patients with diagnoses commonly associated with retinal vasculitis and all patients who were diagnosed with a systemic vasculitis were included in the review. Charts for diagnoses represented by ten or fewer patients were only reviewed when the entity was known to be strongly associated with retinal vasculitis such as acquired immune deficiency syndrome (AIDS) and tuberculosis. The etiology of the uveitis was assessed using an algorithm that we published in 1990 (4) with minor modification over the years such as the increased use of chest computerized tomographic scanning (currently with a special hilar protocol to reduce radiation) (5) to diagnose subjects with sarcoidosis.

Retinal vasculitis cases were identified by documentation of active inflammation usually in the form of cells in the anterior chamber of the eye and/or the vitreous humor along with perivascular exudates, intraretinal hemorrhage, or cotton wool spots as seen on clinical examination (see Figures 1 and 2) or by vascular occlusion or leakage as identified by fluorescein angiogram at any point of time while attending the clinic. These vascular changes are not specific for vasculitis. For example, cotton wool spots are common in the setting of diabetes mellitus, HIV infection, or poorly controlled hypertension. Hence, we required that the vascular changes occurred in association with other evidence for intraocular inflammation. No minimum follow-up time was required and if there were multiple visits, all available records were reviewed.

Of the 1,390 charts reviewed, 153 had idiopathic uveitis with unclassifiable disease association. “Idiopathic” uveitis is a common diagnosis in any uveitis clinic and is used to designate a disease which is presumed to be non-infectious and which does not fit within a recognizable diagnostic entity. The 153 idiopathic uveitis patients were selected arbitrarily as a representative sample from a total of 677 patients with idiopathic disease. Patients with idiopathic uveitis and associated retinal vasculitis differed from patients classified with primary retinal vasculitis because the examining physician considered the vasculitis to be the major clinical manifestation for the latter group.

We elected not to review all charts for all HLA – B27 associated uveitis and reactive arthritis in our clinic’s total uveitis population as these entities are not typically associated with retinal vasculitis and the uveitis is identical to that seen with ankylosing spondylitis, a diagnosis that we reviewed in 133 patients. Considering the missing charts, the excluded diagnoses, and the subset of patients with idiopathic uveitis evaluated, the review included about 63% of the total uveitis charts in the database. This study was reviewed and approved by the Institutional Review Board at the Oregon Health & Science University.

RESULTS

We reviewed the charts of 1390 patients who were seen at the uveitis clinic of the Oregon Health & Science University, Casey Eye Institute between 1985 when the clinic began and 2010. We elected to review charts selectively, but included all available charts from patients who had a diagnosis which was known to have an association with retinal vasculitis, whether commonly or uncommonly. We also tried to include all the relatively common diagnoses such as ankylosing spondylitis or juvenile idiopathic arthritis, even if the diagnosis is not thought to have an association with retinal vasculitis. The results of this

NIH-PA Author Manuscript

NIH-PA Author Manuscript

NIH-PA Author Manuscript

chart review are shown in Table 1. We identified 207 patients with evidence for retinal vasculitis. This included 29 patients with identifiable intraocular infections. These diagnoses are listed in Table 2. The series also included 11 patients with a diagnosed systemic vasculitis (Table 3). Four of these patients had associated retinal vasculitis, but in one instance the vasculitis was secondary to cytomegaloviral infection (see Figure 2). Thus retinal vasculitis secondary to systemic vasculitis accounted for 3 of 207 cases of retinal vasculitis or 1.4 %. Our series also included one patient with antiphospholipid antibody syndrome and retinal vascular occlusions and intra-retinal hemorrhage. We regard this entity as more of an occlusive vasculopathy rather than a true vasculitis, but even if we reclassified this subject as a systemic vasculitis, the percentage changes only slightly. Similarly, we did not include livedoid vasculopathy as a vasculitis since it is generally regarded as a thrombotic, non-inflammatory condition. A number of diseases are not usually classified as systemic vasculitides, but they can be associated with vasculitis as a component. These illnesses included Behcet's disease, Cogan's syndrome, systemic lupus erythematosus, and rheumatoid arthritis. They are listed separately in Table 4. Assuming that our findings on a subset of patients with idiopathic uveitis can be extrapolated, idiopathic uveitis would have been the entity that accounted for the greatest number of patients with retinal vasculitis in this series. The second most common diagnosis was pars planitis. This is an entity characterized by cellular exudates overlying the pars plana, an anatomic region posterior to the ciliary body and just anterior to furthest extension of the retina. Pars planitis is associated with multiple sclerosis in approximately 15% of cases (6).

We believe that this is the first survey to determine the frequency of retinal vasculitis in association with a variety of specific subsets of uveitis such as birdshot choroidopathy or Vogt-Koyanagi-Harada syndrome. With the exception of a few entities which were too rare to draw firm conclusions, Behcet's disease was the systemic disease most often associated with retinal vasculitis, although we could not detect retinal vasculitis in 70% of the patients with Behcet's and uveitis in this series.

Several systemic diseases that are not generally considered to be systemic vasculitides, such as sarcoidosis and multiple sclerosis, were commonly associated with retinal vasculitis in this series. Retinal vasculitis was occasionally detected, but rarely in some entities that are relatively frequent within the uveitis clinic, such as ankylosing spondylitis, herpes simplex keratouveitis, or tubulointerstitial nephritis. Our series included one patient with rheumatoid arthritis and retinal vasculitis. As we have identified over 200 patients with retinal vasculitis and only one with RA, we hesitate to conclude that RA is causally related to retinal vasculitis.

DISCUSSION

We believe that this is the largest study to date on patients with retinal vasculitis, the first case series on this diagnosis from a clinic in North America, and the first series to analyze a variety of subsets of uveitis for the relationship of each to retinal vasculitis. In 1989, Graham et. al. reported on 150 patients in a London clinic with retinal vasculitis (7). Her series excluded patients with infections, but she too noted a subset with primary vasculitis. Eighty-three patients in her series had an associated "systemic inflammatory disease", usually

NIH-PA Author Manuscript

NIH-PA Author Manuscript

NIH-PA Author Manuscript

Behcet's disease or sarcoidosis. In the London series, 6 patients or 4% had a systemic vasculitis, three with PAN and 3 with Granulomatosis with polyangiitis's. Although one can find anecdotal reports of either polyarteritis nodosa or granulomatosis with polyangiitis affecting the retinal vessels (8–11), the largest case series of which we are aware illustrating these associations includes only four patients. Gallagher et. al. described 3 patients who had ANCA associated vasculitis and retinal vasculitis (12). Conversely, in a series of 140 patients with granulomatosis with polyangiitisevaluated at the Mayo Clinic over a 16 year period, 40 patients had ocular involvement, usually orbital disease or scleritis/episcleritis. Only 4 or 2.9% had retinal vasculitis, one of whom may have had retinal hemorrhage and cotton wool spots on the basis of hypertensive renal disease rather than secondary to vasculitis. (13) Our experience is concordant with the Mayo report in that we evaluate patients with granulomatosis with polyangiitis and either scleritis or orbital inflammation more commonly than we encounter this diagnosis as a cause of uveitis. Similarly an NIH series that described a 15 year experience with granulomatosis with polyangiitis included only one patient with uveitis and retinal vasculitis was not mentioned specifically in the synopsis of his ophthalmic findings (14). A series from Massachusetts Eye and Ear Infirmary on ocular findings in polyarteritis included two patients with retinal vasculitis (8). These publications provide additional evidence for the uncommon nature of the association between systemic vasculitis and retinal vasculitis.

While Table 3 indicates that giant cell arteritis, polyarteritis nodosa, granulomatosis with polyangiitis, and eosinophilic granulomatosis with polyangiitis are rare causes of uveitis, when the latter two diseases do cause uveitis, retinal vasculitis is relatively frequent (two of five patients as calculated by excluding the patient with vasculitis secondary to CMV infection).

One form of vasculitis which frequently does cause uveitis is Kawasaki's syndrome in children (15, 16). The typical eye findings include both a conjunctivitis and an anterior uveitis. Retinal involvement is very rare. Although children are seen in the Casey Eye uveitis clinic, we did not receive referrals to evaluate patients with Kawasaki's disease during the period of this study.

In this study we reviewed the charts of 1390 patients with uveitis and found evidence for retinal vasculitis in 207. As might be expected, entities like ankylosing spondylitis and juvenile idiopathic arthritis are rarely associated with retinal vasculitis, while Behcet's disease is commonly associated with retinal vasculitis. Other diseases like sarcoidosis and multiple sclerosis which are not considered to be systemic forms of vasculitis are nonetheless clearly associated with retinal vasculitis. Of major clinical importance, 14.9% of the patients with retinal vasculitis had an identifiable infectious cause. Perhaps surprisingly to rheumatologists, the systemic vasculitides including PAN, microscopic PAN, polyangiitis with granulomatosis, Eosinophilic granulomatosis with polyangiitis, and giant cell arteritis combined accounted for only 1.4% of the patients with retinal vasculitis. Even systemic lupus erythematosus, which can be associated with systemic vasculitis, accounted for only 1% of the patients with retinal vasculitis.

NIH-PA Author Manuscript

NIH-PA Author Manuscript

NIH-PA Author Manuscript

In the introduction we called attention to some of the differences in the way in which retinal vasculitis is diagnosed compared to systemic vasculitis. There is also a theoretical reason why systemic vasculitis should rarely co-exist with systemic vasculitis. Vascular beds in different portions of the body differ. For example, MaDCAM is an adhesion molecule primarily restricted to gut vasculature (17). Ruoslahti and colleagues have elegantly shown that short peptide sequences will bind preferentially to specific vasculature beds (18). Rheumatologists are aware that leukocytoclastic vasculitis is confined to small vessels, while polyarteritis affects medium-sized vessels, and giant cell arteritis can affect large vessels. The retina is appropriately considered to be an extension of the brain. Both in terms of size and function, retinal vessels are distinct. Since specific vasculitides demonstrate a preference for specific vascular beds, it might not be surprising that systemic vasculitis rarely affects retinal vessels. Likewise, a systemic vasculitis can also cause a central nervous system vasculitis, but this association is uncommon.

Our study has several limitations. First, as a retrospective chart review, we encountered charts that were lost or which had inadequate notes to determine all the information we sought. Second, the diagnosis of retinal vasculitis can be subjective. For example, observers might disagree as to whether vascular sheathing is present. Third, a fluorescein angiogram is arguably the most sensitive test to detect retinal vasculitis, and this was not obtained on every patient or at every visit. Fourth, we reviewed nearly 1400 charts, but we elected to review only a subset of charts from patients with idiopathic uveitis, who by definition did not have a causally related systemic illness, and we elected not to review all charts from patients who had diagnoses that are relatively uncommon in our clinic and/or which are not typically associated with retinal vasculitis. Finally, any series like this will be affected by geographic and referral biases. We have, for example, an unusually low percentage of patients with HIV in our series, in part because of the prevalence of HIV infection in Portland, Oregon, and partially due to referral patterns in our community. The frequency of Behcet's disease, an important cause of retinal vasculitis, is obviously affected by the location of the clinic. Systemic lupus erythematosus can be associated with a severe occlusive retinopathy (19) which we did not observe.

Retinal vasculitis can be divided into subsets based on the involvement of arteries, veins, or both. We did not analyze those subsets for this report. In some cases, the vascular involvement could be sufficiently characteristic that a specific diagnosis such as sarcoidosis or multiple sclerosis is suggested. Primary retinal vasculitis also has discrete subsets which include Eales' disease (20) (a form of peripheral periphlebitis which is common in India in patients who have skin test reactivity to tuberculin), frosted branch angiitis (21), IRVAN (idiopathic retinal vasculitis with aneurysms and neuroretinitis) (22), Susac syndrome (23) (an occlusive retinal vasculopathy with eighth nerve disease and other central nervous system findings), and cerebral retinal vasculopathy associated with mutations in TREX-1 (24). Our series includes one patient diagnosed with Eales' disease and one with Susac syndrome. Both are included within the primary retinal vasculitis grouping.

Vasculitis can also affect scleral or choroidal vessels. These diagnoses are not included in this report unless uveitis was diagnosed in association with the scleritis or the choroidal vasculopathy.

NIH-PA Author Manuscript

NIH-PA Author Manuscript

NIH-PA Author Manuscript

The uveitis service is occasionally asked formally or informally by physicians and sometimes by attorneys to offer advice on patients who have retinal vasculitis and a form of systemic vasculitis such as polyangiitis with granulomatosis or giant cell arteritis (a relatively common diagnosis which accounted for none of our patients with retinal vasculitis). Although most of these patients are not included in this series because they were not formally seen in our clinic, follow-up information was often available. In the vast majority of these referrals, we have concluded that the retinal vasculitis was due to an infection secondary to the immunosuppression rather than a manifestation of the systemic vasculitis. Obviously, such a conclusion has major therapeutic implications.

In summary, this case series indicates that patients with retinal vasculitis rarely suffer from systemic vasculitis. In fact, patients with retinal vasculitis are much more likely to suffer from an ocular infection, non-vasculitic systemic inflammatory diseases such as sarcoidosis, or an inflammatory syndrome restricted to the eye, such as birdshot choroidopathy, rather than systemic vasculitis. The literature cited above supports the converse of these observations: patients with systemic vasculitis rarely develop retinal vasculitis. In our experience, the relationship between retinal vasculitis and systemic vasculitis is commonly misunderstood by both ophthalmologists and rheumatologists and the consequence of this misunderstanding can lead to misguided therapy and blindness.

Acknowledgments

This work was supported by Research to Prevent Blindness, the William C. Kuzell Foundation, the Stan and Madelle Rosenfeld Family Trust, the William and Mary Bauman Foundation

References

1. Bourdette DN, Rosenberg NL, Yatsu FM. Herpes zoster ophthalmicus and delayed ipsilateral cerebral infarction. Neurology. 1983; 33(11):1428–32. [PubMed: 6605495]
2. Kaithiresan S, Kelsey PB, Steere AC, Foster CS, Curvelo MS, Stone JR. Case records of the Massachusetts General Hospital. Case 14-2005. A 38 year-old man with fever and blurred vision. New England Journal of Medicine. 2005; 352:2003–12. [PubMed: 15888702]
3. Tolentino, M.; Dana, MR. UpToDate. 2011. Retinal vasculitis associated with systemic disorders and infections.
4. Rosenbaum JT. An algorithm for the systemic evaluation of patients with uveitis: guidelines for the consultant. Seminars in Arthritis and Rheumatism. 1990; 19:248–257. [PubMed: 2181671]
5. Kaiser PK, Lowder CY, Sullivan P, et al. Chest computerized tomography in the evaluation of uveitis in elderly women. Am J Ophthalmol. 2002; 133(4):499–505. [PubMed: 11931783]
6. Malinowski SM, Pulido JS, Folk JC. Long-term visual outcome and complications associated with pars planitis. Ophthalmology. 1993; 100:818–824. [PubMed: 8510893]
7. Graham EM, Stanford MR, Sanders MD, Kasp E, Dumonde DC. A point prevalence study of 150 patients with idiopathic retinal vasculitis: 1. Diagnostic value of ophthalmological features. Br J Ophthalmol. 1989; 73(9):714–21. [PubMed: 2804027]
8. Akova YA, Jabbur NS, Foster CS. Ocular presentation of polyarteritis nodosa. Clinical course and management with steroid and cytotoxic therapy. Ophthalmology. 1993; 100(12):1775–81. [PubMed: 7903120]
9. Morgan CM, Foster CS, D'Amico DJ, Gragoudas ES. Retinal vasculitis in polyarteritis nodosa. Retina. 1986; 6(4):205–9. [PubMed: 2883710]
10. Gallagher MJ, Ooi KG, Thomas M, Gavin M. ANCA associated pauci-immune retinal vasculitis. Br J Ophthalmol. 2005; 89(5):608–11. [PubMed: 15834094]

NIH-PA Author Manuscript

NIH-PA Author Manuscript

NIH-PA Author Manuscript

11. Curi AL, Freeman G, Pavesio C. Aggressive retinal vasculitis in polyarteritis nodosa. Eye (Lond). 2001; 15(Pt 2):229–31. [PubMed: 11339598]
12. Haynes BF, Fishman ML, Fauci AS, Wolff SM. The ocular manifestations of Wegener's granulomatosis. Fifteen years experience and review of the literature. Am J Med. 1977; 63(1):131–41. [PubMed: 327802]
13. Bullen CL, Liesegang TJ, McDonald TJ, DeRemee RA. Ocular complications of Wegener's granulomatosis. Ophthalmology. 1983; 90(3):279–90. [PubMed: 6602963]
14. Emad Y, Basaffar S, Ragab Y, Zeinhom F, Gheita T. A case of polyarteritis nodosa complicated by left central retinal artery occlusion, ischemic optic neuropathy, and retinal vasculitis. Clin Rheumatol. 2007; 26(5):814–6. [PubMed: 16575492]
15. Fink CW. Vasculitis. Pediatric Clinics of North America. 1986; 33:1203–1219. [PubMed: 2876408]
16. Ohno S, Miyajima T, Higuchi M, et al. Ocular manifestations of Kawasaki's disease (mucocutaneous lymph node syndrome). American Journal of Ophthalmology. 1982; 93:713–717. [PubMed: 7201245]
17. Shigematsu T, Specian RD, Wolf RE, Grisham MB, Granger DN. MAdCAM mediates lymphocyte-endothelial cell adhesion in a murine model of chronic colitis. American Journal of Physiology-Gastrointestinal and Liver Physiology. 2001; 281(5):G1309–G1315. [PubMed: 11668040]
18. Ruoslahti ERD. An address system in the vasculature of normal tissues and tumors. Annual Reviews of Immunology. 2000; 18:813–827.
19. Jabs DA, Fine SL, Hochberg MC, Newman SA, Heiner GG, Stevens MB. Severe retinal vaso-occlusive disease in systemic lupus erythematous. Arch Ophthalmol. 1986; 104(4):558–63. [PubMed: 3954661]
20. Elliot AJ. 30-year observation of patients with Eale's disease. Am J Ophthalmol. 1975; 80(3 Pt 1): 404–8. [PubMed: 1163588]
21. Watanabe Y, Takeda N, Adachi-Usami E. A case of frosted branch angiitis. Br J Ophthalmol. 1987; 71(7):553–8. [PubMed: 3651369]
22. Chang TS, Aylward GW, Davis JL, et al. Idiopathic retinal vasculitis, aneurysms, and neuro-retinitis. Retinal Vasculitis Study. Ophthalmology. 1995; 102(7):1089–97. [PubMed: 9121757]
23. Susac JO, Egan RA, Rennebohm RM, Lubow M. Susac's syndrome: 1975–2005 microangiopathy/autoimmune endotheliopathy. J Neurol Sci. 2007; 257(1–2):270–2. [PubMed: 17331544]
24. Mateen FJ, Krecke K, Younge BR, et al. Evolution of a tumor-like lesion in cerebroretinal vasculopathy and TREX1 mutation. Neurology. 75(13):1211–3. [PubMed: 20876473]

NIH-PA Author Manuscript

NIH-PA Author Manuscript

NIH-PA Author Manuscript

Figure 1.

Retinal photograph from a patient with primary retinal vasculitis. Photograph illustrates cotton wool spot, vascular sheathing, and intraretinal hemorrhage.

NIH-PA Author Manuscript

NIH-PA Author Manuscript

NIH-PA Author Manuscript

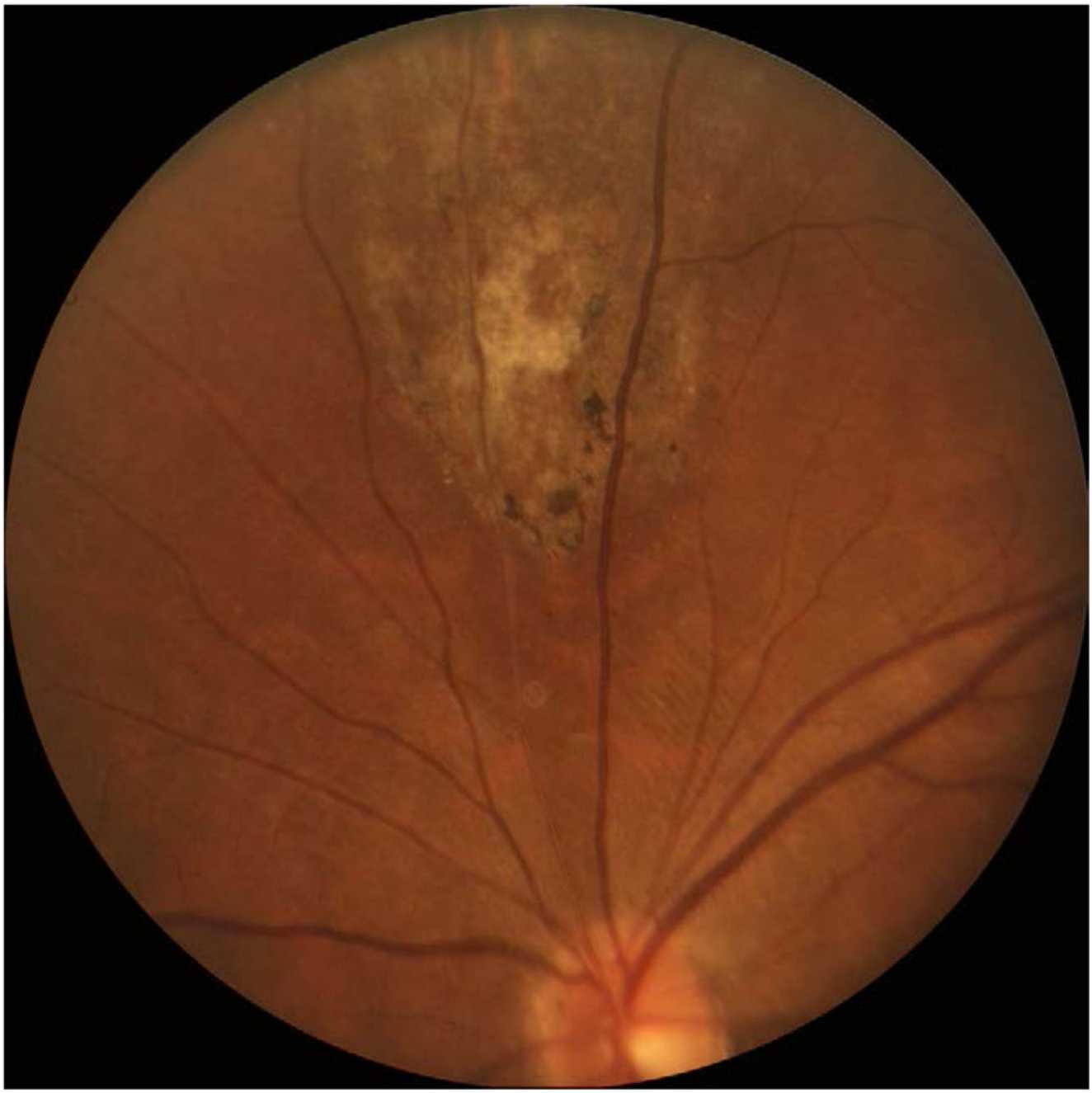

Figure 2.

Retinal photograph from a patient with eosinophilic granulomatosis with polyangiitis. An area of white retinitis is surrounded by a pigmented scar. An occluded vessel affected by vasculitis runs through the center of the lesion. The retinitis developed while the patient was receiving immunosuppression. It was attributed to CMV infection and it responded to intravitreally injected antiviral therapy and a reduction in the immunosuppression.

NIH-PA Author Manuscript

NIH-PA Author Manuscript

NIH-PA Author Manuscript

Table 1

Specific subsets of uveitis and their association with retinal vasculitis

Uveitis Diagnosis	Number reviewed	Number with retinal vasculitis	Percentage
Acute retinal necrosis	23	7	30.4%
AIDS/CMV	10	5	50.0%
Ankylosing spondylitis	133	1	0.8%
Antiphospholipid antibody syndrome	1	1	100.0%
Behcet's disease	46	14	30.4%
Birdshot choroidopathy	34	9	26.5%
Blau syndrome	2	0	0.0%
Central nervous system vasculitis	4	1	33.3%
Eosinophilic granulomatosis with polyangiitis	2	2	100.0%
Cogan's syndrome	2	0	0.0%
Crohn's disease	11	1	9.1%
Endophthalmitis	3	1	33.3%
Glaumatocyclitic crisis	2	0	0.0%
Herpes simplex	46	3	6.5%
Herpes zoster	32	1	3.1%
Histoplasmosis	3	0	0.0%
HLA - B27 associated	4	0	0.0%
Interstitial nephritis	39	1	2.6%
Ischemia	5	1	20.0%
Juvenile idiopathic arthritis	98	5	5.1%
Lymphoma	17	3	17.6%
Multifocal choroiditis	5	2	40.0%
Multiple sclerosis	25	4	16.0%
Neuroretinitis	3	0	0.0%
Pars planitis	194	36	18.6%
Psoriatic arthritis	25	4	16.0%
Sarcoid	150	13	8.7%
Scleritis	25	2	8.0%
Serpiginous chorioretinopathy	4	1	25.0%
Sympathetic ophthalmia	14	1	7.1%
Syphilis	8	3	37.5%
Systemic lupus erythematosus	4	2	50.0%
Toxoplasmosis	49	7	14.3%
Tuberculosis	5	2	40.0%
Ulcerative colitis	11	1	9.1%
Vogt-Koyanagi Harada	58	7	12.1%
Leukocytoclastic vasculitis	1	0	0.0%

NIH-PA Author Manuscript

NIH-PA Author Manuscript

NIH-PA Author Manuscript

Uveitis Diagnosis	Number reviewed	Number with retinal vasculitis	Percentage
Pigmentary dispersion	3	0	0.0%
Post - operative	6	0	0.0%
Post-trauma	4	0	0.0%
Polychondritis	3	0	0.0%
Pulmonary vasculitis	1	0	0.0%
Punctate inner choroidopathy	6	0	0.0%
Reactive arthritis	6	0	0.0%
Rheumatoid Arthritis	1	1	100.0%
Granulomatosis with polyangiitis	3	1	33.3%
Other systemic illness	41	3	7.7%
Other masquerades	7	2	33.3%
Other infections	7	0	0.0%
Other uveitides	16	6	30.0%
Idiopathic (unclassifiable)	153	18	11.8%
Primary retinal vasculitis	35	35	100.0%
Total	**1390**	**207**	**14.9%**

Examples of “other systemic illness” included autoimmune hepatitis, erythema nodosum, granulomatous arthritis, neutropenia, myelopathy, peripheral neuropathy, optic neuritis, Behcet’s suspect, rheumatoid arthritis suspect, sarcoid suspect, and livedoid vasculopathy. The patient with livedoid vasculopathy did not have retinal vasculitis.

Examples of “other masquerades” included giant retinal tear, uveitis glaucoma hyphema syndrome, and orbital xanthogranuloma. Lymphoma, ischemia, and pigmentary dispersion syndrome are additional examples of masquerade syndromes that mimic inflammation within the eye.

Examples of “other infections” included viral keratouveitis, metastatic fungal infection, and bacterial meningitis.

Examples of “other uveitides” included autoimmune retinopathy, non-specific orbital inflammatory disease, and “white dot syndromes” that were not listed separately such as multiple evanescent white dot syndrome.

NIH-PA Author Manuscript

NIH-PA Author Manuscript

NIH-PA Author Manuscript

Table 2

The relationship between retinal vasculitis and intra-ocular infection

Uveitis Diagnosis	Number reviewed	Number with retinal vasculitis	Percentage
Acute retinal necrosis	23	7	30.4%
AIDS/CMV	10	5	50.0%
Endophthalmitis	3	1	33.3%
Herpes simplex	46	3	6.5%
Herpes zoster	32	1	3.1%
Syphilis	8	3	37.5%
Toxoplasmosis	49	7	14.3%
Tuberculosis	5	2	40.0%
Total	**176**	**29**	**16.5%**

NIH-PA Author Manuscript

NIH-PA Author Manuscript

NIH-PA Author Manuscript

Table 3

The relationship between retinal vasculitis and systemic vasculitis

Uveitis Diagnosis	Number reviewed	Number with retinal vasculitis	Percentage
Pulmonary vasculitis	1	0	0.0%
Leukocytoclastic vasculitis	1	0	0.0%
Granulomatosis with polyangiitis	3	1	33.3%
Central nervous system vasculitis	4	1	25.0%
–Eosinophilic granulomatoisis with polyangiitis	2	2	100.0%
Total	**11**	**4***	**36.4%***

*includes one patient with eosinophilic granulomatosis with polyangiitis and CMV retinitis. This patient is not represented in Table 2.

NIH-PA Author Manuscript

NIH-PA Author Manuscript

NIH-PA Author Manuscript

Table 4

Retinal vasculitis identified in patients with systemic diseases which may have a systemic vasculitis component

Uveitis Diagnosis	Number reviewed	Number with retinal vasculitis	Percentage
Behcet's disease	46	14	30.4%
Cogan's syndrome	2	0	0.0%
Systemic lupus erythematosus	4	2	50.0%
Rheumatoid arthritis	1	1	100.0%
Total	53	17	32.1%