Nucl Med Mol Imaging (2013) 47:299–300
DOI 10.1007/s13139-013-0226-4

INTERESTING IMAGE

^{18}F-FDG PET-CT-Negative Recurrent High-Grade Anaplastic Astrocytoma Detected by ^{18}F-FDOPA PET-CT

Sellam Karunanithi · Harmandeep Singh · Punit Sharma · Deepak Kumar Gupta · Chandrasekhar Bal

Received: 27 May 2013 / Revised: 3 August 2013 / Accepted: 7 August 2013 / Published online: 27 August 2013
© Korean Society of Nuclear Medicine 2013

A 37-year-old woman with grade 3 anaplastic astrocytoma (AA) of the left frontal lobe, underwent surgical excision, chemotherapy and external beam radiation therapy in 2004. After being in remission for 5 years, recurrence was suspected clinically when she presented with seizures. The result of contrast-enhanced magnetic resonance imaging (MRI) was equivocal for recurrence and radiation necrosis (*not available*). The patient was then referred for ^{18}F-fluorodeoxyglucose (^{18}F-FDG) positron emission tomography-computed tomography (PET-CT), as the initial primary tumour was high grade in nature. ^{18}F-FDG PET-CT was negative for recurrence and demonstrated only post-operative changes in the left frontal region (Fig. 1a, b, *arrow*). Due to strong clinical suspicion, 3,4-dihydroxy-6-^{18}F-fluoro-L-phenylalanine (^{18}F-FDOPA) PET-CT was done, 5 days after ^{18}F-FDG PET-CT. The study revealed an ^{18}F-FDOPA-avid mass lesion in the left frontal region (Fig. 1c, d, *arrow*), thereby confirming the presence of recurrent disease. The patient underwent surgical resection of the mass, and it was confirmed by histopathology as grade 3 AA. However, after a short asymptomatic period of 4 months the patient became symptomatic again. Follow-up MRI after 6 months of surgery revealed presence of ipsilateral and contralateral multifocal contrast enhancing recurrent mass lesions (Fig. 1e, f, *arrow*), suggesting the progression of disease. The patient was started on temozolamide but she died after 8 months' follow-up.

Though MRI is routinely used in assessment of brain tumours, its ability to differentiate between treatment-induced changes and residual or recurrent tumour is limited [1]. ^{18}F-FDG PET was the first tracer used for assessment of brain tumours [2]; however, it has a low tumour-to-background ratio in brain, limiting its utility. ^{18}F-FDG uptake correlates with tumour grade, with high-grade gliomas (grades III and IV) showing higher uptake than low-grade gliomas [3, 4]. Therefore, in spite of its limitations, ^{18}F-FDG PET-CT is used for imaging of high-grade glioma. Amino acid PET radiotracers including ^{18}F-FDOPA display superior contrast to ^{18}F-FDG because of low uptake of amino acids in normal brain tissue [5]. They have particularly special value in the detection of low-grade gliomas [6]. However, ^{18}F-FDOPA tumour uptake cannot provide reasonable predictions about tumour grade and proliferation in recurrent tumours that have undergone treatments [7]. Also, their difficult synthesis or need for an on-site cyclotron limits their widespread use. The present case shows the utility of ^{18}F-FDOPA PET-CT in detection of a recurrent high-grade AA that was missed by ^{18}F-FDG PET-CT. It highlights that ^{18}F-FDG PET-CT can be falsely negative, even in high-grade recurrent gliomas and, therefore, in cases with strong clinical suspicion ^{18}F-FDOPA PET-CT can be an alternative imaging modality to rule out recurrence even when ^{18}F-FDG PET-CT is negative.

S. Karunanithi · H. Singh · P. Sharma · C. Bal (✉)
Department of Nuclear Medicine, All India Institute of Medical Sciences, Ansari Nagar, New Delhi 110029, India
e-mail: csbal@hotmail.com

D. K. Gupta
Department of Neurosurgery, All India Institute of Medical Sciences, New Delhi, India

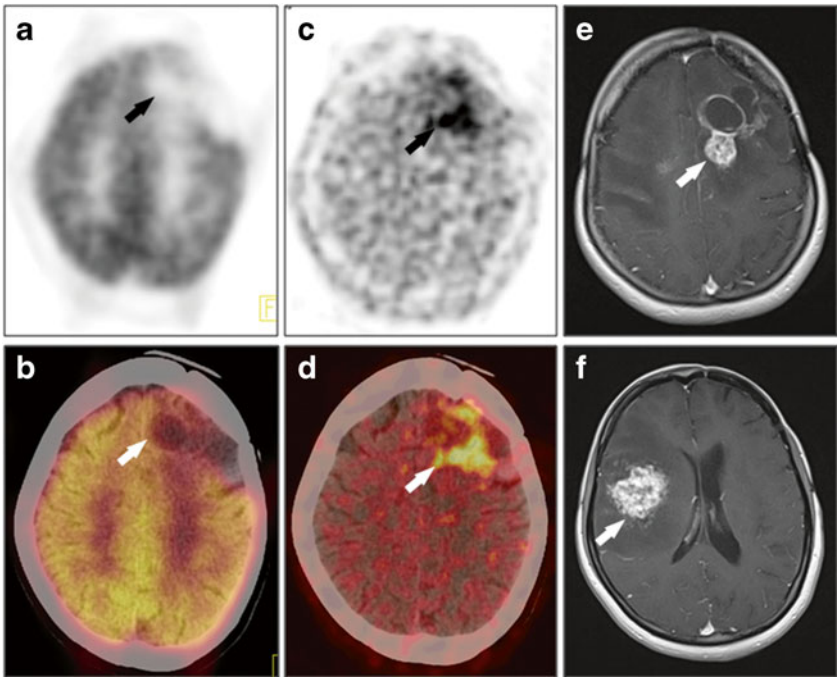

Fig. 1 **a, b** ^{18}F-FDG PET-CT. **c, d** ^{18}F-FDOPA. **e, f** Six-month follow-up MRI

Conflicts of interest None.

References

1. Derlon JM, Chapon F, Noel MH, et al. Non-invasive grading of oligodendrogliomas: correlation between in vivo metabolic pattern and histopathology. Eur J Nucl Med. 2000;27:778–87.
2. Patronas NJ, Di Chiro G, Brooks RA, et al. Work in progress: [^{18}F] fluorodeoxyglucose and positron emission tomography in the evaluation of radiation necrosis of the brain. Radiology. 1982; 144:885–9.
3. Alavi JB, Alavi A, Chawluk J, et al. Positron emission tomography in patients with glioma: a predictor of prognosis. Cancer. 1988;62:1074–8.
4. Delbeke D, Meyerowitz C, Lapidus RL, et al. Optimal cutoff levels of ^{18}F-fluorodeoxyglucose uptake in the differentiation of low -grade from high-grade brain tumors with PET. Radiology. 1995;195:47–52.
5. Jager PL, Vaalburg W, Pruim J, et al. Radiolabeled aminoacids : basic aspects and clinical applications in oncology. J Nucl Med. 2001;42: 432–45.
6. Chen W, Silverman DH, Delaloye S, et al. ^{18}F-FDOPA PET imaging of brain tumors: comparison study with ^{18}F-FDG PET and evaluation of diagnostic accuracy. J Nucl Med. 2006;47:904–11.
7. Fueger BJ, Czernin J, Cloughesy T, et al. Correlation of 6-18F-fluoro-L-dopa PET uptake with proliferation and tumor grade in newly diagnosed and recurrent gliomas. J Nucl Med. 2010;51:1532–8.