International Orthopaedics (SICOT) (2014) 38:905–909
DOI 10.1007/s00264-013-2183-z

ORTHOPAEDIC HERITAGE

Orthopaedics in the dawn of civilisation, practices in ancient Egypt

Galal Zaki Said

Received: 1 November 2013 / Accepted: 2 November 2013 / Published online: 17 November 2013
© Springer-Verlag Berlin Heidelberg 2013

Egypt had professional doctors as early as the old kingdom 5,000 years ago. There were also specialists in different branches of medicine. Homer (ca. 800 BC) remarked in the Odyssey: "In Egypt, the men are more skilled in medicine than any of human kind". Hippocrates, Herophilos, Erasistratus and later Galen studied at the temple of Amenhotep, and acknowledged the contribution of ancient Egyptian medicine to Greek medicine [1].

Mummified bodies, skeletal remains, wall paintings and papyri have shown some of the ancient orthopaedic practices. Fractures were splinted by pieces of bark or wood padded with linen [2]. The bandage was first dipped in powdered beans or barley mixed with honey and resins that stiffened it after drying [3]. There are many examples of excellently handled fractures of the long bones that had united in perfect alignment. This is particularly impressive in a case of oblique fracture of the femur in an adult, which united without any over-riding (Fig. 1). In a painting from Ipuy's tomb, Ramses II's sculptor, a person setting the shoulder of a prostrate workman is depicted, which is similar to the method devised by Kocher for reducing dislocated shoulders 3,000 years later (Fig. 2) [4].

Probably the oldest medical document ever written is the Edwin Smith surgical papyrus (Fig. 3). It was translated from Hieratic (cursive style of writing hieroglyphic) to English by Prof. J. Breasted [5]. The papyrus is a copy of an original, which dates to the 30th century BC, the time of pyramid building. In this papyrus, 48 cases, mostly injuries, were described free from any magic. Descriptions of the patients and their treatment were detailed systematically starting with wounds of the scalp, fracture of the skull exposing the brain, fracture of the neck with paralysis of the arms and legs, fracture of the collarbone and moving down to the extremities. The author, commonly believed to be Imhotep, instructs the treating physician first to listen to the patient's complaint and then to examine him using his eyes and hands. After reaching a diagnosis he makes a declaration: an ailment which I would treat, an ailment which I would contend and an ailment which I would not treat. This formal and structured approach is the basis of our current approach to the patient. Three examples of these cases are cited here:

> Case 25: Treatment of a dislocated jaw: ".. should put your thumbs, upon the ends of the two rami of the mandible in the inside of his mouth, and your two claws (the other fingers) under his chin, and you should cause them to fall back so that they rest in their place".
> Case 31: Traumatic quadriplegia: "If you examine a man having dislocation in a vertebra of his neck, should you find him unconscious of his two arms and his two legs, while his phallus is erected …. and urine drops from his member without his knowing it….." "….it is a dislocation of a vertebra of neck extending to his back-bone …, an ailment which I would not treat"
> Case 35: Fracture of the clavicle: "If you treat a man for a break in his collarbone and you find his collarbone shortened and out of alignment with respect to its companion, an ailment I will treat. Place him prostrate on his back with something folded between his shoulder blades; you should spread out with his two shoulders to stretch apart his collar bone until break falls in its place".

The ancient Egyptian surgeon has evidently practised autopsy. He describes a case of closed fracture dislocation of the cervical spine as a vertebra "sinking into the interior of the neck as the foot settles in cultivated soil", where one vertebra is said to "penetrate into the other". He could distinguish between fractures and luxations by

G. Z. Said (✉)
Department of Orthopedic and Trauma Surgery, Assiut University, P.O. Box 100, Assiut, Egypt
e-mail: gzsaid@yahoo.com

Fig. 1 Fractures of long bones which have united in perfect alignment



Fig. 2 Painting from Ipuy's tomb in Thebes. A person is setting the shoulder of a prostrate workman

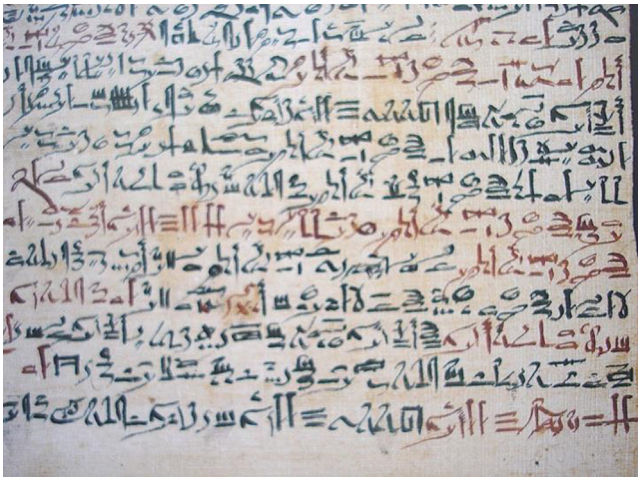

Fig. 3 Edwin Smith surgical papyrus; Case 31: Traumatic quadriplegia

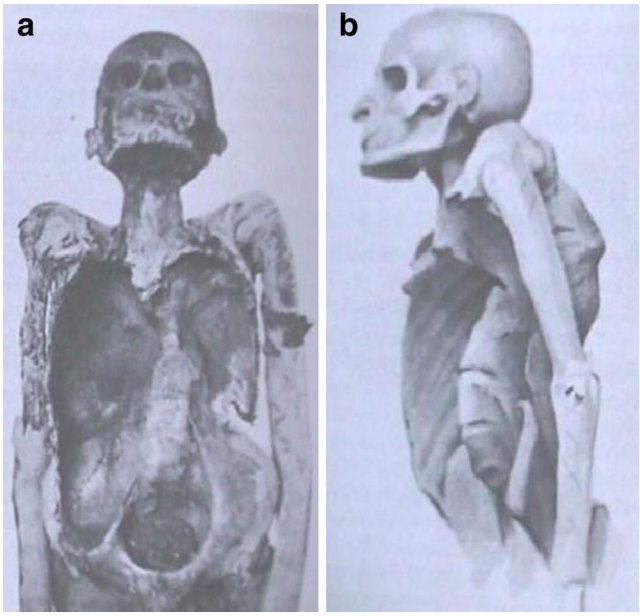

Fig. 4 Nesparehan, a priest of Amun in the 21st dynasty, described Pott's disease of the spine with typical deformity and a big right psoas abscess

crepitus, and defined sprain as "rending of two membranes although each is still in its place."

Infected open fractures with fever were considered grave injuries. The favourite dressing of the wound in the first day was fresh meat (haemostatic). In the following



Fig. 5 Seneb, an achondroplasic dwarf, with two children replacing his normal legs

Fig. 6 Skeleton of achondroplasic dwarf, from Hierakonpolis, Upper Egypt

days a dressing of honey (hygroscopic) and oil (to prevent sticking of the dressing) was used unless it was feared it would interfere with drainage. The application of mouldy bread was also practised (in modern days, penicillin was first extracted from moulds) [1].

Several cases of tuberculosis of the spine were reported as early as the predynastic time. The most authenticated case is that described in Nesparehan, a priest of Amun. It shows the typical collapse of a dorsal vertebra with angular kyphosis and a big psoas abscess in the right iliac fossa (Fig. 4).



Fig. 8 A stella of Kig-Tut-Ankh Amun and his wife, showing the Pharaoh using a walking stick

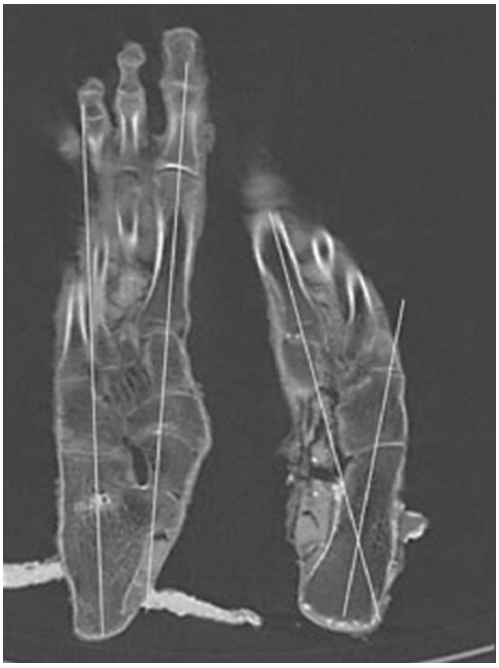

Fig. 7 CT scan of Tut-Ankh-Amun's feet showing shorter left foot, the seat of varus deformity

Several examples of congenital anomalies, deformities and hormonal disturbances are present in Ancient Egyptian history. Seneb is a typical example of achondroplasic dwarf in the 19th dynasty (Fig. 5). He held important priesthoods in

Fig. 9 Queen of Punt, from Dair El Bahari Temple, 18th dynasty



Fig. 10 Ruma, portrayed on his funeral stella, with a grossly wasted and shortened leg accompanied by an equinus deformity suggesting poliomyelitis

addition to being overseer of weaving of the palace. Other dwarfs were employed as personal attendants and entertainers. Skeletons of two achondroplasic dwarfs were found in a necropolis of Hierakonpolis in Upper Egypt (Fig. 6).



Fig. 11 Surgical instruments from Kom Ombo Temple including (1) knives, (2) drill, (3) saw, (4) forceps or pincers, (5) censer, (6) hooks, etc.

Fig. 12 Radiograph of right knee of Usermentu showing fixation by iron pin

A case of severe bilateral clubfeet is depicted in a Middle Kingdom tomb of Baqt in Beni Hassan. Above it is written the word djeneb, meaning "crooked". The Egyptian Pharaoh Septah of the 19th dynasty suffered from club foot; his mummy is shown in the Egyptian Museum in Cairo. A recent CT scan of the feet of Tut-Ankh-Amun, the famous Pharaoh of the 18th dynasty, revealed that he suffered from severe varus deformity of his left foot which was also appreciably short (Fig. 7) [6]. This is probably why the Pharaoh was usually depicted using a walking stick (Fig. 8). Thirty-two wooden walking sticks, gilded and beautifully decorated, were found in his tomb.

The Queen of Punt in a bas-relief from the temple of Queen Hatshepsut in Dair El Bahari (18th dynasty) raises a diagnostic problem. She is excessively fat, with exaggerated lumbar lordosis, suggesting spondyloptosis or bilateral congenital dislocation of hips (Fig. 9).

Poliomyelitis was also known at that time and was shown in some paintings and sculptures. Ruma, a doorkeeper from the 19th dynasty is portrayed on his funeral

Fig. 13 Prosthesis of the right big toe made of wood and leather

stella with a withered leg, most likely caused by paralytic poliomyelitis (Fig. 10).

Surgery was evidently advanced in Egypt at the end of the dynastic era as shown by the elaborate surgical instruments engraved in a panel in Kom Ombo Temple in 180–47 BC. Knives, a drill, a saw, hooks, forceps and shears can be recognised (Fig. 11). Two cases of successful amputations, one of arm and the other of leg were recorded in the literature, suggesting the use of the bone saw. In a mummy found in Usermontu's sarcophagus, who lived ca. 630 BC, radiographs revealed that the right knee joint is the seat of intramedullary fixation by an iron pin [7]. Forensic medical study suggests that it had been inserted around the time of death (Fig. 12) [8].

Probably the oldest known prosthesis is that replacing the right big toe in a mummy of a woman found in excavations at the necropolis of Thebes (Fig. 13) [9].

These were examples of how ancient Egyptian healers treated skeletal injuries and diseases. These may also open our imagination of the possible state of medical practice at the dawn of civilisation.

References

1. Nunn JF (1996) Ancient Egyptian medicine. British Museum Press, London
2. Smith GE (1908) The most ancient splints. Br Med J 1:732–736
3. Ghalioungui P, el Dawakhly Z (1965) Health and healing in Ancient Egypt. Dar Al-Maarif, Cairo
4. Hussein MK (1968) Kocher's method is 3000 years old. J Bone Joint Surg B 50B:669–671
5. Breasted JH (1930) The Edwin-Smith surgical papyrus. The Chicago University Press, Chicago
6. Hawass Z, Gad YZ, Ismail S et al (2010) Ancestry and pathology in King Tutankhamun's family. JAMA 303:638–647
7. Snow K (1996) BYU professor finds evidence of advanced surgery in ancient mummy. Brigham Young University Magazine, BYU, Utah
8. Colton C (2013) Orthopedic challenges in Ancient Egypt. Bone & Joint360 2(2):2–7
9. Nerlich AG, Zink A, Szeimies U, Hagedorn HG (2000) Ancient Egyptian prosthesis of the big toe. Lancet 356:2176–2179