NIH Public Access
Author Manuscript
Catheter Cardiovasc Interv. Author manuscript; available in PMC 2013 December 01.

Published in final edited form as:
Catheter Cardiovasc Interv. 2013 December 1; 82(7): . doi:10.1002/ccd.24983.

Angiographic Characteristics of Femoropopliteal In-Stent Restenosis: Association with Long-Term Outcomes After Endovascular Intervention

Ehrin J. Armstrong, MD, MSc[1], **Satinder Singh, MD**[1], **Gagan D. Singh, MD**[1], **Khung-Keong Yeo, MBBS**[1], **Shaan Ludder, BA**[1], **Gregory Westin, BA**[1], **David Anderson, BA**[1], **David L. Dawson, MD**[2], **William C. Pevec, MD**[2], and **John R. Laird, MD, FSCAI**[1,*]

[1]Division of Cardiovascular Medicine and the Vascular Center, University of California, Davis Medical Center, Sacramento, California

[2]Division of Vascular and Endovascular Surgery and the Vascular Center, University of California, Davis Medical Center, Sacramento, California

Abstract

Objectives—The purpose of this study was to identify the relationship between angiographic patterns of restenosis and outcomes after endovascular treatment of femoro-popliteal in-stent restenosis (FP-ISR).

Background—ISR is a frequent clinical problem after femoro-popliteal stenting.

Methods—This was a single center study of all endovascular interventions for FP-ISR from 2006 to 2012. Class I ISR was defined as focal lesions ≤50 mm; Class II ISR as lesions > 50 mm; and Class III ISR as stent chronic total occlusion. Recurrent ISR was defined as peak systolic velocity ratio > 2.4 by duplex ultrasound.

Results—Among 75 cases of FP-ISR, 28 (37%) were Class I, 22 (29%) were Class II, and 25 (33%) were Class III. The mean lesion length was 26 mm for Class I, 135 mm for Class II, and 178 mm for Class III ISR. Patients with Class III ISR more frequently had ISR extending into both the superficial femoral and popliteal artery (48% vs. 18%, $P = 0.005$). Balloon angioplasty was used most frequently to treat Class I ISR, while adjunctive atherectomy and/or stenting was used for almost all cases of Class III ISR. During 2-year follow-up, rates of repeat restenosis were 39% for Class I, 67% for Class II, and 72% for Class III ISR ($P = 0.04$). Rates of stent occlusion were 8% for Class I, 11% for Class II, and 52% for Class III ISR ($P = 0.009$). Class III ISR was associated with significantly increased risk of recurrent ISR (HR 2.4, 95% CI 1.1–5.6) and recurrent occlusion (HR 5.8, 95% CI 1.8–19.0) compared to other types of ISR.

Conclusion—Angiographic patterns of FP-ISR are important determinants of subsequent outcomes. Repeat restenosis and occlusion remain common despite currently available technologies.

Keywords

peripheral arterial disease; superficial femoral artery; in-stent restenosis

© 2013 Wiley Periodicals, Inc

*Correspondence to: John R. Laird, Medical Director of the Vascular Center, UC Davis Medical Center, 4860 Y Street, Suite 3400, Sacramento, CA 95817. john.laird@ucdmc.ucdavis.edu.

Conflict of interest: Nothing to report.

NIH-PA Author Manuscript
NIH-PA Author Manuscript
NIH-PA Author Manuscript

NIH-PA Author Manuscript

NIH-PA Author Manuscript

NIH-PA Author Manuscript

INTRODUCTION

Stenting of the superficial femoral and popliteal artery is an increasingly common treatment for lifestyle-limiting claudication and critical limb ischemia. Although early self-expanding stents had high rates of stent fracture and failure [1], newer nitinol-self expanding stents have increased conformability and low fracture rates out to three years [2]. Despite advances in femoropopliteal (FP) stent technology, in-stent restenosis (ISR) remains a common clinical problem, with an estimated rate of 19–37% in clinical trials of moderate length (up to 150 mm) lesions [3,4]. Proposed treatment options for FP-ISR include balloon angioplasty, cutting balloon angioplasty, atherectomy (either excisional or with a laser), repeat stenting, or endoluminal bypass with a covered stent [5–8]. Outside of the United States, drug coated balloons and drug eluting stents have also emerged as a promising treatment for FP-ISR [9,10]. A recent study found that, analogous to coronary ISR, different angiographic classes of FP-ISR are independent predictors of outcomes after balloon angioplasty [11,12]. Whether these findings apply to other treatment modalities for FP-ISR remains uncertain.

The purpose of this study was to describe the angiographic characteristics of FP-ISR and the association of these findings with subsequent clinical outcomes among a real-world cohort of patients treated with balloon angioplasty, atherectomy, and provisional bare metal or covered stent placement. We hypothesized that ISR length would be an important determinant of recurrent restenosis, but that stent occlusion would also be an independent predictor of adverse clinical outcomes.

METHODS

The PAD-UCD Registry comprises all patients with a clinical diagnosis of peripheral arterial disease who underwent diagnostic angiography and/or therapeutic endovascular intervention at the University of California, Davis Medical Center beginning in 2006. During this timeframe, three vascular surgeons and one interventional cardiologist performed the procedures. At the time of data analysis, the registry included 975 patients and 1,490 unique procedures. The study protocol was approved by the Institutional Review Board at UC Davis Medical Center.

Data Collection and Definitions

During the study period 256 patients underwent FP stenting, and 75 patients underwent procedures for FP-ISR. FP stenting was defined as any stent placement between the origin of the superficial femoral artery and the distal popliteal artery prior to the origin the anterior tibial artery. These procedures were retrospectively analyzed from review of electronic medical record documentation. Preprocedure and postprocedure history and physical examination documentation were used to identify clinical presentation as well as postprocedure outcomes and medical management. The Rutherford classification was used to identify the category of limb ischemia both during the initial stent placement and at the time of intervention for FP-ISR [13].

Ankle-brachial pressure index (ABI) measurements and duplex ultrasound (DUS) were obtained in patients before endovascular treatment and at follow-up. Two physicians reviewed all angiographic images to verify lesion morphology and characteristics, TransAtlantic InterSociety Consensus (TASC) II classification, and status of the distal run-off vessels. In-stent restenosis was classified by visual estimate as class I (focal, lesion length ≤50 mm), class II (diffuse, >50 mm long), or class III (chronic total occlusion of the stent), as recently described [12]. Unsubtracted digital images were examined to identify the presence of stent fractures, which were classified on a 1–4 scale by type [14]. Procedural

NIH-PA Author Manuscript

NIH-PA Author Manuscript

NIH-PA Author Manuscript

data included the type of intervention performed: balloon angioplasty, cutting balloon angioplasty, cryoplasty, excisional atherectomy, or laser atherectomy. The type of stent (self-expanding or self-expanding covered) was also recorded. Procedural success was defined as <30% stenosis at the conclusion of the procedure without major adverse cardiovascular event.

Patients were routinely seen 30 days after the revascularization procedure. This visit included an assessment of the patient's clinical improvement as well as interval ABI and DUS examination. Postoperative follow-up, consisting of a clinical and serial DUS examination, was then conducted every 3 months during the first postoperative year and every 6–12 months thereafter.

Restenosis was evaluated with serial ABI and toe brachial index (TBI) measures and DUS at 0–30 days, 4–6 months, 9–12 months, and every 6 months thereafter. Restenosis was defined as the presence of >50% stenosis at the treatment site (peak systolic velocity ratio >2.4), or by target lesion revascularization. Target vessel revascularization was defined as any repeat endovascular intervention or surgical bypass to the stented vessel. Major amputation was defined as any amputation above the level of the ankle joint.

Outcomes

The primary endpoint was restenosis (>50% stenosis by DUS or angiographic assessment). Secondary outcomes included stent occlusion, target vessel revascularization, need for surgical bypass grafting, and ipsilateral major amputation.

Data Analysis

Mean values with standard deviation were used to describe continuous variables, and numerical values (percentages) were used for categorical variables. Univariate analysis was used to identify predictors of restenosis. Continuous variables were compared using analysis of variance. Categorical values were compared by the chi square or Fisher's exact test. Freedom from binary restenosis and freedom from occlusion were analyzed with the use of Kaplan–Meier survival estimates and the log-rank test.

All tests were performed using two-sided tests, and the value for statistical significance was <0.05. Analyses were conducted using STATA Version 11.2 (STATA Corporation, College Station, Texas). All authors had full access to and take full responsibility for the integrity of the data. All authors have read and agree to the manuscript as written.

RESULTS

During the study period, 75 patients underwent endovascular intervention for FP-ISR. 28 cases were Class I (focal ≤50 mm), 22 were Class II (diffuse, >50 mm), and 25 were Class III ISR (chronic total occlusion). Thirty-nine (52%) of the patients had stents initially implanted during endovascular limb salvage for critical limb ischemia; the indication for the initial intervention did not differ among groups. The median time from initial stent implantation to treatment for ISR was 9.5 months (IQR 6.9–13.3 months), without any difference among groups.

The baseline characteristics of the patients at the time of treatment for ISR were similar regardless of ISR class, with a high prevalence of diabetes, coronary artery disease, and current or former smoking (Table I). Preprocedure statin use was also similar among groups, ranging from 79 to 84%. The indication for the ISR intervention was primarily claudication among patients with Class I or Class II ISR, whereas a majority of patients with Class III ISR (56%) underwent intervention for critical limb ischemia. No patients initially treated for

NIH-PA Author Manuscript

NIH-PA Author Manuscript

NIH-PA Author Manuscript

claudication subsequently presented with critical limb ischemia due to FP-ISR, and all of the patients with critical limb ischemia and FP-ISR had their initial stent placed during treatment for critical limb ischemia.

The angiographic characteristics for each ISR class are summarized in Table II. The mean length of ISR for each class was 26, 135, and 178 mm, respectively. Patients with Class III ISR were more likely to have TASC II C/D lesions at the time of intervention for FP-ISR. Patients with Class III ISR also more frequently had restenotic lesions that extended into both the SFA and popliteal arteries (11, 27, and 48% for class I, II, and III respectively, $P = 0.01$). The overall stent fracture rate was 17%, with similar fracture rates among groups. However, all of the severe stent fractures (grade 3–4) occurred among patients with Type III ISR ($P = 0.02$). There was no difference in rates of below-knee runoff or reference vessel diameter among the three ISR classes.

Treatment characteristics are summarized in Fig. 1. There was significant heterogeneity in treatment approach related to the ISR class due operator preference for a given modality as a function of FP-ISR complexity. Patients with Class I ISR were more frequently (61%) treated with either balloon or cutting balloon angioplasty alone, whereas only one patient (4%) with Class III ISR was treated with cutting balloon angioplasty alone ($P < 0.001$). Laser atherectomy was the most common adjunctive debulking technique, representing 45 and 60% of the Class II and III ISR cases, respectively ($P < 0.001$ vs. Class I). Laser atherectomy was used both in conjunction with balloon angioplasty and with stenting. Placement of a new stent was most common (56%) among patients with Class III ISR. Covered stent grafts were used in 11, 23, and 16% of the patients with Class I, II and III FP-ISR.

Procedural success was achieved in 74/75 (99%) of patients. During the procedure, two cases of distal embolization occurred among patients undergoing laser atherectomy, and both patients were successfully treated with aspiration thrombectomy with restoration of distal flow. One case of flow-limiting dissection occurred in a patient with Class I ISR for whom balloon angioplasty alone was initially attempted; this patient was treated successfully with provisional stenting. Postprocedure, all groups had significant improvement in ABI and TBI measurements at 30 days (Table III), with a mean ABI gain of 0.28 ± 0.2 ($P < 0.001$ compared with preprocedure ABI). All but one patient had stable or improved Rutherford classification at 30-day follow up. There were no subsequent major amputations of the ipsilateral limb among any of the study subjects. Six deaths occurred over a median follow up of 2 years: one in a patient with class I ISR, and five in patients with class III ISR ($P = 0.1$). All six of these patients had critical limb ischemia.

During long-term follow-up to 2 years, the Kaplan-Meier estimated rates of restenosis were 39% for Class I ISR, 67% for Class II ISR, and 72% for Class III ISR ($P = 0.04$). Compared to Class I ISR, Class III ISR was associated with a significantly higher risk of restenosis (HR 2.4, 95% CI 1.1–5.6) (Fig. 2). Reocclusion rates at 2 years were 8% for Class I ISR, 11% for Class II ISR, and 52% for Class III ISR ($P = 0.009$). Class III ISR was also independently associated with an increased risk of occlusion during long-term follow-up (HR 5.8, 95% CI 1.8–19) when compared to Class I or Class II ISR (Fig. 3). The 2-year rates of target vessel revascularization were similar among groups: 39% for Class I ISR, 28% for Class II ISR, and 32% for Class III ISR ($P = 0.7$). Although patients with Class III ISR had higher absolute rates of subsequent bypass surgery, the difference was not statistically significant (HR 3.4, 95% CI 0.6–20), (Fig. 4).

NIH-PA Author Manuscript

NIH-PA Author Manuscript

NIH-PA Author Manuscript

DISCUSSION

The major finding of this study is that the angiographic classification of FP-ISR predicts restenosis and occlusion after endovascular treatment. Rates of restenosis and reintervention were high for all classes of ISR, but Class III ISR (occlusion of the stent) was associated with significantly increased rates of restenosis and reocclusion compared to other groups. These findings are especially significant because the study cohort consisted of a real-world group of patients for whom a multimodality approach to the treatment of FP-ISR was employed.

Consistent with the real-world application of techniques, the majority of patients with Class I ISR (61%) were treated solely with balloon or cutting balloon angioplasty, and only a minority of these patients required debulking atherectomy or adjunctive stenting. The comparatively good long-term results among patients with Class I FP-ISR suggest that balloon angioplasty with provisional stenting remains a reasonable treatment approach toward focal FP-ISR under 50 mm in length. A previous randomized study did not find any difference in outcomes with balloon versus cutting balloon angioplasty, so either technique is likely acceptable in such cases, although cutting balloon angioplasty is significantly more expensive than balloon angioplasty [5]. In comparison, patients with diffuse FP-ISR (Class II) or total occlusion of the stent (Class III) were more frequently treated with atherectomy, either with or without new stent placement. The use of atherectomy is theoretically attractive, as it may remove much of the neointima and create a larger lumen cross sectional area, thereby potentially reducing the risk of recurrent restenosis. However, recent results with excisional or laser atherectomy for the treatment of ISR have not convincingly decreased rates of subsequent restenosis [6,7]. The poor results following atherectomy for class II or class III FP-ISR in this and previous studies suggest that atherectomy with or without adjunctive balloon angioplasty is not an effective long-term treatment for class II or class III FP-ISR.

Adjunctive stenting was selectively employed in this cohort. The decision to place a new stent in the setting of ISR is difficult, as implantation of a new stent may further stimulate inflammatory pathways leading to restenosis. Although some investigators have recommended use of nitinol stents covered with polytetrafluoroethylene (PTFE) to exclude the neointima, concerns regarding edge restenosis and subsequent thrombosis remain, especially among patients with limited infrapopliteal runoff [15–17]. An alternative strategy includes combined laser atherectomy and placement of a PTFE-covered endoprosthesis. The SALVAGE study, which utilized laser atherectomy with placement of a PTFE-covered nitinol self-expanding stent, reported primary patency of 48% at 12 months [7].

The categories of FP-ISR used in this study were initially described by Tosaka et al. [12], who reported that Class III ISR was an independent predictor of restenosis, reocclusion, and need for subsequent bypass. That study's findings may have less broad applicability, because all patients were treated with balloon angioplasty only and the results may therefore not reflect outcomes among patients treated with atherectomy or adjunctive stenting. Similar to that study, we found that class III ISR remained an independent predictor of restenosis and reocclusion despite more frequent use of atherectomy and stent placement among patients with class III ISR. Although our study was underpowered to detect differences in bypass rates, there was also a nonsignificant trend toward greater rates of subsequent surgical bypass among patients with class III ISR. Although this study was underpowered to examine the differential effects of a given device, the similarity of these results despite use of adjunctive technologies potentially suggests no additional benefit of currently available interventions on rates of restenosis.

NIH-PA Author Manuscript

NIH-PA Author Manuscript

NIH-PA Author Manuscript

The high rate of restenosis and reocclusion among patients FP-ISR suggests that new technologies are necessary to address this clinical problem. Recent studies have reported encouraging results with drug-coated balloons and drug-eluting stents in reducing rates of restenosis, and these technologies may also have benefit in treatment of FP-ISR [18–21]. A series of 39 patients treated for FP-ISR with a paclitaxel-coated balloon reported a 1-year primary patency rate of 92.1% [9]. The mean lesion length in that study was 82.9 mm, and 20.5% of patients had class III ISR. The overall size of the cohort was too small to determine whether use of the paclitaxel-coated balloon had a differential effect depending on the class of ISR, but patients in that study with class III ISR had outcomes similar to the overall group. If these results are replicated in a larger cohort, then drug-coated balloons may become first-line therapy for FP-ISR. Drug-eluting stents may also be a reasonable treatment for FP-ISR, especially if initial results are suboptimal after balloon angioplasty. In the Zilver PTX Registry, a subset of 142 lesions was treated for FP-ISR with a paclitaxel-eluting stent, and the reported freedom from target lesion revascularization at 2 years was 69% [10].

This study has several potential limitations. This was an observational study, and interventions were therefore performed according to the operators' discretion. However, these findings represent real-world application of currently available technology in the United States. Second, the small size of the sample cohort may have made the study underpowered to detect differential outcomes among types of ISR. The small sample size also limited our ability to perform multivariable adjustment. Third, the broad use of techniques does not allow us to comment on the differential utility of a given technique for each class of FP-ISR.

In summary, angiographic patterns of FP-ISR remain important determinants of subsequent outcomes after endovascular intervention. Repeat restenosis and occlusion remain common despite currently available (non-drug-eluting) technologies. Class III (total occlusion) ISR is associated with increased rates of restenosis and reocclusion compared to other types of FP-ISR. Future studies should be performed with drug-coated balloons and drug-eluting stents to confirm whether these technologies reduce the rates of restenosis and improve clinical outcomes after treatment of FP-ISR.

REFERENCES

1. Scheinert D, Scheinert S, Sax J, et al. Prevalence and clinical impact of stent fractures after femoropopliteal stenting. J Am Coll Cardiol. 2005; 45:312–315. [PubMed: 15653033]
2. Laird JR, Katzen BT, Scheinert D, et al. Nitinol stent implantation vs. balloon angioplasty for lesions in the superficial femoral and proximal popliteal arteries of patients with claudication: Three-year follow-up from the RESILIENT randomized trial. J Endovasc Ther. 2012; 19:1–9. [PubMed: 22313193]
3. Schillinger M, Sabeti S, Loewe C, et al. Balloon angioplasty versus implantation of nitinol stents in the superficial femoral artery. N Engl J Med. 2006; 354:1879–1888. [PubMed: 16672699]
4. Laird JR, Katzen BT, Scheinert D, et al. Nitinol stent implantation versus balloon angioplasty for lesions in the superficial femoral artery and proximal popliteal artery: Twelve-month results from the RESILIENT randomized trial. Circ Cardiovasc Interv. 2010; 3:267–276. [PubMed: 20484101]
5. Dick P, Sabeti S, Mlekusch W, et al. Conventional balloon angioplasty versus peripheral cutting balloon angioplasty for treatment of femoropopliteal artery in-stent restenosis: Initial experience. Radiology. 2008; 248:297–302. [PubMed: 18566179]
6. Zeller T, Rastan A, Sixt S, et al. Long-term results after directional atherectomy of femoro-popliteal lesions. J Am Coll Cardiol. 2006; 48:1573–1578. [PubMed: 17045890]
7. Laird JR Jr, Yeo KK, Rocha-Singh K, et al. Excimer laser with adjunctive balloon angioplasty and heparin-coated self-expanding stent grafts for the treatment of femoropopliteal artery in-stent

NIH-PA Author Manuscript

NIH-PA Author Manuscript

NIH-PA Author Manuscript

restenosis: Twelve-month results from the SALVAGE study. Catheter Cardiovasc Interv. 2012; 80:852–859. [PubMed: 22422738]

8. Yeo KK, Malik U, Laird JR. Outcomes following treatment of femoropopliteal in-stent restenosis: A single center experience. Catheter Cardiovasc Interv. 2011; 78:604–608. [PubMed: 21567880]
9. Stabile E, Virga V, Salemme L, et al. Drug-eluting balloon for treatment of superficial femoral artery in-stent restenosis. J Am Coll Cardiol. 2012; 60:1739–1742. [PubMed: 23040582]
10. Dake MD, Scheinert D, Tepe G, et al. Nitinol stents with polymer-free paclitaxel coating for lesions in the superficial femoral and popliteal arteries above the knee: Twelve-month safety and effectiveness results from the Zilver PTX single-arm clinical study. J Endovasc Ther. 2011; 18:613–623. [PubMed: 21992630]
11. Mehran R, Dangas G, Abizaid AS, et al. Angiographic patterns of in-stent restenosis: Classification and implications for long-term outcome. Circulation. 1999; 100:1872–1878. [PubMed: 10545431]
12. Tosaka A, Soga Y, Iida O, et al. Classification and clinical impact of restenosis after femoropopliteal stenting. J Am Coll Cardiol. 2012; 59:16–23. [PubMed: 22192663]
13. Rutherford RB, Baker JD, Ernst C, et al. Recommended standards for reports dealing with lower extremity ischemia: Revised version. J Vasc Surg. 1997; 26:517–538. [PubMed: 9308598]
14. Popma JJ, Tiroch K, Almonacid A, Cohen S, Kandzari DE, Leon MB. A qualitative and quantitative angiographic analysis of stent fracture late following sirolimus-eluting stent implantation. Am J Cardiol. 2009; 103:923–929. [PubMed: 19327417]
15. Fischer M, Schwabe C, Schulte KL. Value of the hemobahn/viabahn endoprosthesis in the treatment of long chronic lesions of the superficial femoral artery: 6 years of experience. J Endovasc Ther. 2006; 13:281–290. [PubMed: 16784314]
16. Kedora J, Hohmann S, Garrett W, Munschaur C, Theune B, Gable D. Randomized comparison of percutaneous Viabahn stent grafts vs prosthetic femoral-popliteal bypass in the treatment of superficial femoral arterial occlusive disease. J Vasc Surg. 2007; 45:10–16. discussion 16. [PubMed: 17126520]
17. Saxon RR, Coffman JM, Gooding JM, Ponec DJ. Long-term patency and clinical outcome of the Viabahn stent-graft for femoropopliteal artery obstructions. J Vasc Interv Radiol. 2007; 18:1341–1349. quiz 1350. [PubMed: 18003983]
18. Micari A, Cioppa A, Vadala G, et al. Clinical evaluation of a paclitaxel-eluting balloon for treatment of femoropopliteal arterial disease: 12-month results from a multicenter Italian registry. JACC Cardiovasc Interv. 2012; 5:331–338. [PubMed: 22440500]
19. Tepe G, Zeller T, Albrecht T, et al. Local delivery of paclitaxel to inhibit restenosis during angioplasty of the leg. N Engl J Med. 2008; 358:689–699. [PubMed: 18272892]
20. Werk M, Langner S, Reinkensmeier B, et al. Inhibition of restenosis in femoropopliteal arteries. Paclitaxel-coated versus uncoated balloon: Femoral paclitaxel randomized pilot trial. Circulation. 2008; 118:1358–1365. [PubMed: 18779447]
21. Dake MD, Ansel GM, Jaff MR, et al. Paclitaxel-eluting stents show superiority to balloon angioplasty and bare metal stents in femoropopliteal disease: Twelve-month Zilver PTX randomized study results. Circ Cardiovasc Interv. 2011; 4:495–504. [PubMed: 21953370]

NIH-PA Author Manuscript

NIH-PA Author Manuscript

NIH-PA Author Manuscript

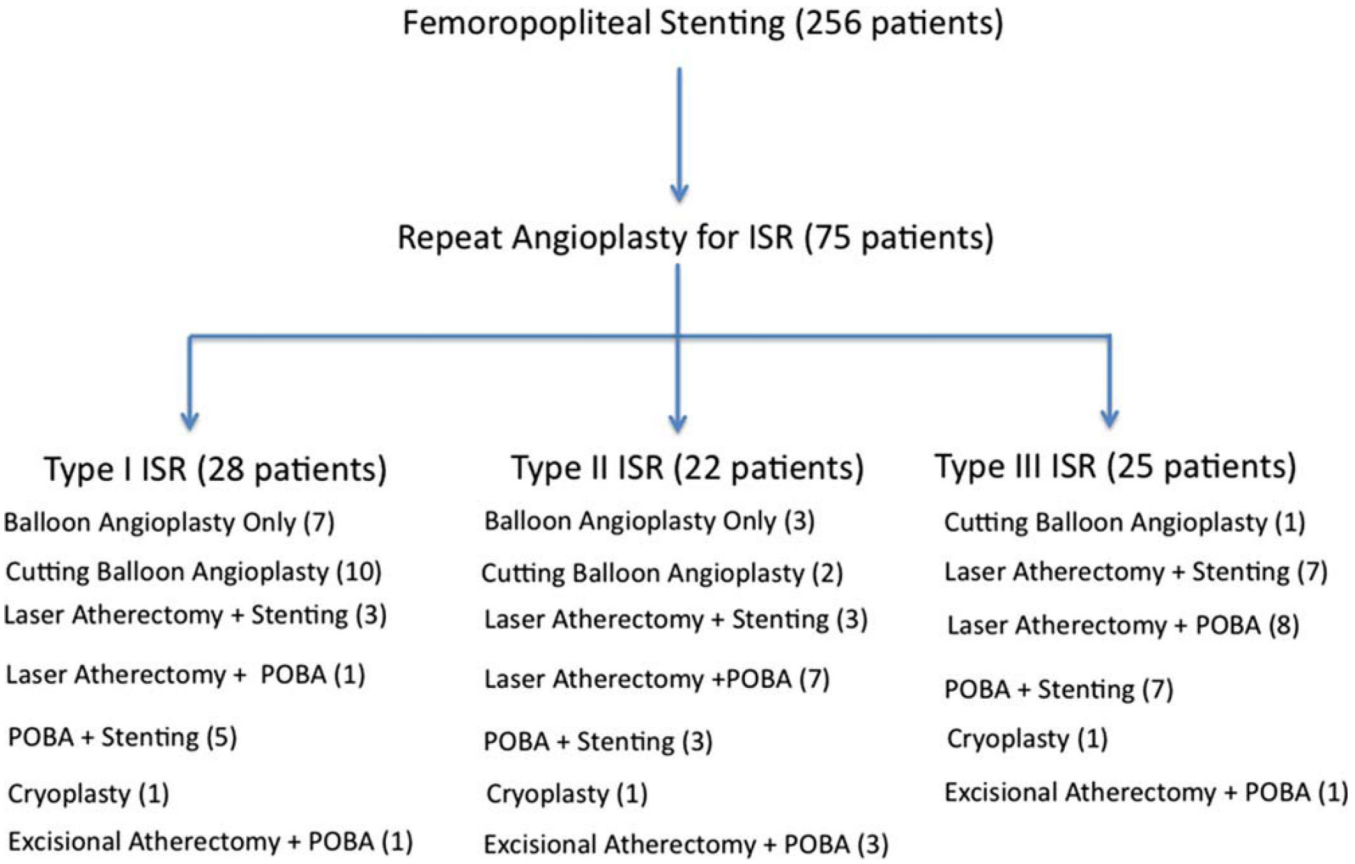

Fig. 1.
Study Design. Patients were categorized by type of in-stent restenosis and the treatment modality utilized. [Color figure can be viewed in the online issue, which is available at wileyonlinelibrary.com.]

NIH-PA Author Manuscript

NIH-PA Author Manuscript

NIH-PA Author Manuscript

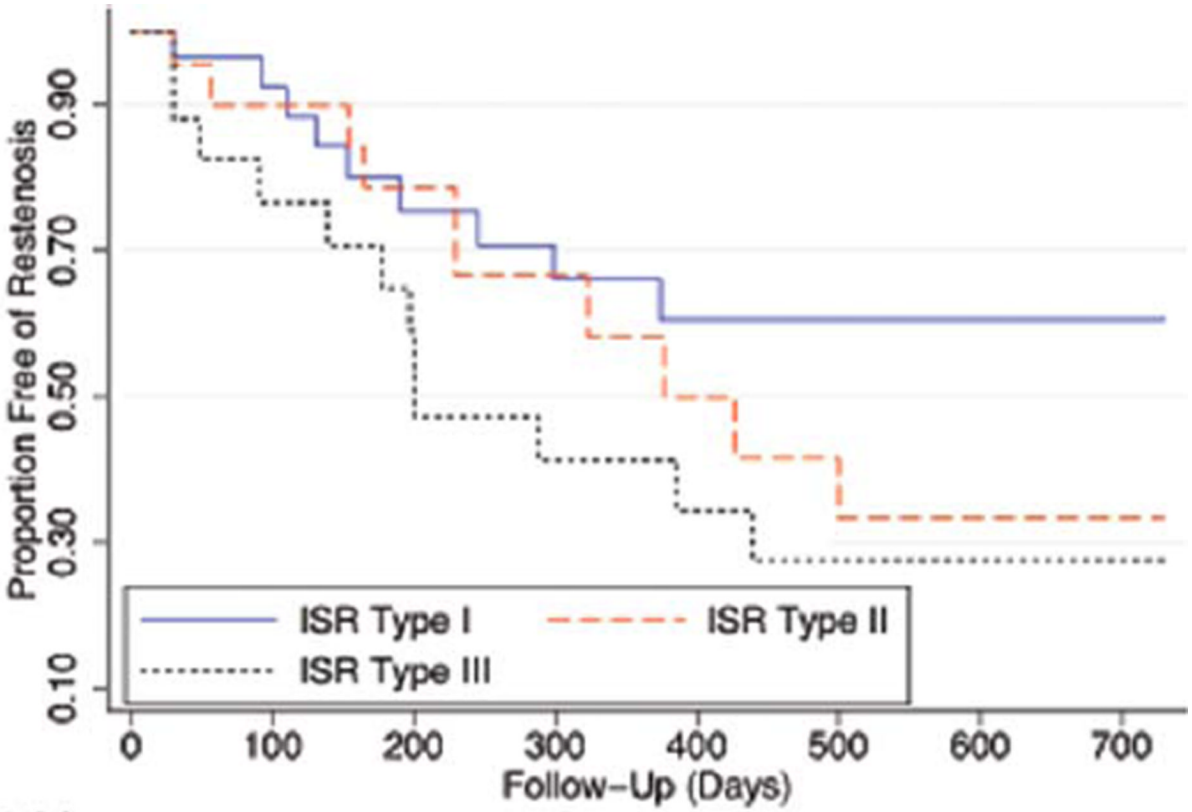

Number at risk								
ISR Type I	28	23	16	14	11	9	8	8
ISR Type II	22	16	14	8	6	5	4	4
ISR Type III	25	13	10	7	5	4	3	2

Fig. 2.

Rates of Restenosis by ISR Classification. Overall restenosis rates were high. Type III (total occlusion of the stent) ISR was associated with higher rates of recurrent restenosis than type I or type II ISR. [Color figure can be viewed in the online issue, which is available at wileyonlinelibrary.com.]

NIH-PA Author Manuscript

NIH-PA Author Manuscript

NIH-PA Author Manuscript

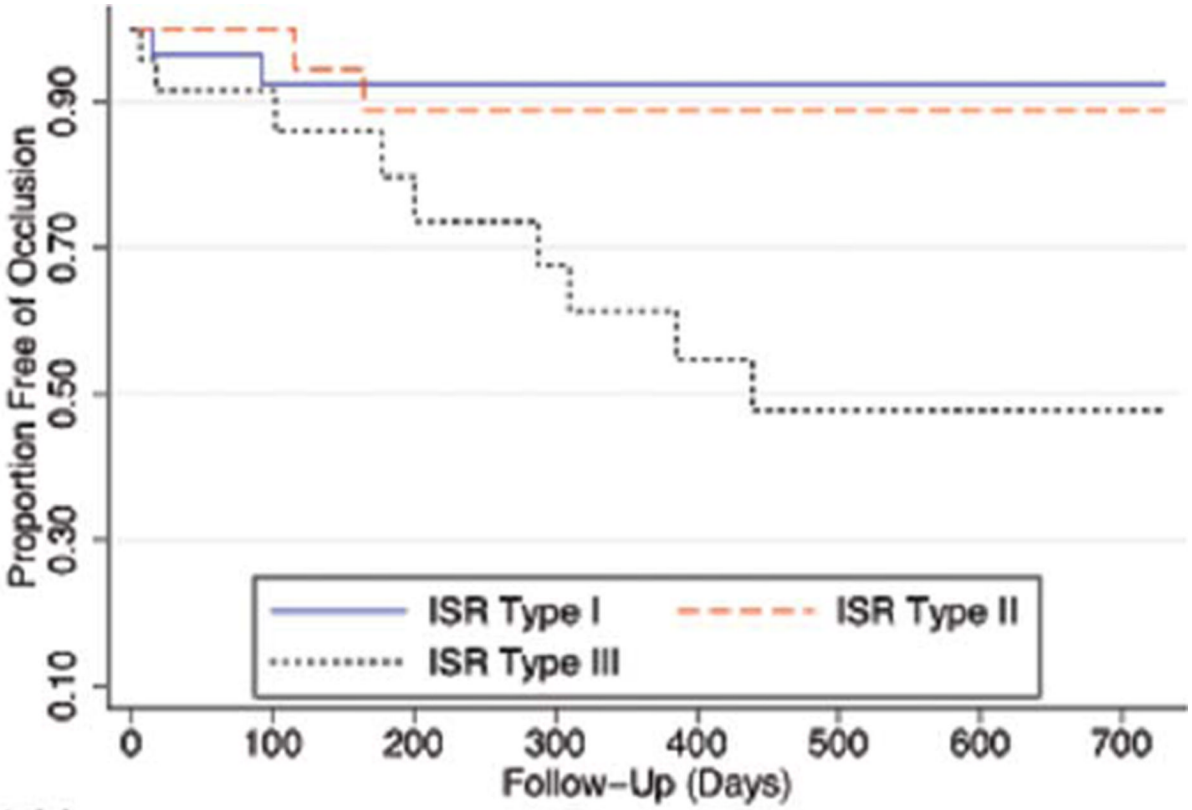

Number at risk								
ISR Type I	28	23	20	19	16	14	12	12
ISR Type II	22	18	16	12	10	10	9	8
ISR Type III	25	16	13	11	8	7	6	5

Fig. 3.

Rates of Occlusion by ISR Classification. Type I (focal) and type II (diffuse) ISR were associated with low subsequent rates of subsequent stent occlusion, while type III (occlusion of the stent) was associated with significantly higher rates of reocclusion. [Color figure can be viewed in the online issue, which is available at wileyonlinelibrary.com.]

NIH-PA Author Manuscript

NIH-PA Author Manuscript

NIH-PA Author Manuscript

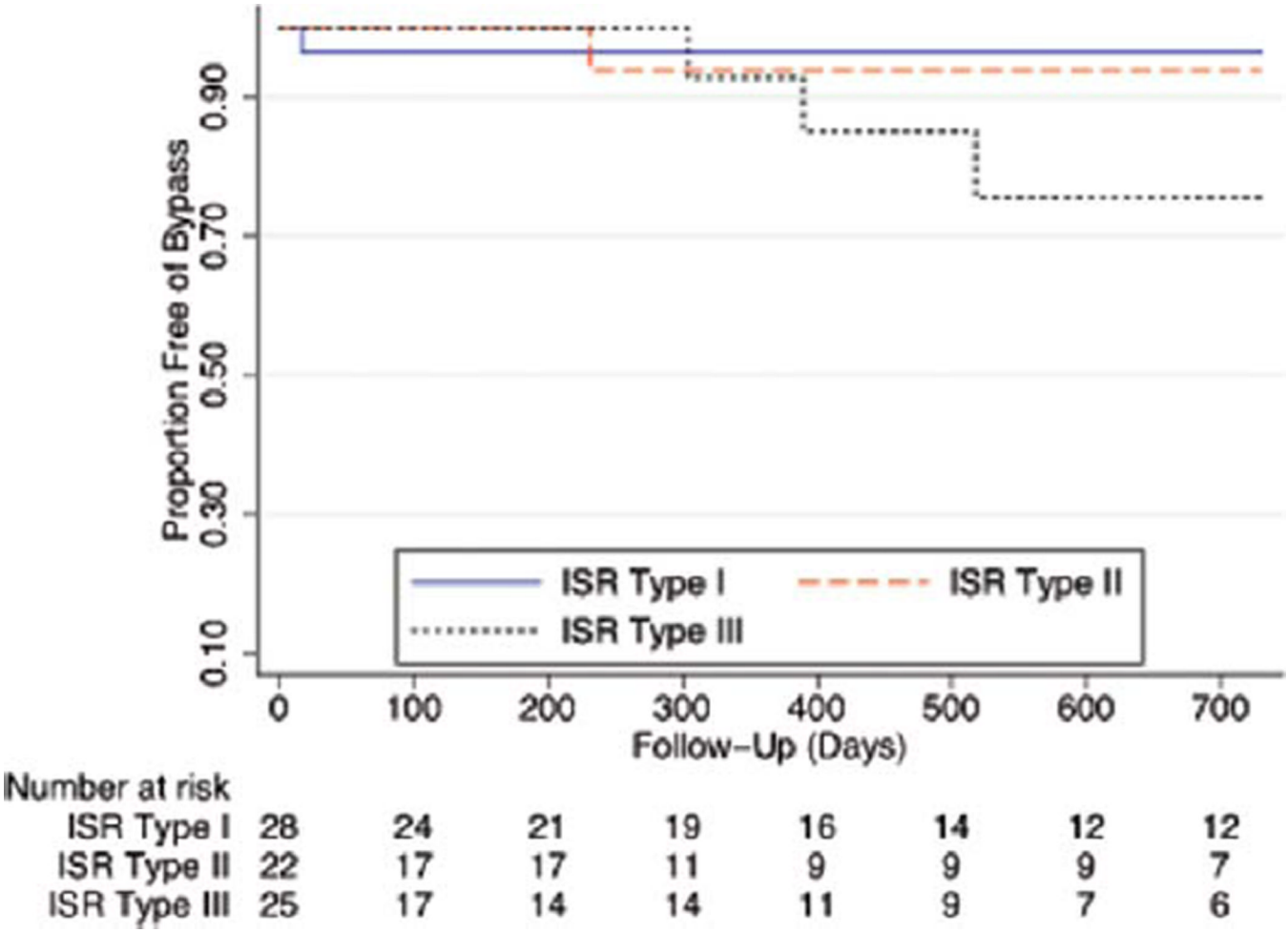

Fig. 4.

Rates of Bypass Surgery By ISR Classification. There was a nonsignificant trend toward higher rates of subsequent surgical bypass among patients with type III ISR. [Color figure can be viewed in the online issue, which is available at wileyonlinelibrary.com.]

NIH-PA Author Manuscript

NIH-PA Author Manuscript

NIH-PA Author Manuscript

TABLE I

Baseline Patient Characteristics

Variable	Type I ISR (*n* = 28)	Type II ISR (*n* = 22)	Type III ISR (*n* = 25)	*P* value
Age, years	67 ± 10	68 ± 12	70 ± 23	0.9
Male (%)	13 (46)	11 (50)	13 (52)	0.9
BMI (kg/m^2)	28 ± 6	29 ± 7	26 ± 4	0.2
Current/former smoker (%)	24 (86)	16 (73)	15 (63)	0.2
CHF (%)	7 (25)	4 (18)	7 (28)	0.7
Diabetes (%)	15 (56)	14 (63)	15 (60)	0.8
GFR	69 ± 31	72 ± 37	67 ± 49	0.9
CKD (%)	11 (39)	7 (32)	14 (56)	0.2
HTN (%)	25 (89)	22 (100)	21 (84)	0.2
CAD (%)	15 (56)	9 (41)	14 (56)	0.5
Statin (%)	22 (79)	18 (82)	21 (84)	0.9
Aspirin (%)	26 (93)	22 (100)	20 (80)	0.06
Clopidogrel (%)	22 (79)	16 (73)	16 (64)	0.5
Initial Indication for Stent				0.9
Claudication	14 (50)	11 (50)	11 (44)	
CLI	14 (50)	11 (50)	14 (56)	
Initial Stent Length, mm	148 ± 107	207 ± 70	193 ± 95	0.3
Rutherford Class at time of ISR (%)				0.2
1–3	16 (57)	15 (68)	11 (44)	
4–6	12 (43)	7 (32)	14 (56)	
ABI	0.7 ± 0.2	0.7 ± 0.2	0.6 ± 0.2	0.2
TBI	0.4 ± 0.2	0.4 ± 0.2	0.2 ± 0.1	0.03

BMI, body mass index; CHF, congestive heart failure; GFR, glomerular filtration rate; CKD, chronic kidney disease; HTN, hypertension; CAD, coronary artery disease; CLI, critical limb ischemia; ISR, in-stent restenosis; ABI, ankle brachial index; TBI, toe brachial index.

NIH-PA Author Manuscript

NIH-PA Author Manuscript

NIH-PA Author Manuscript

TABLE II

Angiographic Characteristics

Variable	Type I ISR (*n* = 28)	Type II ISR (*n* = 22)	Type III ISR (*n* = 25)	*P* value
Total lesion length, mm	26 ± 12	135 ± 76	178 ± 101	<0.001
Reference vessel diameter, mm	5.3 ± 0.7	5.2 ± 0.5	5.3 ± 0.8	0.7
TASC II C/D	4 (17)	6 (32)	16 (73)	<0.001
Stent Fracture	3 (11)	6 (27)	4 (16)	0.3
Below-Knee Runoff	2.1 ± 0.8	1.9 ± 0.9	1.9 ± 1.0	0.5
Stent Fracture Grade				0.02
1–2	3	6	0	
3–4	0	0	4	
ISR Location				0.01
SFA	24 (86)	15 (68)	10 (40)	
Popliteal	1 (4)	1 (5)	3 (12)	
Both	3 (11)	6 (27)	12 (48)	

TASC, Trans-Atlantic Inter-Society Consensus; SFA, superficial femoral artery.

NIH-PA Author Manuscript

NIH-PA Author Manuscript

NIH-PA Author Manuscript

TABLE III

Procedural Outcomes

Variable	Type I ISR (*n* = 28)	Type II ISR (*n* = 22)	Type III ISR (*n* = 25)	*P* value
Procedural Success	28 (100)	22 (100)	24 (96)	0.6
Embolization	0 (0)	1 (5)	1 (4)	0.5
Dissection	1 (4)	0 (0)	0 (0)	1.0
Post-Procedure ABI	0.92 ± 0.23	0.99 ± 0.09	0.87 ± 0.27	0.3
Post-Procedure TBI	0.46 ± 0.23	0.55 ± 0.18	0.39 ± 0.11	0.2
Clinical Improvement at 30 days	100%	100%	96%	0.9
Major Amputation, 2 years	0	0	0	N/A
Death, 2 years	4%	0%	23%	0.1
Restenosis, 2 years	39%	67%	72%	0.04
Reocclusion, 2 years	8%	11%	52%	0.009
TVR, 2 years	39%	28%	32%	0.7