

Published in final edited form as:

*Retina*. 2013 January ; 33(1): 160–165. doi:10.1097/IAE.0b013e3182618c22.

## EXERCISE-INDUCED ACUTE CHANGES IN SYSTOLIC BLOOD PRESSURE DO NOT ALTER CHOROIDAL THICKNESS AS MEASURED BY A PORTABLE SPECTRAL-DOMAIN OPTICAL COHERENCE TOMOGRAPHY DEVICE

AHMAD A. ALWASSIA, MD\*, MEHREEN ADHI, MBBS\*, JASON Y. ZHANG, MD\*, CAIO V. REGATIERI, MD, PhD<sup>†,‡</sup>, ADEEB AL-QUTHAMI, MD<sup>‡</sup>, DEEB SALEM, MD<sup>‡</sup>, JAMES G. FUJIMOTO, PhD<sup>§</sup>, and JAY S. DUKER, MD\*

\*Department of Ophthalmology, New England Eye Center, Tufts Medical Center, Boston, Massachusetts

<sup>†</sup>Department of Ophthalmology, Federal University of São Paulo, São Paulo, Brazil

<sup>‡</sup>Division of Cardiology, Tufts Medical Center, Boston, Massachusetts

<sup>§</sup>Department of Electrical Engineering and Computer Science, Research Laboratory of Electronics, Massachusetts Institute of Technology, Cambridge, Massachusetts

### Abstract

**Purpose**—To measure choroidal thickness in patients manifesting an acute change in systemic arterial blood pressure using a portable spectral-domain optical coherence tomography device (iVue).

**Methods**—Fifteen patients (15 eyes) undergoing cardiac exercise stress testing were scanned using a portable spectral-domain optical coherence tomography system (iVue). Two scan protocols were used: cross line scan for measuring choroidal thickness and the retina map scan to measure retinal thickness. Each patient was scanned before and within 3 minutes after the stress test. Blood pressure was measured at the same time as the acquisition of the scans. Choroidal thickness was measured from the posterior edge of the retinal pigment epithelium to the choroid–sclera junction at 500- $\mu$ m intervals up to 1,000  $\mu$ m temporal and nasal to the fovea. Retinal thickness was measured by an automated software. All choroidal thickness measurements were performed by two independent observers.

**Results**—Fifteen patients (15 eyes) with a mean age of 60.6 ( $\pm$ 10.4 years) were scanned. There was a significant increase in systolic but not diastolic pressure after stress testing ( $P < 0.05$ ). The mean choroidal thickness measurements showed no significant difference before and after exercise stress testing ( $P > 0.05$ ). In addition, there was no significant difference in retinal thickness before and after stress testing measurements ( $P > 0.05$ ).

**Conclusion**—There was no change in choroidal thickness or retinal thickness, despite an acute change in the systemic systolic blood pressure induced by exercise.

## Keywords

choroid; choroidal thickness; optical coherence tomography (OCT); retinal thickness; stress test; choroidal blood flow; blood pressure

The ability to image the choroid successfully using optical coherence tomography (OCT) has not been possible until recently because of its location and the attenuation of the OCT signal by the retinal pigment epithelium (RPE). Recent studies<sup>1-5</sup> report successful examination and measurement of choroidal thickness in healthy and disease states using the Heidelberg Spectralis (Heidelberg Engineering, Heidelberg, Germany), RTVue (Optovue, Inc, Fremont, CA), and Cirrus HD-OCT (Carl Zeiss Meditec, Inc, Dublin, CA) spectral-domain (SD) OCT instruments.

The choroid serves many functions. It is responsible for supplying oxygen and nutrients to the RPE and the retina up to the inner nuclear layer. It is also believed to play a role in temperature regulation and waste product removal.<sup>6</sup> Thus, a structurally and functionally normal choroidal vasculature is essential for the function of the retina. Abnormal choroidal blood volume or compromised flow or both can result in photoreceptor dysfunction and death.<sup>7</sup> The choroid circulation displays one of the highest rates of blood flow in the body.<sup>8</sup> In fact, per tissue gram, the choroid has four times more blood flowing through it than does the cortex of the kidney.<sup>9</sup> Most of the blood in the eye is found in the choriocapillaris.<sup>8</sup> In a vascular disease such as diabetes, the choroid shows evidence of degeneration, as suggested by previous studies.<sup>7</sup> The choriocapillaris layer is highly innervated by both sympathetic and parasympathetic nerves.<sup>10</sup> These nerves are thought to play a role in the regulation of choroidal blood flow.<sup>8</sup> In addition to sympathetic regulation, autoregulation is another mechanism by which blood flow can be controlled.<sup>8</sup> Moreover, there are nonvascular smooth muscles in the choroid that are thought to play a role in altering the thickness of the choroid under the influence of local mediators.<sup>11</sup>

Little is known about the regulation of choroidal thickness and its role in different diseases. There are vasoactive substances both endogenous and exogenous that have been shown to alter the thickness of the choroid.<sup>8</sup> Vance et al<sup>12</sup> demonstrated that sildenafil citrate ingestion produced a significant increase in choroidal thickness, as measured by SD-OCT. Intravenous acetazolamide increases choroidal thickness,<sup>13</sup> while nitric oxide released locally has been shown to play a role in increasing choroidal thickness by relaxing both vascular and nonvascular smooth muscles.<sup>14</sup> There are a number of other vasoactive substances with potential influence on the choroid, and their role in disease states is still to be elucidated.<sup>15</sup>

The choroid thickness can be altered by at least 3 mechanisms: 1) local signaling that either stimulates or inhibits the fluid pumping capacity of the RPE and therefore altering the amount of fluid flux from the retina into the choroid<sup>16</sup>; 2) an increase or decrease in vascular permeability of the choriocapillaris that affects the amount of protein that leaks out of these vessels, which in turn changes the oncotic pressure in the choroid<sup>17</sup>; and 3) dilation or constriction of both the vascular and nonvascular smooth muscles.<sup>18</sup>

Previous studies<sup>19,20</sup> have demonstrated that increases in blood pressure (BP) induced by isometric exercise were not linearly associated with an increase in ocular perfusion indicating a degree of autoregulation. The present study was designed to determine whether acute changes in systemic BP after exercise alter choroidal thickness.

## Methods

### Subjects

This study was performed on 15 eyes of 15 patients scheduled to undergo cardiac exercise stress testing in the cardiovascular stress testing unit. Because the patients are in a department that is distant from the ophthalmology clinic, a portable SD-OCT device was used to measure choroidal thickness in patients where they underwent cardiac stress testing. The patients were scanned using a portable SD-OCT immediately before and within 3 minutes after the stress test. Blood pressure was measured immediately before and within 3 minutes after the stress test at the same time as the OCT scans. A 3-minute period was chosen because the BP was still elevated because of the stress test, and it was not possible to image subjects with OCT during the actual stress test. Patients with concomitant ocular abnormalities, such as diabetic retinopathy, central serous chorioretinopathy, high myopia, vascular occlusions, and those with previous ocular surgery, were excluded. All patients were studied at the Tufts Medical Center in Boston, MA, between July 2011 and September 2011. This study was approved by the Institutional Review Board at the Tufts Medical Center, and it adhered to the tenets of the Declaration of Helsinki.

### Choroidal Thickness Measurements

Patients were scanned using the iVue (Optovue, Fremont, CA) before and within 3 minutes after the stress test to ensure that the scan is acquired while the BP was at its highest value. The scan pattern used for choroidal thickness measurement is the iVue Cross line scan, which is a  $2 \times 6$  mm scan consisting of 2,048 A scans (pixels). The images were taken using the standard protocol, and they were not inverted to bring the choroid in closer proximity to the zero-delay line because image inversion using the iVue software results in a low-resolution pixilated image. The cross line scan uses image averaging to decrease the signal-to-noise ratio without eye tracking. All reviewed scans had an intensity of 6/10 or greater. Using the iVue linear measurement tool, 2 independent observers measured choroidal thickness perpendicularly from the outer edge of the hyperreflective RPE to the inner sclera at the fovea and at intervals of 500- $\mu$ m, temporal and nasal to the fovea, up to 1,000  $\mu$ m.

### Correspondence of Choroidal Thickness Measurements from the iVue to Cirrus

To test the correspondence of choroidal thickness measurements from the iVue device to other instrument, 20 eyes of 20 healthy subjects were scanned using both the portable iVue SD-OCT device and the Cirrus SD-OCT device (Carl Zeiss Meditec). The iVue OCT system has a light source centered at 800 nm wavelength and achieves a resolution of 5  $\mu$ m axial in tissue. The system uses image averaging (20 B scans) to decrease the signal-to-noise ratio. This feature allows for better choroidal visualization. The patients were scanned on both devices consecutively on the same day. All reviewed scans had an intensity of 6/10 or greater. Using the iVue and Cirrus linear measurement tool, 2 independent observers measured choroidal thickness perpendicularly from the outer edge of the hyperreflective RPE to the inner sclera at the fovea and at intervals of 500  $\mu$ m temporal and nasal to the fovea, up to 1,000  $\mu$ m from each machine, and a comparison was made. There was no statistically significant difference between the choroidal thickness measurements obtained from the iVue versus the Cirrus SD-OCT systems ( $P = 0.75$ ).

### Retinal Thickness Measurement

Retinal thickness measurements were obtained from the automated iVue software. The data for the retinal thickness were extrapolated from the retina map scan protocol, which is a  $6 \times 6$  mm map that takes 7 raster scans with 250  $\mu$ m separation. The retina map image displays the retinal thickness in 5 locations in perifoveal area.

## Blood Pressure Measurements

Blood pressure measurements were performed via an automated BP cuff. The resting BP was taken before the stress test, and the post-stress test BP was taken within 3 minutes after the test. The patients were scanned using the OCT device at the same time the BP was being recorded.

## Statistical Analysis

Data are expressed as means  $\pm$  standard error of the mean. Statistical analyses were performed using a paired t test. A 95% confidence interval and a 5% level of significance were adopted; therefore, the results with a  $P$  value  $\leq 0.05$  were considered significant. All statistics were calculated using Graph Pad Prism 5.0 software for Windows (GraphPad Software, Inc., La Jolla, CA).

## Results

Fifteen patients (15 eyes) with a mean age of 60.6 ( $\pm 10.4$  years) with no history of any ocular disease or surgery were scanned. Of the 15 patients, 3 patients had controlled hypertension. One patient had controlled diabetes mellitus (with no evidence of retinopathy). Figures 1 and 2, as well as Tables 1 to 3 outline the results. There was a significant increase in systolic but not diastolic pressure after stress testing ( $P < 0.05$ ), as depicted in Table 1. Choroidal thickness measurements at all locations before and after stress test are shown in Table 2, while retinal thickness measurements are shown in Table 3. There was no significant difference in choroidal thickness at all locations before and after stress test ( $P > 0.05$ ) (Figure 1). The average choroidal thickness before the stress test was  $217.5 \pm 98.77 \mu\text{m}$  (range, 90–426  $\mu\text{m}$ ) compared with  $217.1 \pm 98.26 \mu\text{m}$  (range, 84–395  $\mu\text{m}$ ) after the stress test. The average subfoveal choroidal thickness before the stress test was  $224.3 \pm 110.6 \mu\text{m}$  (range, 81–455  $\mu\text{m}$ ) compared with  $222.5 \pm 103.7 \mu\text{m}$  (range, 81–406  $\mu\text{m}$ ) after the stress test. In addition, there was no significant difference in retinal thickness at all locations before and after the stress test ( $P > 0.05$ ) (Figure 2). There was no statistically significant difference between the choroidal thickness measurements obtained from the iVue versus the Cirrus SD-OCT systems ( $P = 0.75$ ) (Figure 3).

## Discussion

In this investigation, the iVue OCT system was used to acquire blank measurements, images, and measurements. The portable OCT allowed measurements to be made outside the ophthalmology clinic immediately after exercise-induced elevation of the BP. In this study, choroidal thickness was successfully measured in all enrolled patients. This is the first study to report successful choroidal thickness measurements using the iVue OCT and to compare them with another SD-OCT device. Based on the data from 20 eyes of 20 healthy subjects, no statistically significant difference was found between the 2 devices ( $P = 0.75$ ) in the choroidal thickness values (Figure 3).

There are many factors that may affect the choroid. A study by Chakraborty et al<sup>21</sup> showed significant diurnal variation in choroidal thickness over 2 consecutive days. Aging is a factor associated with changes in choroidal thickness, and older patients are reported to have thinner choroids.<sup>22</sup> In addition to physiological causes, there are several diseases where choroidal thickness has been shown to be significantly different from that of normal subjects.<sup>23</sup> For example, the choroid thickness has been found to be thinner in patients with age-related macular degeneration. In patients with central serous chorioretinopathy, it is hypothesized that the choroid is hyperpermeable, and thus there is an increase in choroidal thickness compared with that of healthy subjects.<sup>24</sup> However, diabetic patients with

retinopathy have thinner choroids and show a decrease in the mean subfoveal choroidal blood flow, as measured by laser Doppler flowmetry.<sup>25</sup>

There is a dense network of sympathetic innervations of the choroid that suggest a mechanism of choroidal blood flow regulation.<sup>10,26</sup> Our study is the first to present evidence of the regulation of blood flow in the choroidal circulation in vivo, as measured by thickness measurements using SD-OCT; also, this investigation demonstrated no significant change in the thickness of the choroid and the retina, despite significant change in BP. Thus, these results suggest some type of blood flow regulation. The mechanism of this regulation is probably mediated by the intricate sympathetic innervations or by autoregulation by the choroidal vessels.<sup>8</sup> The sympathetic nerves innervate both the vascular and the nonvascular smooth muscle in the choroid.<sup>11</sup> It is possible that contraction of the nonvascular smooth muscle alone keeps the choroid thickness constant, despite the increase in systemic BP.<sup>8</sup> However, a number of factors are probably involved in keeping the choroidal thickness from changing. The current study does not address the mechanism for regulation.

As a result of the advances in imaging modalities, our understanding of the choroid is increasing and choroidal changes in varying disease states are receiving growing attention. Such advances will play an important role in understanding the pathophysiology of many retinal diseases and may help guide therapeutic options in the future. Furthermore, understanding the factors that help regulate the choroid should also help us understand and manage disease states, that is, how would the loss of autoregulation effect disease states and play a role in ischemia and/or injury?<sup>27</sup>

We believe that our findings that an exercise-induced increase in systolic BP does not alter the thickness of the choroid or retina is one-step in understanding the pathophysiology of the choroid. These findings are also important because they show that acute changes in BP do not change choroidal thickness. It is important to remove acute BP change as a possible confounding factor if choroidal thickness measurements are to be used to assess retinal abnormality in the future.

## Acknowledgments

Supported in part by a Research to Prevent Blindness Unrestricted grant to the New England Eye Center/ Department of Ophthalmology, Tufts University School of Medicine; National Institutes of Health contracts (R01-EY11289-23, R01-EY13178-07, and R01-EY013516-07), Air Force Office of Scientific Research (FA9550-07-1-0101 and FA9550-07-1-0014); and the Massachusetts Lions Eye Research Fund.

J. G. Fujimoto received royalties from intellectual property owned by M.I.T. and licensed to Carl Zeiss Meditech, Inc and has stock options in Optovue, Inc. J. S. Duker received research support from Carl Zeiss Meditech, Inc, Optovue, Inc, and Topcon Medical Systems, Inc.

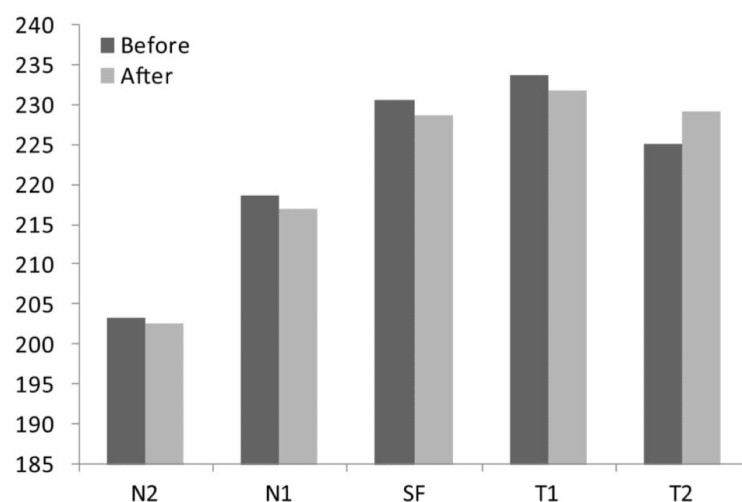
## References

1. Margolis R, Spaide RF. A pilot study of enhanced depth imaging optical coherence tomography of the choroid in normal eyes. *Am J Ophthalmol*. 2009; 147:811–815. [PubMed: 19232559]
2. Fujiwara T, Imamura Y, Margolis R, et al. Enhanced depth imaging optical coherence tomography of the choroid in highly myopic eyes. *Am J Ophthalmol*. 2009; 148:445–450. [PubMed: 19541286]
3. Imamura Y, Fujiwara T, Margolis R, Spaide RF. Enhanced depth imaging optical coherence tomography of the choroid in central serous chorioretinopathy. *Retina*. 2009; 29:1469–1473. [PubMed: 19898183]
4. Spaide RF. Age-related choroidal atrophy. *Am J Ophthalmol*. 2009; 147:801–810. [PubMed: 19232561]

5. Manjunath V, Taha M, Fujimoto JG, Duker JS. Choroidal thickness in normal eyes measured using Cirrus HD optical coherence tomography. *Am J Ophthalmol*. 2010; 150:325–329. e321. [PubMed: 20591395]
6. Parver LM. Temperature modulating action of choroidal blood flow. *Eye (Lond)*. 1991; 5:181–185. [PubMed: 2070878]
7. Cao J, McLeod S, Merges CA, Luty GA. Choriocapillaris degeneration and related pathologic changes in human diabetic eyes. *Arch Ophthalmol*. 1998; 116:589–597. [PubMed: 9596494]
8. Nickla DL, Wallman J. The multifunctional choroid. *Prog Retin Eye Res*. 2010; 29:144–168. [PubMed: 20044062]
9. Alm A, Bill A. Ocular and optic nerve blood flow at normal and increased intraocular pressures in monkeys (*Macaca irus*): a study with radioactively labelled microspheres including flow determinations in brain and some other tissues. *Exp Eye Res*. 1973; 15:15–29. [PubMed: 4630581]
10. Schrod F, De Laet A, Tassignon MJ, et al. Intrinsic choroidal neurons in the human eye: projections, targets, and basic electrophysiological data. *Invest Ophthalmol Vis Sci*. 2003; 44:3705–3712. [PubMed: 12939283]
11. Poukens V, Glasgow BJ, Demer JL. Nonvascular contractile cells in sclera and choroid of humans and monkeys. *Invest Ophthalmol Vis Sci*. 1998; 39:1765–1774. [PubMed: 9727398]
12. Vance SK, Imamura Y, Freund KB. The effects of sildenafil citrate on choroidal thickness as determined by enhanced depth imaging optical coherence tomography. *Retina*. 2011; 31:332–335. [PubMed: 20975620]
13. Dallinger S, Bobr B, Findl O, et al. Effects of acetazolamide on choroidal blood flow. *Stroke*. 1998; 29:997–1001. [PubMed: 9596249]
14. Snyder SH, Brecht DS. Biological roles of nitric oxide. *Sci Am*. 1992; 266:68–71. 74–67. [PubMed: 1373517]
15. Bogner B, Tockner B, Runge C, et al. The effect of vasopressin on choroidal blood flow, intraocular pressure, and orbital venous pressure in rabbits. *Invest Ophthalmol Vis Sci*. 2011; 52:7134–7140. [PubMed: 21791588]
16. Rymer J, Wildsoet CF. The role of the retinal pigment epithelium in eye growth regulation and myopia: a review. *Vis Neurosci*. 2005; 22:251–261. [PubMed: 16079001]
17. Pendrak K, Papastergiou GI, Lin T, et al. Choroidal vascular permeability in visually regulated eye growth. *Exp Eye Res*. 2000; 70:629–637. [PubMed: 10870521]
18. Kee CS, Marzani D, Wallman J. Differences in time course and visual requirements of ocular responses to lenses and diffusers. *Invest Ophthalmol Vis Sci*. 2001; 42:575–583. [PubMed: 11222513]
19. Riva CE, Titze P, Hero M, et al. Choroidal blood flow during isometric exercises. *Invest Ophthalmol Vis Sci*. 1997; 38:2338–2343. [PubMed: 9344357]
20. Kiss B, Dallinger S, Polak K, et al. Ocular hemodynamics during isometric exercise. *Microvasc Res*. 2001; 61:1–13. [PubMed: 11162191]
21. Chakraborty R, Read SA, Collins MJ. Diurnal variations in axial length, choroidal thickness, intraocular pressure, and ocular biometrics. *Invest Ophthalmol Vis Sci*. 2011; 52:5121–5129. [PubMed: 21571673]
22. Ikuno Y, Kawaguchi K, Nouchi T, Yasuno Y. Choroidal thickness in healthy Japanese subjects. *Invest Ophthalmol Vis Sci*. 2010; 51:2173–2176. [PubMed: 19892874]
23. Manjunath V, Goren J, Fujimoto JG, Duker JS. Analysis of choroidal thickness in age-related macular degeneration using spectral-domain optical coherence tomography. *Am J Ophthalmol*. 2011; 152:663–668. [PubMed: 21708378]
24. Kim SW, Oh J, Kwon SS, et al. Comparison of choroidal thickness among patients with healthy eyes, early age-related maculopathy, neovascular age-related macular degeneration, central serous chorioretinopathy, and polypoidal choroidal vasculopathy. *Retina*. 2011; 31:1904–1911. [PubMed: 21878855]
25. Nagaoka T, Kitaya N, Sugawara R, et al. Alteration of choroidal circulation in the foveal region in patients with type 2 diabetes. *Br J Ophthalmol*. 2004; 88:1060–1063. [PubMed: 15258025]

26. Schrod F, Tines R, Brehmer A, Neuhuber WL. Intrinsic choroidal neurons in the duck eye receive sympathetic input: anatomical evidence for adrenergic modulation of nitrgic functions in the choroid. *Cell Tissue Res.* 2001; 304:175–184. [PubMed: 11396712]
27. Reiner A, Del Mar N, Zagvazdin Y, et al. Age-related impairment in choroidal blood flow compensation for arterial blood pressure fluctuation in pigeons. *Invest Ophthalmol Vis Sci.* 2011; 52:7238–7247. [PubMed: 21828151]

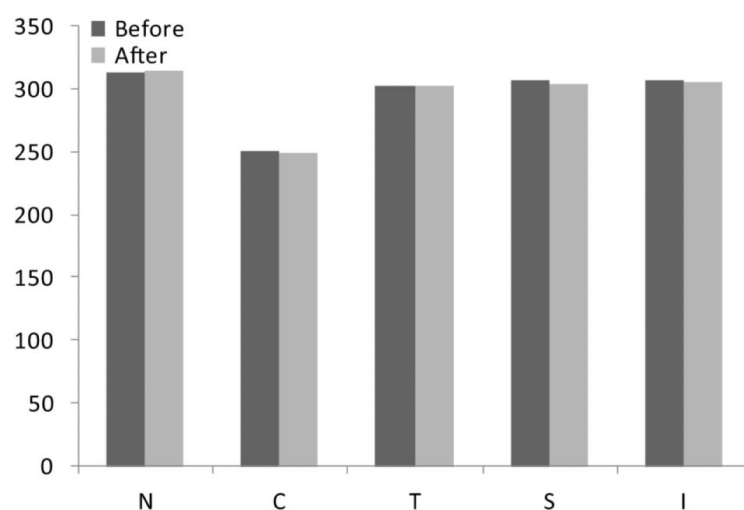




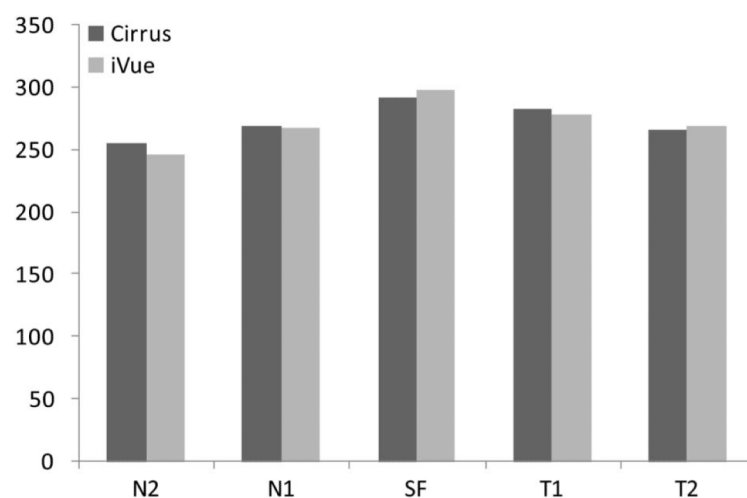
**Fig. 1.**

Graph displaying the choroidal thickness at the different location: N2 (1,000  $\mu\text{m}$  nasally), N1 (500  $\mu\text{m}$  nasally), SF (subfoveal), T1 (500  $\mu\text{m}$  temporal), and T2 (1,000  $\mu\text{m}$  temporal). No significant difference was observed before and after stress testing measurements, despite significant change in systolic blood pressure, as outlined in Table 1.





**Fig. 2.** Graph showing the retinal thickness for the different regions in relation to the fovea: N (nasal), C (center), T (temporal), S (superior), and I (inferior). There is no significant difference in thickness measurements before and after stress testing.



**Fig. 3.**

Graph comparing the choroidal thickness obtained from the Cirrus SD-OCT versus those obtained using the iVue portable SD-OCT system. There was no statistically significant difference in the choroidal thickness measurements obtained by the 2 systems ( $P = 0.75$ ).

**Table 1**

Average Blood Pressure Before and After the Stress Test

Blood Pressure Measurements	Systolic BP, mmHg	Diastolic BP, mmHg
Average BP before stress testing, mean (SD)	120.4 (12.4)	71.8 (6.5)
Average BP after stress testing, mean (SD)	164.4 (21.1)	74.6 (7.2)
<i>P</i>	0.00000006	0.19

There is a significant increase in systolic but not diastolic blood pressure in the before and after stress test recordings.

**Table 2**

Average and Standard Deviation for the Choroid Thickness Measurements at the Different Locations Before and After Stress Testing

Choroidal Thickness Measurement	N2 (1,000 $\mu\text{m}$ Nasal)	N1 (500 $\mu\text{m}$ Nasal)	SF (Subfoveal)	T1 (500 $\mu\text{m}$ Temporal)	T2 (1,000 $\mu\text{m}$ Temporal)
Before, mean $\pm$ SD	213.66 $\pm$ 104.8	228.50 $\pm$ 109.9	239.16 $\pm$ 116.9	239.08 $\pm$ 108.2	229 $\pm$ 94.8
After, mean $\pm$ SD	214.33 $\pm$ 105.7	225.66 $\pm$ 109.2	236.33 $\pm$ 109.3	235.75 $\pm$ 111.5	233.25 $\pm$ 92.5

No significant difference was observed.

**Table 3**

Average and Standard Deviation for the Retinal Thickness Measurements at the Different Locations Before and After Stress Testing

Retinal Thickness Measurement	Nasal, $\mu\text{m}$	Center, $\mu\text{m}$	Temporal, $\mu\text{m}$	Superior, $\mu\text{m}$	Inferior, $\mu\text{m}$
Before, mean $\pm$ SD	312.80 $\pm$ 28.1	248.27 $\pm$ 15.1	299.11 $\pm$ 11.7	305.27 $\pm$ 16.8	305.36 $\pm$ 10.6
After, mean $\pm$ SD	314.45 $\pm$ 29.0	247.72 $\pm$ 17.8	299.70 $\pm$ 13.2	303.45 $\pm$ 19.1	304.63 $\pm$ 14.1

No significant difference was observed.