NIH Public Access
Author Manuscript
Neurocase. Author manuscript; available in PMC 2013 June 19.

Published in final edited form as:
Neurocase. 2013 June ; 19(3): 295–301. doi:10.1080/13554794.2012.667124.

ApoE and TDP-43 neuropathology in two siblings with familial FTLD-motor neuron disease

Keith A. Vossel[1,2], **Nga Bien-Ly**[2,3], **Aubrey Bernardo**[2], **Katya Rascovsky**[1], **Anna Karydas**[1], **Gil D. Rabinovici**[1], **Manu Sidhu**[1], **Eric J. Huang**[4], **Bruce L. Miller**[1], **Yadong Huang**[1,2,4,†], and **William W. Seeley**[1,†]

[1]Department of Neurology, University of California, San Francisco, CA, USA

[2]Gladstone Institute of Neurological Disease, San Francisco, CA, USA

[3]Biomedical Sciences Graduate Program, San Francisco, CA, USA

[4]Department of Pathology, University of California, San Francisco, CA, USA

Abstract

Frontotemporal lobar degeneration with motor neuron disease (FTLD-MND) is characterized by neuronal cytoplasmic inclusions containing TDP-43. Apolipoprotein E4 (apoE4), derived from the apoE ε4 allele, enhances brain atrophy in FTLD through unknown mechanisms. Here, we studied two siblings with *C9ORF72*-linked familial FTLD-MND, an apoE ε4 homozygote and an apoE ε3 homozygote. The apoE ε4 homozygote had more cognitive-behavioral symptoms, fronto-insulo-temporal atrophy, and apoE fragments and aggregates in the anterior cingulate cortex. ApoE formed complexes with TDP-43 that were more abundant in the apoE ε4 homozygote. Although differences seen in a sibling pair could arise due to chance, these findings raise the possibility that apoE4 exacerbates brain pathology in FTLD through formation of neurotoxic apoE fragments and interactions with TDP-43.

Keywords

Apolipoprotein E; TDP-43; Frontotemporal dementia; Motor neuron disease; Neuropathology

Frontotemporal dementia with motor neuron disease (FTD-MND) represents a clinical spectrum due, in the vast majority of patients, to underlying frontotemporal lobar degeneration with transactive response DNA-binding protein 43 (TDP-43) immunoreactive inclusions (FTLD-TDP). Patients may present with impairments in executive skills, language, or, most often, social behavior, or with MND features such as weakness, fasciculations, or spasticity. Often, there is a strong family history of dementia or MND with autosomal-dominant inheritance sometimes linked to chromosome 9 (Hosler et al., 2000). Recently, disease within chromosome 9-linked FTD-MND families was linked to a hexanucleotide expansion in *C9ORF72* (Dejesus-Hernandez et al., 2011; Renton et al., 2011).

© 2012 Psychology Press, an imprint of the Taylor & Francis Group, an Informa business

Address correspondence to Dr. W. W. Seeley, Memory and Aging Center, University of California, 350 Parnassus Ave., Ste 905, San Francisco, CA 94143-1207, USA. (wseeley@memory.ucsf.edu). .
†Yadong Huang and William W. Seeley contributed equally to this work.

Financial Disclosure: None reported.

NIH-PA Author Manuscript
NIH-PA Author Manuscript
NIH-PA Author Manuscript

NIH-PA Author Manuscript

NIH-PA Author Manuscript

NIH-PA Author Manuscript

Apolipoprotein E (apoE), a lipid transport protein, is encoded by a gene with three alleles (ε2, ε3, and ε4), resulting in three apoE isoforms (apoE2, apoE3, and apoE4) (Mahley, 1988). ApoE4, implicated in numerous neurological disorders, enhances brain atrophy within vulnerable regions in behavioral variant frontotemporal dementia (bvFTD) (Agosta et al., 2009). The current study follows these observations with a clinicopathological comparison of two siblings with *C9ORF72*-linked FTLD-MND. One patient carries two apoE ε4 alleles and the other carries two apoE ε3 alleles, providing a unique opportunity to study the influence of apoE genotype on FTLD-MND.

PATIENT COMPARISON

This investigation was approved by the UCSF committee on human research. Both subjects provided written informed consent before participating. To protect patient identities, demographic information has been modified; altered information may or may not include age, gender, and occupation. Disease duration and clinical features have not been modified.

Patient 1

A 54-year-old lawyer began to develop profound behavioral and cognitive symptoms. He exhibited excessive collecting behaviors, a compulsively regimented schedule, fixed motor routines, disinhibition, and sweet cravings. On examination, speech was impulsive and tangential with occasional cursing and word-finding pauses. He had diminished bulk and power in the dominant arm and leg with brisk reflexes and an extensor plantar response. An electromyogram/nerve conduction study (EMG/NCS) showed chronic denervation with reinnervation changes in several muscles of the upper and lower extremities consistent with MND. He later developed delusions, loss of empathy, and repetitive motor behavior. His speech was perseverative, and he showed poor insight. He developed fasciculations in all extremities and a slower, stiffer gait. Motor function slowly declined, and he died at the age of 61.

Patient 2

The sibling of Patient 1, a 57-year-old journalist, had intermittent cramping and muscle twitching in her dominant arm that evolved into loss of strength and dexterity. The following year, she developed diffuse muscle atrophy and quadraparesis with dysarthria and dysphagia. Mild behavioral changes included occasional subvocalizations and mental rigidity. On examination, she was cooperative but exhibited psychomotor acceleration and mild impulsivity with breakdown of personal barriers. Cranial nerve and motor examination revealed diminished bulk throughout with weakness and spasticity and extensor plantar responses bilaterally. An EMG/NCS was consistent with MND. She later developed prominent pseudobulbar symptoms. She died from complications of MND at age 60.

Genetic analysis

The family had a history of FTLD-MND with autosomal-dominant inheritance. Two additional first-degree relatives and two second-degree relatives had suspected or autopsy-confirmed FTLD-MND. ApoE genotyping and genetic testing for progranulin mutations were performed as described (Agosta et al., 2009; Tartaglia et al., 2010). Superoxide dismutase 1 (SOD1) mutations were assessed by polymerase chain reaction-single strand confirmation polymorphism and DNA sequencing (Athena Diagnostics). Genotyping for the presence of an expanded hexanucleotide repeat in a noncoding region of chromosome 9 open reading frame 72 (*C9ORF72*) was performed using repeat primed PCR as described (Dejesus-Hernandez et al., 2011). Patient 1 was homozygous for apoE ε4 and negative for progranulin and SOD1 mutations. Patient 2 was homozygous for apoE ε3. Both patients carried repeat expansions on *C9ORF72*.

NIH-PA Author Manuscript

NIH-PA Author Manuscript

NIH-PA Author Manuscript

Cognition and behavior

Neuropsychological testing (Kramer et al., 2003) and Neuropsychiatric Inventory (NPI) (Cummings et al., 1994) showed impairments in verbal episodic memory and executive dysfunction (Table 1) and higher NPI scores (Table 2) in Patient 1, indicating more severe cognitive-behavioral deficits that implicate frontal-insular-subcortical and medial temporal networks.

Neuroimaging

MRI scans were obtained with a 1.5-Tesla Magnetom Vision system (Siemens) as described (Agosta et al., 2009). Patient 1 had greater frontal, insular, and subcortical atrophy than Patient 2 (Figure 1). Patient 2 had focal precentral gyrus atrophy, consistent with her predominantly motor presentation.

Neuropathology

Neuropathological examination (W. W. S. and E. J. H.) followed standard dementia assessment procedures. Brain tissues were collected at 12.8 (Patient 1) and 6.5 (Patient 2) hours after death.

Histological examination revealed neuronal cytoplasmic inclusions containing TDP-43 in the anterior cingulate cortex (ACC), hippocampal dentate gyrus, substantia nigra, and bulbar motor nuclei, confirming the diagnoses of FTLD-TDP and MND in both patients (Figure 2A–E) (Mackenzie, 2007). ACC TDP-43 pathology took the form of infrequent compact, granular, or skein-like/filamentous neuronal cytoplasmic inclusions, rare glial cytoplasmic inclusions, and sparse neuropil threads. These cortical pathomorphologies were slightly more prominent in Patient 1 but remained too sparse to classify in either patient according to established FTLD-TDP subtypes (Mackenzie et al., 2011). In addition, both patients showed numerous ubiquitin-positive inclusions in dentate gyrus granule cells that outnumbered the TDP-43 inclusions seen within sections of the same region. Modified Bielschowsky silver staining revealed diffuse plaques in hippocampus and sparse neuritic plaques in ACC and neocortical areas in Patient 1. The hippocampal plaques were confirmed to contain amyloid-β by immunostaining with the 3D6 antibody. Immunostaining for tau protein revealed neurofibrillary tangles (NFTs) in the medial temporal lobe corresponding with Braak Stage 1 Alzheimer's disease-related pathology (Braak & Braak, 1991). Patient 2 had no amyloid plaques or NFTs.

To compare brain apoE levels in Patient 1 (ε4 homozygote) and Patient 2 (ε3 homozygote), we analyzed brain lysates from the frozen samples as described (Huang et al., 2001). The supernatant and the solubilized pellets were subjected to SDS–PAGE and analyzed by western blotting. Full-length apoE levels were similar between patients in the ACC and cerebellum. However, apoE fragments and larger complexes in ACC were more abundant in Patient 1 (Figure 2F). Several high-molecular-weight complexes containing apoE were also detected by anti-TDP-43, suggesting that apoE forms complexes with TDP-43. The biochemical interaction between these proteins was confirmed by co-immunoprecipitation (Figure 2G). Complexes containing apoE and TDP-43 were stable in 4% SDS and were found at a molecular weight of ~54 kDa, which is higher than the molecular weight of either protein and suggests the complexes included additional fragments of apoE or TDP-43 or additional molecules.

DISCUSSION

We took advantage of a rare opportunity to explore how apoE genotype influences FTLD severity (Agosta et al., 2009). Patient 1, an apoE ε4 homozygote, had more severe cognitive-

NIH-PA Author Manuscript

NIH-PA Author Manuscript

NIH-PA Author Manuscript

behavioral symptoms, brain atrophy, and neuropathology than Patient 2, his apoE ε3 homozygous sibling. Patient 1 had more abundant apoE fragments and high-molecular-weight apoE-TDP-43 complexes in the ACC, an early-affected region in bvFTD (Seeley et al., 2008). Both siblings carried hexanucleotide expansions on *C9ORF72*, recently described as the most common genetic cause of FTD and amyotrophic lateral sclerosis (ALS) (Dejesus-Hernandez et al., 2011; Renton et al., 2011).

Syndromic heterogeneity is common in *C9ORF72*-linked FTLD-MND, even within the same family. The length of the hexanucleotide repeat expansion in *C9ORF72* is one factor that could influence the disease. However, there is little evidence for anticipation in *C9ORF72*-linked families (Dejesus-Hernandez et al., 2011), suggesting that other factors besides repeat length may influence the disease phenotype or course. Accurate sizing of the repeat length is difficult and we were unable to compare the repeat sizes between these patients.

While differences between these patients could have arisen due to chance or other unstudied factors, our findings raise the possibility that apoE4 exacerbates neuropathology in FTLD-MND by forming neurotoxic fragments (Huang, 2010) and through interactions with TDP-43. Mechanisms of apoE4 pathogenesis in vulnerable neurons include cytoskeletal disruption, mitochondrial dysfunction, impairments in neuronal plasticity (Huang, 2010) and deficits in intracellular trafficking (Chen, Durakoglugil, Xian, & Herz, 2010). Our findings suggest that apoE4 aggravates TDP-43 pathology by forming apoE-TDP-43 complexes which may themselves prove toxic, disrupt normal nuclear localization and RNA processing functions of TDP-43, or impair cell survival through unknown mechanisms whose investigation is warranted by this report.

ApoE4 is also strongly linked to Alzheimer's disease (AD), and co-morbid Alzheimer's pathology might have contributed to Patient 1's cognitive dysfunction. However, diffuse plaques and NFTs in Patient 1 were largely restricted to medial temporal lobes, a common finding in cognitively normal apoE ε4 carriers at this age (Kok et al., 2009). Medial temporal structures were one of several regions where neuroimaging showed greater atrophy in Patient 1 than in Patient 2. Other regions affected in Patient 1, including the ACC and frontoinsular cortex, show little atrophy in AD, especially compared to FTLD (Rabinovici et al., 2007), making it unlikely that AD pathology mediated Patient 1's greater involvement of these regions. Clinical and anatomical heterogeneity is common within FTD-MND families, however, such that the role of apoE genotype requires further exploration in larger samples.

An effect of apoE4 on behavior and brain atrophy has also been reported in FTLD without MND (Agosta et al., 2009; Engelborghs et al., 2006), indicating that apoE4 may have a general influence on neurodegeneration severity within the FTLD spectrum. Interestingly, apoE4 is associated with shortened survival in ALS, a related TDP-43 proteinopathy (Drory, Birnbaum, Korczyn, & Chapman, 2001). Since cognitively impaired ALS patients have shorter survival than cognitively normal ALS patients (Olney et al., 2005), apoE4-related influences on brain pathology could account for this survival effect, a possibility that merits additional study.

Acknowledgments

We thank S. DeArmond for expertise with neuropathological examination, K. Possin for assistance deriving normative data for neuropsychological tests, S. Ordway for editorial review, and J. Carroll for graphics support.

Funding/Support: This work was supported by NIH grants P01 AG022074 (Y.H.), AG023501 (B.L.M. and W.W.S.), the Consortium for Frontotemporal Dementia Research, and the McBean Family Foundation (K.A.V.).

NIH-PA Author Manuscript

NIH-PA Author Manuscript

NIH-PA Author Manuscript

REFERENCES

Agosta F, Vossel KA, Miller BL, Migliaccio R, Bonasera SJ, Filippi M, et al. Apolipoprotein E epsilon4 is associated with disease-specific effects on brain atrophy in Alzheimer's disease and frontotemporal dementia. Proceedings of the National Academy of Sciences of the United States of America. 2009; 106:2018–2022. [PubMed: 19164761]

Braak H, Braak E. Neuropathological stageing of Alzheimer-related changes. Acta Neuropathologica. 1991; 82:239–259. [PubMed: 1759558]

Chen Y, Durakoglugil MS, Xian X, Herz J. ApoE4 reduces glutamate receptor function and synaptic plasticity by selectively impairing ApoE receptor recycling. Proceedings of the National Academy of Sciences of the United States of America. 2010; 107:12011–12016. [PubMed: 20547867]

Cummings JL, Mega M, Gray K, Rosenberg-Thompson S, Carusi DA, Gornbein J. The Neuropsychiatric Inventory: Comprehensive assessment of psychopathology in dementia. Neurology. 1994; 44:2308–2314. [PubMed: 7991117]

Dejesus-Hernandez M, Mackenzie IR, Boeve BF, Boxer AL, Baker M, Rutherford NJ, et al. Expanded GGGGCC hexanucleotide repeat in noncoding region of C9ORF72 causes chromosome 9p-linked FTD and ALS. Neuron. 2011; 72:245–256. [PubMed: 21944778]

Drory VE, Birnbaum M, Korczyn AD, Chapman J. Association of APOE epsilon4 allele with survival in amyotrophic lateral sclerosis. Journal of the Neurological Sciences. 2001; 190:17–20. [PubMed: 11574101]

Engelborghs S, Dermaut B, Marien P, Symons A, Vloeberghs E, Maertens K, et al. Dose dependent effect of APOE epsilon4 on behavioral symptoms in frontal lobe dementia. Neurobiology of Aging. 2006; 27:285–292. [PubMed: 16399213]

Hosler BA, Siddique T, Sapp PC, Sailor W, Huang MC, Hossain A, et al. Linkage of familial amyotrophic lateral sclerosis with frontotemporal dementia to chromosome 9q21–q22. The Journal of the American Medical Association. 2000; 284:1664–1669.

Huang Y. Abeta-independent roles of apolipoprotein E4 in the pathogenesis of Alzheimer's disease. Trends in Molecular Medicine. 2010; 16:287–294. [PubMed: 20537952]

Huang Y, Liu XQ, Wyss-Coray T, Brecht WJ, Sanan DA, Mahley RW. Apolipoprotein E fragments present in Alzheimer's disease brains induce neurofibrillary tangle-like intracellular inclusions in neurons. Proceedings of the National Academy of Sciences of the United States of America. 2001; 98:8838–8843. [PubMed: 11447277]

Kok E, Haikonen S, Luoto T, Huhtala H, Goebeler S, Haapasalo H, et al. Apolipoprotein E-dependent accumulation of Alzheimer disease-related lesions begins in middle age. Annals of Neurology. 2009; 65:650–657. [PubMed: 19557866]

Kramer JH, Jurik J, Sha SJ, Rankin KP, Rosen HJ, Johnson JK, et al. Distinctive neuropsychological patterns in frontotemporal dementia, semantic dementia, and Alzheimer disease. Cognitive and Behavioral Neurology. 2003; 16:211–218. [PubMed: 14665820]

Mackenzie IR. The neuropathology of FTD associated With ALS. Alzheimer Disease and Associated Disorders. 2007; 21:S44–S49. [PubMed: 18090423]

Mackenzie IR, Neumann M, Baborie A, Sampathu DM, Du Plessis D, Jaros E, et al. A harmonized classification system for FTLD-TDP pathology. Acta Neuropathologica. 2011; 122:111–113. [PubMed: 21644037]

Mahley RW. Apolipoprotein E: Cholesterol transport protein with expanding role in cell biology. Science. 1988; 240:622–630. [PubMed: 3283935]

Olney RK, Murphy J, Forshew D, Garwood E, Miller BL, Langmore S, et al. The effects of executive and behavioral dysfunction on the course of ALS. Neurology. 2005; 65:1774–1777. [PubMed: 16344521]

Rabinovici GD, Seeley WW, Kim EJ, Gorno-Tempini ML, Rascovsky K, Pagliaro TA, et al. Distinct MRI atrophy patterns in autopsyproven Alzheimer's disease and frontotemporal lobar degeneration. American Journal of Alzheimer's Disease and Other Dementias. 2007; 22:474–488.

Renton AE, Majounie E, Waite A, Simon-Sanchez J, Rollinson S, Gibbs JR, et al. A hexanucleotide repeat expansion in C9ORF72 is the cause of chromosome 9p21-linked ALS-FTD. Neuron. 2011; 72:257–268. [PubMed: 21944779]

NIH-PA Author Manuscript

NIH-PA Author Manuscript

NIH-PA Author Manuscript

Seeley WW, Crawford R, Rascovsky K, Kramer JH, Weiner M, Miller BL, et al. Frontal paralimbic network atrophy in very mild behavioral variant frontotemporal dementia. Archives of Neurology. 2008; 65:249–255. [PubMed: 18268196]

Tartaglia MC, Sidhu M, Laluz V, Racine C, Rabinovici GD, Creighton K, et al. Sporadic corticobasal syndrome due to FTLD-TDP. Acta Neuropathologica. 2010; 119:365–374. [PubMed: 19876635]

NIH-PA Author Manuscript

NIH-PA Author Manuscript

NIH-PA Author Manuscript

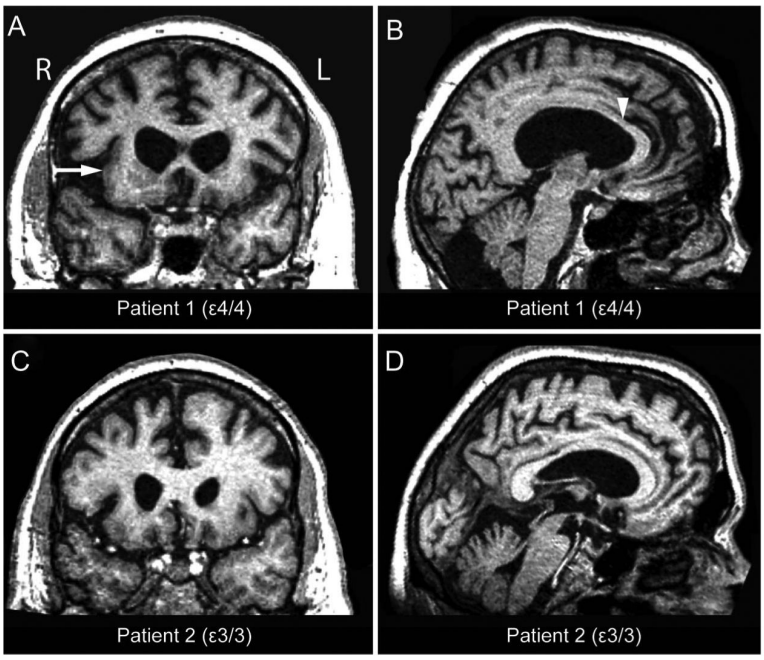

Figure 1.

Structural MRI comparison. MR images of Patient 1 (A, B), an apoE ε4 homozygote, taken 1 year after initial presentation, showed gray matter atrophy in FTLD-vulnerable regions, including the lateral and medial prefrontal cortex, anterior cingulate cortex, and frontoinsulae (A, arrow), as well as thinning of the anterior corpus callosum (B, arrowhead) and *ex vacuo* ventricular enlargement. MR images of Patient 2 (C, D), an apoE ε3 homozygote, taken 2 years after initial presentation, showed less significant atrophy in these regions. R = right, L = left.

NIH-PA Author Manuscript

NIH-PA Author Manuscript

NIH-PA Author Manuscript

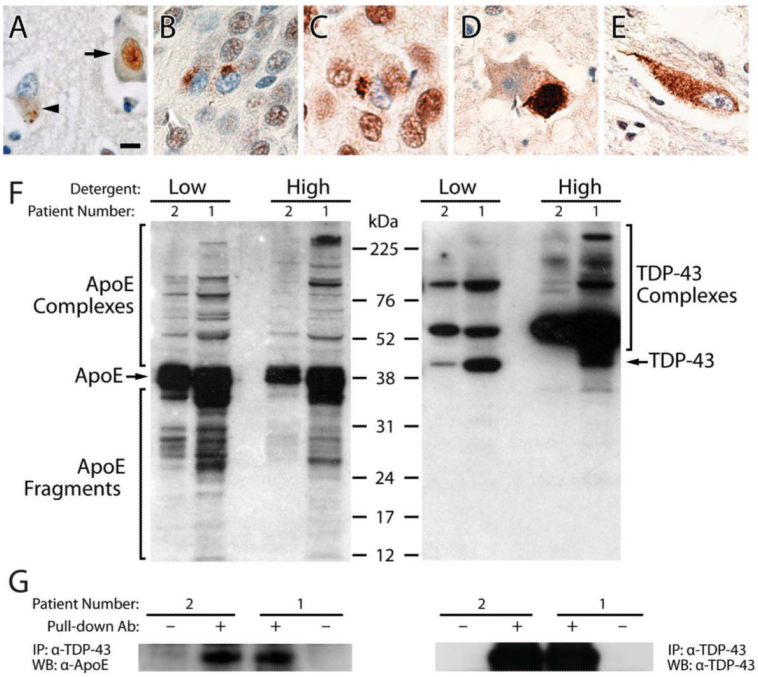

Figure 2.

Histological and biochemical analysis. Immunohistochemistry with an antibody to human transactive response DNA-binding protein 43 (TDP-43) (polyclonal rabbit, Proteintech Group, #10782-2-AP, 1:2000) revealed neuronal cytoplasmic inclusions with absence of nuclear staining (A, arrowhead; arrow indicates adjacent neuron with normal nuclear TDP-43 staining) in the anterior cingulate cortex (ACC) (A, Patient 1), hippocampal dentate gyrus (DG) granule cells (B, Patient 1, C, Patient 2) and in bulbar motor nuclei, including the nucleus ambiguous (D, Patient 1) and spinal accessory nucleus (E, Patient 2). Western blotting of detergent-solubilized pellet fractions of the ACC (10 μg of protein per lane) with anti-human apoE (polyclonal goat, Calbiochem, 1:8000) revealed similar amounts of full-length apoE in both patients; however, Patient 1's ACC contained more apoE fragments and high-molecular-weight complexes (F, left panel). Membranes were stripped and re-probed with anti-human TDP-43 (1:600). Several high-molecular-weight complexes positive for apoE also contained TDP-43; these apoE-TDP-43 complexes were more abundant in Patient 1's ACC (F, right panel). Interactions between apoE and TDP-43 were confirmed by co-immunoprecipitation (G). Protein lysates (50 μg/reaction) from high detergent buffer samples (4% SDS) were incubated with anti-human TDP-43 antibody (2 μl/reaction) and magnetic beads pre-coated with Protein A (Pierce #21348, 50 μl/reaction) at 4°C for 12 hours. The precipitated proteins were analyzed by western blotting with anti-human apoE (1:4000) to demonstrate interactions between the two proteins and with anti-human TDP-43 antibody (1:600) to demonstrate pull-down of TDP-43. SDS-stable apoE-TDP-43 complexes were found at ~54 kDa.

NIH-PA Author Manuscript

NIH-PA Author Manuscript

NIH-PA Author Manuscript

Table1

Neuropsychological testing results for Patient 1 and Patient 2 at initial presentation

	Patient 1 (apoE ε4/4)	Patient 2 (apoE ε3/3)	Age-matched normal values (mean ± SD)
MMSE (0–30)	25	29	29.8 ± 0.4
Memory			
CVLT-SF Learning (max = 36)	22	31	33.0 ± 1.4
CVLT-SF 10 min recall (max = 9)	2	7	7.9 ± 1.5
CVLT-SF delayed recognition (max = 9)	7	9	8.8 ± 0.4
Modified Rey-O 10 min recall (max = 17)	14	10	14.1 ± 2.4
Executive function			
Modified trails-B (correct lines)	86” (14/3E)	17” (14/1E)	26.7 ± 6.1”
D-word fluency (1 min)	8	12	18.0 ± 3.5
Backward digit span	4	4	4.6 ± 1.6
Language			
Semantic fluency (animals/1 min)	22	11	22.3 ± 6.0
Abbreviated BNT (max = 15)	14	14	14.7 ± 0.8
Visuospatial function			
Modified Rey-O copy (max = 17)	17	17	16 ± 1.2

Normal values were derived from age-matched normal controls at the UCSF Memory and Aging Center.

BNT, Boston Naming Test; CVLT-SF, California Verbal Learning Test-Short Form; E, errors; MMSE, Mini-Mental State Exam; Modified Rey-O, modified Rey-Osterrieth complex figure.

NIH-PA Author Manuscript

NIH-PA Author Manuscript

NIH-PA Author Manuscript

Table2

Neuropsychiatry Inventory (NPI) behaviors

	Patient 1 (apoE *e*4/4)			Patient 2 (apoE *e*3/3)		
	Initial	**Year 2**	**Year 3**	**Initial**	**Year 2**	**Year 3**
Delusions	3	2	9	0	0	0
Hallucinations	0	0	9	0	0	0
Agitation	2	0	2	0	1	0
Depression	0	0	0	0	0	0
Anxiety	0	0	0	0	0	0
Elation/euphoria	1	1	1	0	0	0
Apathy	8	2	1	0	0	0
Disinhibition	3	2	0	0	0	0
Irritability	0	0	1	1	0	0
Aberrant motor behavior	6	3	8	3	0	0
Sleep behavior	0	4	0	0	0	0
Eating disorder	2	2	6	0	0	0
NPI total	25	16	37	4	1	0

The score for each behavioral domain is the frequency by severity product score (range 0–12) (Cummings et al., 1994).