CASE REPORT

Limbic encephalitis as the presenting symptom of oesophageal adenocarcinoma: another cancer to search?

Renata Barbosa Menezes,[1] Adson Freitas de Lucena,[2] Fernanda Martins Maia,[2] Antônia Rosivalda Teixeira Marinho[2]

[1]Department of Emergency, Fortaleza's General Hospital, Fortaleza, Ceara, Brazil
[2]Department of Neurology, General Hospital of Fortaleza, Fortaleza, Ceara, Brazil

Correspondence to
Renata Barbosa Menezes, renata_bmenezes@yahoo.com.br

SUMMARY

Limbic encephalitis is a syndrome characterised by irritability, depression, sleeping disturbance, convulsion, hallucination and short-period memory loss that is commonly associated with a malignancy even if there is no evidence of it by the time of presentation. Most reported cases of limbic encephalitis as a paraneoplastic syndrome are associated with small-cell lung cancer and lymphoma. This article is a case report of a patient with limbic encephalitis associated with an oesophageal adenocarcinoma. The patient is a middle-aged man who presented apathy and unstable mood. After months, developed diplopia, reduced visual acuity and involuntary movements. Later, gait disability, disorientation, memory loss and aggressive behaviour were detected, associated with seizures. After investigation, limbic encephalitis was diagnosed and, as the patient developed dysphagia, oesophageal adenocarcinoma was detected. Oesophageal carcinoma usually does not have neurological symptoms associated.

BACKGROUND

This is the first report of limbic encephalitis as the initial symptom of oesophageal carcinoma with neuroimaging documentation of progressive disease affecting the central nervous system (CNS) and diagnosis with the patient still alive.

CASE PRESENTATION

A middle-aged male patient, literate, presented apathy, anorexia and adynamia, resulting in impairment in his daily work in May 2009. Associated to these symptoms, he also had early satiety after feed and halitosis. A few months later, his family noted mood lability and tearfulness.

Three months later, the patient reported diplopia, decreased visual acuity, shivers on his legs that lasted up to 5 min and involuntary movements on arms that stopped while sleeping. On the fourth month of the disease progression, he developed gait instability. He had also one episode of disorientation, during which he could not recognise his wife and exhibited intermittent aggressive behaviour. Two weeks later, he presented an epileptic seizure. By this time, he was started on carbamazepine 1 mg once daily and fluoxetine 20 mg once daily.

Concurrently, his gastric symptoms had increased and he started to present dysphagia. He was admitted in the regional hospital and was diagnosed with a vegetative lesion after a contrasted oesophagography. He was then transferred to a tertiary hospital, where it was confirmed by biopsy that he had an oesophageal adenocarcinoma. By the end of the year, he was submitted to a tumour's resection and was discharged.

A few months later, the patient's neurological deterioration progressed, with a decrease of visual acuity and dysarthria. The involuntary movements worsened. He was admitted to the neurology department of Fortaleza's General Hospital. Physical examination revealed disorientation, slowness of thought, bilateral abducens paresis, vertical eye paresis, tetraparesis (proximal predominance on the upper extremities, slight on), unstable gait with small steps and dysmetria.

INVESTIGATIONS

A CT scan was performed and showed a hypodense lesion on the left mesial temporal lobe. An MRI study showed hyperintense T2 and fluid-attenuated inversion-recovery (FLAIR) lesions on both mesial temporal lobes (figure 1A–C). EEG registered a slow spike-wave epileptiform dysfunction on the right temporal lobe. The cerebrospinal fluid (CSF) did not show relevant abnormalities.

Full blood count, renal and liver functions, inflammatory markers like C reactive protein and plasma viscosity, serum protein electrophoresis, angiotensin-converting enzyme, serum B_{12} and folate with normal results.

DIFFERENTIAL DIAGNOSIS

Serology for herpes simplex virus, hepatitis B and C, syphilis, toxoplasma, varicella zoster, HIV, Epstein-Barr virus, cytomegalovirus were negative; antinuclear antibody, double-stranded DNA, anticardiolipin antibody, antineutrophil cytoplasmic antibody, rheumatoid factor, antithyroid peroxidase antibody, carcinoembryonic antigen, anti-Hu were also requested and were found to be negative.

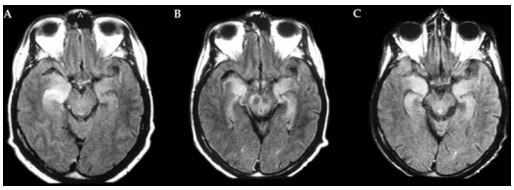

Figure 1 MRI T2-weighted: high signal of mesial temporal lobes: (A) in 2009, (B) in 2010 and (C) in 2011.

To cite: Menezes RB, de Lucena AF, Maia FM, *et al*. *BMJ Case Rep* Published online: [*please include* Day Month Year] doi:10.1136/bcr-2012-008201

TREATMENT

An immunoglobulin therapy was initiated for 5 days. The patient had some improvement, but after 13 days the frequency and duration of his muscular contractions worsened. He received an additional 1 g methylprednisolone pulse therapy during 5 days. The involuntary contractions decreased and he was discharged home.

OUTCOME AND FOLLOW-UP

A year and a half later, he was admitted again because of a gall bladder infection. His physical examination revealed an important weight loss, inability to walk, a difficult speech and inferior limbs areflexia. His minimental status examination was 17/30. The MRI showed diffuse cortical atrophy and the temporal lesions were maintained. He had a progressive disability to eat, and a jejunostomy was performed. The patient developed surgical complications, then a bowel obstruction and aspiration pneumonia and died 38 days later.

DISCUSSION

Classic paraneoplastic limbic encephalitis (PLE) is characterised by irritability, depression, sleeping disorders, seizure, hallucination and short-term memory loss. Most of the patients evolve with confusion and epileptic temporal lobe seizures.[1] Although limbic encephalitis has a typical symptomatology, there are many other atypical manifestations that can precede the malignancy in several years, making it difficult to diagnose in these situations.[2 3] Also, the symptoms can be confounded with many other illnesses which delay the diagnosis.[4]

There is a higher predominance in women, especially after the sixth decade. It is mostly associated with small-cell lung cancer and lymphoma. In men it is also described to be related to testis malignancies.[1–4]

The most accepted pathophysiological mechanism is the expression, by the tumour, of antigens that normally can be found only in the CNS. If the antibodies and T cells directed to these antigens break the blood–brain barrier and have contact with neurons that have oncogenes, this disease will be expressed.[1–6] Studies showed that many patients had antibodies against neuronal antigens, however 40–50% of the patients did not have known paraneoplastic antibodies.[7]

Limbic encephalitis with positive antibodies can be categorised in two groups depending on the antigens. The first group is related to intracellular antigens (anti-Hu, anti-Ma2, CV2/CRMP5 and amphiphysin) and the second to neural cell membrane antigens (VGKC and NMDA receptors).[1 4] The last ones can be found in high concentrations at hippocampi and cerebellum and have a typical distribution.[8]

In this patient, the search for anti-Hu was negative and the other antibodies associated with the disease could not be tested. The MRI, however, showed the classical signs related to limbic encephalitis and the search for other causes that could explain the symptoms were negative.

Nowadays the diagnosis does not depend of pathological confirmation of limbic system inflammation. Most of the authors rely on clinical, imaging (MRI) and electrical (EEG) evidence and also on CSF inflammatory pattern.[9] In 2004, Graus *et al*[10] suggested a set of criteria in an attempt to facilitate the identification of a paraneoplastic neurological syndrome (PNS) that can also help identify limbic encephalitis.

Imaging studies showed the mesial temporal lobe was typically affected as well as mesial cortical structures (cingulate gyrus, frontal cortex and mammillary bodies).[2] It can evolve to a myeloencephalitis with basal ganglia involvement, especially in patients with anti-Hu positive.[1] Around 70–80% of patients with a typical limbic encephalitis syndrome, with or without CSF abnormalities, have a high sign on mesial temporal lobes on T2 or FLAIR MRI sequences.[9]

CSF usually presents normal glucose levels, high protein level with prevalence of mononuclear inflammatory cells.[11] A negative CSF cytology for malignant cells and a lack of meningeal enhancement on MRI helps exclude leptomeningeal deposits, but pleocytosis and oligoclonal bands support an immune-mediated disorder such as PLE.[2] EEG can bring a focal or generalised slow and/or epileptiform pattern on temporal lobes.[1–9]

The treatment is often frustrating, but still, corticotherapy, high doses of immunoglobulin, irradiation and plasmapheresis can cause a temporary remission.[2] Immunosuppressive intervention with cyclophosphamide and corticosteroids are directed to mechanisms of mimicry and consequent autoimmune response and the neural inflammation.[4]

Some studies suggest that paraneoplastic syndromes associated with a cytotoxic T-cell mediation have a restricted answer to treatment. However, syndromes associated to membrane antigens have less inflammatory component and respond better to treatment with immunotherapy.[1 11] Another way of treating these patients is the removal of the underlying tumour, which can improve or stabilise the deficits for long periods.[12] In most cases, treatment is limited and non-specific, mostly directed to symptoms control.[4]

Oesophageal cancer is unusually related to paraneoplastic syndromes in the CNS and this case is the third described in literature over a period of 29 years. The first and second cases, described, respectively, in 1983[13] and 1986[14] are worth mentioning. Van Sweden reported a case of a relatively young man, who presented first prominent motor symptoms years before the psychiatric presentation, with a well-established diagnosis made only during post-mortem. Gritzman reported a case where no psychiatric symptoms were present but limbic encephalitis was detected upon autopsy. With the advances achieved through neuroimaging studies, inflammatory changes can be detected in early stages, right after the appearance of psychiatric symptoms, as the case presented, allowing a faster intervention and the possibility of treatment, with reduction of symptoms and improvement of quality of live. A large review on PLE (3) describing this syndrome included only the two aforementioned cases, showing how rare this clinical picture occurs in oesophageal cancer.

Learning points

- Paraneoplastic syndromes congregate a set of signs and symptoms that express damage to organs and tissues far from the primary site of a malignancy or its metastasis.
- Limbic encephalitis is a syndrome that is commonly associated with a malignancy even if there is no evidence of it at the time of presentation.
- Limbic encephalitis secondary to a malignancy is a relativity frequent paraneoplastic syndrome with clinical subtypes which have a variable response to treatment.
- Oesophageal carcinoma usually does not have associated neurological symptoms.
- Paraneoplastic limbic encephalitis associated with motor symptoms should raise the suspicion of oesophageal cancer as the cause of a paraneoplastic syndrome.

There are also reports relating oesophageal cancer to pure motor polyneuropathy,[15] brain metastasis,[16] leptomeningeal carcinomatosis.[17] Revising these three very well-documented cases, we believe that PLE associated with motor symptoms (pyramidal, motor neuron and movement disorders) might raise the suspicion of oesophageal carcinoma as a possible cause of a paraneoplastic syndrome.

Contributors RBM collected data and images from medical records, searched the articles for literature review and wrote the manuscript along with AFdL. ARTM and FMM conducted the data collected and reviewed the manuscript.

Competing interests None.

Patient consent Obtained.

Provenance and peer review Not commissioned; externally peer reviewed.

REFERENCES

1 Tuzun E, Dalmau J. Limbic encephalitis and variants: classification, diagnosis and treatment. *Neurologist* 2007;13:261–71.
2 Pearce JM. Paraneoplastic limbic encephalitis. *Eur Neurol* 2005;53:106–8.
3 Gultekin SH, Rosenfeld MR, Voltz R, *et al*. Paraneoplastic limbic encephalitis: neurological symptoms, immunological findings and tumour association in 50 patients. *Brain* 2000;123(Pt 7):1481–94.
4 Foster AR, Caplan JP. Paraneoplastic limbic encephalitis. *Psychosomatics* 2009;50:108–13.
5 Dalmau J, Bataller L. Clinical and immunological diversity of limbic encephalitis: a model for paraneoplastic neurologic disorders. *Hematol Oncol Clin North Am* 2006;20:1319–35.
6 Okamoto S, Hirano T, Takahashi Y, *et al*. Paraneoplastic limbic encephalitis caused by ovarian teratoma with autoantibodies to glutamate receptor. *Intern Med* 2007;46:1019–22.
7 Bataller L, Kleopa KA, Wu GV, *et al*. Autoimmune limbic encephalitis in 39 patients: immunophenotypes and outcomes. *J Neurol Neurosurg Psychiatry* 2007;78:381–5.
8 Samarasekera SR, Vincent A, Welch JL, *et al*. Course and outcome of acute limbic encephalitis with negative voltage-gated potassium channel antibodies. *J Neurol Neurosurg Psychiatry* 2007;78:391–4.
9 Lawn ND, Westmoreland BF, Kiely MJ, *et al*. Clinical, magnetic resonance imaging, and electroencephalographic findings in paraneoplastic limbic encephalitis. *Mayo Clin Proc* 2003;78:1363–8.
10 Graus F, Delattre JY, Antoine JC, *et al*. Recommended diagnostic criteria for paraneoplastic neurological syndromes. *J Neurol Neurosurg Psychiatry* 2004;75:1135–40.
11 Newman NJ, Bell IR, McKee AC. Paraneoplastic limbic encephalitis: neuropsychiatric presentation. *Biol Psychiatry* 1990;27:529–42.
12 Rosenfeld M, Dalmau JO. Paraneoplastic disorders of the CNS and autoimmune synaptic encephalitis. *Continuum Lifelong Learn Neurol* 2012;18:366–83.
13 Gritzman MCD, Fritz VU, Perkins S, *et al*. Motor neuron disease associated with carcinoma. *S Afr Med J* 1983;63:288–91.
14 Van Sweden B, Van Peteghem P. Psychopathology in paraneoplastic encephalopathy: an electroclinical observation. *J Clin Psychiatry* 1986;47:267–8.
15 Mostoufizadeh S, Maryam S, Seze J. A case of paraneoplastic demyelinating motor polyneuropathy. *Case Rep Neurol* 2012;4:71–6.
16 Kanemoto A, Hashimoto T, Harada H, *et al*. Occurrence and clinical features of brain metastasis after chemotherapy of esophageal carcinoma. *J Radiat Res* 2012;52:509–15.
17 Abdo AA, Coderre S, Bridges RJ. Leptomeningeal carcinomatosis secondary to gastroesophageal adenocarcinoma: a case report and review of the literature. *Can J Gastroenterol* 2002;16:807–11;quiz 831–2.

Copyright 2013 BMJ Publishing Group. All rights reserved. For permission to reuse any of this content visit http://group.bmj.com/group/rights-licensing/permissions.
BMJ Case Report Fellows may re-use this article for personal use and teaching without any further permission.

Become a Fellow of BMJ Case Reports today and you can:
- Submit as many cases as you like
- Enjoy fast sympathetic peer review and rapid publication of accepted articles
- Access all the published articles
- Re-use any of the published material for personal use and teaching without further permission

For information on Institutional Fellowships contact consortiasales@bmjgroup.com

Visit casereports.bmj.com for more articles like this and to become a Fellow