Eur Spine J (2013) 22 (Suppl 3):S461–S465
DOI 10.1007/s00586-012-2634-z

CASE REPORT

L5 spinal nerve injury caused by misplacement of outwardly-inserted S1 pedicle screws

Masahiro Inoue · Gen Inoue · Tomoyuki Ozawa · Masayuki Miyagi · Hiroto Kamoda · Tetsuhiro Ishikawa · Miyako Suzuki · Yoshihiro Sakuma · Yasuhiro Oikawa · Kazuyo Yamauchi · Sumihisa Orita · Masashi Takaso · Tomoaki Toyone · Kazuhisa Takahashi · Seiji Ohtori

Received: 26 August 2012 / Revised: 5 December 2012 / Accepted: 16 December 2012 / Published online: 28 December 2012
© Springer-Verlag Berlin Heidelberg 2012

Abstract
Purpose To evaluate L5 nerve root injuries caused by outwardly misplaced S1 pedicle screws.
Summary of Background Data Pedicle screws remain the criterion standard for fixation of L5–S1 to correct lumbosacral instability. When inserting S1 pedicle screws, it is possible to injure the L5 nerve root if screws are inserted outwardly and the tip of the screw perforates the anterior cortex of the sacrum. Despite this risk, to our knowledge this type of injury has never been reported as a case series.
Methods We experienced 2 cases of L5 nerve root injury caused by outwardly-inserted S1 pedicle screws. In both cases, bilateral S1 pedicle screws were inserted outwardly using a free-hand technique, and on one side, screws induced severe pain by impinging on an L5 root. Computed tomography after the selective rootgraphy of the injured nerve showed the nerve compressed laterally by screw threads in Case 1 and crushed between the screw threads and the sacral body in Case 2.
Results In both cases, leg pain disappeared immediately after the infiltration of the nerve with lidocaine, but symptoms recurred within a few days in Case 1 and within an hour in Case 2. Conservative treatment of three spinal nerve infiltrations was effective in Case 1, but reinsertion of the rogue screw was necessary in Case 2.
Conclusions Surgeons should recognize that lateral inclination of S1 pedicle screws can cause L5 nerve root injury, which may require reinsertion of the screw, especially in cases where insertion is difficult because of overlapping surrounding muscle or bony tissue.

Keywords Nerve injury · Pedicle screw · Lumbosacral fixation

M. Inoue · M. Miyagi · H. Kamoda · T. Ishikawa · M. Suzuki · Y. Sakuma · Y. Oikawa · K. Yamauchi · S. Orita · K. Takahashi · S. Ohtori
Department of Orthopaedic Surgery, Graduate School of Medicine, Chiba University, Chiba, Japan

G. Inoue (✉) · M. Takaso
Department of Orthopaedic Surgery, Kitasato University, School of Medicine, 1-15-1, Kitasato, Minami-ku, Sagamihara, Kanagawa 252-0374, Japan
e-mail: ginoue@kitasato-u.ac.jp

T. Ozawa · T. Toyone
Department of Orthopaedic Surgery, Teikyo University Chiba Medical Center, Ichihara, Japan

Introduction

Pedicle screws are widely used in spinal surgery. Numerous articles have reported the effectiveness of pedicle screws [1–6]. However, pedicle screws that perforate the pedicle cortex may increase the risk of neurovascular complications [7–9]. In a systematic review, the accuracy with which pedicle screws were inserted using a free-hand technique was reported as from 69 to 100 %, which is lower than the accuracy obtained with fluoroscopic assistance or Computed tomography (CT) navigation [10, 11].

Pedicle screws are still generally used to fuse L5–S1 in lumbosacral fixation for correction of lumbosacral instability [12–14]. Various methods for the insertion of sacral pedicle screws have been reported. Bicortical or tricortical methods that penetrate the anterior sacral cortex or cranial S1 endplate are evidently more stable than monocortical methods that penetrate the posterior cortex alone. However, these methods carry a risk of nerve or vascular injury in front of the sacrum when sacral pedicle screws are inserted inwardly [15–24]. Conversely, on the anterolateral

side of the S1 sacral bone, L5 nerve roots are arranged from the center cranially to laterally and can be injured if an S1 pedicle screw is inserted outwardly and perforates the anterior cortex. Despite this risk of injury, to our knowledge there has been no previously published report of any L5 nerve root injury caused by an outwardly-inserted S1 pedicle screw perforating the anterior cortex of sacrum. Two cases in which the L5 spinal nerve was injured after insertion of S1 pedicle screws are currently reported, for which reinsertion was required in one case but not in the other.

Case 1

A 68-year-old man was diagnosed with spondylolisthesis and referred to our university hospital after a 4-month history of lower back pain and left unilateral L5 nerve impairment. His symptoms were severe, and L5 nerve root infiltration was ineffective and temporary. Preoperative radiographic evaluation indicated L4–5 canal stenosis and L5–S1 foraminal stenosis, and thus, L4–L5 posterolateral fusion and L5–S1 transforaminal lumbar interbody fusion (TLIF) were performed using a left total facetectomy with pedicle screws. All pedicle screws were inserted using a free-hand technique. Postoperative anteroposterior X-ray imaging showed bilateral S1 screws that were inserted outwardly. After surgery, preoperative symptoms had disappeared, but contralateral numbness and pain in the L5 area appeared on the day of surgery. An L5 nerve rootgraphy was performed using 1.0 ml of the contrast medium iotorolan (Schering). Both rootgraphy and the following computed tomography (CT) revealed that the right S1 pedicle screw passed diagonally against the pedicle medullary canal toward the far lateral side at an outward angle of 15° and penetrated 9.0 mm distant from the anterior cortex of the sacrum. The L5 nerve root was compressed laterally by the perforating S1 screw (Figs. 1, 2a, b). Radicular pain disappeared immediately after infiltration of the L5 spinal nerve with lidocaine (1.5 ml of 1 % solution), but the effectiveness of this treatment was temporary and radicular pain gradually recurred within a few days. Symptoms were transiently improved in a conservative manner by three-time L5 spinal nerve infiltrations and daily oral medication with 180 mg of Loxoprofen. Symptoms remitted within 2 months and had not relapsed at the final follow-up, 1 year after surgery.

Case 2

A 62-year-old man was diagnosed with spondylolytic spondylolisthesis and referred to our university hospital after a 4-month history of lower back pain and left unilateral L5 nerve impairment. His symptoms had gradually increased. Preoperative images indicated a left L5–S1 foraminal stenosis, and L5–S1 TLIF was performed using a left total facetectomy with free hand-inserted pedicle screws. Immediately after surgery, contralateral lower leg pain and motor weakness appeared. Postoperative plain X-ray images showed bilateral L5 pedicle screws inserted outwardly. A right L5 selective rootgraphy using 1.0 ml of iotorolan indicated that the nerve root was pushed inwardly by a misplaced S1 screw (Fig. 3), and CT after the right L5 rootgraphy indicated bilateral screws were not inserted through the pedicle and abutted the outer cortex of the vertebral body (Fig. 4a). The right S1 screw was inserted 17° outwardly and penetrated 8.6 mm distant from the anterior cortex of the sacrum. The right L5 nerve root was encroached upon by the pedicle screw and the lateral side of the S1 endplate, without any remaining free space, effectively crushing the nerve between the screw threads and the sacral body. Postoperative symptoms disappeared temporarily after infiltrating the L5 nerve root with lidocaine (1.5 ml of 1 % solution), but completely recurred within an hour. The L5 radicular pain was uncontrollable, even with continuous oral or intravenous injection of opioids. We, therefore, reinserted the misplaced S1 pedicle screw 1 month after initial surgery. Symptoms improved immediately after reinsertion, and there was no relapse during a two-year follow-up (Fig. 4b).

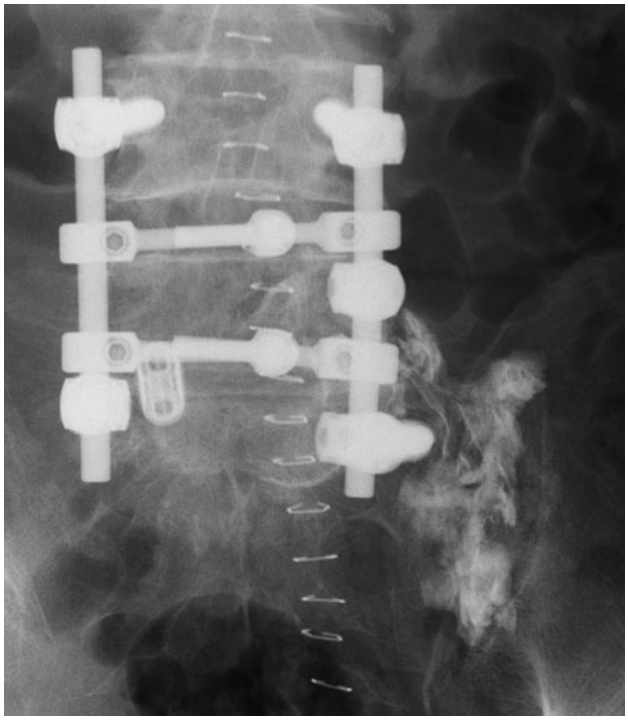

Fig. 1 Right L5 selective rootgraphy. The outwardly-inserted pedicle screw laterally compresses the L5 nerve root

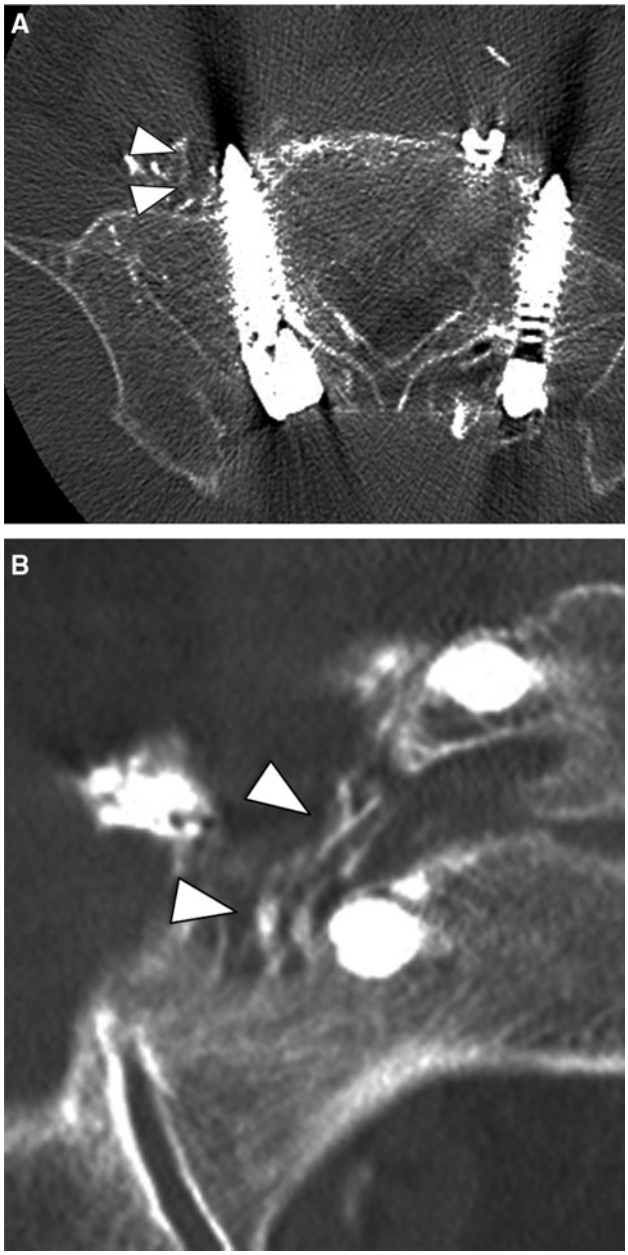

Fig. 2 Computed tomography (CT) after the right L5 rootgraphy. **a** In the axial section, the right L5 nerve root is compressed laterally by the perforating S1 screw (*white arrow heads*). The right s1 pedicle screw passes diagonally against the pedicle medullary canal toward the far lateral side, at an outward angle of 15° and penetrates 9.0 mm distant from the anterior cortex of the sacrum. **b** In the coronal section, the L5 nerve root is compressed laterally by the perforating S1 screw (*white arrow heads*)

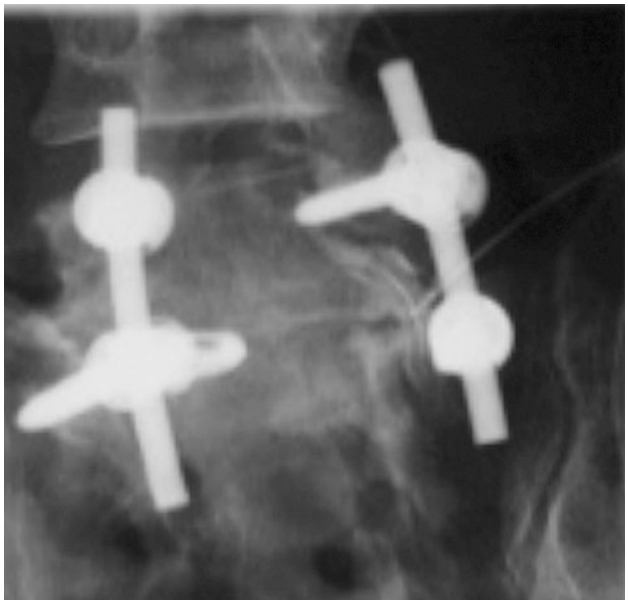

Fig. 3 Right L5 selective rootgraphy using 1.0 ml of iotorolan shows that the nerve root is pushed inward by a misplaced S1 screw

Discussion

Pedicle screw fixation remains the standard method for correction of L5–S1 lumbosacral instability [12–14]. Bicortical or tricortical methods that penetrate the anterior sacral cortex or cranial S1 endplate are reported to provide stronger stability than monocortical methods that only penetrate the posterior cortex [15–18]. It is generally agreed that medially oriented placement of S1 pedicle screws provides greater stability than either centrally or laterally oriented positions because the mean bone mineral density in the central region of the sacrum is approximately 30 to 60 % higher than that in the alar region [25, 26]. By contrast, several authors have recommended that placement of S1 pedicle screws in a central position should be avoided because of the risk this placement carries of damage to the iliac vessels, the sympathetic chain, and the lumbosacral trunk, which are all close to the sacrum [19–24]. Therefore, from both biomechanical and anatomical points of view, it is recommended that S1 pedicle screws should be inserted inwardly with an acceptable angle reported as about 30° to 40°, almost the same as that of the S1 facet angle [27–31]. However, in general, S1 pedicle screws are inserted from a medial entry point with an outward angle, because of the prominent dorsal overhang of the posterior iliac crest and paravertebral muscle mass [30, 32–35]. If screws are inserted outwardly, they risk causing an L5 spinal nerve injury, and thus, great care should be taken. The L5 nerve roots are arranged from centrally more cranially to laterally more posteriorly, so damage is anatomically possible. Moreover, Waikakul et al. [36] have reported that almost one-third of the L4 nerve roots join the L5 nerve roots at the level above the most anterior part of the sacroiliac joint, suggesting that an S1 pedicle screw could injure not only L5, but also L4 nerve roots. Nevertheless, apparently no previously published article has reported L5 or conjoined L4 and L5 nerve root injury induced by an S1 pedicle screw.

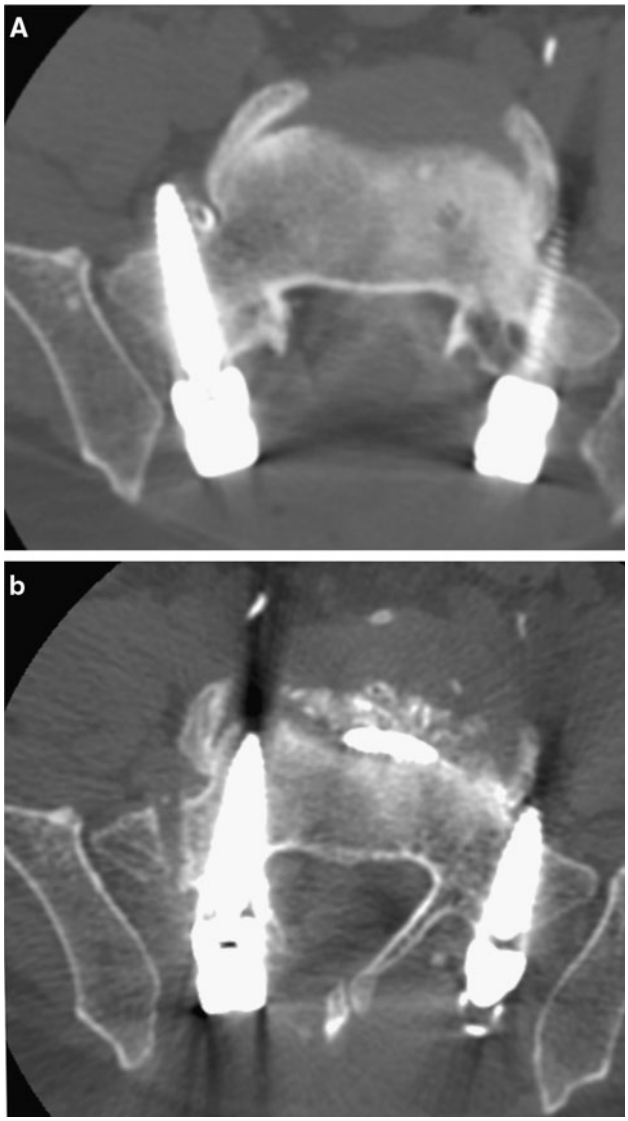

Fig. 4 **a** CT after the right L5 rootgraphy shows that bilateral screws were not inserted through the pedicle and abutted the outer cortex of the vertebral body. The right S1 screw was inserted 17° outwardly and penetrated 8.6 mm distant from the anterior cortex of the sacrum. The right L5 nerve root is crushed between the pedicle screw and the lateral side of the S1 endplate, without any space to move. **b** CT after reinsertion indicates that the right screw was reinserted with 4° medial inclination and anchored in the vertebral body

To diagnose an L5 nerve injury caused by an S1 pedicle screw, selective nerve rootgraphy and infiltration of a minimum volume of lidocaine were effective. Symptoms were improved by conservative therapy in case 1 and neither case relapsed during the follow-up, so we believe that reinsertion is not always necessary. We found a difference in the morphology during L5 rootgraphy. In case 1, the L5 nerve root coursed outside of the S1 pedicle screw and there was space lateral to the screw. By contrast, in case 2 the L5 nerve root coursed inside of the S1 pedicle screw, crushed between the screw threads and the sacral body and was restrained from moving because no space was available. The difference in these findings may be one of the reasons for which the prognosis was different. In the two current cases, preoperative X-ray imaging did not reveal any severe degenerative scoliosis or rotation of vertebra; therefore, no radiological assistance (e.g., fluoroscopy, computed tomography, or navigation) was used. Surgeons should be alerted to the misplacement of S1 pedicle screws to avoid involvement not only anterior to the anteromedial neurovascular tissue, but also anterolateral to the arrangement of the L5 nerve root. If insertion proves difficult because of overlapping of surrounding muscle or bony tissue, confirmation of an accurate screw position with some radiological assistance should be made without hesitation to avoid neurovascular complications.

Conflict of interest None.

References

1. Bridwell KH, Sedgewick TA, O'Brien MF, Lenke LG, Baldus C (1993) The role of fusion and instrumentation in the treatment of degenerative spondylolisthesis with spinal stenosis. J Spinal Disord 6:461–472
2. Mardjetko SM, Connolly PJ, Shott S (1994) Degenerative lumbar spondylolisthesis: a meta-analysis of literature 1970–1993. Spine 19(Suppl):2256–2265
3. Yuan HA, Garfin SR, Dickman CA, Mardjetko SM (1994) A historical cohort study of pedicle screw fixation in thoracic, lumbar, and sacral spinal fusions. Spine 19(Suppl):2279–2296
4. Christensen FB (2004) Lumbar spinal fusion. Outcome in relation to surgical methods, choice of implant and postoperative rehabilitation. Acta Orthop Scand Suppl 75:2–43
5. Ledonio CG, Polly DW Jr, Vitale MG, Wang Q, Richards BS (2011) Pediatric pedicle screws: comparative effectiveness and safety: a systematic literature review from the Scoliosis Research Society and the Pediatric Orthopaedic Society of North America task force. J Bone Joint Surg Am 93:1227–1234
6. Robertson PA, Plank LD (2008) Prospective cohort analysis of disability reduction with lumbar spinal fusion surgery in community practice. J Spinal Disord Tech 21:235–240
7. Lonstein JE, Denis F, Perra JH, Pinto MR, Smith MD, Winter RB (1999) Complications associated with pedicle screws. J Bone Joint Surg Am 81:1519–1528
8. Okuda S, Miyauchi A, Oda T, Haku T, Yamamoto T, Iwasaki M (2006) Surgical complications of posterior lumbar interbody fusion with total facetectomy in 251 patients. J Neurosurg Spine 4:304–309
9. Rivet DJ, Jeck D, Brennan J, Epstein A, Lauryssen C (2004) Clinical outcomes and complications associated with pedicle screw fixation-augmented lumbar interbody fusion. J Neurosurg Spine 1:261–266
10. Kosmopoulos V, Schizas C (2007) Pedicle screw placement accuracy: a meta-analysis. Spine 32:E111–E120
11. Gelalis ID, Paschos NK, Pakos EE, Politis AN, Arnaoutoglou CM, Karageorgos AC, Ploumis A, Xenakis TA (2012) Accuracy of pedicle screw placement: a systematic review of prospective in vivo studies comparing free hand, fluoroscopy guidance and navigation techniques. Eur Spine J 21:247–255

12. Jacobs WC, Vreeling A, De Kleuver M (2006) Fusion for low-grade adult isthmic spondylolisthesis: a systematic review of the literature. Eur Spine J 15:391–402
13. Zhou ZJ, Zhao FD, Fang XQ, Zhao X, Fan SW (2011) Meta-analysis of instrumented posterior interbody fusion versus instrumented posterolateral fusion in the lumbar spine. J Neurosurg Spine 15:295–310
14. Schwab FJ, Nazarian DG, Mahmud F, Michelsen CB (1995) Effects of spinal instrumentation on fusion of the lumbosacral spine. Spine 20:2023–2028
15. McCord DH, Cunningham BW, Shono Y, Myers JJ, McAfee PC (1992) Biomechanical analysis of lumbosacral fixation. Spine 17: S235–S243
16. von Strempel A, Trenkmann S, Krönauer I, Kirsch L, Sukopp C (1998) The stability of bone screws in the os sacrum. Eur Spine J 7:313–320
17. Lehman RA Jr, Kuklo TR, Belmont PJ Jr, Andersen RC, Polly DW Jr (2002) Advantage of pedicle screw fixation directed into the apex of the sacral promontory over bicortical fixation: a biomechanical analysis. Spine 27:806–811
18. Orita S, Ohtori S, Eguchi Y, Kamoda H, Arai G, Ishikawa T, Miyagi M, Inoue G, Ochiai N, Kishida S, Takaso M, Aoki Y, Takahashi K (2010) Radiographic evaluation of monocortical versus tricortical purchase approaches in lumbosacral fixation with sacral pedicle screws: a prospective study of ninety consecutive patients. Spine 35:E1230–E1237
19. Ergur I, Akcali O, Kiray A, Kosay C, Tayefi H (2007) The role of fusion and instrumentation in the treatment of degenerative spondylolisthesis with spinal stenosis. Eur Spine J 16:1519–1523
20. Esses SI, Botsford DJ, Huler RJ, Rauschning W (1991) Surgical anatomy of the sacrum: a guide for rational screw fixation. Spine 16:S283–S288
21. Licht NJ, Rowe DE, Ross LM (1992) Pitfalls of pedicle screw fixation in the sacrum. Spine 17:892–896
22. Mirkovic S, Abitbol JJ, Steinman J, Edwards CC, Schaffler M, Massie J, Garfin SR (1991) Anatomic consideration for sacral screw placement. Spine 16:S289–S294
23. Morse BJ, Ebraheim NA, Jackson WT (1994) Preoperative CT determination of angles for sacral screw placement. Spine 19: 604–607
24. Xu R, Ebraheim NA, Yeasting RA, Wong FY, Jackson WT (1995) Morphometric evaluation of the first sacral vertebra and the projection of its pedicle on the posterior aspect of the sacrum. Spine 20:936–940
25. Smith SA, Abitbol JJ, Carlson GD, Anderson DR, Taggart KW, Garfin SR (1993) The effects of depth of penetration, screw orientation, and bone density on sacral screw fixation. Spine 18: 1006–1010
26. Zheng Y, Lu WW, Zhu Q, Qin L, Zhong S, Leong JC (2000) Variation in bone mineral density of the sacrum in young adults and its significance for sacral fixation. Spine 25:353–357
27. Arman C, Naderi S, Kiray A, Aksu FT, Yilmaz HS, Tetik S, Korman E (2009) The human sacrum and safe approaches for screw placement. J Clin Neurosci 16:1046–1049
28. Okutan O, Kaptanoglu E, Solaroglu I, Beskonakli E, Tekdemir I (2004) Determination of the length of anteromedial screw trajectory by measuring interforaminal distance in the first sacral vertebra. Spine 29:1608–1611
29. Robertson PA, Stewart NR (2000) The radiologic anatomy of the lumbar and lumbosacral pedicles. Spine 25:709–715
30. de Peretti F, Argenson C, Bourgeon A, Omar F, Eude P, Aboulker C (1991) Anatomic and experimental basis for the insertion of a screw at the first sacral vertebra. Surg Radiol Anat 13:133–137
31. Louis R (1986) Fusion of the lumbar and sacral spine by internal fixation with screw plates with screw plates. Clin Orthop Relat Res 203:18–33
32. Robertson PA, Plank LD (1999) Pedicle screw placement at the sacrum: anatomical characterization and limitations at S1. J Spinal Disord 12:227–233
33. Kaptanoglu E, Okutan O, Tekdemir I, Beskonakli E, Deda H (2003) Closed posterior superior iliac spine impeding pediculo-corporeal S-1 screw insertion. J Neurosurg 99(2 Suppl):29–34
34. Asher MA, Strippgen WE (1986) Antrhopometric studies of the human sacrum relating to dorsal transsacral implant. Clin Orthop Relat Res 203:58–62
35. Xu R, Ebraheim NA, Mohamed A, el-Gamal H, Yeasting RA (1995) Anatomic considerations for dorsal sacral plate-screw placement. J Spinal Disord 8:352–356
36. Waikakul S, Chandraphak S, Sangthongsil P (2010) Anatomy of L4 to S3 nerve roots. J Orthop Surg (Hong Kong) 18:352–355