

Alfred Schmitz
Ursula E. Jaeger
Roy Koenig
Joerg Kandyba
Ulrich A. Wagner
Juergen Giesecke
Ottmar Schmitt

A new MRI technique for imaging scoliosis in the sagittal plane

Received: 17 April 2000
Revised: 18 November 2000
Accepted: 18 December 2000
Published online: 16 February 2001
© Springer-Verlag 2001

This study was conducted at the Departments of Orthopaedics and Radiology, University of Bonn, Germany.

A. Schmitz (✉) · O. Schmitt
Department of Orthopaedics,
University of Bonn,
Sigmund-Freud Strasse 25,
53105 Bonn, Germany
Fax: +49-228-2879091

U. E. Jaeger, R. Koenig · J. Kandyba
Department of Radiology,
University of Bonn, Germany

U. A. Wagner
Orthopaedic Hospital,
Langen-Debstedt, Germany

J. Giesecke
Philips Medical Systems,
Best, The Netherlands

Abstract The purpose of the present study was to introduce a new magnetic resonance imaging (MRI) procedure showing the whole spine in a coronal and sagittal plane, and to study the assessment of sagittal Cobb angle measurements using this technique. Prospectively we studied 32 patients (average age 14.8 years) with idiopathic scoliosis (mean thoracic Cobb angle 33° on radiograph) and 18 patients (average age 14.5 years) without scoliosis. The MRI investigation was carried out in a standard supine position. The cervical and upper thoracic spine and the lower thoracic and lumbar spine were measured on a 1.5-T Gyroscan ACS-NT Powertrak 6000 system. An algorithm was developed to combine the results of the cranial and caudal scans into a coronal and a sagittal image of the whole spine (MR total spine imaging). Measurement of the

sagittal Cobb angle conducted ten times by four independent investigators revealed an intraobserver variance of 1.6° and an interobserver variance of 1.8°. In the group with scoliosis the mean sagittal Cobb angle from T4 to T12 was 12° (range -3° to 24°) and in the group without scoliosis 22° (range 16° to 30°), which was a significant difference. MR total spine imaging makes it possible to image scoliosis in the sagittal plane. On these MR projections, idiopathic thoracic scoliosis was identified by a reduced sagittal Cobb angle. MR total spine imaging would allow monitoring of scoliosis in the sagittal plane, which can reveal relevant clinical data without radiation exposure.

Keywords Idiopathic scoliosis · Sagittal plane · MRI · Cobb angle

Introduction

In idiopathic scoliosis, biomechanical, biological and clinical views confirm that the deformity in the sagittal plane is of primary pathogenetic significance [8]. A fixed lordotic section causes rotation and increased lateral curvature of the spine as a result of the asymmetry in the coronal plane [2]. Various studies confirm that lordosis of the thoracic vertebrae is characteristic for idiopathic scoliosis in adolescents [3, 8, 11].

The scoliotic deformity in the follow-up of scoliosis patients is usually examined using anteroposterior (AP) radiographs. An additional lateral radiograph, while pro-

viding additional information, would result in increased X-ray exposure. On the lateral X-ray projection, the mean entrance surface radiation dose for the thoracic spine is 6.1 mGy and for the lumbar spine 6.7 mGy [1]. However, monitoring the scoliotic deformity on a lateral view can provide additional information, useful, for example, for assessing the effect of brace treatment in two planes or determining further prognostic factors.

The technique of MR total spine imaging developed by the authors allows visualization of the whole spine in the coronal and sagittal planes [4, 5]. The present study aimed to establish whether MR total spine imaging is a reliable and useful method to image scoliosis in the sagittal plane.

Materials and methods

In this prospective study, 32 patients with idiopathic scoliosis (20 with a thoracic curve and 12 with an S-shaped curve) and a group of 18 patients without scoliosis were studied. The average age in the group with scoliosis was 14.8 years (range 11–29 years) and in the other group 14.5 years (range 7–27 years). The non-scoliotic group consisted of patients referred to the outpatient orthopaedic department, in which no scoliotic deformity (defined as Cobb angle $<5^\circ$) could be determined on conventional standing AP radiographs. Informed consent was obtained from all patients.

The MR investigation was carried out in a standard supine position with the pelvis horizontal and the head flat. The cervical and upper thoracic vertebrae and the lower thoracic and lumbar vertebrae were measured in two scans. Measurements were carried out using a 1.5-T Gyroscan with an ACS-NT Powertrak 6000 system (Philips Medical Systems, The Netherlands). The coronal and sagittal images were reconstructed from the cranial and caudal scans. Due to scoliotic deformity, normal planar MR images of the spine can not depict all spinal vertebrae and vertebral discs at once. A solution to this problem is the generation of composite coronal and sagittal images from small slices of coronal or sagittal multi-stack images adequately depicting individual disc spaces. To enable the selection of such coronal and sagittal images, a path through the centres of all intervertebral discs is defined using multi-stack coronal and sagittal reconstructions. Composite coronal and sagittal images assembled from those small image slices depicting the disc spaces allow the measurement of scoliosis. The average total acquisition time per patient was 14 min and

postprocessing on a Pentium PC took approximately another 7 min.

The Cobb angles were measured on the MR images at the PC work station. The sagittal Cobb angle was calculated in preliminary measurements in all patients between T4 and T12. In the scoliosis group, a second measurement was taken of the sagittal Cobb angle from the levels of the scoliotic deformity. To assess the reproducibility of the sagittal measurement (positioning and evaluation), a single patient was measured ten times, being required to stand up after each measurement. The MR images were evaluated by four independent investigators (one orthopaedist, three radiologists) and the Cobb angle was measured between T4 and T12.

For statistical analysis, the difference between the mean sagittal Cobb angle of the two groups was tested by a nonparametric test (Mann-Whitney-U test, statistic programme SPSS for Windows).

Results

In the group with idiopathic scoliosis, the mean Cobb angle was 28° (10° – 58°) for the thoracic curve on the coronal supine MR images. The conventional standing AP radiographs had an average Cobb angle of 33° (12° – 60°).

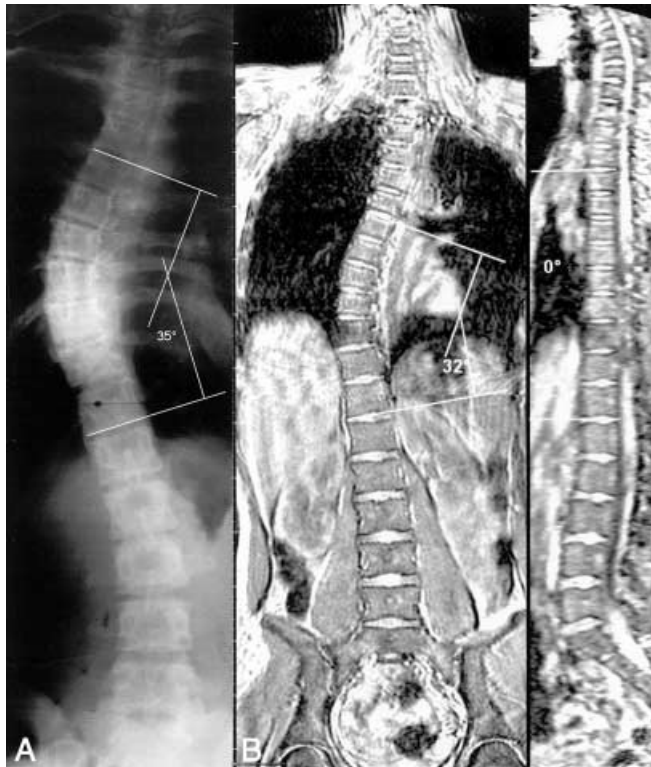

Fig. 1A,B A 15-year-old girl with right thoracic scoliosis and brace treatment. **A** Conventional radiograph with a coronal Cobb angle of 35° . **B** Magnetic resonance (MR) total spine imaging with a coronal Cobb angle of 32° . In the sagittal plane the thoracic lordosis is shown with a sagittal Cobb angle (T4–T12) of 0°

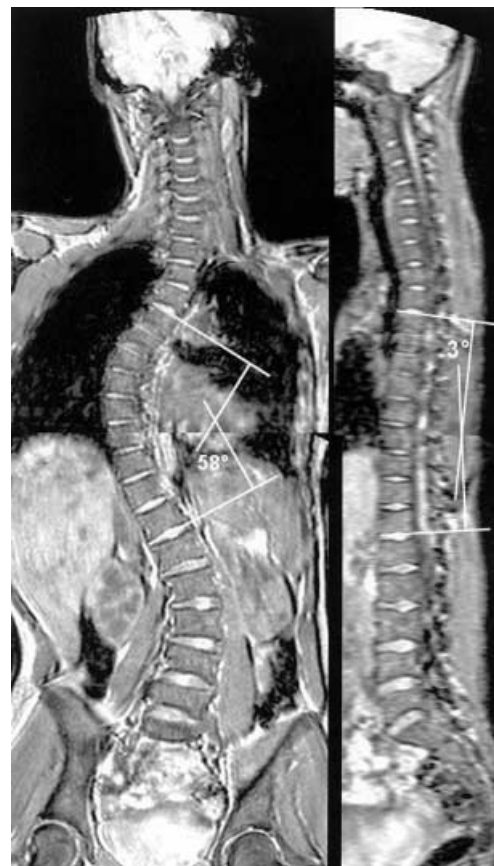

Fig. 2 MR total spine imaging in a 16-year-old patient with a coronal Cobb angle of 58° and a sagittal Cobb angle (T4–T12) of -3° (performed at first examination in our clinic; operative treatment is planned). The spine is remarkably straight in the sagittal plane; the lordosis extends from T6 to L1

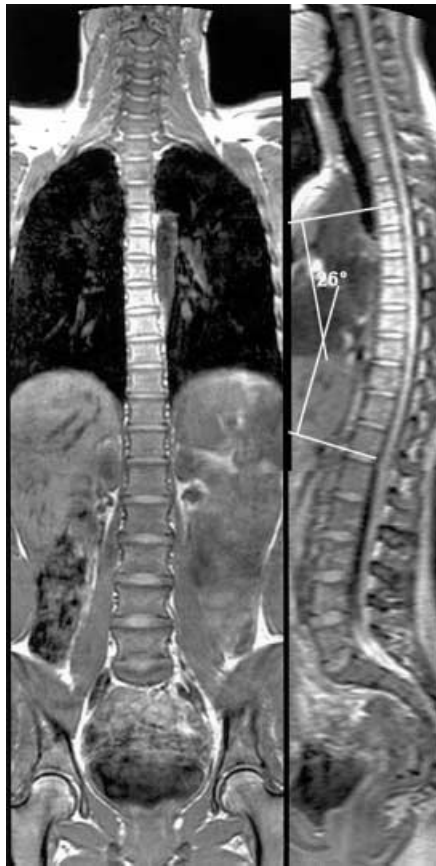


Fig. 3 A 14-year-old girl of the group without scoliosis. MR total spine imaging shows a sagittal Cobb angle (T4–T12) of 26°

The mean deviation between supine MR total spine projection and standing AP radiograph was -4.5° , with a range from 0° to -11° .

On the supine MR images in the sagittal plane, the Cobb angle in the segments of the scoliotic deformity measured on average only 9° (-4° to 22°). The mean sagittal Cobb angle for the standardised measurement between T4 and T12 was 12° (-3° to 24°) (Fig. 1, Fig. 2). The mean sagittal Cobb angle (T4–T12) of the group without scoliosis was 22° (15° to 30°) (Fig. 3). Table 1 shows the mean values and the standard deviations of the coronal and sagittal Cobb angles on MR images.

For the sagittal Cobb angle, there was a significant difference (Mann-Whitney-U test, $P < 0.01$) between the group with idiopathic scoliosis and the group without scoliosis.

Some cases are of particular interest. One measurement of a 15-year-old girl with a coronal Cobb angle of 32° on supine MRI and with brace treatment showed in the sagittal plane projection a thoracic lordosis (Fig. 1A, B). Another female patient had a short-curve thoracic scoliosis of 22° between T1 and T5. For this section the lateral projection showed only a minimal kyphosis of 2° , but

Table 1 Comparison of the mean (\pm SD) sagittal Cobb angles (T4–T12) on supine magnetic resonance (MR) total spine imaging of patients with idiopathic scoliosis and a group without scoliosis (Cobb angle $< 5^\circ$)

	Idiopathic scoliosis ($n=32$)	Group without scoliosis ($n=18$)
Age (years)	$14.8^\circ \pm 3.4^\circ$	$14.5^\circ \pm 4.9^\circ$
Coronal Cobb angle of thoracic curve	$28^\circ \pm 9.9^\circ$	$0.9^\circ \pm 1.7^\circ$
Sagittal Cobb angle (T4–T12)	$12^\circ \pm 7.7^\circ$ [[asteriskmath]]	$22^\circ \pm 3.4^\circ$ [[asteriskmath]]

* $P < 0.01$; Mann-Whitney-U test

the sagittal Cobb angle between T4 and T12 was 20° . Therefore there was a segmental lordotic fixation in the portion of scoliotic curve, which was compensated over the whole thoracic spine.

The patient who was measured ten times had a coronal Cobb angle on supine MRI of 20° and a sagittal Cobb angle of 16° . The intraobserver variance was 1.6° and the interobserver variance was 1.8° .

Discussion

Thoracic lordosis or reduction of the normal kyphosis is a typical sign in idiopathic scoliosis [10]. In contrast to the study of Probst-Procter and Bleck [9], which was unable to establish any significant difference in kyphosis or lordosis on the lateral X-ray images in a comparison of 104 healthy children and 114 children with scoliosis, more recent studies confirm that there is a significant difference in the sagittal profile with idiopathic scoliosis [8, 10, 15].

Raso et al. [10] found a kyphosis of less than 16° on the lateral routine radiographs in 59 out of 138 patients with scoliosis. When the spine was viewed at 90° to the apical vertebrae, 64 out of 138 cases (46%) were hypokyphotic ($< 10^\circ$ between T5 and T12). Xiong et al. [15] were able to show that in cases of scoliosis with Cobb angles of more than 8° , the thoracic kyphosis is already reduced compared to the control group, which means that the changes in the sagittal plane can be shown in early stages of idiopathic scoliosis. For Dickson et al. [3], lordosis of the spine is the decisive pathogenetic factor in the occurrence of idiopathic scoliosis, based on the theory of rotational lordosis expounded by Sommerville [11]. In an epidemiological study of 16,000 school children, those cases developing an idiopathic scoliosis also showed a progressive lordosis of the thoracic vertebrae [7].

Therefore, monitoring scoliosis in the sagittal plane promises interesting clinical data. However, due to the high level of radiation exposure, which increases for children during the course of a scoliosis programme lasting several years, lateral radiographs of the spine are usually only carried out during the first investigation or as a part

of the preoperative assessment. As a result, scoliosis could not be previously monitored in the sagittal plane.

MR total spine imaging was developed to reduce X-ray exposure in the follow-up of scoliosis patients, who are mainly adolescent female patients [4, 5]. Therefore, the coronal and sagittal MR reconstructions simulate the conventional X-ray projections. The appearance of scoliosis on these projections must necessarily not be a true representation of the actual deformity in three dimensions. However, the MR technique allows Cobb angle measurements in a coronal and sagittal plane, which might give additional, relevant data in scoliosis.

In the current study, sagittal Cobb angles were reliably measured in scoliosis using this technique. MR total spine imaging showed a significantly reduced mean sagittal Cobb angle (T4–T12) for the group with idiopathic scoliosis compared to the group without scoliosis. Typically, segmental flattening was seen in the portion of scoliotic deformity.

The MR examinations were carried out in a supine position. For the coronal Cobb angles in the scoliosis group, we found a mean deviation of -4.5° on supine MR images compared to conventional radiographs in standing position. In the study of Torell et al. [12], the mean coronal Cobb measures for 287 patients with idiopathic scoliosis were 39.4° standing and 30.6° supine on conventional radiographs. As in the coronal plane, we would expect some difference in the sagittal Cobb angle measures between standing and supine position. Because of the additional X-ray exposure involved, we did not take comparable lateral X-rays. However, the MR technique allows imaging in the coronal and sagittal plane during the same exami-

nation and actually with the same MR sequence. Therefore, we are planning to use the sagittal projection as well for longitudinal follow-up of the same patients. Clinical relevance for the patient would therefore stem from an intraindividual change in the follow-up when comparing supine MR sagittal views with supine MR sagittal views of the same patient. Therefore, although interesting, we believe that for this intention a comparison of positioning differences is not necessary.

Using MR total spine imaging for monitoring sagittal Cobb angles could reveal further relevant clinical data in scoliosis. Willner [14] suspected a negative correlation between kyphosis and thoracic scoliosis, as flattening of the kyphosis is often seen in progressive, severe scoliosis. Monitoring scoliosis in the sagittal plane may show whether flattening of the thoracic kyphosis correlates with poor prognosis. The lateral MR projection could help us detect progressing scoliosis earlier. MR total spine imaging might also be helpful in assessing the effect of brace treatment. It is presumed that thoracic lordosis is increased during brace treatment [6, 13], and studies aimed at quantifying such changes in lordosis are therefore being currently undertaken with this MR technique.

Judged from the time and resources involved, MR total spine imaging would cost less than a normal MR lumbar spine study, but certainly more than a conventional total spine radiograph.

MR total spine imaging could be a useful tool for imaging scoliosis in the sagittal plane without any additional radiation exposure. Future studies have to show whether the MR technique may become a practical procedure in scoliosis diagnosis.

References

1. Almen A, Mattson S (1996) Dose distribution at radiographic examination of the spine in pediatric radiology. *Spine* 21:750–756
2. Burwell RG, Cole AA, Cook TA, Grivas TB, Kiel AW, Moulton A, Thirlwall AS, Upadhyay SS, Webb JK, Wemyss-Holden SA, et al (1992) Pathogenesis of idiopathic scoliosis. The Nottingham concept. *Acta Orthop Belg* 58:33–58
3. Dickson RA, Lawton JD, Archer IA, Butt WP (1984) The pathogenesis of idiopathic scoliosis. *J Bone Joint Surg Br* 66:8–15
4. Jaeger UE, Koenig R, Gieseke J, Wagner UA, Kandyba J, Ostertun B, Schild HH (1998) MR total spine projection in juvenile scoliosis: an alternative to radiographic follow-up. *Radiology* 209:402
5. Konig R, Jaeger U, Ostertun B, Kandyba J, Wagner UA, Gieseke J, Schild HH (1999) MR whole-spine recording: computer-assisted simulation of the conventional x-ray technique. *RoFo Fortschr* 170:258–261
6. Labelle H, Dansereau J, Bellefleur C, Poitras B (1996) Three-dimensional effect of the Boston brace on the thoracic spine and rib cage. *Spine* 21:59–66
7. Mahood JK, Hull FR, Howell D, Dickson RA (1990) The lateral profile in idiopathic scoliosis – a longitudinal cohort study. *Orthop Trans* 14:724–725
8. Millner PA, Dickson RA (1996) Idiopathic scoliosis: biomechanics and biology. *Eur Spine J* 5:362–373
9. Propst-Procter SL, Bleck EE (1983) Radiograph determination of lordosis and kyphosis in normal and scoliotic children. *J Pediatr Orthop* 3:344–346
10. Raso JV, Russell GG, Hill DL, Moreau M, McIvor J (1991) Thoracic lordosis in idiopathic scoliosis. *J Pediatr Orthop* 11:599–602
11. Sommerville EW (1952) Rotational lordosis: the development of the single curve. *J Bone Joint Surg Br* 34:421–427
12. Torell G, Nachemson A, Haderspeck-Grib K, Schultz A (1985) Standing and supine Cobb measures in girls with idiopathic scoliosis. *Spine* 10:425–427
13. Willers U, Normelli H, Aaro S, Svensson O, Hedlund R (1993) Long-term results of Boston brace treatment on vertebral rotation in idiopathic scoliosis. *Spine* 18:432–435
14. Willner S (1984) Effect of the Boston thoracic brace on the frontal and sagittal curves of the spine. *Acta Orthop Scand* 55:457–460
15. Xiong B, Sevastik J, Hedlund R, Sevastik B (1994) Sagittal configuration of the spine and growth of the posterior elements in early scoliosis. *J Orthop Res* 12:113–118