

## CASE REPORT

## Duodenal perforation caused by a bird feather

Manash Ranjan Sahoo,<sup>1,2</sup> Anil Kumar<sup>2</sup><sup>1</sup>Department of General Surgery, S.C.B Medical College, Cuttack, Odisha, India<sup>2</sup>Department of Surgery, S.C.B Medical College, Cuttack, Odisha, India**Correspondence to**  
Dr Manash Ranjan Sahoo,  
manash67@gmail.com**SUMMARY**

Ingestion of gastrointestinal (GI) foreign bodies represents a challenging clinical scenario. The greater risk is at extremes of age, in those wearing dentures, alcoholics and mentally handicapped. We present a case of duodenal perforation caused by a bird feather. A 64-year-old man was presented with abdominal pain for 4 days. Abdominal examination showed signs of peritonitis. The erect abdominal x-ray showed free gas under diaphragm. Exploratory laparotomy showed purulent fluid, but no definite site of perforation could be found. So the abdomen was closed with a drain in Morison's pouch. The postoperative recovery was uneventful. He came for a repeat check-up at 4 weeks with dull aching pain in the upper abdomen and was advised for a routine upper GI endoscopy which revealed a feather penetrating the first part of the duodenum, which was removed with a foreign body removing forceps. GI foreign bodies represent a significant problem and an increased level of suspicion is important for timely diagnosis and treatment.

**BACKGROUND**

Ingestion of gastrointestinal (GI) foreign bodies represents a challenging clinical scenario. The greater risk is at extremes of age, in those wearing dentures<sup>1</sup> (dentures cover the most tactile area of the palate and the foreign body goes unnoticed) or in patients with previous bowel pathology (diverticular disease, intestinal stricture), alcoholics and mentally handicapped. Cricopharyngeal sphincter, constrictions of the oesophagus, distal ileum and ileocaecal junction are the normal anatomical sites of foreign body impaction.<sup>2</sup> The majority of patients do not recall ingesting the foreign body, it is being discovered either upon investigation (abdominal x-ray or CT scan), or during operation. About 80% of ingested particles pass out without complications.<sup>3</sup> Only about 20% fail to pass through.<sup>4</sup> The clinical presentation may include frank peritonitis, localised abscess formation, enterovesical fistula, intestinal obstruction and intestinal haemorrhage. Perforation occurs in less than 1% of cases and is caused by sharp objects and erosions.<sup>5</sup> Of these sharp objects, chicken bones and fish bones account for half of the reported perforations. The most common sites of perforation are the ileocaecal junction and sigmoid colon.<sup>3</sup> There are more than 300 cases of bowel perforation caused by foreign bodies reported in the literature. Cases of fish bones, chicken bones and dentures are the commonest objects followed by toothpicks and cocktail sticks, but a feather causing duodenal perforation has never been documented. We present a

case report of duodenal perforation caused by a bird feather.

**CASE PRESENTATION**

A 64-year-old man presented with severe abdominal pain, vomiting, absolute constipation for 4 days, without any history of acid peptic disease. Upon examination his vitals were stable, except tachycardia with signs of diffuse peritonitis that is, tenderness, cardboard-like rigidity of the abdomen and absence of bowel sounds. Based on the above clinical findings, the patient was diagnosed to be a case of peritonitis probably owing to any hollow viscus perforation.

**INVESTIGATIONS**

In an erect abdominal x-ray he had free gas under the right dome of diaphragm. Ultrasound of the abdomen showed free peritoneal collections. Routine haemogram showed a raised total leucocyte count with increased neutrophils. For all of the aforementioned clinical features, he was diagnosed to have florid peritonitis probably owing to hollow viscus perforation and was immediately planned for exploratory laparotomy.

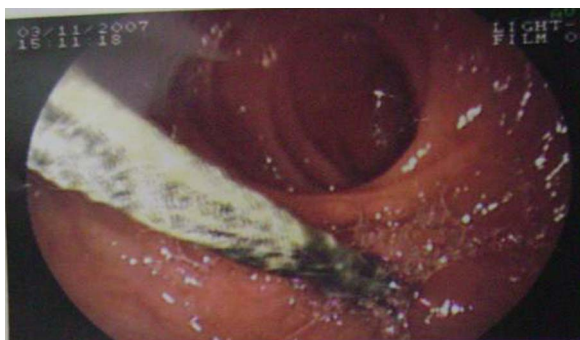**TREATMENT**

After opening the abdomen with an upper midline incision, around 500 ml of purulent exudative peritoneal fluid was sucked out. Occasional fibrinous plaques were visible but no definite site of perforation could be found. Thorough peritoneal toileting with 4 litres of normal saline was performed and a second look for the site of perforation was attempted, but in vain. So it was decided to close the abdomen after putting an abdominal tube drain in the hepatorenal pouch of Morison. The postoperative recovery was uneventful. Drain was removed on the fourth and the stitches were removed on the eighth postoperative day and he was discharged. When he attended his first follow-up 4 weeks after laparotomy with the feather penetrating the first part of the duodenum upon upper GI endoscopy (figure 1), it was removed with a foreign body removing forceps (figure 2) and the specimen was found to be a long and a stout feather with a pointed tip (figure 3). After removing the feather the patient was asked about the chances of either eating a bird with feathers or having eaten a bird feather mistakenly, but the patient did not remember or quote such incidents. Also, the patient did not have any psychiatric illness.

**OUTCOME AND FOLLOW-UP**

He came for repeat a check-up with a dull aching pain in the upper abdomen 4 weeks after being

**To cite:** Sahoo MR, Kumar A. *BMJ Case Rep* Published online: [please include Day Month Year] doi:10.1136/bcr-2013-008635



**Figure 1** A feather in the first part of the duodenum in the upper gastrointestinal endoscopy.

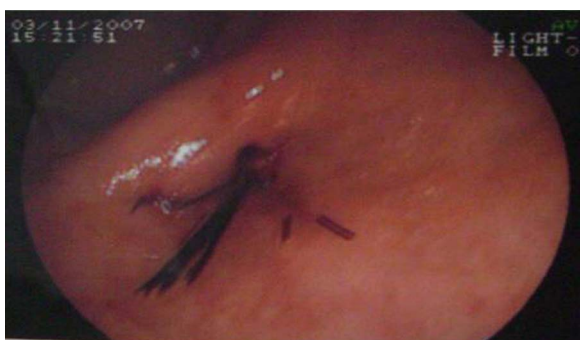discharged and was advised for a routine upper GI endoscopy. A feather penetrating the first part of the duodenum was visible with a visible scar surrounding it (figure 1). A second follow-up with an upper GI endoscopy was 1 month after the endoscopic removal of the feather which revealed a normal duodenum without any pathological conditions (figure 4).

## DISCUSSION

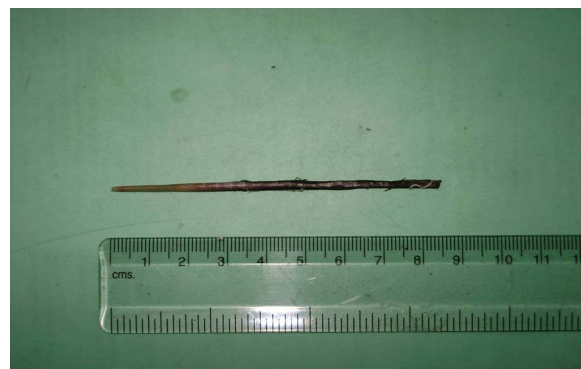Foreign body ingestion is common in children, elderly patients with dental prosthesis, alcoholics and psychiatric patients. Coins, small toys, pins, dentures, fish bones, chicken bones and nails are the commonly ingested materials,<sup>5</sup> followed by toothpicks and cocktail sticks. But a feather causing duodenal perforation has never been documented. A definite preoperative history of foreign body ingestion is rare as highlighted in the present case.

The important factors for ingestion of foreign bodies and impaction are dentures which cover the most tactile area of the palate and the foreign body goes unnoticed, sensory defects owing to cerebrovascular accident, previous gastric surgery facilitating the passage of foreign bodies, achlorhydria where the foreign body passes unaltered from the stomach, patients with previous bowel pathology (diverticular disease, intestinal stricture) causing impaction.<sup>1</sup> Overeating, rapid eating or a voracious appetite may be the contributing factors for ingesting chicken bones.

Most ingested foreign bodies pass through the GI tract uneventfully within 1 week. Cricopharyngeal sphincter, constrictions of the oesophagus, distal ileum and ileocaecal junction are the normal anatomical sites of foreign body impaction.<sup>2</sup> The pathological areas such as oesophageal rings or webs, pyloric stenosis, intestinal stricture and congenital malformations are the other areas of impaction. Impacted foreign bodies may



**Figure 2** The duodenum after removal of the foreign body.



**Figure 3** A long and stout feather with a pointed tip of approximately 8.5 cm.

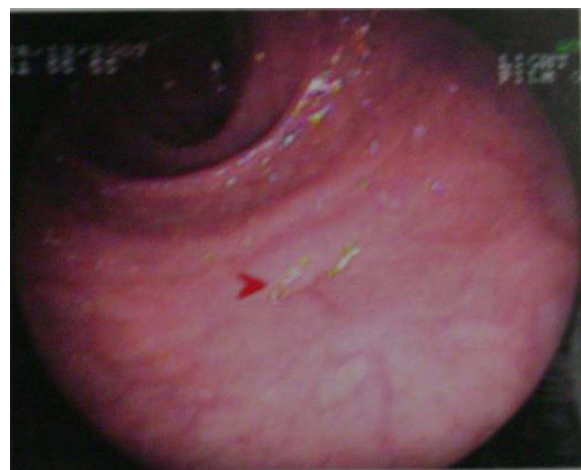
cause evident peritonitis, localised abscess formation, enterovesical fistula, intestinal obstruction and intestinal haemorrhage.<sup>5–9</sup>

The incidence of perforation caused by foreign body penetration is reported to be less than 1%. The most common sites of perforation are the ileocaecal junction and sigmoid colon. Other sites are the duodenojejunal flexure, appendix, colonic flexure, diverticulae and the anal sphincter.<sup>1</sup> Colonic diverticulitis or previously unsuspected colon carcinoma have been reported as secondary findings in the cases of sigmoid perforation caused by chicken bones.<sup>10–11</sup> Penetration of duodenum with migration of the foreign body into the pancreas and liver causing pancreatic and hepatic abscesses is also reported.<sup>12–14</sup>

The foreign bodies impacted in the oesophagus or stomach can be extracted endoscopically. The surgical extraction is indicated in failed endoscopic retrieval.

## Learning point

- Gastrointestinal foreign bodies represent a significant problem. Endoscopy and open or laparoscopic surgery are the options available and an increased level of suspicion is important for the timely diagnosis and treatment to prevent unnecessary morbidity and mortality to the patients.



**Figure 4** Upper gastrointestinal endoscopy showing normal duodenum 1 month after removal of the foreign body.

**Competing interests** None.

**Patient consent** Obtained.

**Provenance and peer review** Not commissioned; externally peer reviewed.

## REFERENCES

- 1 Cleator IG, Christie J. An unusual case of swallowed dental plate and perforation of the sigmoid colon. *Br J Surg* 1973;60:163–5.
- 2 Nandi P, Ong GB. Foreign body in oesophagus: review of 2394 cases. *Br J Surg* 1978;65:5–9.
- 3 Perelman H. Tooth pick perforations of the gastrointestinal tract. *J Abdom Surg* 1965;4:51–3.
- 4 Goh BK, Chow PK, Quah HM, *et al*. Perforation of the gastrointestinal tract secondary to ingestion of foreign bodies. *World J Surg* 2006;30:372–7.
- 5 Samdani T, Singhal T, Balakrishnan S, *et al*. An apricot story: view through a keyhole. *World J Emerg Surg* 2007;2:20.
- 6 Prelman H. Toothpick perforation of the gastrointestinal tract. *J Abdom Surg* 1963;4:51.
- 7 Hussain M, Bahl DV, Maletha M. The ileum: an unusual site of perforation by a swallowed artificial denture. *Internet J Surg* 2007;10:2.
- 8 Khan MS, Bryson C, O'Brien A, *et al*. Colovesical fistula caused by chronic chicken bone perforation. *Ir J Med Sci* 1996;165:51–2.
- 9 Read TE, Jacono F, Prakash C. Coloenteric fistula from chicken bone perforation of the sigmoid colon. *Surgery* 1999;125:354–6.
- 10 Gomez N, Roldos F, Andrade R. Intestinal perforation caused by chicken bone mimicking perforated colonic diverticulitis. *Acta Gastroenterol Latinoam* 1997;27:329–30.
- 11 Osler T, Stackhouse CL, Dietz PA, *et al*. Perforation of the colon by ingested chicken bone, leading to diagnosis of carcinoma of the sigmoid. *Dis Colon Rectum* 1985;28:177–9.
- 12 Mc Pherron RC, Karlon M, Williams RD. Foreign body perforation of the intestinal tract. *Am J Surg* 1957;94:564.
- 13 Chintamani, Singhal V, Lubhana P, *et al*. Liver abscess secondary to a broken needle migration—a case report. *BMC Surgery* 2003;3:8.
- 14 Toyonaga T, Shinohara M, Miyatake E, *et al*. Penetration of the duodenum by an ingested needle with migration to the pancreas: report of a case. *Surg Today* 2001;31:1436–2813.

Copyright 2013 BMJ Publishing Group. All rights reserved. For permission to reuse any of this content visit <http://group.bmj.com/group/rights-licensing/permissions>.  
BMJ Case Report Fellows may re-use this article for personal use and teaching without any further permission.

Become a Fellow of BMJ Case Reports today and you can:

- Submit as many cases as you like
- Enjoy fast sympathetic peer review and rapid publication of accepted articles
- Access all the published articles
- Re-use any of the published material for personal use and teaching without further permission

For information on Institutional Fellowships contact [consortiasales@bmjgroup.com](mailto:consortiasales@bmjgroup.com)

Visit [casereports.bmj.com](http://casereports.bmj.com) for more articles like this and to become a Fellow