NIH Public Access
Author Manuscript
NMR Biomed. Author manuscript; available in PMC 2014 February 01.

Published in final edited form as:
NMR Biomed. 2013 February ; 26(2): 204–212. doi:10.1002/nbm.2837.

Serial measurement of hepatic lipids during chemotherapy in colorectal cancer patients: A ^{1}H magnetic resonance spectroscopy study

Jing Qi[1], **Yuman Fong**[1], **Leonard Saltz**[1], **Michael I. D'Angelica**, **Nancy E. Kemeny**[1], **Mithat Gonen**[1], **Jinru Shia**[1], **Amita Shukla-Dave**[1], **William M. Jarnagin**[1], **Richard K. G. Do**[1], **Lawrence H. Schwartz**[2], **Jason A. Koutcher**[1], and **Kristen L. Zakian**[1]

[1]Memorial Sloan-Kettering Cancer Center, New York, New York, USA

[2]Columbia University College of Physicians and Surgeons, New York, New York, USA

Abstract

Background and Rationale—Hepatic steatosis is a hallmark of chemotherapy-induced liver injury. We made serial ^{1}H magnetic resonance spectroscopy (MRS) measurements of hepatic lipids in patients over the time course of a 24-week chemotherapy regimen to determine whether ^{1}H MRS can be used to monitor the progression of chemotherapy-induced steatosis.

Experimental Procedures—Thirty-four patients with stage III or IV colorectal cancer receiving FOLFOX (n = 21) or hepatic arterial infusion of floxuridine with systemic irinotecan (n=13) were studied prospectively. ^{1}H MRS studies were performed at baseline and after 6 and 24 weeks of treatment. A ^{1}H MR spectrum was acquired from the liver during a breath-hold and the ratio of fat to fat+water (FFW) was calculated to give a measure of hepatic triglycerides (HTGC). The methodology was histologically validated in 18 patients and reproducibility was assessed in 16 normal volunteers.

Results—Twenty-seven patients completed baseline, 6-week and 24-week ^{1}H-MRS exams and one was censored. Thirteen of 26 patients (50%) showed an increase in FFW after completion of treatment. Six patients (23%) developed hepatic steatosis and two patients converted from steatosis to non-steatotic liver. Patients whose six-week hepatic lipid levels had increased significantly compared to baseline had a high probability of lipid elevation relative to baseline at the completion of treatment as well.

Conclusion—Serial ^{1}H-MRS is effective for monitoring HTGC changes during chemotherapy and detecting chemotherapy-associated steatosis. Six of 26 patients developed steatosis during chemotherapy. Lipid changes were observable at 6 weeks.

Keywords

fat; liver; FOLFOX; steatosis; imaging

INTRODUCTION

Advanced colorectal cancer (CRC) patients are routinely treated with combination chemotherapy in either the adjuvant or neo-adjuvant setting. FOLFOX (5 fluorouracil (5FU) + folinic acid + oxaliplatin) and FOLFIRI (5FU + folinic acid + irinotecan) are the most

Corresponding author: Kristen L. Zakian, Ph.D., Associate Attending Physicist, Department of Medical Physics, Memorial Sloan-Kettering Cancer Center, 1275 York Ave., New York, NY 10021. Phone: 212-639-8595, Fax: 212-717-3010, zakiank@mskcc.org.

$watermark-text
$watermark-text
$watermark-text

$watermark-text

$watermark-text

$watermark-text

common treatment regimens (1–3). However, there have been multiple reports of liver abnormalities including fibrosis, steatosis, and steatohepatitis following treatment (4–10). For patients who have undergone curative resection of primary CRC, adjuvant chemotherapy increases the chance of long-term survival; however, liver toxicity is a significant concern. Furthermore, due to the high incidence of hepatic metastases, some of these patients may eventually need liver resection; and parenchymal abnormalities may impact the feasibility and safety of the procedure. In previous studies of patients who received neoadjuvant chemotherapy prior to resection of liver metastases, severe steatosis was recognized as a risk factor for perioperative morbidity and mortality (11–13). A method for monitoring and grading steatosis could potentially allow selection of patients for surgery as well as for therapies to modulate such liver injury. While liver biopsy is considered the gold standard for evaluation of hepatic steatosis, it is invasive, carries a risk of bleeding and is not practical for serial assessments.

This pilot study examines the effectiveness of ^{1}H Magnetic Resonance Spectroscopy (^{1}H-MRS), a non-invasive test, for monitoring of hepatic triglycerides (HTGC) during chemotherapy. ^{1}H MRS has been widely used to assess liver lipids and has been found to agree well with histology (14–18). MR imaging techniques for the quantitative assessment of liver fat have advanced rapidly in recent years (19–23) and compare favorably in accuracy with MRS. These imaging techniques could be valuable in future studies of the effect of chemotherapy on the liver.

Experimental

MR scanning and Spectroscopic Data Processing

Liver MR images and spectra were acquired on a 1.5 Tesla MR scanner (General Electric, Milwaukee, WI) using a 4-channel torso phased-array coil. All subjects provided written informed consent for enrollment in this institutional review board-approved study, and Health Insurance Portability and Accountability Act (HIPAA) guidelines were followed. T_2-weighted axial images were obtained for localization using a fat-suppressed fast spin-echo sequence. For ^{1}H-MRS, a 2.0 × 2.0 × 2.0 cm^3 volume (voxel) was placed in the peripheral right hepatic lobe, away from the diaphragm, and avoiding large blood vessels and ducts. A point-resolved spectroscopy sequence (PRESS) (24) was used to acquire a ^{1}H MR spectrum in a single breath-hold without water suppression. The acquisition parameters were: repetition time (TR) = 5s, echo time (TE) = 40ms, number of acquisitions = 4, scan time = 20s, spectral width = 2000 Hz, number of complex points per spectrum = 512. The total scan time including imaging was approximately 20 minutes. In 10 patients, breath-held PRESS acquisitions were also performed at echo times of 30ms, 40ms, 60ms, 90ms, 140ms, and 190ms so that T_2 values could be calculated. Software for combining multicoil data and peak fitting was kindly provided by Dikoma Shungu, Ph.D. (Weill-Cornell Medical College, New York, NY). Spectra from multiple coils were weighted based on the amplitude of the water peak and combined by a sum of squares algorithm. Peak areas (PA) were calculated using time-domain fitting assuming a lorentzian lineshape. Because the majority of our subjects were lean, reliable fitting of lipid peaks other than the methylene peak at 1.3 ppm was usually not possible due to low lipid SNR in these breath-held spectra. We fit the methyl peak (0.9 ppm) when possible in order to improve the accuracy of the methylene peak fit, but we used only the methylene peak area for our total liver lipid calculations. Water and methylene peak areas were corrected for T_2 relaxation using the mean of the measured T_2 values for 10 subjects (66 ± 6 ms for methylene lipid and 45 ± 6 ms for water). We estimated the total fat area (PA_{fat}) using the relative ratios for fat peaks given in Hamilton, et, al. (25). The methylene peak including the small contribution from the 1.6 ppm lipid peak comprised 70% of total lipids. The expected contribution from the 4.25 and 5.3 ppm lipid peaks to the water peak (6.8% of total lipids) (25) was calculated and

subtracted from the water area to give the corrected water peak area (PA_{water}). Finally, the total fat fraction was calculated as: FFW $=PA_{fat}/(PA_{water}+PA_{fat})$.

Histologic validation and inter-examination reproducibility of FFW measurements

To validate the FFW measurement technique, ^{1}H-MRS data were compared to histologic steatosis grade in 21 patients from whom tissue was available. Fifteen of these patients took part in the serial MRS study described herein and had tissue obtained prior to or following that study. Six other patients underwent a single ^{1}H-MRS exam prior to partial hepatectomy for metastatic CRC. Three patients were excluded because ^{1}H-MRS followed a partial hepatectomy where regenerative effects could not be excluded, resulting in a final group of 18 patients for correlation between ^{1}H-MRS and histologic steatosis (demographic and clinical data in Supplemental Table 1). One patient yielded pre-treatment biopsy tissue as well as resection tissue after completion of chemotherapy. Liver tissue was processed by standard clinical procedures. Steatosis was graded on a 0–4 scale based on the percentage of fatty changes in hepatocytes (Supplemental Table 2) by an experienced hepatopathologist (JS) who was blinded to the ^{1}H-MRS results. FFW measurements were compared to histologic steatosis grade.

To investigate the reproducibility of the ^{1}H-MRS FFW measurements, 16 heathy adults were studied twice with a 2 week interval between MRS exams using the same technique employed in the patients (demographics in supplemental Table 1). This long time interval was chosen because the interval between serial studies for a given patient was, at minimum, 6 weeks. During the second exam, the voxel location was chosen to match as closely as possible the baseline voxel location. The baseline and two week FFW values were compared to determine the reproducibility of the ^{1}H-MRS measurement technique.

All patients and healthy subjects were requested to eat lightly on the day of the ^{1}H-MRS study and to fast for two hours prior to the study. Longer fasting periods and standardization to a specific time of day were not possible because the MR studies were performed at the convenience of the patients and often on days when they were subsequently given chemotherapy.

Serial Assessment of Hepatic Lipids during Chemotherapy

Thirty-four patients with stage III or IV colorectal cancer were studied prospectively. Accrual took place between February, 2007 and November, 2010. Twenty-one patients were treated with FOLFOX according to a modified FOLFOX 6 schedule, and 13 received hepatic arterial infusion of floxuridine (HAI-FUDR) combined with systemic irinotecan (IRI). Patients' clinical characteristics are listed in Table 1. Nineteen of the 21 patients in the FOLFOX group were treated in the adjuvant setting after colectomy. In each FOLFOX cycle, oxaliplatin and leucovorin were given intravenously over a two-hour period, followed immediately by a rapid bolus injection of 5FU and then continuous infusion of 5FU over two days. The time between cycle start dates was two weeks. Twelve FOLFOX cycles were planned and the mean number of cycles given was 10 (range 7–12). In the HAI-FUDR/IRI group, FUDR in the reservoir of an implanted pump was infused via the hepatic artery over two weeks followed by two weeks of heparinized saline infusion. Irinotecan was given as a 30 minute intravenous infusion every two weeks. The time between cycle start dates was four weeks and the number of cycles was determined on an individual basis. All 13 patients in the HAI-FUDR/IRI group had undergone prior chemotherapy and 5 had undergone curative liver resection or radiofrequency ablation of liver metastases. The remaining 8 patients had unresectable liver metastases at the start of the study.

$watermark-text $watermark-text $watermark-text

$watermark-text

$watermark-text

$watermark-text

$H-MRS exams were performed at 3 time points: prior to chemotherapy, after 6 weeks (3 FOLFOX cycles or 1.5 HAI-FUDR/IRI cycles), and after 24 weeks (12 FOLFOX cycles or 6 HAI-FUDR/IRI cycles). In the 14 pretreated patients, prior chemotherapy had ended 1–18 months (median = 1mo.) before the baseline $H-MRS exam. $H-MRS data for all three time points were available in 27 patients. The other 7 patients had unusable or unavailable data for the 24-week time point for the reasons described herein. Patient 2 underwent partial hepatectomy after FOLFOX cycle 4 and was withdrawn from the study. Patient 4 was lost to followup. Patients 10, 23, and 28 withdrew due to treatment- or disease-associated morbidity. Patients 26 and 29 underwent right portal vein embolization during chemotherapy and were withdrawn from the study. The post-24-week $H-MRS exam was performed within one month of the 24-week treatment with the exception of patient 19 whose final $H-MRS took place 3 months after completion of treatment at the patient's request. One patient (#8) was censored from the study because the time between baseline MRI and first treatment exceeded 60 days. The median time between baseline MRI and first treatment was 4.5 days (range 0–40 days) in the final cohort of 26 patients. There was no significant weight change between baseline MRI and treatment start date in these patients.

Statistical analyses

The association between FFW and histologic steatosis grade was assessed by analysis of variance (when histology grade was used as ordinal) as well as the Wilcoxon test (when grade was binary: 0–1 vs 2 or higher (< 25% vs ≥ 25%)). A receiver operating characteristic (ROC) curve based on the MRS and histologic data was constructed using the empirical method and the best FFW cutoff that discriminated patients with steatosis from others was chosen using the threshold where the ROC curve was closest to the upper left corner (26). Because one patient contributed two data points, the effect of clustering on the comparison between histology and MRS data was analyzed using the design-effect method (27). The results indicated that the effect of clustering was minimal and standard methods were valid. Reproducibility of FFW measurements in healthy volunteers was evaluated using the coefficient of variation (CV). Association between 6-week FFW and 24-week FFW was assessed by a chi-square test and between baseline parameters (ALT, BMI) and change in FFW at 24 weeks with the Wilcoxon test. Comparison of the baseline rates of steatosis in pre-treated and treatment naïve groups was performed using Fisher's exact test. All analyses were performed using SAS version 9.2 (Cary, NC).

RESULTS

Validation and Reproducibility

In the surgical cohort, histologic steatosis was detected in 8 tissue samples, while the remaining 11 had grade 0 or 1 liver fat content (see Figure 1). A positive correlation was found between the $H MRS-measured FFW and histologic steatosis grade ($r = 0.67$, $p < 0.001$), validating the MRS technique. A value of FFW = 0.039 corresponded to the point where the ROC curve was closest to the upper left corner, and this cutpoint was used to define steatosis by MRS in our serial study. The cutpoint gave 87.5% sensitivity and 100% specificity for the detection of histologic steatosis with area under the curve of 0.967 (95% CI: 0.861–1.00). In the normal volunteer reproducibility analysis, the baseline and 2-week FFW values showed a high degree of correlation ($R = 0.976$), and the inter-exam CV was 15%. Therefore, only changes in FFW of ≥ 15% were considered significant in our serial patient study.

Serial FFW changes during chemotherapy

Examples of water-lipid proton spectra from two FOLFOX-treated patients who were studied serially are shown in Figure 2. Patient 15 showed an increase in liver lipids after 3

$watermark-text

$watermark-text

$watermark-text

cycles of chemotherapy (6 weeks) and a further increase after 12 cycles (24 weeks), while patient 5 showed no changes. Figure 3 shows the baseline and 24 week FFW values for 26 patients segregated by treatment regimen. In the FOLFOX group (Fig. 3a), 9 of 18 patients had an increase in FFW of greater than 15% while 3 patients had no change and 6 had decreased FFW values. Patient 12 (asterisk) was treated for more than 5 years prior to and during the study with anti-HIV HAART therapy. In the HAI-FUDR/IRI group (Fig. 3b), 4 of 8 patients showed increased FFW while 2 patients had no change and 2 had decreased FFW. The percentages of patients with increased FFW were not significantly different between the two treatment groups (P = NS). One patient in the HAI-FUDR/IRI group (#25) had a baseline BMI of 27.9 kg/m^2, was a long-time cholesterol-lowering statin user and had very high HTGC at baseline (FFW = 0.45) which did not change significantly after 24 weeks of treatment.

Clinical steatosis changes over the course of treatment

In addition to measuring the change in FFW, we also analyzed the results in terms of steatosis using a cutpoint of FFW = 0.039. Ten of the 26 patients (38%) had FFW levels corresponding to histologic steatosis before chemotherapy. In these 10 subjects, four experienced an increase in lipids after 24 weeks of treatment, three experienced a decrease, and three experienced no change. Thus, in this limited data set, steatosis at baseline did not predispose a patient to an increase in lipids during treatment. As demonstrated in Table 2, six patients who were not steatotic by ^{1}H-MRS at baseline developed steatosis (23%; 95% CI: [9–44%]). Two patients who were steatotic converted to non-steatotic. The remaining 18 patients had unchanged steatosis status. Of the 6 patients who converted from non-steatotic to steatotic, five received FOLFOX and one received HAI-FUDR/IRI. In this limited group, the type of chemotherapy did not significantly affect the percent of patients who converted to steatosis (P = NS). In patients who became steatotic, the average change in FFW was +299%, while the average change in those who converted to non-steatotic was -66%. In the patients whose steatosis status changed, neither baseline values of BMI or ALT, nor changes in these parameters during chemotherapy were related to steatosis status changes (P=NS).

Hepatic Lipid Changes in Patients with Prior Chemotherapy or Statin Treatment

Nine patients in our serial population had been exposed to prior chemotherapy. Four of 9 (44%) had increased FFW values after 24 weeks and 1 (11%) converted from non-steatotic to steatotic. Conversely, 8 of 17 chemotherapy-naïve patients (47%) experienced increased FFW after treatment and 5 (29%) converted from non-steatotic to steatotic. Therefore, prior chemotherapy was not predictive of increased HTGC or change in steatotic status after treatment. Six of the serial-MRS patients had been treated prior to and during the study with cholesterol-lowering statin medication. One of these patients was concurrently on HAART treatment. In the remaining 5 patients after 24 weeks of treatment, 2 had increased FFW, 2 had decreased FFW, and 1 had no change in FFW. One of these 5 converted from non-steatotic to steatotic. Based on this limited sample, statin treatment did not appear to alter HTGC in a specific direction or change steatosis status. If we conservatively censor statin (N=5) or statin-HAART (N=1) treated patients from our population, the rate of conversion from non-steatotic to steatotic is 5/20 (25.0%; 95% CI: [9–49%]).

Significance of early elevation in liver HTGC

We investigated whether patients who experienced an early increase in liver lipids after 6 weeks of chemotherapy were more likely to complete 24 weeks of chemotherapy with elevated lipids. Figure 4a illustrates FFW levels at baseline, after 6 weeks and after completion of 24 weeks of chemotherapy. In the branch diagram in Fig. 4b, the patients are sorted according to their 6-week FFW trend relative to baseline and then further divided according to the 24-week FFW change relative to baseline. The top-most branch in the

$watermark-text

$watermark-text

$watermark-text

diagram indicates that 14 patients experienced an increase in FFW after 6 weeks and 10 of these (85%) completed 24 weeks with FFW values greater than baseline. Of the 12 patients who experienced no change or a decrease in FFW after 6 weeks of chemotherapy, 10 (83%) completed chemotherapy with FFW values less than or equal to baseline (lowest branch). The association between the baseline-to-6-week FFW change and the baseline-to-24-week FFW change was significant (P=0.004). Thus, patients who experienced an early increase in lipids were more likely to complete therapy with elevated lipids relative to baseline. Conversely, patients who experienced no change or a decrease in FFW after 6 weeks were more likely to finish the study with unchanged or decreased hepatic lipids. The post-chemotherapy ^{1}H-MRS for patient 19 was performed 3 months after the completion of chemotherapy. The patient's 6-week FFW had increased relative to baseline by 888% (from 0.017 to 0.170). At 3 months after the completion of chemotherapy, the FFW had declined to 0.056 but remained elevated compared to baseline suggesting partial recovery of liver lipid metabolism after cessation of chemotherapy.

DISCUSSION

This pilot study demonstrates that ^{1}H-MRS is a reliable technique for monitoring hepatic lipids over the course of chemotherapy. After 24 weeks of chemotherapy, 13/26 patients (50%) experienced an increase in HTGC, and 6 (23%) converted from non-steatotic to steatotic. As this was a small-sample study, a steatosis conversion rate as high as 44% would be within our 95% confidence limits. The goal of this work was not to define the fraction of patients who are expected to become steatotic but, by studying patients serially, to provide evidence that steatotic changes caused by chemotherapy were detectable by ^{1}H-MRS.

Hepatic steatosis has been reported in colorectal cancer patients who have been treated by regimens including 5FU/interferon(28), HAI-FUDR(29), 5FU/folinic acid (30), and 5FU/levamisole (31). However, others have reported that steatosis is no higher in treated patients than in chemotherapy-naïve cohorts (7, 9, 16, 32, 33). Recently, Makowiec, et. al. (34) reported a histologic steatosis rate of 46% in patients who had received 5FU-based, oxaliplatin-based, or irinotecan-based treatment and a rate of 18% in a similar population which had not undergone chemotherapy. Taking the difference between these two populations results in a rate of approximately 28% for chemotherapy-induced steatosis which is similar to our result. Differences could be due to population and treatment variations. Both studies emphasize a corollary point: a single post-chemotherapy assessment of steatosis in a patient population may not be valid for estimating the rate of steatosis induction by chemotherapy.

The high rate of steatosis in the U.S. population is well-recognized (15, 35) and serial ^{1}H-MRS studies are ideal for monitoring treatment-induced lipid changes. Radiologic modalities including ultrasound (US), computerized tomography (CT), MRI and ^{1}H-MRS have been used to evaluate HTGC in nonalcoholic fatty liver disease (36–38). ^{1}H-MRS and fat-sensitive MRI have shown better correlation with histopathologic steatosis than US and CT (39) and ^{1}H MRS has been applied to evaluate hepatic lipids in multiple longitudinal studies (40–44). To our knowledge, serial changes in HTGC induced by chemotherapy have not been investigated using *in vivo* MRI or ^{1}H-MRS. Only two prior studies have presented serial imaging data during chemotherapy and neither was originally designed to investigate hepatic lipids. The appearance of steatosis was noted on serial CT scans obtained for tumor response assessment to 5FU/interferon-α in patients with metastatic CRC(28). Peppercorn, et. al. found a decrease of > 10 Hounsfield units on serial CT scans in 10 of 21 patients (48%) who underwent treatment with 5FU, a change sufficient to indicate steatosis (30). CT is less sensitive to steatosis than MR methods (39), is not quantitative, and utilizes non-ionizing radiation, making it non-ideal for serial monitoring.

$watermark-text

$watermark-text

$watermark-text

HAI-FUDR combined with systemic chemotherapy has been shown to improve response rates for hepatic metastases (45, 46) and to prolong survival after resection of hepatic metastases (47, 48). While systemic chemotherapies often cause GI and hematopoietic toxicities, the main toxicity to HAI-FUDR is biliary sclerosis (49). Further, irinotecan has been associated with steatohepatitis (6). We were therefore interested to determine whether HAI-FUDR/IRI would cause a high rate of liver steatosis. In our limited number of patients, the percentage of steatosis development in the HAI-FUDR/IRI group (1/9) was not higher than that in the FOLFOX group (5/17).

Our data indicate that patients who experienced an increase in hepatic lipids after 6 weeks of chemotherapy had an 85% probability of completing chemotherapy with lipids elevated relative to baseline. Furthermore, patients with unchanged or decreased lipids after 6 weeks had an 83% probability of no change/decrease at the completion of therapy. This indicates that 1) lipids can begin to increase relatively early in the chemotherapy course, and 2) the probability that a given patient will complete chemotherapy with increased hepatic lipids can be assessed fairly accurately at 6 weeks. In CT-based data, Sorensen, et. al. (28) found 2/23 patients receiving 5FU/IFN developed steatosis after 4–8 weeks. The pathogenesis of the accumulation of lipids within hepatocytes during chemotherapy is poorly understood (28–30). It has been hypothesized (50) that chemotherapy and other liver toxins generate hypoxia which causes activation of Kupffer cells, release of vasoactive agents, and ultimately, the generation of a cascade of mediators and molecules including reactive oxygen species which may cause liver injury. Damage to hepatocytes may perturb fatty acid metabolism resulting in steatosis (51). Our data suggest that an early increase in liver lipids detected by ^{1}H-MRS may be a risk factor for developing steatosis during the chemotherapy course.

In the single patient whose final FFW measurement was made 3 months after the cessation of chemotherapy, the data suggest that lipid levels may recover when treatment ceases. In a previous study of patients treated by 5FU, CT-observed steatosis recovered toward normal 3–6 months after cessation of chemotherapy (30). A long-term ^{1}H-MRS follow-up study is underway to test this hypothesis.

Patient 12 had a remarkable increase in FFW at 24 weeks; however, his condition was complicated by concurrent anti-retroviral treatment. Insulin resistance induced by antiretroviral treatment is a major contributor to the development of hepatic steatosis in patients on HAART (52, 53). The dramatic increase in FFW from 0.074 to 0.324 while on FOLFOX suggests a potential synergistic effect. However, a study focusing on this population would be necessary to address this hypothesis. In an investigation of the combined use of FOLFOX and HAART, no increase in chemotherapy toxicity was observed (54).

There were several limitations to this study. The first was the use of a single liver location to assess steatosis. We chose to use breath-held, single-voxel ^{1}H spectroscopy because it is highly sensitive and reproducible and we were hoping to detect relatively small changes in liver lipids (55). Furthermore, when accrual began, we did not have access to the accurate rapid MRI techniques for hepatic lipid quantitation which have recently been developed (19–23). This limited us to serial analysis of one location. It has been reported that steatosis is more often diffuse than focal (51), and in a study of 5FU-induced steatosis, the lipid distribution was found to be diffuse in all subjects (30). However, others have shown evidence of fatty heterogeneity in the liver (56–58). Because we quantified liver fat at a single location over time, use of the single voxel technique does not detract from our serial results. Recently-developed quantitative MRI techniques are a viable option for serial

$watermark-text

$watermark-text

$watermark-text

studies such as the one performed here with the advantage of greater spatial information with which to characterize fatty liver heterogeneity.

While the average T_2 values that we measured for fat and water were comparable to literature values (15), it is preferable to measure T_2 values in individual subjects to avoid inter-subject differences. Recent MRS techniques permit rapid individual assessments of T_2 values, enhancing the accuracy of fat quantification in the liver (59). Furthermore, changes in T_2 values in individual subjects during treatment, while unable to account for the magnitude of the FFW changes seen in our study, should be monitored. Future serial studies should implement T2-measurements at each time point. The use of a TE value of 40 ms could have permitted J coupling modulation of the methylene peak which would result in an overestimation of fat fraction (60). Therefore, while internal comparisons of our serial data are valid, caution should be exercised when comparing our FFW values to literature values obtained using a different TE.

In a similar vein, care must be used when comparing our MRS cutoff value for clinically significant steatosis to cutoff values in other studies due to differences in both MRS and histologic methodology. In our study, the pathologist deemed steatosis comprising greater than 25% of tissue to be clinically significant. Others have used different MRS parameters and/or different histologic fatty tissue percentages (5—33%) to define clinically important steatosis (16, 61, 62).

Another limitation in the current study was that most patients were treated with FOLFOX which is less likely to be associated with steatosis/steatohepatitis than irinotecan-based regimens (6, 33). The patient population reflects current clinical practice where FOLFOX is the standard-of-care after resection of primary colorectal cancer with high-risk features. The study was motivated in part by our hepatobiliary surgeons who had observed liver abnormalities in this population (63).

Time of day of the MRS exam was not controlled due to the restrictions imposed by patients' schedules. In addition, the patients were only asked to eat lightly on the day of, and fast for two hours prior to the exam because more stringent limits could have affected their well-being on a day when they were also being given chemotherapy. Szczepaniak, et. al. found no difference in hepatic lipids in fasted subjects compared to subjects at 4 hours following a high-fat meal (15). This suggests that our patients' fasting state did not affect our results. Furthermore, the use of the same dietary restrictions and a two-week interval in our reproducibility study in normal volunteers provided a coefficient of variation which reflected potential temporal variations and placed a stringent requirement on the degree of lipid change required for significance.

In conclusion, serial ^{1}H-MR spectroscopy demonstrated that 23% of patients given FOLFOX or HAI-FUDR/IRI developed steatosis after 24 weeks of treatment. Patients whose hepatic lipids increased after 6 weeks of chemotherapy were more likely to complete 24 weeks of treatment with elevated lipids. In future trials of chemotherapy, ^{1}H-MRS could be easily implemented to monitor HTGC. Additionally, the effectiveness of agents designed to ameliorate hepatic steatosis could be non-invasively measured.

Supplementary Material

Refer to Web version on PubMed Central for supplementary material.

$watermark-text
$watermark-text
$watermark-text

Acknowledgments

The authors would like to acknowledge the following physician-collaborators: Diane Reidy-Lagunes, Ki-Young Chung, Zsofia K. Stadler, Neil H. Segal, David P. Kelsen, Raymond Meng, Ronald Dematteo, Martin Weiser, Eileen O'Reilly, and Peter Allen.

Support: This work was supported by NIH R21 CA130226-01

Abbreviations

MRS	magnetic resonance spectroscopy
FOLFOX	a chemotherapy regimen including 5-fluorouracil,folinic acid, and oxaliplatin
FUDR	floxuridine
FFW	ratio of fat to fat plus water
HTGC	hepatic triglycerides
CI	confidence interval
CRC	colorectal cancer
5FU	5-fluorouracil
FOLFIRI	a chemotherapy regimen including 5-fluorouracil, folinic acid, and irinotecan
TR	repetition time
TE	echo time
PRESS	point-resolved spectroscopy
PA	peak area
MR	magnetic resonance
HAI	hepatic arterial infusion
IRI	irinotecan
ROC	receiver operating characteristic
CV	coefficient of variation
ALT	alanine transaminase
BMI	body mass index
CI	confidence interval
HIV	human immunodeficiency virus
HAART	highly active antiretroviral therapy
NS	not significant
US	ultrasound
CT	computerized tomography
GI	gastrointestinal
IFN	interferon

$watermark-text $watermark-text $watermark-text

REFERENCES

1. Saltz LB, Cox JV, Blanke C, Rosen LS, Fehrenbacher L, Moore MJ, Maroun JA, Ackland SP, Locker PK, Pirotta N, Elfring GL, Miller LL. Irinotecan plus fluorouracil and leucovorin for metastatic colorectal cancer. Irinotecan Study Group. N Engl J Med. 2000; 343:905–914. [PubMed: 11006366]
2. Goldberg RM, Sargent DJ, Morton RF, Fuchs CS, Ramanathan RK, Williamson SK, Findlay BP, Pitot HC, Alberts SR. A randomized controlled trial of fluorouracil plus leucovorin, irinotecan, and oxaliplatin combinations in patients with previously untreated metastatic colorectal cancer. J Clin Oncol. 2004; 22:23–30. [PubMed: 14665611]
3. Adam R, Delvart V, Pascal G, Valeanu A, Castaing D, Azoulay D, Giacchetti S, Paule B, Kunstlinger F, Ghemard O, Levi F, Bismuth H. Rescue surgery for unresectable colorectal liver metastases downstaged by chemotherapy: a model to predict long-term survival. Ann Surg. 2004; 240:644–657. discussion 657–648. [PubMed: 15383792]
4. Fernandez FG, Ritter J, Goodwin JW, Linehan DC, Hawkins WG, Strasberg SM. Effect of steatohepatitis associated with irinotecan or oxaliplatin pretreatment on resectability of hepatic colorectal metastases. J Am Coll Surg. 2005; 200:845–853. [PubMed: 15922194]
5. Cleary JM, Tanabe KT, Lauwers GY, Zhu AX. Hepatic toxicities associated with the use of preoperative systemic therapy in patients with metastatic colorectal adenocarcinoma to the liver. Oncologist. 2009; 14:1095–1105. [PubMed: 19880627]
6. Vauthey JN, Pawlik TM, Ribero D, Wu TT, Zorzi D, Hoff PM, Xiong HQ, Eng C, Lauwers GY, Mino-Kenudson M, Risio M, Muratore A, Capussotti L, Curley SA, Abdalla EK. Chemotherapy regimen predicts steatohepatitis and an increase in 90-day mortality after surgery for hepatic colorectal metastases. J Clin Oncol. 2006; 24:2065–2072. [PubMed: 16648507]
7. Pawlik TM, Olino K, Gleisner AL, Torbenson M, Schulick R, Choti MA. Preoperative chemotherapy for colorectal liver metastases: impact on hepatic histology and postoperative outcome. J Gastrointest Surg. 2007; 11:860–868. [PubMed: 17492335]
8. Chun YS, Laurent A, Maru D, Vauthey JN. Management of chemotherapy-associated hepatotoxicity in colorectal liver metastases. Lancet Oncol. 2009; 10:278–286. [PubMed: 19261256]
9. Rubbia-Brandt L, Audard V, Sartoretti P, Roth AD, Brezault C, Le Charpentier M, Dousset B, Morel P, Soubrane O, Chaussade S, Mentha G, Terris B. Severe hepatic sinusoidal obstruction associated with oxaliplatin-based chemotherapy in patients with metastatic colorectal cancer. Ann Oncol. 2004; 15:460–466. [PubMed: 14998849]
10. Bilchik AJ, Poston G, Curley SA, Strasberg S, Saltz L, Adam R, Nordlinger B, Rougier P, Rosen LS. Neoadjuvant chemotherapy for metastatic colon cancer: a cautionary note. J Clin Oncol. 2005; 23:9073–9078. [PubMed: 16361615]
11. Kooby DA, Fong Y, Suriawinata A, Gonen M, Allen PJ, Klimstra DS, DeMatteo RP, D'Angelica M, Blumgart LH, Jarnagin WR. Impact of steatosis on perioperative outcome following hepatic resection. J Gastrointest Surg. 2003; 7:1034–1044. [PubMed: 14675713]
12. McCormack L, Petrowsky H, Jochum W, Furrer K, Clavien PA. Hepatic steatosis is a risk factor for postoperative complications after major hepatectomy: a matched case-control study. Ann Surg. 2007; 245:923–930. [PubMed: 17522518]
13. Vetelainen R, van Vliet A, Gouma DJ, van Gulik TM. Steatosis as a risk factor in liver surgery. Ann Surg. 2007; 245:20–30. [PubMed: 17197961]
14. Longo R, Pollesello P, Ricci C, Masutti F, Kvam BJ, Bercich L, Croce LS, Grigolato P, Paoletti S, de Bernard B, et al. Proton MR spectroscopy in quantitative in vivo determination of fat content in human liver steatosis. J Magn Reson Imaging. 1995; 5:281–285. [PubMed: 7633104]
15. Szczepaniak LS, Nurenberg P, Leonard D, Browning JD, Reingold JS, Grundy S, Hobbs HH, Dobbins RL. Magnetic resonance spectroscopy to measure hepatic triglyceride content: prevalence of hepatic steatosis in the general population. American Journal of Physiology - Endocrinology And Metabolism. 2005; 288:E462–E468. [PubMed: 15339742]
16. Urdzik J, Bjerner T, Wanders A, Weis J, Duraj F, Haglund U, Noren A. The value of pre-operative magnetic resonance spectroscopy in the assessment of steatohepatitis in patients with colorectal liver metastasis. J Hepatol. 2011

$watermark-text
$watermark-text
$watermark-text

17. Hajek M, Dezortova M, Wagnerova D, Skoch A, Voska L, Hejlova I, Trunecka P. MR spectroscopy as a tool for in vivo determination of steatosis in liver transplant recipients. MAGMA. 2011; 24:297–304. [PubMed: 21744232]
18. Roldan-Valadez E, Favila R, Martinez-Lopez M, Uribe M, Rios C, Mendez-Sanchez N. In vivo 3T spectroscopic quantification of liver fat content in nonalcoholic fatty liver disease: Correlation with biochemical method and morphometry. J Hepatol. 2010; 53:732–737. [PubMed: 20594607]
19. Hines CDG, Frydrychowicz A, Hamilton G, Tudorascu D, Vigen K, Yu H, McKenzie C, Sirlin C, Brittain J, Reeder S. T(1) independent, T(2) (*) corrected chemical shift based fat-water separation with multi-peak fat spectral modeling is an accurate and precise measure of hepatic steatosis. Journal of Magnetic Resonance Imaging. 2011; 33:873–881. [PubMed: 21448952]
20. Meisamy S, Hines CD, Hamilton G, Sirlin CB, McKenzie CA, Yu H, Brittain JH, Reeder SB. Quantification of hepatic steatosis with T1-independent, T2-corrected MR imaging with spectral modeling of fat: blinded comparison with MR spectroscopy. Radiology. 2011; 258:767–775. [PubMed: 21248233]
21. Yokoo T, Bydder M, Hamilton G, Middleton MS, Gamst AC, Wolfson T, Hassanein T, Patton HM, Lavine JE, Schwimmer JB, Sirlin CB. Nonalcoholic fatty liver disease: diagnostic and fat-grading accuracy of low-flip-angle multiecho gradient-recalled-echo MR imaging at 1.5 T. Radiology. 2009; 251:67–76. [PubMed: 19221054]
22. Yu H, Shimakawa A, Hines CD, McKenzie CA, Hamilton G, Sirlin CB, Brittain JH, Reeder SB. Combination of complex-based and magnitude-based multiecho water-fat separation for accurate quantification of fat-fraction. Magn Reson Med. 2011; 66:199–206. [PubMed: 21695724]
23. Springer F, Ehehalt S, Sommer J, Ballweg V, Machann J, Binder G, Claussen CD, Schick F. Assessment of relevant hepatic steatosis in obese adolescents by rapid fat-selective GRE imaging with spatial-spectral excitation: a quantitative comparison with spectroscopic findings. Eur Radiol. 2011; 21:816–822. [PubMed: 20890760]
24. Bottomley, P., inventor. Selective volume method for performing localized NMR spectroscopy. USA patent. 4,480,228. 1984.
25. Hamilton G, Yokoo T, Bydder M, Cruite I, Schroeder ME, Sirlin CB, Middleton MS. In vivo characterization of the liver fat 1H MR spectrum. NMR in Biomedicine. 2011; 24:784–790. [PubMed: 21834002]
26. Gönen, M., editor. Analyzing Receiver Operating Characteristic Curves Using SAS. NC: SAS Press; 2007.
27. Obuchowski NA. Nonparametric analysis of clustered ROC curve data. Biometrics. 1997; 53:567–578. [PubMed: 9192452]
28. Sorensen P, Edal AL, Madsen EL, Fenger C, Poulsen MR, Petersen OF. Reversible hepatic steatosis in patients treated with interferon alfa-2a and 5-fluorouracil. Cancer. 1995; 75:2592–2596. [PubMed: 7736406]
29. Zeiss J, Merrick HW, Savolaine ER, Woldenberg LS, Kim K, Schlembach PJ. Fatty liver change as a result of hepatic artery infusion chemotherapy. Am J Clin Oncol. 1990; 13:156–160. [PubMed: 2138409]
30. Peppercorn PD, Reznek RH, Wilson P, Slevin ML, Gupta RK. Demonstration of hepatic steatosis by computerized tomography in patients receiving 5-fluorouracil-based therapy for advanced colorectal cancer. British Journal of Cancer. 1998; 77:2008–2011. [PubMed: 9667683]
31. Moertel CG, Fleming TR, Macdonald JS, Haller DG, Laurie JA. Hepatic toxicity associated with fluorouracil plus levamisole adjuvant therapy. Journal of clinical oncology. 1993; 11:2386–2390. [PubMed: 8246027]
32. Ryan P, Nanji S, Pollett A, Moore M, Moulton CA, Gallinger S, Guindi M. Chemotherapy-induced liver injury in metastatic colorectal cancer: semiquantitative histologic analysis of 334 resected liver specimens shows that vascular injury but not steatohepatitis is associated with preoperative chemotherapy. Am J Surg Pathol. 2010; 34:784–791. [PubMed: 20421779]
33. Aloia T, Sebagh M, Plasse M, Karam V, Levi F, Giacchetti S, Azoulay D, Bismuth H, Castaing D, Adam R. Liver histology and surgical outcomes after preoperative chemotherapy with fluorouracil plus oxaliplatin in colorectal cancer liver metastases. J Clin Oncol. 2006; 24:4983–4990. [PubMed: 17075116]

$watermark-text
$watermark-text
$watermark-text

34. Makowiec F, Mohrle S, Neeff H, Drognitz O, Illerhaus G, Opitz OG, Hopt UT, zur Hausen A. Chemotherapy, liver injury, and postoperative complications in colorectal liver metastases. J Gastrointest Surg. 2011; 15:153–164. [PubMed: 21061183]
35. Browning JD, Szczepaniak LS, Dobbins R, Nuremberg P, Horton JD, Cohen JC, Grundy SM, Hobbs HH. Prevalence of hepatic steatosis in an urban population in the United States: impact of ethnicity. Hepatology. 2004; 40:1387–1395. [PubMed: 15565570]
36. Thomas EL, Hamilton G, Patel N, O'Dwyer R, Dore CJ, Goldin RD, Bell JD, Taylor-Robinson SD. Hepatic triglyceride content and its relation to body adiposity: a magnetic resonance imaging and proton magnetic resonance spectroscopy study. Gut. 2005; 54:122–127. [PubMed: 15591516]
37. Kotronen A, Westerbacka J, Bergholm R, Pietilainen KH, Yki-Jarvinen H. Liver fat in the metabolic syndrome. J Clin Endocrinol Metab. 2007; 92:3490–3497. [PubMed: 17595248]
38. Rijzewijk L, van der Meer R, Lubberink M, Lamb H, Romijn J, de Roos A, Twisk J, Heine R, Lammertsma A, Smit JWA, Diamant M. Liver fat content in type 2 diabetes: relationship with hepatic perfusion and substrate metabolism. Diabetes. 2010; 59:2747–2754. [PubMed: 20693345]
39. van Werven J, Marsman H, Nederveen A, Smits N, ten Kate FJ, van Gulik T, Stoker J. Assessment of hepatic steatosis in patients undergoing liver resection: comparison of US, CT, T1-weighted dual-echo MR imaging, and point-resolved 1H MR spectroscopy. Radiology. 2010; 256:159–168. [PubMed: 20574093]
40. Petersen KF, Dufour S, Befroy D, Lehrke M, Hendler RE, Shulman GI. Reversal of nonalcoholic hepatic steatosis, hepatic insulin resistance, and hyperglycemia by moderate weight reduction in patients with type 2 diabetes. Diabetes. 2005; 54:603–608. [PubMed: 15734833]
41. Cowin GJ, Jonsson JR, Bauer JD, Ash S, Ali A, Osland EJ, Purdie DM, Clouston AD, Powell EE, Galloway GJ. Magnetic resonance imaging and spectroscopy for monitoring liver steatosis. J Magn Reson Imaging. 2008; 28:937–945. [PubMed: 18821619]
42. Heath M, Kow L, Slavotinek J, Valentine R, Toouli J, Thompson C. Abdominal adiposity and liver fat content 3 and 12 months after gastric banding surgery. Metabolism, clinical and experimental. 2009; 58:753–758. [PubMed: 19375765]
43. Thomas EL, Brynes A, Hamilton G, Patel N, Spong A, Goldin R, Frost G, Bell J, Taylor-Robinson S. Effect of nutritional counselling on hepatic, muscle and adipose tissue fat content and distribution in non-alcoholic fatty liver disease. World Journal of Gastroenterology. 2006; 12:5813–5819. [PubMed: 17007047]
44. Belfort R, Harrison S, Brown K, Darland C, Finch J, Hardies J, Balas B, Gastaldelli A, Tio F, Pulcini J, Berria R, Ma J, Dwivedi S, Havranek R, Fincke C, DeFronzo R, Bannayan G, Schenker S, Cusi K. A placebo-controlled trial of pioglitazone in subjects with nonalcoholic steatohepatitis. The New England journal of medicine. 2006; 355:2297–2307. [PubMed: 17135584]
45. Allen-Mersh TG, Earlam S, Fordy C, Abrams K, Houghton J. Quality of life and survival with continuous hepatic-artery floxuridine infusion for colorectal liver metastases. Lancet. 1994; 344:1255–1260. [PubMed: 7526096]
46. Kemeny N, Huang Y, Cohen AM, Shi W, Conti JA, Brennan MF, Bertino JR, Turnbull AD, Sullivan D, Stockman J, Blumgart LH, Fong Y. Hepatic arterial infusion of chemotherapy after resection of hepatic metastases from colorectal cancer. N Engl J Med. 1999; 341:2039–2048. [PubMed: 10615075]
47. Power DG, Kemeny NE. Role of adjuvant therapy after resection of colorectal cancer liver metastases. J Clin Oncol. 2010; 28:2300–2309. [PubMed: 20368552]
48. House MG, Kemeny NE, Gonen M, Fong Y, Allen PJ, Paty PB, Dematteo RP, Blumgart LH, Jarnagin WR, D'Angelica M I. Comparison of Adjuvant Systemic Chemotherapy With or Without Hepatic Arterial Infusional Chemotherapy After Hepatic Resection for Metastatic Colorectal Cancer. Ann Surg. 2011; 254:851–856. [PubMed: 21975318]
49. Kingham TP, D'Angelica M, Kemeny N. Role of intra-arterial hepatic chemotherapy in the treatment of colorectal cancer metastases. Journal of surgical oncology. 2010; 102:988–995. [PubMed: 21166003]
50. Mikalauskas S, Mikalauskiene L, Bruns H, Nickkholgh A, Hoffmann K, Longerich T, Strupas K, Bchler M, Schemmer P. Dietary glycine protects from chemotherapy-induced hepatotoxicity. Amino acids. 2011; 40:1139–1150. [PubMed: 20852907]

$watermark-text

$watermark-text

$watermark-text

51. Angulo P. Nonalcoholic fatty liver disease. The New England journal of medicine. 2002; 346:1221–1231. [PubMed: 11961152]
52. Joshi D, O'Grady J, Dieterich D, Gazzard B, Agarwal K. Increasing burden of liver disease in patients with HIV infection. Lancet. 2011; 377:1198–1209. [PubMed: 21459211]
53. Sulkowski MS, Mehta SH, Torbenson M, Afdhal NH, Mirel L, Moore RD, Thomas DL. Hepatic steatosis and antiretroviral drug use among adults coinfected with HIV and hepatitis C virus. AIDS. 2005; 19:585–592. [PubMed: 15802977]
54. Berretta M, Lleshi A, Cappellani A, Bearz A, Spina M, Talamini R, Cacopardo B, Nunnari G, Montesarchio V, Izzi I, Lanzafame M, Nasti G, Basile F, Berretta S, Fisichella R, Schiantarelli CC, Garlassi E, Ridolfo A, Guella L, Tirelli U. Oxaliplatin based chemotherapy and concomitant highly active antiretroviral therapy in the treatment of 24 patients with colorectal cancer and HIV infection. Current HIV research. 2010; 8:218–222. [PubMed: 20158458]
55. Machann J, Thamer C, Schnoedt B, Stefan N, Haring HU, Claussen CD, Fritsche A, Schick F. Hepatic lipid accumulation in healthy subjects: a comparative study using spectral fat-selective MRI and volume-localized 1H-MR spectroscopy. Magn Reson Med. 2006; 55:913–917. [PubMed: 16506186]
56. Qayyum A, Nystrom M, Noworolski SM, Chu P, Mohanty A, Merriman R. MRI steatosis grading: development and initial validation of a color mapping system. AJR Am J Roentgenol. 2012; 198:582–588. [PubMed: 22357996]
57. Reeder SB, Cruite I, Hamilton G, Sirlin CB. Quantitative Assessment of Liver Fat with Magnetic Resonance Imaging and Spectroscopy. J Magn Reson Imaging. 2011; 34:729–749. [PubMed: 21928307]
58. Springer F, Machann J, Schwenzer NF, Ballweg V, Wurslin C, Schneider JH, Fritsche A, Claussen CD, Schick F. Quantitative assessment of intrahepatic lipids using fat-selective imaging with spectral-spatial excitation and in-/opposed-phase gradient echo imaging techniques within a study population of extremely obese patients: feasibility on a short, wide-bore MR scanner. Invest Radiol. 2010; 45:484–490. [PubMed: 20479651]
59. Pineda N, Sharma P, Xu Q, Hu X, Vos M, Martin DR. Measurement of hepatic lipid: high-speed T2-corrected multiecho acquisition at 1H MR spectroscopy--a rapid and accurate technique. Radiology. 2009; 252:568–576. [PubMed: 19546430]
60. Hamilton G, Middleton MS, Bydder M, Yokoo T, Schwimmer JB, Kono Y, Patton HM, Lavine JE, Sirlin CB. Effect of PRESS and STEAM sequences on magnetic resonance spectroscopic liver fat quantification. J Magn Reson Imaging. 2009; 30:145–152. [PubMed: 19557733]
61. McPherson S, Jonsson JR, Cowin GJ, O'Rourke P, Clouston AD, Volp A, Horsfall L, Jothimani D, Fawcett J, Galloway GJ, Benson M, Powell EE. Magnetic resonance imaging and spectroscopy accurately estimate the severity of steatosis provided the stage of fibrosis is considered. J Hepatol. 2009; 51:389–397. [PubMed: 19505740]
62. van Werven JR. Hepatic unsaturated fatty acids in patients with non-alcoholic fatty liver disease assessed by 3.0T MR spectroscopy. European journal of radiology. 2010; 75:e102–e107. [PubMed: 20116951]
63. Fong Y, Bentrem D. CASH (Chemotherapy-Associated Steatohepatitis) costs. Annals of surgery. 2006; 243:8–9. [PubMed: 16371729]

$watermark-text
$watermark-text
$watermark-text

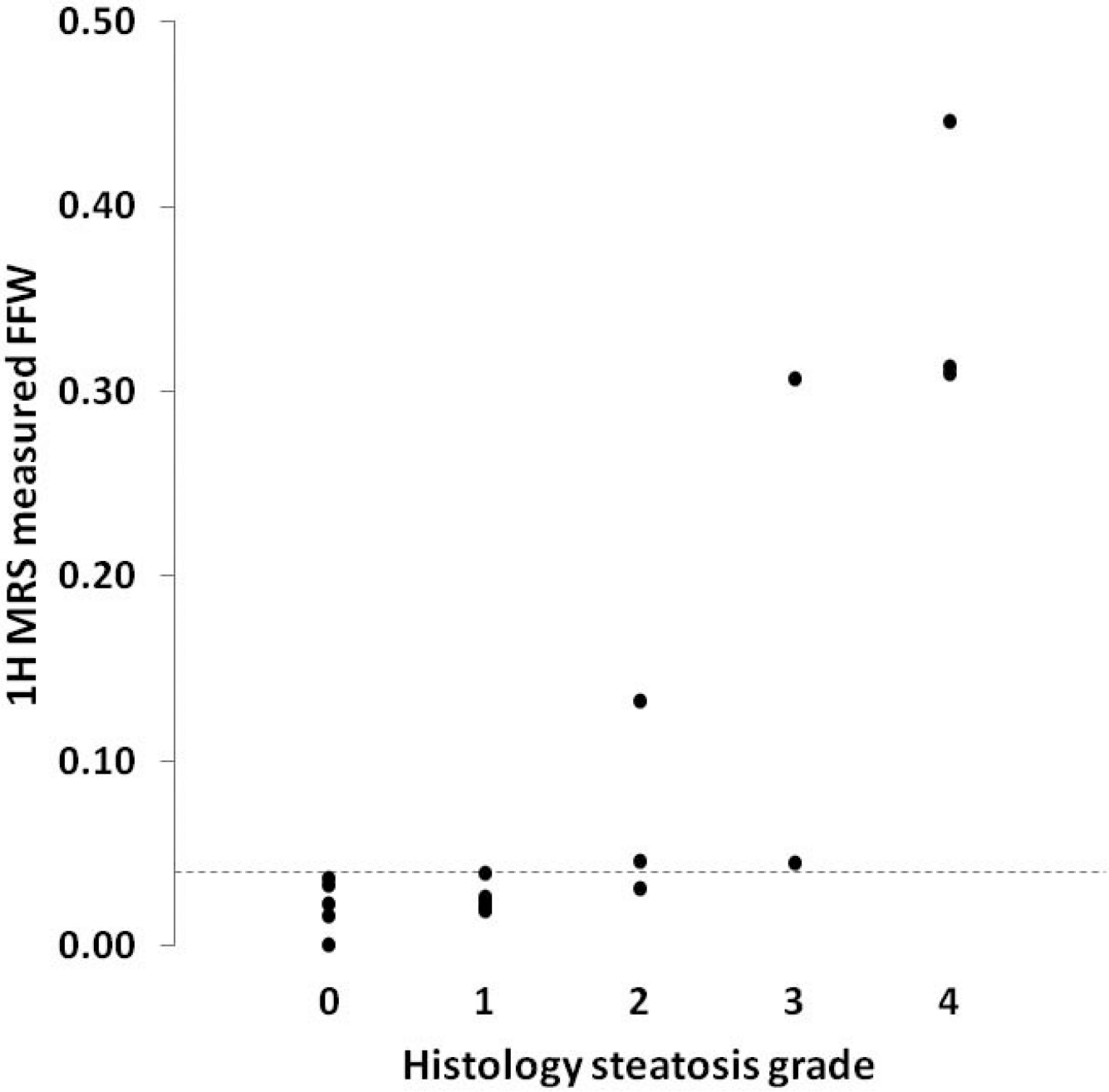

Figure 1.
Fat-to-(fat+water) ratio (FFW) vs. histologic liver steatosis grade in 18 patients (19 tissue samples). Clinical steatosis was defined as grade 2 or higher. The dashed line indicates a cut-point of FFW = 0.039 for clinically significant steatosis based on the ROC curve generated from our spectroscopy and histology data.

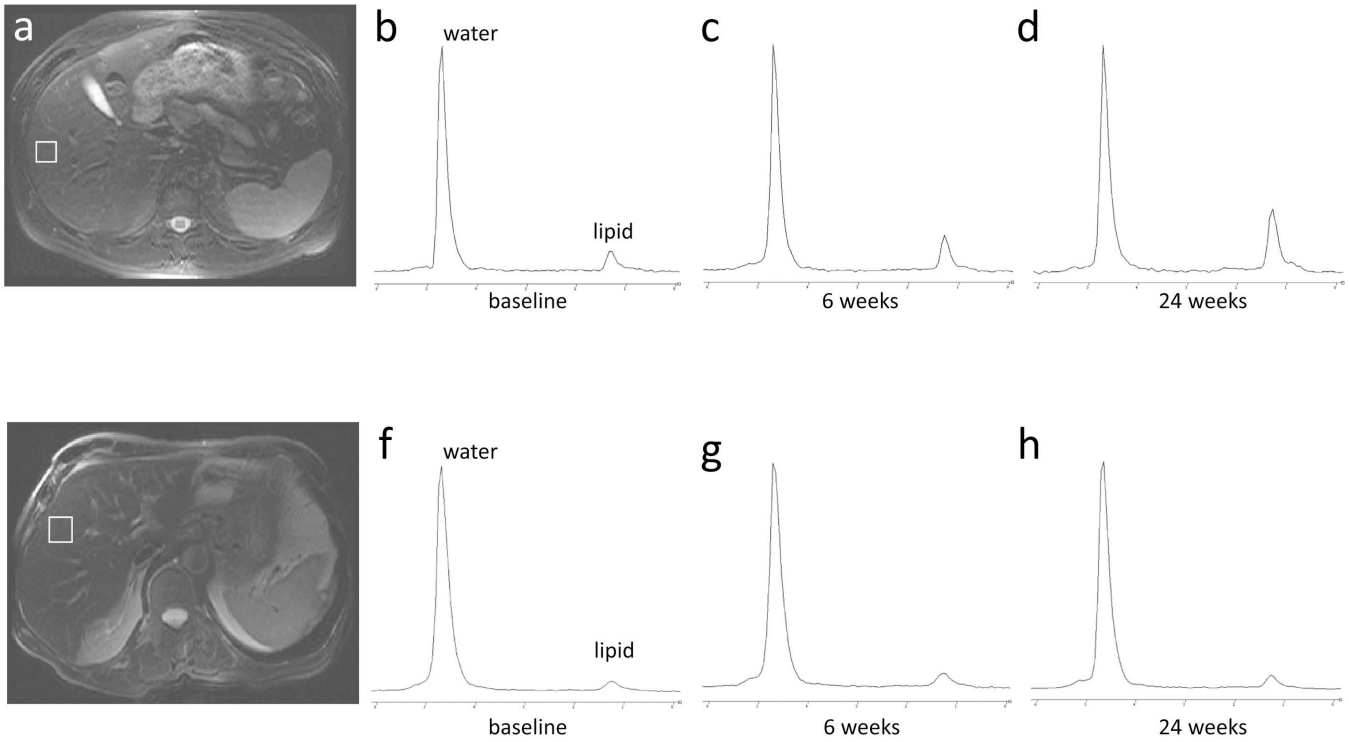

Figure 2.

^{1}H MRS volume-of-interest (a, e) and spectra acquired from patients 15 and 5 who were treated with FOLFOX. Spectra are from baseline (b,f), 3 cycles/6 weeks (c,g) and 12 cycles/24 weeks (d, h). The FFW values for patient 15 were 0.095, 0.150 and 0.260 (b–d). The FFW values for patient 5 were 0.076, 0.061 and 0.049 (f–h). The dimensions of the volume-of-interest were 20 × 20 × 20 mm^3. Breath-held spectral acquisition parameters were: repetition time (TR) = 5s, echo time (TE) = 40ms, spectral width (SW) = 2000 Hz, spectral points = 512, acquisitions = 4.

$watermark-text
$watermark-text
$watermark-text

$watermark-text

$watermark-text

$watermark-text

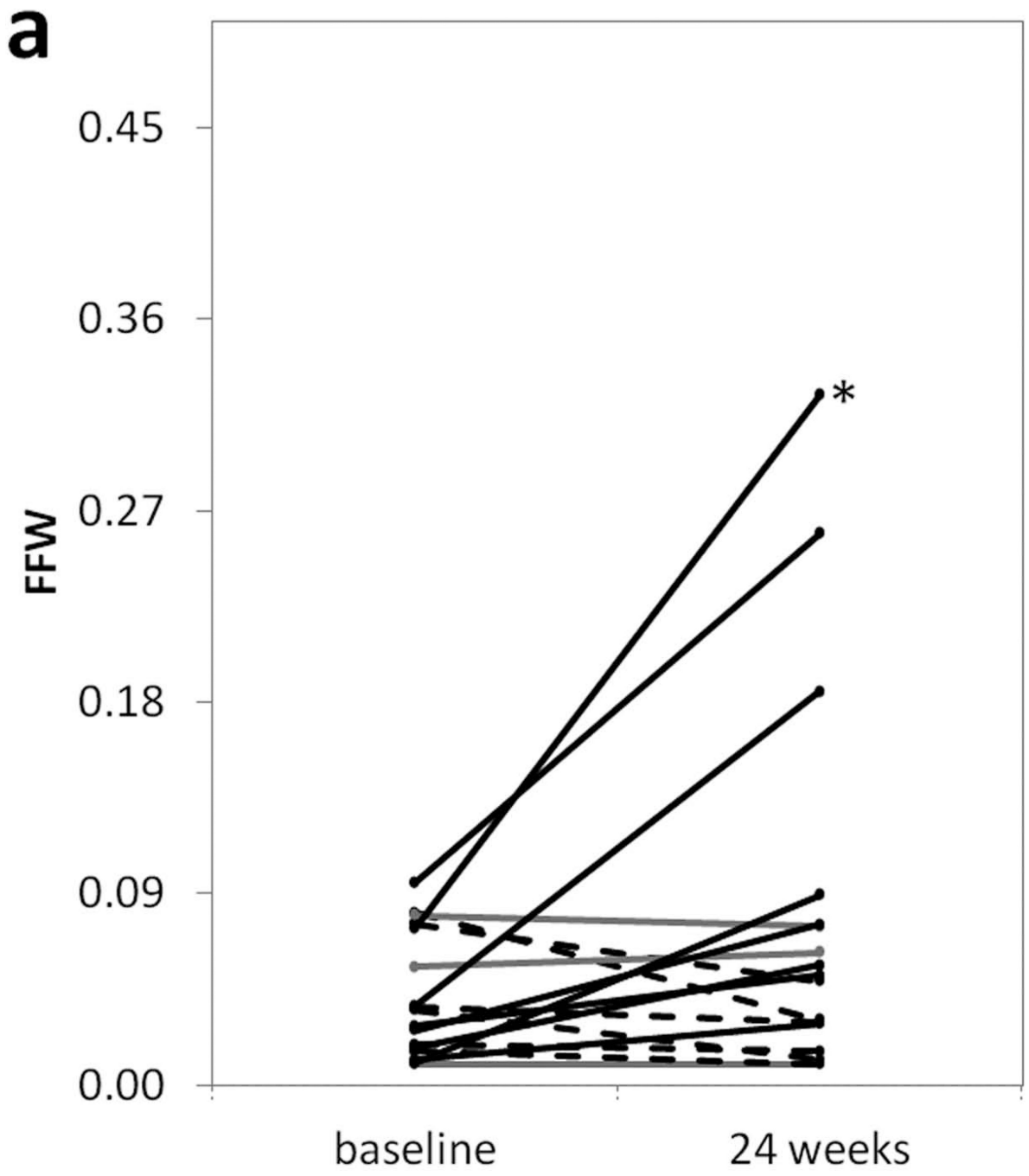

$watermark-text
$watermark-text
$watermark-text

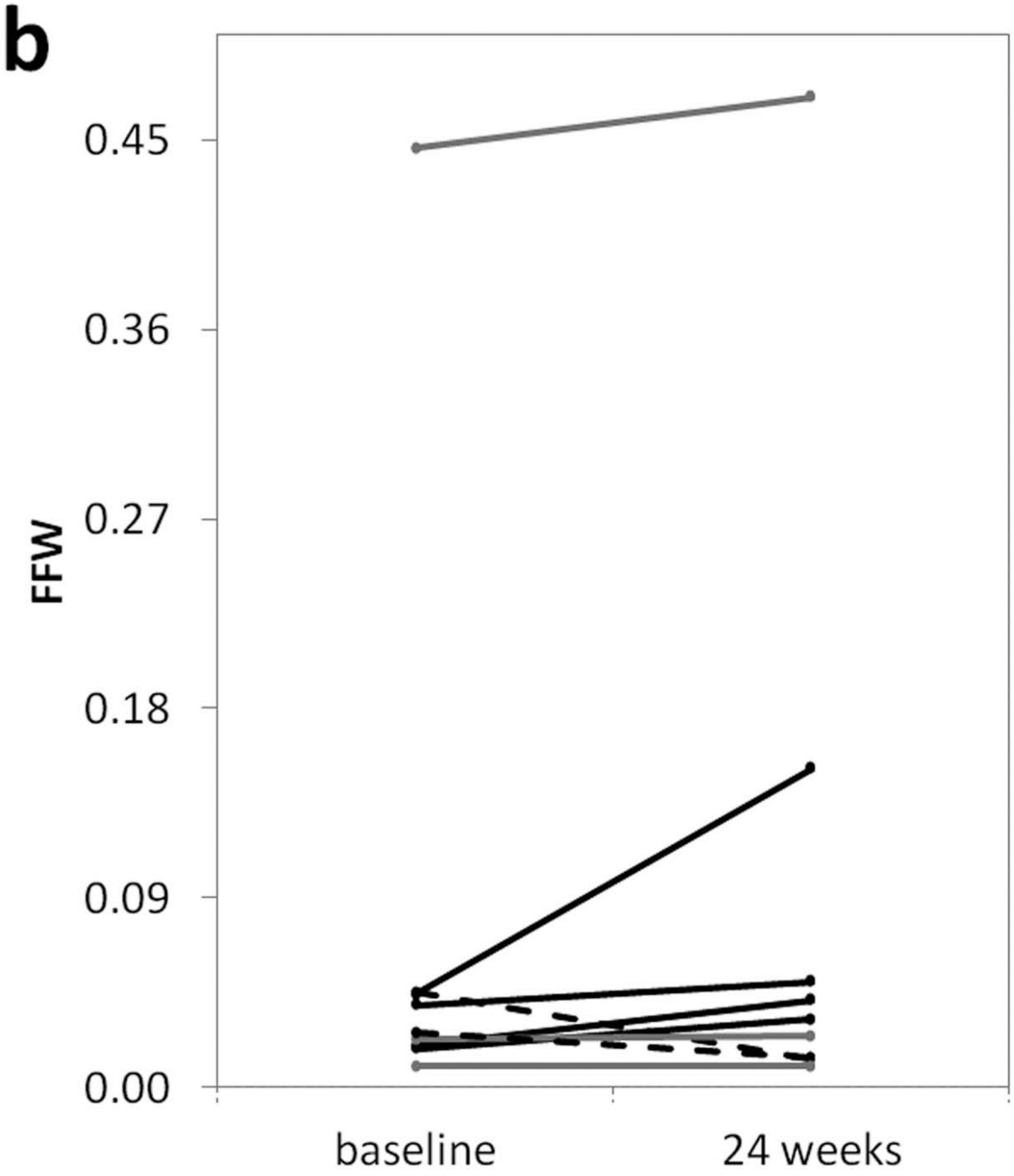

Figure 3.
HTGC changes from baseline to post-24 weeks of FOLFOX (a) or FUDR/Iri (b) treatment. Black line = FFW increase greater than 15%; dashed line = FFW decrease greater than 15%, gray line = FFW change less than 15%. *Patient 12 was treated concurrently with anti-HIV HAART therapy.

$watermark-text

$watermark-text

$watermark-text

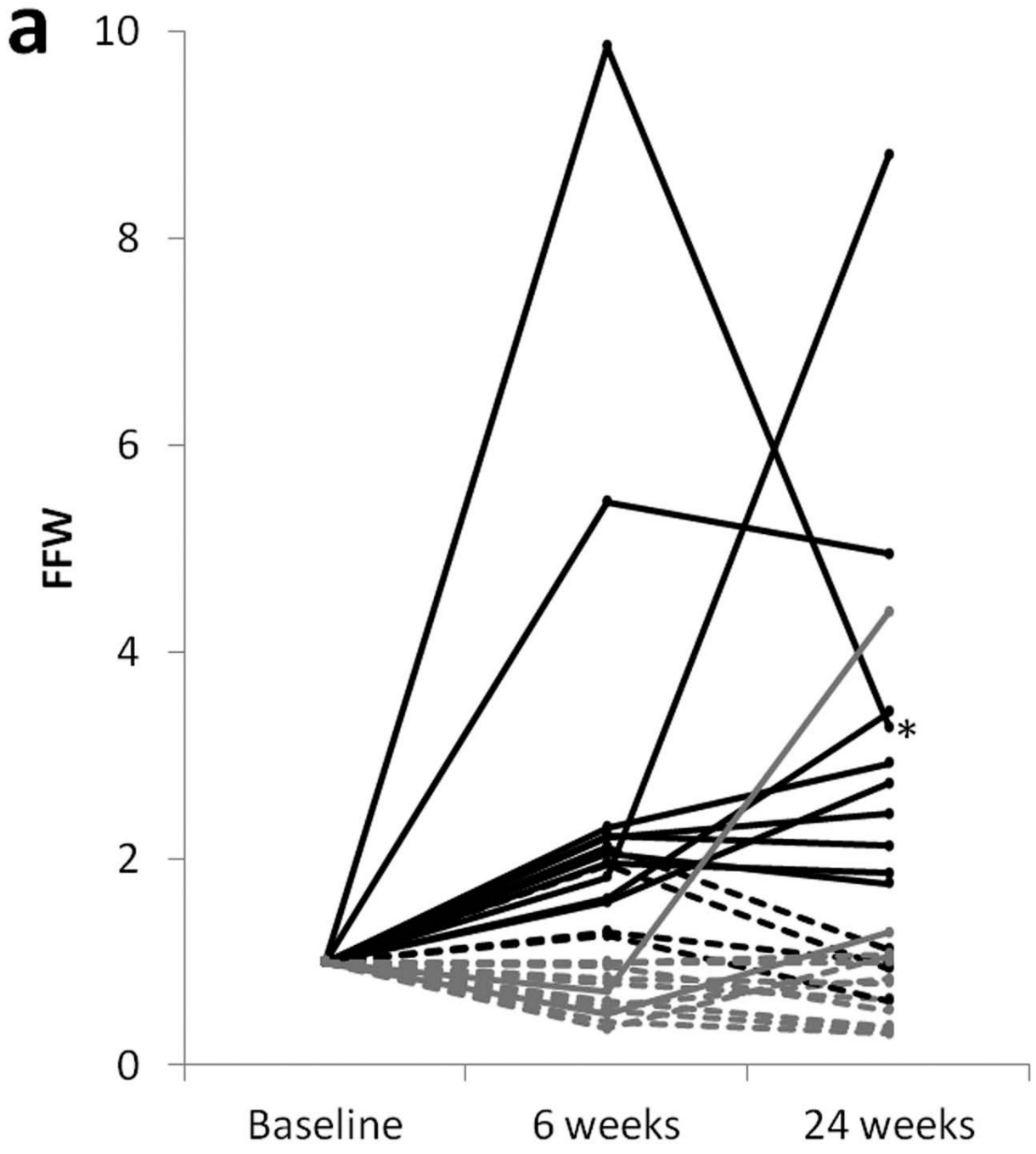

$watermark-text
$watermark-text
$watermark-text

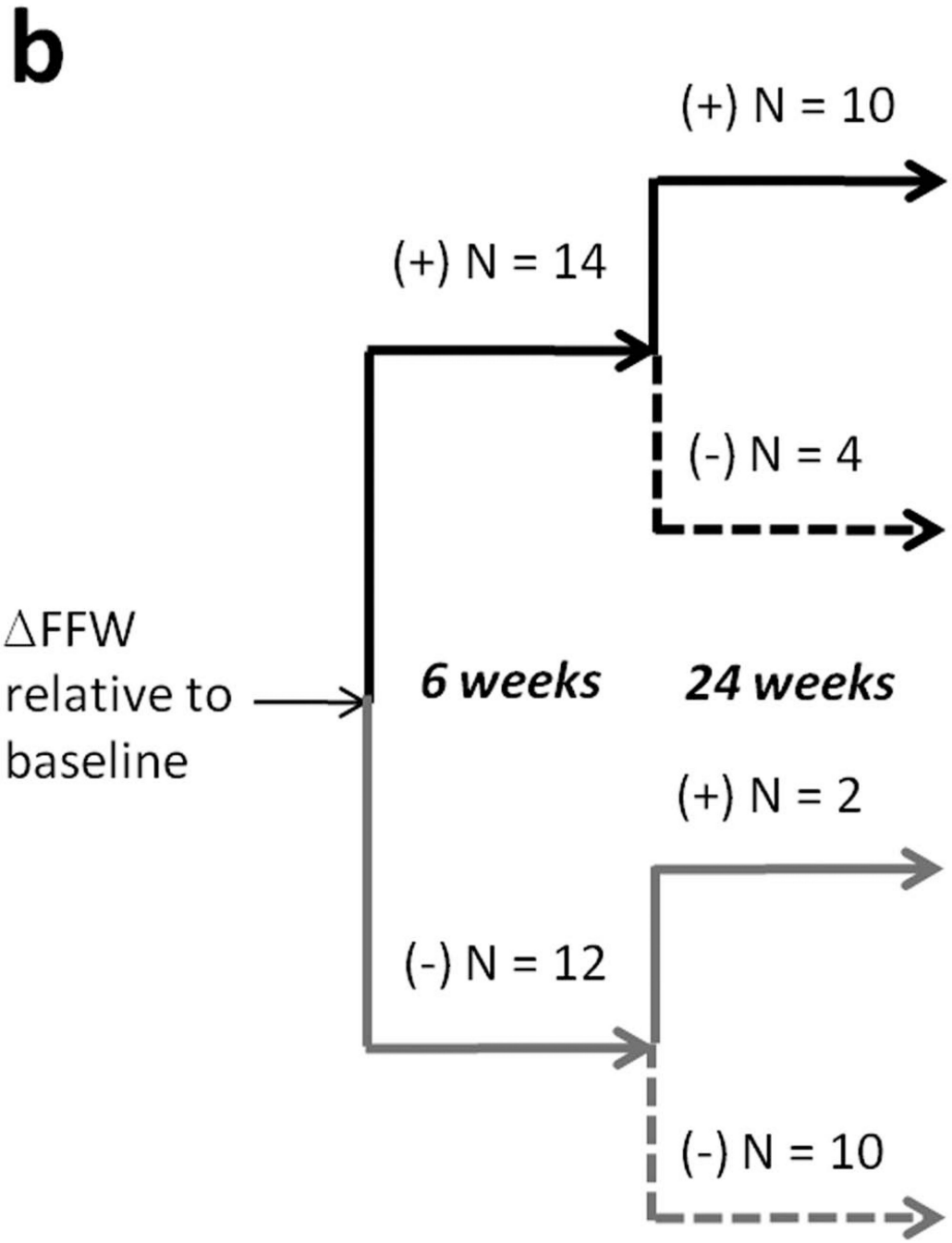

Figure 4.

A) Baseline, 6-week, and 24-week FFW measurements for 26 patients normalized with respect to their baseline values. Line color indicates change in FFW after 6 weeks of chemotherapy: black solid line = FFW increase greater than 15% at 6 weeks and remained elevated at 24 weeks compared to baseline; black dashed line = FFW increase greater than 15%, but returned to within 15% of baseline at 24 weeks; gray solid line = FFW change less than 15% at 6 weeks but increased > 15% at 24 weeks, gray dashed line < 15% change at both 6 and 24 weeks. *The final ^{1}H-MRS data point from patient 19 was acquired 3 months after cessation of chemotherapy. B) Diagram of patient FFW changes during chemotherapy with branching determined by increase (+) or no change/decrease (−) in FFW relative to

baseline. Primary branching was determined by the FFW change at 6 weeks relative to baseline. For example, 14 patients had increased FFW at 6-weeks relative to baseline, while 12 patients had unchanged or decreased FFW values after 6 weeks. Secondary branching was determined by the FFW change at 24 weeks relative to baseline.

$watermark-text
$watermark-text
$watermark-text

$watermark-text $watermark-text $watermark-text

Table 1

Clinical characteristics of 32 patients who underwent FOLFOX or HAI-FUDR/IRI treatment. ALT values are reported due to their association with steatosis and steatohepatitis. Abnormal values are in bold text.

Patient	Gender	Age	Stage of primary cancer	Liver metastases	Prior chemotherapy regimen (cycles)	BMI (kg/m^2)	ALT (U/L)
FOLFOX Group							
1	f	77	T3N1M0 Stage III colon	No	—	21.8	31
2	f	51	T3N2M0 stage IV colon	No	—	20.5	25
3	f	67	T3N0M0 stage IIA-III colon	No	—	22.4	16
4[a]	f	67	T2N1M0 Stage III rectal	No	—	24.5	18
5	m	62	T1N1M0 stage III rectal	No	—	23.0	16
6	m	68	T3N2M0 Stage III colon	No	—	26.7	27
7	f	38	T3N2M0 stage III colon	No	—	26.2	14
8[b]	m	58	T3N2M0 stage III-IV colon	unresectable	FOLFIRI(12)	36.9	**116**
9	m	47	T3N2M0 stage III colon	No	—	29.4	28
10	m	44	T3N0M1 stage IV colon	resected	—	32.0	30
11	m	46	T2N0M1 stage IV colon	No	—	32.0	18
12	m	59	T3N1M0 stage III colon	No	—	23.6	12
13	f	29	T4N2M0 stage III colon	No	—	16.9	15
14	f	71	T4N0M0 stage II colon	No	—	17.5	33
15	m	47	T1N1M0 stage III colon	No	—	29.7	**50**
16	m	45	T3N1M0 stage III colon	No	—	26.4	**43**
17	m	47	T4N1M1 stage IV colon	No	—	22.4	29
18	f	57	T3N0M0 stage II colon	No	—	35.7	24
19	m	45	T3N1M0 stage III colon	No	—	25.5	12
20	m	58	T4N1M0 stage III colon	No	—	21.4	18
21	m	37	T4N0M0 stage II colon	No	—	26.4	18
HAI-FUDR/IRI Group							
22	f	50	stage IV colon, primary intact	unresectable	FOLFOX (12)	30.2	19

$watermark-text $watermark-text $watermark-text

Patient	Gender	Age	Stage of primary cancer	Liver metastases	Prior chemotherapy regimen (cycles)	BMI (kg/m^2)	ALT (U/L)
23	M	42	T3N2M1 stage IV colon	unresectable	FOLFOX(3)/ FOLFIRI(15)	25.8	27
24	f	38	T3N2M1 stage IV colon	unresectable	FOLFOX (14)	26.7	**41**
25	f	64	T3N2M1 stage IV colon	resected	Oxali(2)/Xeloda(3)	27.9	**56**
26	m	62	T3N1M1 stage IV colon	unresectable	FOLFOX (4)	28.4	31
27	f	65	T3N1M1 stage IV colon	resected	FOLFOX (9) FOLFIRI (12)	16.7	26
28	m	44	stage IV rectal, primary intact	unresectable	FOLFOXIRI(10)	25.2	31
29	f	54	T2N1M0 stage III colon	unresectable	FOLFOX (4)	35.3	31
30	f	57	T2N0M0 stage II colon	resected	FOLFOXIRI (3)	29.7	**36**
31	m	62	T3N2M1 stage IV colon	unresectable	FOLFOX (11)	25.2	**36**
32	f	65	T3N2M1 stage IV colon	resected	FOLFOX (12)	23.9	18
33	F	56	T2N1Mx stage IV colon	resected	FOLFOX (12)	24.3	34
34	m	40	T1N1M1 stage IV colon	unresectable	FOLFOX (12)	22.0	**59**

[a]Patient underwent removal of the primary colon tumor after 6 cycles (12 weeks) of FOLFOX

[b]Patient developed liver metastases after colectomy and was treated with FOLFIRI prior to entrance in our study. In our serial study, he initially received 10 cycles of FOLFOX, and then switched to FOLFORI/avastin for another 3 cycles due to disease progression in the liver.

$watermark-text $watermark-text $watermark-text

Table 2

HTGC, BMI and serum alanine transaminase (ALT) at baseline and after 24 weeks of treatment in 8 patients who had conversion of liver steatotic status during chemotherapy.

Pt. No.	Current chemo	Steatosis Change	FFW			BMI (kg/m^2)			ALT (U/L)	
			baseline	24 wk	% change	baseline	24 wk	% change	baseline	24 wk
11	FOLFOX	−/+	2.77E-2	5.15E-2	86%	32.0	35.5	11%	18	30
14	FOLFOX	−/+	1.01E-2	8.93E-2	782%	17.5	18.0	3%	33	29
18	FOLFOX	−/+	3.74E-2	1.85E-1	395%	35.7	35.0	0%	24	25
19	FOLFOX	−/+	1.72E-2	5.64E-2	227%	25.5	26.5	4%	12	21
21	FOLFOX	−/+	2.58E-2	7.53E-2	192%	26.4	25.7	−2%	18	28
27	FUDR/iri	−/+	1.96E-2	4.16E-2	112%	16.7	17.5	5%	26[a]	25[a]
1	FOLFOX	+/−	8.08E-2	3.05E-2	−62%	21.8	21.0	−4%	31	21
30	FUDR/iri	+/−	4.51E-2	1.39E-2	−69%	29.7	32.2	5%	30[a]	23[a]

[a]The baseline and 24 week ALT values in the FUDR/IRI patients were not compared to each other because ALT levels may be influenced by the presence of tumor in the liver and as well as the hepatic arterial infusion of FUDR.