Salpingectomy for Repeated Embryo Nonimplantation After In Vitro Fertilization in Patients with Severe Tubal Factor Infertility

H. DECHAUD,[1,3] T. ANAHORY,[2] N. ALIGIER,[1] F. ARNAL,[2] H. HUMEAU,[2] and B. HEDON[1]

Submitted: October 1, 1999
Accepted: December 28, 1999

Purpose: *To evaluate the impact of salpingectomy on the rates of embryo implantation and pregnancy in patients with severe, irreversible tubal factor sterility.*
Methods: *A retrospective study of patients with repeated failure of in vitro fertilization due to nonimplantation of the embryo. Seventy-two patients with severe and irreversible tubal factor sterility were selected following repeated failure of in vitro fertilization (IVF) due to assumed nonimplantation of the embryo: 35 underwent a salpingectomy before continuing IVF cycles and 37 continued IVF cycles without salpingectomy.*
Results: *After the first IVF cycle consecutive to diagnosis of embryo nonimplantation, the implantation rate was 10.2% in the salpingectomy group and 6.1% in the group without the procedure (P = 0.5). After all IVF cycles, the rate was, respectively, 6.9% and 4.5% (P = 0.2). Salpingectomy improved the pregnancy rate (PR) per transfer (23.5% vs. 9.9 %; P = 0.01). The curves of the cumulative probability of becoming pregnant show that salpingectomy resulted in pregnancy more rapidly.*
Conclusions: *Salpingectomy improves the PR per transfer in patients with severe and irreversible tubal factor sterility who have experienced repeated failure of IVF due to embryo nonimplantation. This procedure also reduces the number of IVF attempts needed to obtain pregnancy.*

KEY WORDS: embryo implantation rate; embryo nonimplantation; in vitro fertilization; salpingectomy; tubal infertility.

INTRODUCTION

Tubal pathologies lead to a lower embryo implantation rate than other forms of infertility (1–3). This finding seems to associated with the severity of the tubal disease (4–6). Distal tubal occlusion with a hydrosalpinx is particularly associated with a problem of embryo implantation, as well as with a lower clinical pregnancy rate (PR) (7–14). Some investigators have suggested that this defect of implantation can be improved by bilateral salpingectomy (15–20).

A recent study showed that salpingectomy performed prior to a first IVF attempt improved the rate of embryo implantation in women with severe tubal disease (21). Would this hold true for salpingectomy performed following repeated failure of IVF because of embryo nonimplantation?

The aim of this study was to determine whether a bilateral salpingectomy, performed after several failures of IVF because of embryo nonimplantation, would improve the implantation rate and PR in women with severe, irreversible tubal pathology.

MATERIALS AND METHODS

Seventy-two infertile patients were included in this retrospective study (last 3 years). All had shown evidence of severe, irreversible tubal pathology that had been assessed as unsuitable for surgical repair based on radiological, falloposcopic, and laparoscopic criteria, established before the initial in vitro fertilization (IVF) attempt. The hysterosalpingographic criteria were extensive inflammatory disease in the proximal part of the tube, with diverticula extending to > 2 cm of the isthmus (salpingitis isthmica nodosa); a hydrosalpinx with a poor prognosis because of disturbed mucosal folds; intra-ampullary adhesions or irregular walls; and obstructive bi- or multifocal pathologies. Intra-ampullary adhesions also were diagnosed by falloposcopy (22). The laparoscopic criteria were proximal nodes and inflammatory thick-walled hydrosalpinx in both

[1] Service de Gynécologie-Obstétrique, Médecine de la Reproduction et Foetologie.
[2] Laboratoire de Fécondation in Vitro.
[3] To whom correspondence should be addressed at Faculté de Médecine, Université Montpellier I, 371, avenue du doyen Gaston Giraud, 34295 Montpellier Cedex 5, France.

1058-0468/00/0400-0200$18.00/0 © 2000 Plenum Publishing Corporation

tubes. So, all patients had a communicating nondraining hydrosalpinx associated with a salpingitis isthmica nodosa. Adhesions alone were not considered to be evidence for severe tubal pathology.

All couples had undergone routine fertility screening and all other parameters were found to be normal. The following parameters were defined as normal for the men of the study: a sperm count of $> 20 \times 10^6$ ml, total mobility after 1 hr of $> 30\%$, normal morphology of $> 25\%$, sperm leukocyte count of < 400/ml, and liquefaction of < 30 min.

Ovulation was assessed by body basal temperature for 3 months before and then throughout a hormonal workup, which included measurement of the serum estradiol level, ultrasonographic (US) examination of the ovaries on cycle day 13, and measurement of serum progesterone level on cycle days 19, 21, and 23. Prolactin, thyroid-stimulating hormone (TSH), testosterone, androstenedione, (DHEA), 17-hydroxyprogesterone, luteinizing hormone (LH), and follicle-stimulating hormone (FSH), were assayed before day 6 of a spontaneous cycle. We considered sperm–mucus interaction to be normal if mobile sperm were present throughout the Huhner postcoital test.

Because of the severity and extensiveness of the tubal lesions, surgical repair was not considered to be an option for these women. All had already undergone several IVF cycles after thorough tubal investigation. The women were recruited for this study because of their tubal pathology and the repeated failure of embryo implantation during several IVF attempts. Embryo nonimplantation was defined as at least three embryo transfers after IVF, with at least nine fresh embryos transferred without obtaining a clinical pregnancy.

Inclusion criteria included patient age < 41; repeated failure of IVF because of embryo nonimplantation (three initial failed attempts); severe and irreversible tubal factor pathology as defined above; all other fertility parameters normal; and, for the salpingectomy group, willingness to continue IVF attempts after salpingectomy.

Patients were assigned to one of two groups: those who agreed to undergo a salpingectomy before continuing IVF attempts and those who did not undergo the procedure. Group 1 was composed of the 35 patients who underwent a bilateral salpingectomy by laparoscopy, using the technique for radical treatment of ectopic pregnancy (EP) (23), before continuing with cycles of IVF. Group 2 patients were those who did not undergo salpingectomy either because they refused to or because it was not proposed. All, however, agreed to continue with cycles of IVF.

All patients were stimulated with a combination of the gonadotropin-releasing hormone (GnRH) agonist (GnRH-a) (Decapeptyl LP 3.75; Ipsen, Paris, France) and human menopausal gonadotropin (hMG) (Humegon; Organon, Paris, France) to obtain multiple follicular development. Each patient received the GnRH-a [3.75 mg intramuscularly (IM)] on day 1 or 2 of a normal cycle. Fourteen days later, pituitary desensitization was evaluated by US examination (no follicle of > 10 mm in diameter) and by serum estradiol levels (< 60 pg/ml). Then, hMG was administered IM every evening at a dosage of 300 IU for 3 days followed by 150 IU every evening for 7 days. At that point, the hMG dosage was modified in accordance with the ovarian response, which was evaluated by serum estradiol levels and daily US examination to observe follicular development. The criteria for hCG administration (5000 IU IM) included an estradiol level of >1500 pg/ml and at least three follicles of >17 mm in diameter. Retrieval of oocytes occurred 35 hr after hCG administration and was performed under US guidance.

Embryo transfer took place 48 hr later in all patients in whom embryos were obtained after IVF. The number of embryos replaced was determined according to the following criteria: age of the patient, ovarian response to exogenous stimulation, the fecundity of the oocytes, morphological aspects of the embryos, and discussion with the couple.

In general, between three to five embryos were replaced in the same patient because of the poor pronostic of implantation in patients with severe tubal pathology. Those embryos with the best appearance were transferred immediately and the others were cryopreserved.

The main outcome was the embryo implantation rate (i.e., the ratio of the number of implanted embryos to the total number of fresh embryos transferred to the uterus). The implanted embryos were counted as follows: one in the case of miscarriage or EP, one in the case of a single ongoing pregnancy, two in the case of a twin ongoing pregnancy, and three in the case of a triplet ongoing pregnancy. These data were calculated in each group for the first IVF attempt consecutive to diagnosis of nonimplantation (i.e., the fourth IVF attempt) and for all IVF attempts of a given couple.

Other outcome measures were the pregnancy rate (PR) per transfer and the rate of live births per transfer. The cumulative PRs in each group were calculated using the cumulative proportion test (the cumulative

probability of becoming pregnant after each IVF attempt according to the number of patients, the number of pregnancies for each IVF attempt, and the number of patients who discontinued IVF after each IVF attempt). We hypothesized that the likelihood of becoming pregnant would have been equal for the patients who became pregnant after IVF and for those who discontinued the treatment.

Statistical analyses were performed with the χ^2 test, the Mann–Whitney test, or the Wilcoxon test for group comparison. Significance was set at $P < 0.05$.

RESULTS

The two groups were comparable in age, with 31.2 yr ± 4.1 and 31.7 yr ± 4, respectively, for the salpingectomy group and the group without salpingectomy. No differences were noted for the duration of infertility between the groups (respectively, 52.1 and 49.2 months) and for gravidity and parity.

The results of ovarian stimulation are reported in Table I. All parameters of ovarian response and number of embryos transferred were comparable in the two groups for the first three IVF attempts, as well as for the fourth and later attempts.

Sixteen clinical pregnancies were obtained in group 1 and 14 in group 2. Two cases of twins were noted in group 1 and 3 cases in group 2. Four first-trimester miscarriages occurred in group 1, which lowered the number of ongoing pregnancies to 12.

Comparison of the fourth IVF attempt (i.e., after salpingectomy in group 1) showed a tendency toward improvement in the embryo implantation rate in the salpingectomy group. The rates were, respectively, 10.2% (14 implanted embryos for 136 embryos transferred) in the salpingectomy group and 6.1% (8 implanted embryos for 130 embryos transferred) in the group without salpingectomy ($P = 0.5$).

The same tendency was noted when all IVF attempts (rank ≥ 4) were analyzed. The implantation rates were 6.9% (18/260) in the salpingectomy group and 4.5% (17/380) in the group without salpingectomy ($P = 0.2$).

The PR per transfer was significantly higher in the salpingectomy group (23.5% vs. 9.9%) ($P = 0.01$), with 16 pregnancies for 68 transfers and 14 pregnancies for 141 transfers, respectively. This significant difference was not observed when only ongoing pregnancies were considered. Salpingectomy not only improved the PR per transfer but also led to more rapid occurrence of pregnancy, since all pregnancies in this group occurred within the first three postsalpingectomy attempts. In the group without salpingectomy, some patients underwent 11 IVF cycles before obtaining a pregnancy. These results are summarized in Table II.

Figure 1 shows the comparison of the cumulative probability of becoming pregnant correlated to the rank of the IVF attempt and to the number of patients who abandoned IVF in each group. At the fourth IVF attempt (i.e., the first after diagnosis of embryo nonimplantation), the probability of becoming pregnant was higher in the salpingectomy group (40% vs. 21.6%).

DISCUSSION

The rationale for this study was that tubal pathology, particularly hydrosalpinx, is associated with lower embryo implantation rates during IVF cycles than other etiologies of infertility (8–11,14,24,25). The hypothesis that bilateral salpingectomy improves the embryo

Table I. Measures of Ovarian Stimulation for 35 Patients Who Had Undergone Salpingectomy versus 37 Patients Who Had Not Undergone Salpingectomy

Treatment groups	No. of hMG ampules per cycle	Estradiol level before oocyte retrieval (pg/mL)	No. of oocytes retrieved per cycle	No. of embryos per cycle	No. of embryos replaced	*P*
Salpingectomy						
First 3 IVF attempts	36 ± 11[a]	1952	9.9 ± 3.4	6.4 ± 2.5	4.1 ± 0.8	NS[b]
Fourth and later attempts	43.4 ± 16	2300	9.9 ± 4.3	6.5 ± 3.5	4.2 ± 1.1	NS
No salpingectomy						
First 3 IVF attempts	40 ± 12	2161	9.9 ± 3.6	6.1 ± 2.5	4 ± 1	NS
Fourth and later attempts	43.5 ± 16	2295	9.8 ± 4	6 ± 3.1	4 ± 1.1	NS

[a] Values are given as mean ± SD.
[b] NS, Not significant.

Table II. Embryo Implantation and Pregnancy Rates for 35 Patients Who Had Undergone Salpingectomy versus 37 Patients Who Had Not Undergone Salpingectomy

Treatment group	Salpingectomy (n = 35)	No salpingectomy (n = 37)	P value
Implantation rate[a] (Fourth IVF attempt only)	10.2%	6.1%	NS[d]
Implantation rate[a] (Rank of IVF attempt ≥ 4)	6.9%	4.5%	NS
Pregnancy rate per transfer[b]	23.5%	9.9%	0.01
Ongoing pregnancy rate per transfer[c]	17.6%	9.9%	NS

[a] Number of implanted embryos per number of fresh embryos replaced into the uterine cavity.
[b] Number of pregnancies per number of transfer.
[c] Number of ongoing pregnancies per number of transfer.
[d] NS, Not significant.

implantation rate and the PR per transfer in patients with severe tubal pathology (10,16,17,20) is widely debated in the literature. The objectives were to explore whether the tubes themselves could be the cause of repeated nonimplantation of embryos and whether their removal could improve the probability of obtaining a pregnancy in these patients on the occasion of a further attempt.

The major finding was that bilateral salpingectomy performed after three IVF failures due to embryo nonimplantation tends to improve the embryo implantation rate in women with severe tubal pathology. This was observed both for the first IVF attempt following salpingectomy as well as for all further attempts. The difference between the salpingectomy group and the group without salpingectomy could not be explained by any other factor known to influence embryo implantation, such as patient age or the number of embryos transferred, because these parameters were statistically comparable in the two groups.

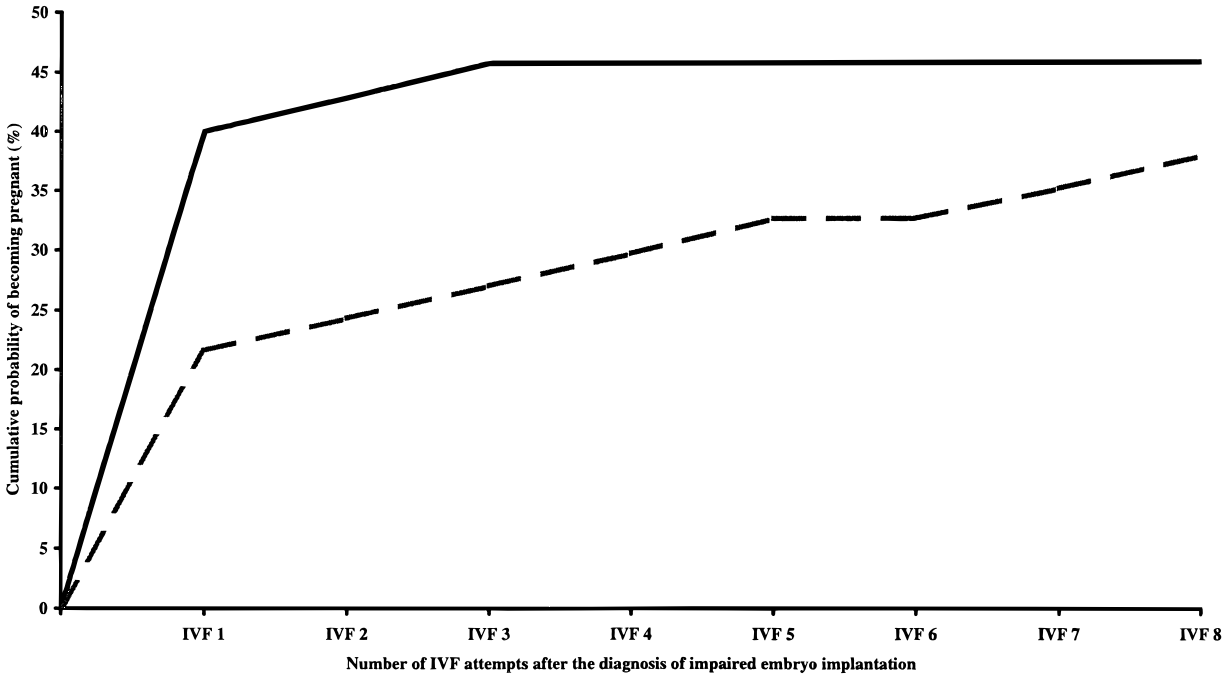

Fig. 1. Plot of the cumulative probability of becoming pregnant after each IVF procedure according to the treatment group (----, no salpingectomy; ——, salpingectomy).

Our study appears to corroborate the data in support of it. The best moment to remove the fallopian tubes needs to be established so that each patient has the maximal possibility of becoming pregnant in optimal conditions.

Recently, a prospective and randomized study analyzed the impact of salpingectomy prior to IVF in patients with severe and irreversible tubal factor infertility (21). The results showed a tendency toward improvement in the embryo implantation rate in the salpingectomy group. The rates were 10.4% in this group and 4.6% in the group without salpingectomy. The PRs per transfer also showed a difference, respectively, 34.2% and 18.7%. Shelton *et al.* (16) investigated whether bilateral salpingectomy improves PR after IVF in patients with hydrosalpinx, and they found that PR per fresh embryo transfer was 42% following salpingectomy, whereas only one pregnancy that ended in miscarriage was noted presalpingectomy (16). However, this study was not statistically valid because it compared the pregnancy outcome of the same patients before and after salpingectomy, without a control group.

Our analysis was similar to theirs, with the important difference that we included a control group of patients without salpingectomy. This was done to determine whether the multiplication of IVF attempts alone could suffice to explain the improved PR. Our study design allowed us to conclude that salpingectomy for severe tubal pathology improved PR and reduced the number of IVF attempts needed to obtain pregnancy.

In cases of major tubal pathology (extensive and inflammatory) bilateral salpingectomy not only improves IVF results, but in certain cases also it may reduce the risks of chronic pelvic pain and acute inflammatory processes in reaction to follicular aspiration or embryo transfer (26). Among the other potential advantages Of this procedure is the prevention of ectopic ampullary pregnancies (27). The risk of ectopic intramural pregnancies remains, however, and these are difficult to diagnose and treat (28,29). It should be recalled that, in cases of tubal factor infertility, the overall ectopic pregnancy rate is 12% as opposed to 3% in other etiologies of infertility (30,31).

Despite the number of studies on the impact of tubal pathology, particularly hydrosalpinx, on embryo implantation, the physiopathology remains unclear. A hydrosalpinx forms after the destruction of the fimbria and consequently by accumulation of diverse tubal secretions (32). Given the continuity of the hydrosalpinx with the uterine cavity, these secretions may flow into the uterus and disrupt the process of embryo implantation (33). The resulting dysfunction in endometrial receptivity may be caused by several phenomena. The cause may be mechanical, but it seems more likely to be an inadequate chemical composition of the hydrosalpinx liquid (32,34). Another hypothesis is that a hydrosalpinx causes an inflammatory endometrial reaction that prevents further endometrial and/or embryo development (35). This inflammatory reaction can be quantified in the endometrium by an excess of macrophages in patients with tubal sterility (36). Recently, a study showed that patients with hydrosalpinx expressed fewer endometrial integrins in comparison with control subjects (37). A bilateral salpingectomy reestablished the expression of these integrins, and thus indicated the deleterious effect of a hydrosalpinx on the endometrium (37). The authors hypothesized that this diagnostic tool can screen for a subgroup of patients with hydrosalpinx for whom salpingectomy would be beneficial. Other suggestions include embryotoxic substances in the hydrosalpinx fluid (38–40) or lipophilic embryotoxic factors in hydrosalpinx fluid (41).

If these hypotheses are correct, bilateral salpingectomy directly treats the cause of endometrial alteration, thus restoring its receptivity. In consequence, embryo implantation would be improved after this procedure.

The efficacy of salpingectomy to treat cases of severe and irreversible tubal pathology before or during IVF attempts remains a subject of debate. However, salpingectomy as a specific response to repeated embryo nonimplantation improves the pregnancy rate per transfer. This surgical act also reduces the number of IVF attempts needed to obtain a pregnancy. The reduction in the number of attempts needed to obtain a pregnancy has both economic and psychological impact, neither of which is negligible. This needs to be taken into consideration in the evaluation of indications for salpingectomy in this group of patients. In selected cases, bilateral salpingectomy tends to improve the success rate of IVF treatment for infertility.

REFERENCES

1. Sims JA, Jones D, Butler L, Muasher SJ: Effect of hydrosalpinx on outcome in in-vitro fertilization (Abstr. No. P-032). *In* American Fertility Society, 1993, p S95
2. Kassabji M, Sims JA, Butler L, Muasher SJ: Reduced pregnancy outcome in patients with unilateral or bilateral hydrosalpinx after in-vitro fertilization. Eur J Obstet Gynecol 1994;56: 129–132

3. Dechaud H, Arnal F, Humeau C, Hedon B: Embryo implantation rate changes with the etiology of infertility (Abstr. No. P.-327). IFFS 1995. Contracept Fertil Sex 1995;23:S144–S145
4. Csemiczky G, Landgren BM, Fried G, Wramsby H: High tubal damage grade is associated with low pregnancy rate in women undergoing in-vitro fertilization treatment. Hum Reprod 1996;11:2438–2440
5. Vasquez G, Boeckx W, Brosens IA: Prospective study of tubal mucosal lesions and fertility in hydrosalpinges. Hum Reprod 1995;10:1075–1078
6. Wainer R, Camus E, Camier B, Martin C, Vasseur C, Merlet F: Does hydrosalpinx reduce the pregnancy rate after in vitro fertilization? Fertil Steril 1997;68:1022–1026
7. Blazar AS, Hogan JW, Seifer DB, Frishman GN, Wheeler CA, Haning RV: The impact of hydrosalpinx on successful pregnancy in tubal factor infertility treated by in vitro fertilization. Fertil Steril 1997;67:517–520
8. Strandell A, Waldenstrom U, Nilsson L, Hamberger L: Hydrosalpinx reduces in-vitro fertilization/embryo transfer pregnancy rates. Hum Reprod 1994;9:861–863
9. Vandromme J, Chasse E, Lejeune B, Van Rysselberge M, Delvigne A, Leroy F: Hydrosalpinges in in-vitro fertilization: An unfavourable prognostic feature. Hum Reprod 1995;10: 576–579
10. Andersen AN, Yue Z, Meng FJ, Petersen K: Low implantation rate after in-vitro fertilization in patients with hydrosalpinges diagnosed by ultrasonography. Hum Reprod 1994;9:1935–1938
11. Fleming C, Hull MG: Impaired implantation after in-vitro fertilization treatment associated with hydrosalpinx. Br J Obstet Gynæcol 1996;103:268–272
12. Katz E, Akman MA, Damewood MD, Garcia JE: Deleterious effect of the presence of hydrosalpinx on implantation and pregnancy rates with in-vitro fertilization. Fertil Steril 1996;66:122–125
13. De Wit W, Gowrising CJ, Kuik DJ, Lens JW, Schats R: Only hydrosalpinges visible on ultrasound are associated with reduced implantation and pregnancy rates after in-vitro fertilization. Hum Reprod 1998;13:1696–1701
14. Zeyneloglu HB, Arici A, Olive DL: Adverse effects of hydrosalpinx on pregnancies rates after in vitro fertilization-embryo transfer. Fertil Steril 1998;70:492–499
15. Poe-Zeigler R, Shelton KE, Toner JP: Salpingectomy(ies) improves the pregnancy rate after IVF in patients with unilateral or bilateral hydrosalpinx. J Assist Reprod Genet 1995;12:S65–
16. Shelton KE, Butier L, Toner JP: Salpingectomy improves the pregnancy rate in in-vitro fertilization patients with hydrosalpinx. Hum Reprod 1996;11:523–525
17. Puttemans PJ, Brosens IA: Salpingectomy improves in-vitro fertilization outcome in patients with a hydrosalpinx: Blind victimization of the Fallopian tube? Hum Reprod 1996;11: 2079–2081
18. Aubriot FX, Chapron C, Morice P, Dubuisson B: Hydrosalpinx et stérilité: Indications de la salpingectomie. Contracept Fertil Sex 1995;23:670–673
19. Andersen AN, Lindhard A, Loft A, Ziebe S, Andersen CY: The infertile patient with hydrosalpinges—IVF with or without salpingectomy? Hum Reprod 1996;11:2081–2084
20. Bredkjær HE, Ziebe S, Hamid B, Zhou Y, Loft A, Lindhard A, Andersen AN: Delivery rates after in-vitro fertilization following bilateral salpingectomy due to hydrosalpinges: A case control study. Hum Reprod 1999;14:101–105
21. Dechaud H, Daures JP, Arnal F, Humeau C, Hedon B: Does previous salpingectomy improve implantation and pregnancy rates in patients with severe tubal factor infertility who are undergoing in vitro fertilization? A pilot prospective randomized study. Fertil Steril 1998;69:1020–1025
22. Dechaud H, Daures JP, Hedon B: Prospective evaluation of falloposcopy. Hum Reprod 1998;13:1815–1818
23. Dubuisson JB, Aubriot FX, Cardone V: Laparoscopic salpingectomy for ectopic pregnancies. Fertil Steril 1987;47:225–228
24. Sharara FI, Scott RT, Marut EL, Queenan JT: In vitro fertilization outcome in women with hydrosalpinx. Hum Reprod 1996;11:526–530
25. Akman MA, Garcia JE, Damewood MD, Watts LD, Katz E: Hydrosalpinx affects the implantation of previously cryopreserved embryos. Hum Reprod 1996;11:1013–1014
26. Peters AJ, Hecht B, Ourinzi K, Deleon F, Wentz AC: Salpingitis or oophoritis: What causes fever salpingitis oocyte aspiration and embryo transfer? Obstet Gynecol 1993;81:876–877
27. Verhulst G, Camus M, Bollen N, Van Steirteghem A, Devroey P: Analysis of the risk factors with regard to the occurence of ectopic pregnancy after medically assisted procreation. Hum Reprod 1993;8:1284–1287
28. Herman A, Ron-El R, Golan A, Weinraub Z, Bukovsky I, Caspi E: The role of tubal pathology and other parameters in ectopic pregnancies occurring in in-vitro fertilization and embryo transfer. Fertil Steril 1990;54:864–868
29. Pavic N, Neuenschwander E, Gschwind C: Interstitial pregnancy following bilateral salpingectomy and in-vitro fertilization and embryo transfer. Fertil Steril 1986;46:701–
30. Dubuisson JB, Aubriot FX, Mathieu L, Foulot H, Mandelbrot L, Bouquet De Joliniere J: Risk factors for ectopic pregnancy in 556 pregnancies after in-vitro fertilization: Implications for preventive managment. Fertil Steril 1991;56:686–690
31. Zouves C, Erenus M, Gomel V: Tubal ectopic pregnancy after in-vitro fertilization and embryo transfer: A role of proximal occlusion or salpingectomy after failed distal tubal surgery. Fertil Steril 1991;56:691–695
32. David A, Garcia C, Czernobilski B: Human hydrosalpinx: Histologic study and chemical composition of fluid. Am J Obstet Gynecol 1969;400–411
33. Mansour RT, Aboulghar MA, Sevour GI, Riad R: Fluid accumulation of the uterine cavity before embryo transfer: A possible hindrance for implantation. J In Vitro Fertil Embryo Transfer 1991;8:157–159
34. Granot I, Dekel N, Fieldust S, Shoham Z, Barash A: Is hydrosalpinx fluid cytotoxic? Hum Reprod 1998;13:1620–1624
35. Ben Rafael Z, Orvieto R: Cytokines—Involvement in reproduction. Fertil Steril 1992;58:1093–1099
36. Dechaud H, Maudelonde T, Daures JP, Rossi IF, Hedon B: Evaluation of endometrial inflammation by quantification of macrophages, T lymphocytes and interleukine 6. J Assist Reprod Genet 1998;15:612–618
37. Meyer WR, Castelbaum AJ, Somkuti S, Sagoskin AW, Doyle M, Harris JE, Lessey BA: Hydrosalpinges adversely affect markers of endometrial receptivity. Hum Reprod 1997;12: 1393–1398
38. Mukherjee T, Copperman AB, Mc Caffrey C, Cook CA, Bustillo M, Obesaju MF: Hydrosalpinx fluid has embryotoxic effects on murine embryogenesis: A case for prophylactic salpingectomy. Fertil Steril 1996;66:851–853

39. Rawe VJ, Liu J, Shaffer S, Compton MG, Garcia JE, Katz E: Effect of human hydrosalpinx fluid on murine embryo development and implantation. Fertil Steril 1997;68:668–670
40. Spandorfer SD, Liu HC, Neuer A, Barmat LI, Davis O, Rosenwaks Z: The embryo toxicity of hydrosalpinx is only apparent at high concentrations: An in vitro model that simulates in vivo events. Fertil Steril 1999;71:619–626
41. Beyler SA, James KP, Fritz MA, Meyer WR: Hydrosalpingeal fluid inhibits in-vitro embryonic development in a murine model. Hum Reprod 1997;12:2724–2728