

Significance of styloidectomy in Eagle's syndrome: an analysis

Sanjeev Mohanty · N. S. Thirumaran · Gopinath M. · Gaurav Bambha · Shalini Balakrishnan

Abstract

Objectives/hypothesis Reported here is a randomized retrospective analysis of 28 cases of elongated styloid process causing nagging cervicofacial pain, both unilateral and bilateral, and the effect of styloidectomy in these cases in relieving the symptom complex of the patient, in situations where conservative management failed in alleviating the symptoms.

Study design Randomized retrospective analysis over a period of 25 months.

Conclusion Elongated styloid process causing glossopharyngeal neuralgia is beginning to be a frequently encountered clinical entity nowadays. Of the 28 cases of elongated styloid process who underwent unilateral/bilateral styloidectomy, 27 patients had total relief of symptoms. Hence, we advocate styloidectomy, following careful diagnosis of the entity with clinical and radiological correlation, if the patient does not respond to medical therapy. The psychological status of the patient would provide clue to the authenticity of the symptoms in unrelieved cases.

Keywords Elongated styloid process · Glossopharyngeal neuralgia · Eagle's syndrome

S. Mohanty · N. S. Thirumaran · Gopinath M. · G. Bambha · S. Balakrishnan
Department of ENT, Head and Neck surgery,
Sri Ramachandra Medical College and Research Institute,
Chennai, India

S. Mohanty (✉)
E-mail: drsanjeevmohanty@gmail.com

Introduction

Ninety-two patients presented to our hospital between June 2006 and August 2008, with complaints like throat pain, difficulty in swallowing, painful swallowing, unexplained ear ache, painful mouth opening or jaw movements and headache. All these patients were thoroughly evaluated clinically and radiologically. Of these 92 cases, 64 cases were diagnosed to have clinical conditions that were responsible for their symptoms. These included conditions like chronic tonsillitis, migraine, gastroesophageal reflux disease, cervical pain due to arthritis and rarely, otalgia of unknown origin and idiopathic glossopharyngeal neuralgia. All the patients were assessed clinically for the presence of elongated styloid process. A total of 28 patients were clinically detected to have elongated styloid process, both unilateral and bilateral after palpation of the tonsillar fossa, thereby causing tenderness. This was further confirmed by radiological investigations. Most of these patients (23 out of 28) presented with difficulty and pain while swallowing as well as persistent throat pain.

Materials and Methods

We studied 28 patients; 17 were females and 39 were males. The diagnosis of elongated styloid was confirmed by the persistence of tenderness on palpating the tonsillar fossa after injection of 10% lignocaine into the fossa. All these patients underwent a trial of the drug carbamazepine, taken orally at a dose of 200 mg TDS for 3 months, but without any relief in symptoms.

A radiological correlation of these clinical findings was done with the help of computerized tomography with three-dimensional reconstructions.

These patients were taken up for styloidectomy after complete evaluation. Twenty-seven patients underwent transoral transtonsillar approach styloidectomy, while

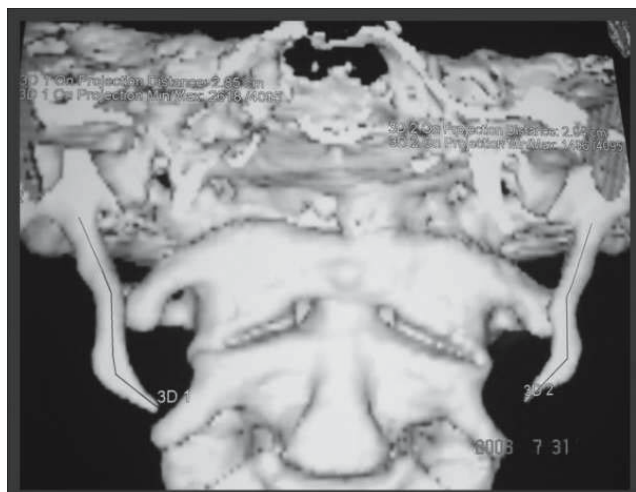


Fig. 1 Bilateral elongated styloid processes

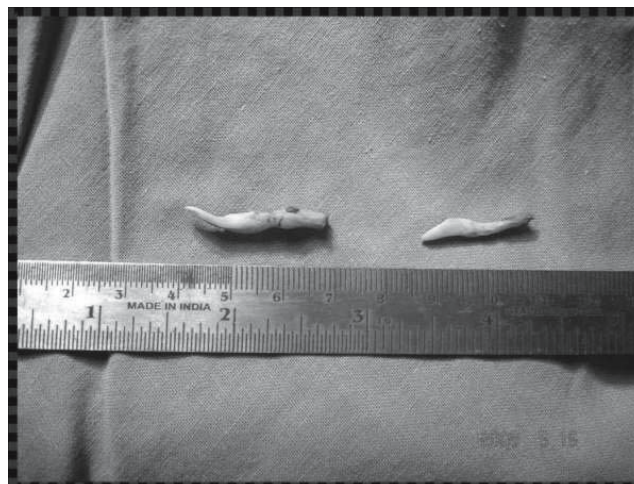


Fig. 2 Styloid measuring 40 mm (left) and 32 mm (right)

one patient required combined transoral transcervical approach due to difficulty in access. The steps in the surgery included conventional or KTP 532 laser-assisted tonsillectomy followed by separation of the capsule of the tonsil and the superior constrictor muscle. The styloid process was identified deep to the superior constrictor muscle. The skeletonizing of the styloid process was an important surgical step, as it made the bony prominence easy to identify. The attachment of the stylohyoid muscle was then identified and separated from the styloid process. The styloid was then palpated up to its attachment at the skull base, and excised using appropriate size bone nibbler. Following styloidectomy in all the cases, the fossa was inspected with rigid endoscope to aid detection of bleeding sites. After achieving good hemostasis, the fossa was packed with gel foam.

Postoperatively, the patients were kept on nasogastric tube feeding for 48 hours along with broad-spectrum intravenous antibiotic, anti-inflammatory and analgesic agents. Most importantly, good oral hygiene was maintained in the postoperative period.

Four of these 28 patients underwent unilateral styloidectomy, depending on the side where elongated styloid was detected by clinical and radiological evidence. Ten patients had already undergone tonsillectomy previously.

The intraoperative difficulties encountered were:

- Excessive bleeding from the fossa
- Difficulty in skeletonizing the entire length due to difficulty in access
- Difficulty in reaching laterally placed styloid processes
- Sustained contraction of the stylohyoid muscle, causing difficulty in identifying the entire length of the styloid

- Rarely, in a few cases, where the calcified portion was deeper than the radiological image.

Thirteen patients had styloid processes measuring between 31 and 40 mm in length. Only one patient had a styloid process measuring above 40 mm and underwent the combined approach styloidectomy. The same patient had a styloid process length of 24 mm on the opposite side (Figs. 1 and 2).

Patients who were found to have styloid process measuring between 12 and 20 mm also underwent glossopharyngeal neurectomy in the same sitting.

All the patients were followed-up at monthly intervals for a duration of 6 months. At the end of 6 months only one patient had the persistence of symptoms. This suggests the importance of psychological assessment, wherein the authenticity of the patient symptoms comes into play.

Discussion

The styloid process arises from the temporal bone immediately in front of the stylomastoid foramen. The normal length of this process is 20–25 mm in adults [1, 2]. The mean radiographic length of the styloid process has been reported to be between 20 and 30 mm [3]. Its shape is cylindrical, tapering gradually toward the apex. The apex of the styloid process is clinically important, because it is located between internal and external carotid arteries, just lateral to the tonsillar fossa, within the lateral pharyngeal wall. The tip of the styloid process is continuous with the stylohyoid ligament, which extends to the lesser cornu of the hyoid bone. Muscular and ligamentous structures are attached at various locations of the process. The attached muscles are the stylopharyngeus (arising from the base), the stylohyoid (attached to the middle portion) and

the styloglossus muscle (originating from the extremity of the process).

The innervations of these three muscles are the glossopharyngeal nerve, the facial nerve, and the hypoglossal nerve, respectively [4]. The stylohyoid process and ligament are derived from the first and second branchial arches, in addition to Reichter's cartilage. In the adult the stylohyoid ligament, which is normally composed of dense fibrous connective tissue, may retain some of its embryonic cartilage and thus have the potential to become partially or completely ossified. This complex is composed of the styloid process, stylohyoid ligament and the stylomandibular ligament [5, 6]. If these structures solidify, they can cause the pain and suffering present in symptomatic cases [3, 7]. Although patients may sometimes show clinical symptoms with the reported prevalence from 1% to 5%, the condition can also occur without any clinical symptoms [5]. With the occurrence of symptoms, this entity is known as either "Eagle's syndrome" or "elongated styloid process syndrome" or "styloid process-carotid artery syndrome" or "stylohyoid syndrome" or "styloid process neuralgia" [5].

Eagle reported several cases of cervicopharyngeal symptoms associated with a radiographic diagnosis of an elongated, ossified styloid process occurring a few months post-tonsillectomy [8]. He described the symptoms as nagging or aching sensation in the throat, similar to the chronic pharyngitis, pain spreading to the ear and the mastoid region, difficulty in swallowing, and a sensation of foreign body in the throat [8, 9]. It may develop inflammatory changes or impinge on the adjacent arteries or sensory nerve endings, leading to the symptoms described. A diagnosis of Eagle's syndrome is applied only when ossification develops within a period of time after trauma, with accompanying symptoms.

Eagle's syndrome may be caused by tonsillectomy or traumatic fracture of a mineralized stylohyoid ligament [10]. A diagnosis of stylohyoid syndrome is applied only when patients have stylohyoid chain ossification and/or styloid process elongation with symptoms; there is no history of cervicopharyngeal trauma [11]. Diagnosis can usually be made on physical examination by digital palpation of the styloid process in the tonsillar fossa, which exacerbates the pain and with radiographic work-up. In addition, relief of symptoms with injection of an anesthetic solution into the tonsillar fossa is highly suggestive of this diagnosis [12].

An estimated 2–4% of the general population presents radiographic evidence of an ossified portion of the stylohyoid chain [13]. The estimated normal radiographic length of styloid process is 20–30 mm. Of pathogenic importance is the spatial position of the tip of this process [4, 8]. Keur states that, if the length of the process or the mineralized part of the stylohyoid ligament appears to be 30 mm or above

on radiography, then it can be considered as an elongated styloid process [4].

When symptoms do exist, there is little correlation between the extent of the symptoms and the severity of the ossification. The majority of symptomatic patients have had no recent history of tonsillectomy or other cervicopharyngeal trauma [13–15]. The clinical symptoms of an elongated styloid process can be misdiagnosed, as salivary gland disease, otitis media, temporomandibular myofascial dysfunction syndrome or glossopharyngeal neuralgia. In addition, stylohyoid syndrome must be differentiated from all the various dysfunction related to temporomandibular joint problems [7, 16]. Treatment options for stylohyoid syndrome include surgical removal of the elongated styloid process or ossified stylohyoid ligament, injection of a steroid solution or long-acting anesthetic at the lesser horn of the hyoid or the inferior aspect of the tonsillar fossa [7, 17]. Treatment in cases of true stylohyoid chain ossification caused by trauma (Eagle's syndrome) is immediate surgical excision, involving the intraoral approach, with complete surgical excision of the styloid process and/or ossified stylohyoid ligament. The extraoral lateral neck approach is only indicated when the intraoral approach is not possible, as in limited jaw opening [15]. Postsurgery, thrombosis of the internal carotid artery is a dreaded complication.

Conclusion

As an anatomical variant, elongated styloid process has been established for long. However, its association with symptoms such as nagging cervicofacial pain, not relieved by conservative management needs to be evaluated, for complete cure. Glossopharyngeal neuralgia as a part of Eagle's syndrome is an important clinical entity. The psychological status of the patient is of prime importance before non-relief of symptoms is judged; it could be a clue to malingering! With a clinical suspicion of elongated styloid process, radiological correlation would be the key to diagnosing this uncommon entity. It goes without saying that a meticulously diagnosed Eagle's syndrome with radiological correlation is best treated by styloidectomy as a final treatment modality to relieve the patient of his nagging symptom complex.

References

1. Eagle WW (1948) Elongated styloid process. *Arch Otolaryngol* 47:630–640
2. Ferrario VF, Sigurt'a D, Daddona A, Dalloca L, Miani A, Tafuro F, Sforza C (1990) Calcification of the stylohyoid ligament: Incidence and morphoquantitative evaluations. *Oral Surg Oral Med Oral Pathol* 69:524–529

3. Monsour PA, Youn WG (1986) Variability of the styloid process and stylohyoid ligament in panoramic radiographs. *Oral Surg Oral Med Oral Pathol* 61:522–526
4. Keur JJ, Campbell JPS, Mc Carthy JF, Ralph WJ (1986) The clinical significance of the elongated styloid process. *Oral Surg Oral Med Oral Pathol* 61:399–404
5. Langlais RP, Miles DA, Van Dis ML (1986) Elongated and mineralized stylohyoid ligament complex: A proposed classification and report of a case of Eagle's syndrome. *Oral Surg Oral Med Oral Pathol* 61:527–32
6. Kawai T, Shimimoto K, Ochiai S (1990) Elongated styloid process as a cause of difficult intubation. *J Oral Maxillofac Surg* 48:1225–8
7. Winkler S, Sammartino FJ, Monari JH (1981) Stylohyoid Syndrome. *Oral Surg Oral Med Oral Pathol* 51:215–7
8. Eagle WW (1937) Elongated styloid process : report of two cases. *Arch Otolaryngol* 25:584–7
9. Bhaskar SN (1981) Synopsis of Oral Pathology. St. Louis: CV Mosby, London pp. 707
10. Babad MS (1995) Eagle's syndrome caused by traumatic fracture of a mineralized stylohyoid ligament. *Cranio* 13:188–92
11. Camarda AJ, Deschamps C, Forest D II (1989) Stylohyoid chain ossification: A discussion of etiology. *Oral Surg Oral Med Oral Pathol* 67:515–20
12. Balbuena L Jr, Hayes D, Ramirez SG, Johnson R (1997) Eagle's syndrome (elongated styloid process). *South Med J* 90:331–4
13. Gossman Jr. JR, Tarsitano JJ (1977) The styloid-stylohyoid syndrome. *J Oral Surg* 35:355–60
14. Kaufman SM, Elzay RP, Irish EF (1970) Styloid process variation: radiologic and clinical study. *Arch Otolaryngol* 91:460–3
15. Camarda AJ, Deschamps C, Forest DI (1989) Stylohyoid chain ossification: A discussion of etiology. *Oral Surg Oral Med Oral Pathol* 67:508–14
16. Barrett AW, Griffiths MJ, Scully C (1993) Osteoarthritis, the temporomandibular joint and Eagle's syndrome. *Oral Surg Oral Med Oral Pathol* 75:273–5
17. Ozawa T, Hasegawa M, Okaue M, Shimoyama T, Hori M, Matsumoto N, Tanaka H (1995) Two cases of symptomatic elongated styloid process. *J Nihon Univ Sch Dent* 37:178–82