Portal Interventions in Liver Transplant Recipients

Wael E. A. Saad, M.D., F.S.I.R. [1]

[1] Division of Vascular Interventional Radiology, Department of Radiology and Medical Imaging, University of Virginia Health System, Charlottesville, Virginia

Semin Intervent Radiol 2012;29:99–104

Address for correspondence and reprint requests Wael E. A. Saad, M.D., F.S.I.R., Division of Vascular Interventional Radiology, Department of Radiology and Medical Imaging, University of Virginia Health System, Box 800170, 1215 Lee Street, Charlottesville, VA 22908 (e-mail: wspikes@yahoo.com).

Abstract

Portal vein interventions in liver transplant recipients represent a group of interventions in the management of several disease entities including portal vein stenosis, portal vein thrombosis, and recurrent liver cirrhosis with portal hypertension with and without gastric varices. The procedures performed in these patient populations include portal vein angioplasty with or without stent placement for portal vein stenosis, portal vein thrombolysis with or without stent placement for portal vein thrombosis, transjugular intrahepatic portosystemic shunts or splenic embolization for cirrhosis, and balloon-occluded retrograde transvenous obliteration for gastric varices. This article discusses these disease entities and the minimal invasive procedures used in their management.

Keywords
- transplant
- liver
- vascular complications
- endovascular
- portal
- portal hypertension
- TIPS
- BRTO

Objectives: On completion of this article, the reader will be able to define the most common portal interventions performed post-liver transplantation, including the indications, technical considerations, and outcomes of such procedures.

Accreditation: Tufts University School of Medicine is accredited by the Accreditation Council for Continuing Medical Education to provide continuing medical education for physicians.

Credit: Tufts University School of Medicine designates this journal-based CME activity for a maximum of ***1 AMA PRA Category 1 Credit***™. Physicians should claim only the credit commensurate with the extent of their participation in the activity.

Portal vein interventions in liver transplant recipients represent a group of interventions in the management of several disease entities, including portal vein stenosis, portal vein thrombosis, and recurrent liver cirrhosis with portal hypertension with and without gastric varices. The procedures performed in these patient populations include portal vein angioplasty with or without stent placement for portal vein stenosis, portal vein thrombolysis with or without stent placement for portal vein thrombosis, transjugular intrahepatic portosystemic shunts (TIPS) or splenic embolization for cirrhosis, and balloon-occluded retrograde transvenous obliteration (BRTO) for gastric varices. This article discusses these disease entities and the minimal invasive procedures used in their management.

Portal Venous Stenosis

Incidence and Presentation

Overall, portal venous stenosis (PVS) is uncommon and occurs in 5% of all liver transplants.[1–4] However, PVS occurs more commonly in transplants using split grafts (4% in adult split grafts and 7 to 27% in pediatric split grafts).[5–8] PVS is rare (<1 to 2%) in adult whole liver grafts.[7,9] In a study by Khalaf, whole grafts versus living related split grafts had a PVS rate of 0% versus 4.3%, respectively.[9] As a result, most of the PVS cases in the literature have been reported in pediatric liver transplant recipients.[5,6,10–14] PVS almost always occurs at the surgical anastomosis,[15] and its distance from the portal bifurcation depends on the length of the graft portal vein stump (distance between the surgical anastomosis and the graft portal bifurcation).[15] If there is a negligible length to the graft stump, then the stenosis occurs right at the portal vein bifurcation/trifurcation (►**Fig. 1**).

Issue Theme Portal Interventions; Guest Editor, Wael E. A. Saad, M.D., F.S.I.R.

Copyright © 2012 by Thieme Medical Publishers, Inc., 333 Seventh Avenue, New York, NY 10001, USA. Tel: +1(212) 584-4662.

DOI http://dx.doi.org/10.1055/s-0032-1312570.
ISSN 0739-9529.

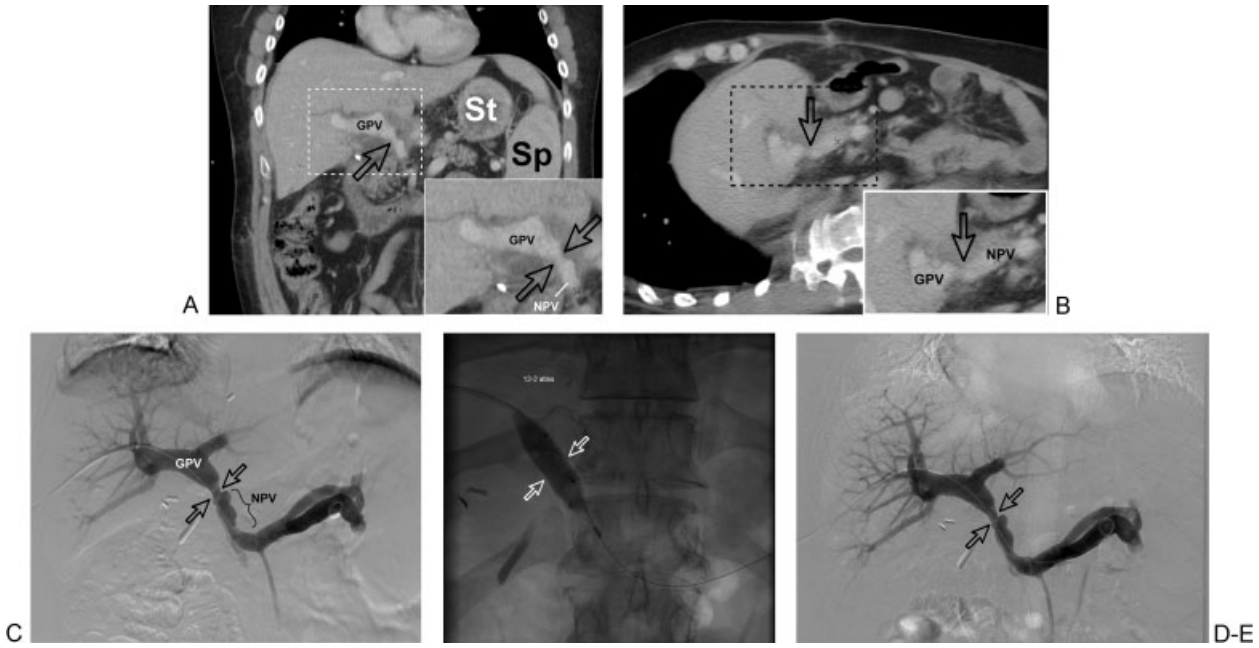

Figure 1 (A) Coronal reformat (with a magnified inset in bottom right corner) of a contrast-enhanced computed tomography (CT) of an adult liver transplant recipient with abnormal liver function tests. There is a stricture at the portal anastomosis (open arrows) between the native/recipient portal vein (NPV) and the graft/donor portal vein (GPV). St, stomach; sp, spleen. (B) Skewed coronal reformat (with a magnified inset in bottom right corner) of a contrast-enhanced CT of the same patient as (A). There is a redemonstration of the stricture at the portal anastomosis (open arrows) between the NPV and the GPV. (C) Digital subtraction portal venogram of the same patient demonstrating the portal anastomotic stricture (open arrows) between the NPV and the GPV. The pressure gradient across the anastomosis was 8 mm Hg. (D) Fluoroscopic spot image of an inflated 12-mm high-pressure balloon. The open arrows mark the site/level of the portal anastomosis. (E) Final digital subtraction portogram after venoplasty demonstrating no significant change in the portal anastomotic stricture (open arrows); however, the pressure gradient across the anastomosis improved from 8 mm Hg to 4 mm Hg. Due to the reduction of the gradient to a satisfactory level, no further interventions were performed.

Split grafts (particularly pediatric left lobe split grafts) have a higher risk of developing portal venous stenoses because the recipient portal vein usually has a small diameter; this is technically challenging and usually requires surgical plication of the relatively larger donor portal vein, predisposing to anastomotic stenoses.[3,7,13] Furthermore, in living donor split hepatic grafts, the portal vein anastomosis is technically challenging because the donor portal vein segment(s) is relatively short and not infrequently requires interposition grafts or multiple/complex anastomotic reconstructions.[5,16] Other known risk factors for developing PVS after transplantation are prior splenectomy (increases risk fivefold) and the Mayo management protocol for cholangiocarcinoma.[4,7,17]

Early portal venous stenoses (occurring within 6 months after transplantation) are probably due to technical reasons.[15] Most portal venous stenoses, however, occur late (after 6 months).[11,12,15,18,19] In three studies evaluating the diagnosis of PVS in adult whole grafts (total of eight patients), the average time lapse between the liver transplant and portal vein stenosis was over a year (range: 1 to 31 months).[7,20] Such delayed PVS is due to scarring/fibrosis with neointimal hyperplasia.[7]

Posttransplant portal vein stenoses have a variable presentation. Severe PVS can lead to portal vein thrombosis, although it can also be asymptomatic with or without abnormal liver function tests. It can also present with uncompensated portal hypertension symptoms (ascites, variceal bleeding) and/or lower limb edema with hepatic graft failure (clinical hepatic failure).[7,8,11,12,18,19,21] In three studies evaluating adult whole grafts with portal vein stenoses (total of 24 patients), 10 patients (42%) had ascites, 8 patients (33%) had variceal bleeding, and 6 patients (25%) were asymptomatic with abnormal laboratory liver function tests only.[7,20–22]

Imaging Diagnosis

Significant posttransplant PVS is difficult to evaluate by cross-sectional studies such as computed tomography (CT) and magnetic resonance imaging (MRI). Both of these are not typically dynamic imaging modalities.[15] It is particularly difficult to assess the portal anastomosis accurately when there is an angulation and/or a size mismatch between the diameter of the native and donor portal veins.[23] For this reason, because Doppler ultrasound offers a hemodynamic assessment, it may be the most accurate noninvasive modality for evaluating and diagnosing PVS.[15] Doppler ultrasound findings suggestive of a significant PVS include peak portal velocities that are three- to fourfold higher at the anastomosis, a focal increase of portal velocity greater than threefold, and a peak velocity >125 cm/second.[23–25] These Doppler findings have a sensitivity and a specificity for PVS of 73% and 95 to 100%, respectively.[23–25]

Transcatheter portography remains the most accurate and gold standard examination because of its ability to directly

visualize the anastomosis as well as to perform portal pressure gradient measurements across the anastomosis.[23,24,26] However, the gradient that signifies a significant anastomotic stenosis is unknown, is controversial, and there are no standards reported.[5,7,15] Most operators use a gradient >4 to 5 mm Hg as an indication for a significant PVS, although some use 3 mm Hg or 8 mm Hg gradients as a threshold.[5,27] In my opinion,[15] there are several reasons for these discrepant reports. First, the case numbers are small and there are numerous variables with liver transplantation. This is complicated by the fact that normalization of the graft dysfunction after treatment may not occur quickly and may be coincidental, if it occurs at all. Second, it is difficult to make a threshold gradient cutoff of a relative measurement, particularly when there can be considerable variations in the portal pressure that affect the measurements. Third, there maybe portosystemic collaterals (including splenorenal or gastrorenal shunts; see later) that decompress the portal circulation of the recipient distal to the anastomosis, and as a result they reduce the portal pressure gradient across the portal anastomosis. Fourth, there is shunting of blood from the hepatic artery to the portal vein, mediated by the hepatic artery buffer response, when there is reduction of flow in the portal vein (due to the stenosis). This may alter pressures and may even redirect normal portal blood flow from hepatopetal to hepatofugal (see article in this issue on nonocclusive hepatic artery hypoperfusion syndrome).[15]

Management

Traditionally, the management of portal vein stenoses was surgical, either by primary repair after resecting the adhesed and scarred anastomosis or by retransplantation.[7,28] However, in 1990 Olcott and coworkers reported the first documented posttransplant PVS balloon dilation.[7,29] From then on, there has been a paradigm shift in which surgery has been largely replaced by catheter-directed endovascular procedures, due to the latter's less invasive nature and reduced periprocedural morbidity.[7]

The percutaneous transhepatic approach is preferred over the TIPS approach for portal vein access.[7,15,23] The TIPS approach has been described elsewhere.[7,30–32] However, this approach takes longer, is more cumbersome, and does not give enough "running room" to the portal anastomoses because the TIPS portal access site is usually close to the PVS.[15] Moreover, the TIPS approach is almost always malaligned with the long axis of the portal vein, making transcatheter manipulations more difficult.[15] Alternatively, most portal veins are easily accessed under ultrasound and/or fluoroscopy via a percutaneous transhepatic approach, which is directly in line with the long axis of the portal vein as well as a more appropriate distance from the puncture to the anastomosis.[15] The direct tract through the liver provides the best mechanical advantage for negotiating severe stenoses.[11,23]

The right percutaneous intercostal approach is more common than a left-sided subxiphoid approach in whole grafts. However, the right intercostal approach likely has a higher risk of bleeding and pleural injury compared with the left portal approach.[15] Intravenous heparin may be given to help reduce the risk of thrombosis during the angioplasty, and postangioplasty anticoagulation is given for 24 to 72 hours after the procedure. Long-term postangioplasty anticoagulation is typically unnecessary.[11] If placement of a stent becomes necessary, self-expanding bare stents are usually used.[11]

Funaki and coworkers found that a third of 30 patients undergoing percutaneous intervention had intraprocedural recoil immediately after angioplasty, requiring immediate stent placement. Of the remaining two-thirds of patients with adequate response to balloon angioplasty, half (one third of the overall population) restenosed 1 to 31 months (mean: 6 months) after the initial angioplasty.[11] Failures of angioplasty (intraprocedural or delayed restenoses) were treated with stent placement with good long-term results.[11] Two complications (7%), both portal vein thromboses, occurred in their experience;[11,23] however, both patients responded favorably to transcatheter thrombolysis.[11,23] When considering the long-term success of a single balloon dilation without stent placement, the results are variable with a long-term patency/success of 36 to 71% at 2 to 3 years.[6,11] When distinguishing pediatric split grafts and adult whole liver grafts, the reported restenosis rates following balloon angioplasty alone are 29 to 37% versus 20%, respectively.[7,20,33]

From a conservative standpoint, stents are usually considered only for intraprocedural recoil and early restenosis (within 6 months) after a technically successful angioplasty.[15] This is because stents may impede future surgeries (retransplantation) and, in the pediatric recipient population, may cause focal narrowing at the stent edge due to graft and recipient growth (stents do not grow with the patient and graft, and thus they may form a relative narrowing).[5,8] The patency results of stents in portal veins is scant. Most stents are self-expanding, and the patency is reported to be as high as 100% over 3 to 5 years.[11,33] Complications from portal vein angioplasty or stent placement include portal vein thrombosis, hemoperitoneum, and hemothorax.[7,11,23,33]

Portal Vein Thrombosis

Incidence and Presentation

Portal venous thrombosis (PVT) is an uncommon complication, occurring in 1 to 4% of transplants.[6,9,11,34] PVT can be classified as early (within a month after transplant) or late (more than a month after transplant) (PVS2). Most PVTs occur within a month after from the transplant.[11,23,34,35] It is likely that >80% of PVT cases are diagnosed within a month (early PVT) from the transplant.[9] Early PVT is more likely to cause graft loss than late PVT.[9] Hypothetically, the causes of early PVT include suboptimal grafts, hypercoagulable states, portal venous stasis, and possibly underlying anatomical defects such as a PVS or kinks. Late PVT may actually be early PVT that was overlooked or thrombosis due to portal vein stenosis and/or kinks. PVT has been described as iatrogenic from intraprocedural angioplasty[11] or secondary to previously placed stents for PVS.[14]

Similar to severe PVS, PVT may present with signs of portal hypertension. If asymptomatic, nonspecific liver function test

abnormalities may be encountered.[18,23,35] Early PVT has a poor prognosis, with up to 100% of cases leading to graft loss.[9] Overall, PVT leads to a reduction in 5-year graft survival when compared with liver transplant recipients without portal vein complications.[16]

Imaging Diagnosis

Doppler ultrasound may demonstrate lack of flow, or echogenic thrombus may be seen.[23,36] Power Doppler should be used to increase the sensitivity of Doppler because conventional Doppler ultrasound may mistakenly perceive very slow flow in the portal vein as PVT. Acute thrombus may cause an increase in the diameter of the portal vein, which can also be observed on Doppler ultrasound, CT, or MRI.

Management

Unlike PVS, where percutaneous transhepatic access is most commonly used, the portal venous approach for PVT varies from one operator/institution to another and can vary from one circumstance to the other.[15] The advantages of the TIPS approach is that it may reduce the risk of intraperitoneal bleeding.[15] In addition, establishing a TIPS shunt can provide outflow to the portal vein, especially if the intrahepatic portal branches are thrombosed with a clot that is recalcitrant to fibrinolysis.[15] Furthermore, a TIPS provides a larger caliber access that allows larger platforms to be introduced to the portal vein. As a result, percutaneous thrombectomy can be performed through the TIPS from a transjugular approach by pulling a Fogarty catheter from the portal vein and into the inferior vena cava.[15] The disadvantages of a TIPS approach is that a TIPS is a more involved procedure that takes longer, has more complications, may need anesthesia, and provides little "running room" to the portal vein anastomosis in case a stent needs to be placed.[15]

The advantages of the percutaneous transhepatic approach were discussed earlier. The disadvantage of this approach is that it may have an increased bleeding risk with the use of thrombolytics/fibrinolytics.[15] Various combinations of mechanical and pharmaceutical thrombolytic devices, drugs, and techniques can be utilized. Adjunct stent deployment has been used to minimize, if not avoid, pharmaceutical fibrinolysis and thus reduce the length of the procedure and the risk of bleeding.[37] The additional advantage of stent placement in the setting of PVT is that it addresses underlying portal venous stenosis, if any is to be found.[11,37]

The experience in transcatheter management of PVT in liver transplant recipients is very scant in the literature.[6,11,18,29,34–39] As a result, definitive conclusions cannot be drawn regarding complications, technical successes, and longevity of successful procedures. Transcatheter management is most likely applicable to late symptomatic PVT. The technical success is probably ~55 to 70% and the mid- to long-term patency is probably on the order of 50 to 60%.[6,35] Iatrogenic PVT following balloon angioplasty for portal vein stenosis is very successful when performed within the same session. It can typically be performed without the use of infusion catheter thrombolysis because the clot is fresh and the underlying PVS has already been identified and treated.[11,15]

Recurrent Portal Hypertension or Consequences of Pretransplant Portal Hypertension

Recurrent portal hypertension after liver transplantation is commonly due to recurrent hepatitis C, late graft failure (primary unexplained hepatic graft failure with cirrhosis), and possibly poor grafts in the first place.[40–42] However, one must understand that the presence of portosystemic collaterals after transplantation, gastric varices with their gastrorenal shunts included, is not necessarily evidence of posttransplant portal hypertension recurrence but may instead be a product of pretransplant portal hypertension. In this setting, one possibility is that the portosystemic collaterals simply did not resolve and were not ligated by the transplant surgeons. It is the case, however, that posttransplant portal hypertension can develop, if not promote, these collaterals.

Transjugular Intrahepatic Portosystemic Shunts

TIPS is the most common interventional radiology procedure performed for portal hypertension recurrence after liver transplantation. TIPS is performed in up to 2% of transplant recipients, and TIPS in transplanted livers represents up to 5 to 6% of all TIPS.[41] The primary leading causes of requiring a TIPS is viral hepatitis recurrence (especially hepatitis C) and primary hepatic graft failure.[40–42] Approximately 80 to 90% of transplants undergoing TIPS are placed due to a transudative complication (ascites and/or hepatic hydrothorax) of portal hypertension.[40,41]

There are no great differences in the technical steps of a TIPS in a transplanted liver compared with TIPS in a native liver. Furthermore, TIPS in transplanted whole grafts appears to be no more technically challenging than TIPS in native livers[41] However, TIPS in whole grafts may be more challenging in institutions where piggyback anastomoses (end-to-side cava-to-cava hepatic graft venous outflow anastomosis) are performed commonly, especially when the piggyback is angulated downward.[41] TIPS in split grafts, especially left lobe split grafts in children, are also typically more challenging than in native livers.[40,41,43] This is due to several reasons: split grafts are small livers with less distance to enter the portal vein target; the orientation is backward in left-sided grafts, and interventionalists are used to a right lobe orientation; undersized grafts (typically split grafts) undergo compensatory hypertrophy that is not necessarily uniform and thus the grafts grow nonuniformly; and the graft is rotated, causing unconventional portohepatic venous orientations.[41,43]

The clinical outcomes of TIPS in transplants appear to be worse when compared with native livers.[40,41] First, TIPS in transplants appear to lead to a worse response in the treatment of ascites when compared with native livers.[40,41] Second, hepatic grafts appear to be more susceptible to the post-TIPS changes in portal hemodynamics. The MELD (Model for End-Stage Liver Disease) score threshold for livers that do well

after TIPS appears to be lower in transplants (MELD of 15 to 17) compared with native livers (MELD of 17 to 19).[41,43,44]

Balloon-Occluded Retrograde Transvenous Obliteration (BRTO)

BRTO of gastric varices, or any form of embolization of portosystemic collaterals in liver transplant recipients, have rarely been reported in large numbers within case series to draw any definite conclusion regarding liver transplantation per se.

The indications for BRTO in the treatment of gastric varices/splenorenal shunts in liver transplant recipients includes gastric variceal bleeding or impending bleeding; encephalopathy; portal venous steal from the hepatic graft (significant portal hepatofugal flow); and as an adjunct to other portal vein procedures for posttransplant portal vein complications (PVS or PVT).[45] Although the first two indications are not specific to the transplant population, the last two indications are. The concept of occluding large or hemodynamically significant portosystemic shunts while managing portal vein stenosis is to optimize hepatopetal flow in the stenotic portal vein to the portal-venous deprived hepatic graft, and to maintain patency of the portal vein by reducing the risk of PVT.

However, using BRTO in the treatment of patients with PVT poses a dilemma. On one hand, closure of a large hepatofugal portosystemic collateral diverts blood toward the liver and maximizes the inflow to the recently opened portal vein, reducing the risk of rethrombosis. However, on the other hand, the large hepatofugal portosystemic collateral may be the only outflow of the mesenteric veins in the presence of portal vein rethrombosis. In that scenario (thrombosed portal vein and loss of the "back-up" spontaneous hepatofugal mesenteric outflow), patients may present with mesenteric engorgement, ischemia, and/or thrombosis. Because all spontaneous portosystemic shunts are extrahepatic, there are no differences in the technical aspects of BRTO in a transplanted liver compared with BRTO in a native liver.

Conclusion

Portal complications after liver transplantation are rare. Minimally invasive image-guided transcatheter techniques are technically and clinically effective in managing posttransplant portal complications. TIPS in whole-graft transplants is technically no more challenging than TIPS in native livers; however, TIPS in split grafts may be more technically challenging. Moreover, TIPS has a lesser clinical response in patients with transplants compared with patients with native (nontransplanted) liver cirrhosis. Technically, BRTO is no different in native livers and nontransplant recipients because it is by definition an extrahepatic procedure. However, the scarcity of reporting of BRTO in transplants in the literature does not enable us to define clinical outcomes.

References

1 Wozney P, Zajko AB, Bron KM, Point S, Starzl TE. Vascular complications after liver transplantation: a 5-year experience. AJR Am J Roentgenol 1986;147(4):657–663

2 Langnas AN, Marujo W, Stratta RJ, Wood RP, Shaw BW Jr. Vascular complications after orthotopic liver transplantation. Am J Surg 1991;161(1):76–82; discussion 82–83

3 Lerut J, Tzakis AG, Bron K, et al. Complications of venous reconstruction in human orthotopic liver transplantation. Ann Surg 1987;205(4):404–414

4 Settmacher U, Nussler NC, Glanemann M, et al. Venous complications after orthotopic liver transplantation. Clin Transpl 2000;14:235–241

5 Woo DH, Laberge JM, Gordon RL, Wilson MW, Kerlan RK Jr. Management of portal venous complications after liver transplantation. Tech Vasc Interv Radiol 2007;10(3):233–239

6 Ueda M, Egawa H, Ogawa K, et al. Portal vein complications in the long-term course after pediatric living donor liver transplantation. Transplant Proc 2005;37(2):1138–1140

7 Schneider N, Scanga A, Stokes L, Perri R. Portal vein stenosis: a rare yet clinically important cause of delayed-onset ascites after adult deceased donor liver transplantation: Two case reports. Transpl Proc 2011;43:3829–3834

8 Buell JF, Funaki B, Cronin DC, et al. Long-term venous complications after full-size and segmental pediatric liver transplantation. Ann Surg 2002;236(5):658–666

9 Khalaf H. Vascular complications after deceased and living donor liver transplantation: a single-center experience. Transpl Proc 2010;42:865–870

10 Raby N, Karani J, Thomas S, O'Grady J, Williams R. Stenoses of vascular anastomoses after hepatic transplantation: treatment with balloon angioplasty. AJR Am J Roentgenol 1991;157(1): 167–171

11 Funaki B, Rosenblum JD, Leef JA, et al. Percutaneous treatment of portal venous stenosis in children and adolescents with segmental hepatic transplants: long-term results. Radiology 2000;215(1): 147–151

12 Funaki B, Rosenblum JD, Leef JA, Hackworth CA, Szymski GX, Alonso EM. Angioplasty treatment of portal vein stenosis in children with segmental liver transplants: mid-term results. AJR Am J Roentgenol 1997;169(2):551–554

13 Rollins NK, Sheffield EG, Andrews WS. Portal vein stenosis complicating liver transplantation in children: percutaneous transhepatic angioplasty. Radiology 1992;182(3):731–734

14 Zajko AB, Sheng R, Bron K, Reyes J, Nour B, Tzakis A. Percutaneous transluminal angioplasty of venous anastomotic stenoses complicating liver transplantation: intermediate-term results. J Vasc Interv Radiol 1994;5(1):121–126

15 Saad WEA. Liver transplant-related vascular disease. In: Dake M, Geshwind J-F, eds. Abrams Angiography: Interventional Radiology. 2012. 3rd ed. Philadelphia, PA: Lippincott Williams & Wilkins

16 Millis JM, Seaman DS, Piper JB, et al. Portal vein thrombosis and stenosis in pediatric liver transplantation. Transplantation 1996; 62(6):748–754

17 Mantel HT, Rosen CB, Heimbach JK, et al. Vascular complications after orthotopic liver transplantation after neoadjuvant therapy for hilar cholangiocarcinoma. Liver Transpl 2007;13(10): 1372–1381

18 Cherukuri R, Haskal ZJ, Naji A, Shaked A. Percutaneous thrombolysis and stent placement for the treatment of portal vein thrombosis after liver transplantation: long-term follow-up. Transplantation 1998;65(8):1124–1126

19 Mathias K, Bolder U, Löhlein D, Jäger H. Percutaneous transhepatic angioplasty and stent implantation for prehepatic portal vein obstruction. Cardiovasc Intervent Radiol 1993;16(5):313–315

20 Park KB, Choo SW, Do YS, Shin SW, Cho SG, Choo IW. Percutaneous angioplasty of portal vein stenosis that complicates liver transplantation: the mid-term therapeutic results. Korean J Radiol 2005;6(3):161–166

21 Sood D, Kumaran V, Kakodkar R, et al. Portal vein stenosis following living donor liver transplant: manifestations and management. Transpl Int 2009;22(4):496–499

22 Wei B-J, Zhai R-Y, Wang J-F, Dai D-K, Yu P. Percutaneous portal venoplasty and stenting for anastomotic stenosis after liver transplantation. World J Gastroenterol 2009;15(15):1880–1885
23 Saad WE, Waldman DL. Endovascular repair of vascular lesions in solid organ transplantation. In Oriel K, Katzen BT, Rosenfield K, eds. Complications in Endovascular Therapy. New York, NY: Taylor & Francis Informa; 2006;223–252
24 Saad WE, Lin E, Ormanoski M, Darcy MD, Rubens DJ. Noninvasive imaging of liver transplant complications. Tech Vasc Interv Radiol 2007;10(3):191–206
25 Chong WK, Beland JC, Weeks SM. Sonographic evaluation of venous obstruction in liver transplants. AJR Am J Roentgenol 2007;188:W515–W521
26 Quiroga S, Sebastià MC, Margarit C, Castells L, Boyé R, Alvarez-Castells A. Complications of orthotopic liver transplantation: spectrum of findings with helical CT. Radiographics 2001;21(5): 1085–1102
27 Shibata T, Itoh K, Kubo T, et al. Percutaneous transhepatic balloon dilation of portal venous stenosis in patients with living donor liver transplantation. Radiology 2005;235(3):1078–1083
28 Duffy JP, Hong JC, Farmer DG, et al. Vascular complications of orthotopic liver transplantation: experience in more than 4,200 patients. J Am Coll Surg 2009;208(5):896–903; discussion 903–905
29 Olcott EW, Ring EJ, Roberts JP, Ascher NL, Lake JR, Gordon RL. Percutaneous transhepatic portal vein angioplasty and stent placement after liver transplantation: early experience. J Vasc Interv Radiol 1990;1(1):17–22
30 González-Tutor A, Abascal F, Cerezai L, Bustamante M. Transjugular approach to treat portal vein stenosis after liver transplantation—a case report. Angiology 2000;51(6):511–514
31 Cheng YF, Ou HY, Tsang LL, et al. Interventional percutaneous trans-splenic approach in the management of portal venous occlusion after living donor liver transplantation. Liver Transpl 2009;15(10):1378–1380
32 McDaniel HM, Johnson M, Pescovitz MD, et al. Intraoperative placement of a Wallstent for portal vein stenosis and thrombosis after liver transplantation. Transplantation 1997;63(4): 607–608
33 Ko GY, Sung KB, Yoon HK, Lee S. Early posttransplantation portal vein stenosis following living donor liver transplantation: percutaneous transhepatic primary stent placement. Liver Transpl 2007;13(4):530–536
34 Baccarani U, Gasparini D, Risaliti A, et al. Percutaneous mechanical fragmentation and stent placement for the treatment of early post-transplantation portal vein thrombosis. Transplantation 2001;15: 1572–1582
35 Durham JD, LaBerge JM, Altman S, et al. Portal vein thrombolysis and closure of competitive shunts following liver transplantation. J Vasc Interv Radiol 1994;5(4):611–615, discussion 616–618
36 Glockner JF, Forauer AR. Vascular or ischemic complications after liver transplantation. AJR Am J Roentgenol 1999;173(4): 1055–1059
37 Davidson BR, Gibson M, Dick R, Burroughs A, Rolles K. Incidence, risk factors, management, and outcome of portal vein abnormalities at orthotopic liver transplantation. Transplantation 1994;57 (8):1174–1177
38 Ciccarelli O, Goffette P, Laterre PF, Danse E, Wittebolle X, Lerut J. Transjugular intrahepatic portosystemic shunt approach and local thrombolysis for treatment of early posttransplant portal vein thrombosis. Transplantation 2001;72(1):159–161
39 Haskal ZJ, Naji A. Treatment of portal vein thrombosis after liver transplantation with percutaneous thrombolysis and stent placement. J Vasc Interv Radiol 1993;4(6):789–792
40 Saad WEA, Darwish WM, Davies MG, Butani D, Waldman DL. Transjugular intrahepatic portosystemic shunts in liver transplant recipients for management of refractory ascites: clinical outcome. J Vasc Interv Radiol 2010;218–223
41 Saad WEA, Darwish WM, Davies MG, et al. Transjugular intrahepatic portosystemic shunts (TIPS) in liver transplant recipients: technical analysis and clinical outcomes. AJR Am J Roentgenol; In press
42 Lerut JP, Goffette P, Molle G, et al. Transjugular intrahepatic portosystemic shunt after adult liver transplantation: experience in eight patients. Transplantation 1999;68(3):379–384
43 Saad WEA, Davies MG, Lee DE, et al. Transjugular intra-hepatic porto-systemic shunt in a living donor left lateral segment liver transplant recipient: technical considerations. J Vasc Interv Radiol 2005;16:873–877
44 King A, Masterton G, Gunson B, et al. A case-controlled study of the safety and efficacy of transjugular intrahepatic portosystemic shunts after liver transplantation. Liver Transpl 2011;17(7): 771–778
45 Saad WEA, Sabri SS. Balloon-occluded transvenous obliteration (BRTO): technical results and outcomes. Semin Interv Radiol 2011;28:333–338