



B. Ramlawi, M.D.

TRANSCATHETER AORTIC VALVE REPLACEMENT (TAVR): ACCESS PLANNING AND STRATEGIES

Basel Ramlawi, M.D.; Javier E. Anaya-Ayala, M.D.; Michael J. Reardon, M.D.

Methodist DeBakey Heart & Vascular Center, The Methodist Hospital, Houston, Texas

Abstract

Transcatheter aortic valve replacement (TAVR) has proven to be a viable tool for the high-surgical-risk population with severe aortic valve stenosis. Vascular access complications are not uncommon with TAVR and may increase early and late mortality. Avoiding these serious complications is the goal. With experience and careful screening, we are now able to risk-stratify patients who may be at increased risk of vascular complications. While the traditional iliofemoral access site remains the most common for TAVR, alternate access sites that have proven to be viable and safe alternatives include the transapical, direct-aortic, and subclavian techniques. TAVR teams should be familiar and comfortable with these approaches as each of them has its own advantages and weaknesses. The best option is usually one in which the procedure is tailored to the patient. The present review examines our current access planning and strategies for TAVR.

Introduction

Aortic valve replacement is a class I indication for patients with severe aortic stenosis and symptoms in the ACC/AHA guidelines for the treatment of cardiac valvular disease.¹ Since some patients can be judged too high a risk to undergo surgery, they may be denied aortic valve replacement. Transcatheter aortic valve replacement (TAVR) has been developed as a potential option for this patient group. To date, there are two studies that have evaluated two valve devices: The PARTNER Trial using the Edwards SAPIEN valve, which was approved for use in nonsurgical candidates by the FDA in December 2011,^{2,3} and the CoreValve US Pivotal Trial (using the Medtronic CoreValve) that is currently active and accruing patients. Both of these devices require large bore access for placement. The Edwards SAPIEN valve used in the PARTNER Trial can be inserted using an iliofemoral access or a transapical cardiac access. For the valves used in the PARTNER Trial, the small valve (23 mm) required a 22-Fr sheath and the large valve (26 mm) required a 24-Fr sheath for iliofemoral access. Both valves used a 26-Fr sheath when direct transapical cardiac insertion was used in patients who were not candidates for iliofemoral access. A newer version, the SAPIEN XT, can be inserted using an 18-Fr sheath via the iliofemoral route. The Medtronic CoreValve currently comes in 23 mm, 26 mm, 29 mm, and 31 mm sizes and all are inserted through an 18-Fr sheath. For both valves, the femoral route is the preferred method of insertion whenever possible. When iliofemoral access is not possible with the CoreValve, both subclavian artery and direct aortic approaches have been used.

Planning access for TAVR requires knowledge of the luminal size as well as the degree of vessel calcification and tortuosity. We consider a high-quality thin-slice CT scan with contrast that extends from the femoral artery to the subclavian artery the cornerstone of evaluation. Arteriography and intravascular ultrasound (IVUS) can add additional data but are not considered acceptable as standalone imaging modalities. For the non-

interventionist, it is important to remember that the size of the catheters to be used is listed as the outer diameter (OD), while the size of the sheaths to be used is listed as the inner diameter (ID). In the French sizing system, 3 Fr equals 1 mm — therefore, the ID of the 18-Fr, 22-Fr, and 24-Fr sheaths are 6 mm, 7 mm, and 8 mm respectively. In general, the outer diameter is about 1 mm larger, which is important in planning access. In noncalcified arteries, we can generally insert a sheath through an artery that is about 0.75% of the sheath's outer diameter; in a heavily or circumferentially calcified artery, we need an artery that is 1.25% of the sheath's outer diameter. This translates into minimal vessel diameters of 6 mm, 7 mm, and 8 mm in noncalcified arteries and 7 mm, 8 mm, and 9 mm for heavily calcified arteries using the 18-Fr, 22-Fr, and 24-Fr sheaths, respectively. Most tortuosity will straighten adequately for sheath insertion once a stiff wire is placed, but extreme tortuosity should be avoided as it may lead to sheath kinking and an inability to deliver the device. Two special circumstances deserve mention. The first is previously placed Dacron grafts in the aortoiliac position. These may prove problematic to cross with large sheaths as they can accordion and bind the sheaths. While they may be used, the size, path, and any redundancy of the graft should be considered. Second, abdominal aortic aneurysm (AAA) can pose a hazard in crossing and device insertion if the sheath ends within the aneurysm itself. If the iliofemoral route is to be used with an AAA, it is important to choose a sheath with enough length to extend above the AAA so that all device changes occur outside of and not within the AAA. At the Methodist DeBakey Heart & Vascular Center (MDHVC), our approach is to always use the iliofemoral route when possible. Vascular complications are common with TAVR and can increase early and late mortality, and they are best avoided by careful screening and choosing a non-iliofemoral approach in questionable cases. This manuscript discusses our approach to TAVR access, closure, and complications that can occur.

Femoral Access

Femoral access is the preferred placement methodology when possible, and we have discussed our requirements in considering this approach above. We generally access both femoral arteries for femoral access TAVR — one femoral artery is for placement of the 18-Fr sheath, and the other is for placement of a 5-Fr graduated pigtail catheter through a 6-Fr sheath into the noncoronary sinus as a marker for valve placement and to allow arteriography during placement for positioning. We occasionally use access from the arm for this. The nondevice sheath femoral artery is punctured first using a micro puncture needle, and a 6-Fr sheath is placed after fluoroscopic confirmation of appropriate wire position from the micro puncture needle. A contra or a LIMA catheter and a 0.035-mm glide wire are used to access the opposite iliofemoral system and then place a 0.018-mm safety wire. The safety wire allows access contralateral to the iliofemoral system on the sheath side if injury is noted during sheath insertion or removal. The sheath side may be accessed by direct surgical cut down or percutaneously, which is our preferred approach when appropriate. For the percutaneous approach we use fluoroscopy and the safety wire to guide puncture of the common femoral artery and placement of a 6-Fr sheath. A soft, J-tipped 0.035-mm wire is placed into the descending thoracic aorta (DTA), and two ProGlide closure devices are used to “pre-close” the puncture site. The soft J-tipped wire and an exchange catheter are inserted into the DTA. The soft wire is exchanged for a super-stiff Amplatz wire, and the catheter and 6-Fr sheath are removed. Progressive dilators of 10 Fr, 12 Fr, 14 Fr, and 18 Fr are used to dilate the access vessels, and the 18-Fr sheath is then inserted into the proximal abdominal aorta. Balloon aortic valvuloplasty and subsequent device placement are then done through the 18-Fr sheath.

Noniliofemoral Access

Femoral access is our preferred insertion route. When this is not possible or safe, we use a noniliofemoral approach. Since the MDHVC is a CoreValve Trial site, we use the subclavian artery as our next option and, after that, a direct aortic option if subclavian artery insertion is not possible or safe. We have recently begun implantation of the Edwards SAPIEN Valve, which may be inserted directly through the left ventricular apex via a small left thoracotomy or by the direct aortic approach.

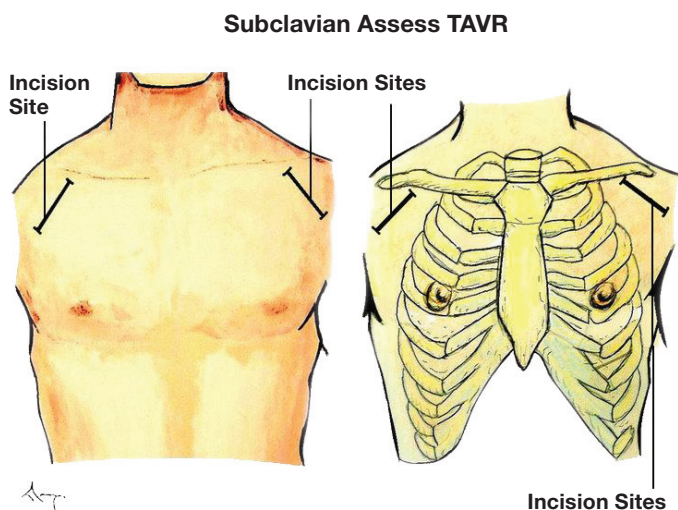


Figure 1. Schematic drawing demonstrating the access site for a subclavian access.

Subclavian Access

The subclavian artery has recently become a site of access for TAVR.^{4,5} The subclavian artery can be easily exposed in the deltopectoral groove of the anterior chest wall (Figure 1). We make a 3-cm incision in the deltopectoral groove that is carried down to the fibers of the pectoralis major, which are split along the lines of their fibers and retracted. The pectoralis minor can then be retracted or divided to expose the subclavian artery. It is important to remember that the brachial plexus is just superior to the subclavian artery, and care should be taken in this dissection. The artery is surrounded with a vessel loop and a purse-string suture of 5-0 polypropylene placed in the anterior artery wall. The center of this purse string is punctured with a standard needle, and a soft, J-tip 0.035 wire is placed with a 6-Fr sheath placed over this. A catheter is placed over the wire into the ascending aorta, and then the soft wire is exchanged for a super stiff Amplatz wire. Dilators of 10 Fr, 12 Fr, 14 Fr, and 18 Fr are then passed over the stiff wire. This allows the 18-Fr sheath to then be passed through the subclavian artery into the proximal ascending aorta. From this point the device insertion follows a standard procedure. In general,

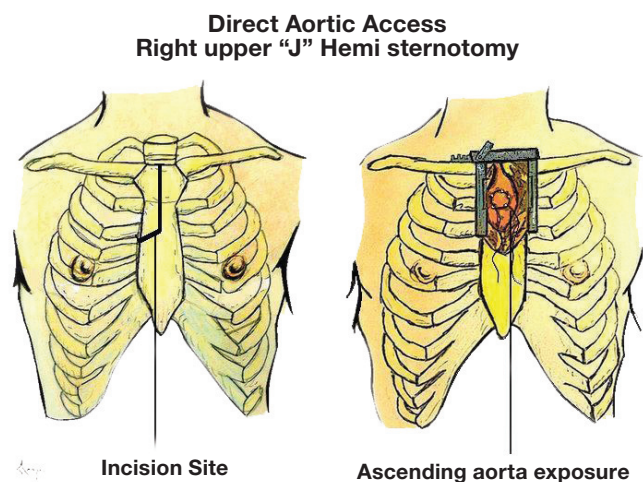


Figure 2. Direct Aortic, Upper J hemisternotomy.

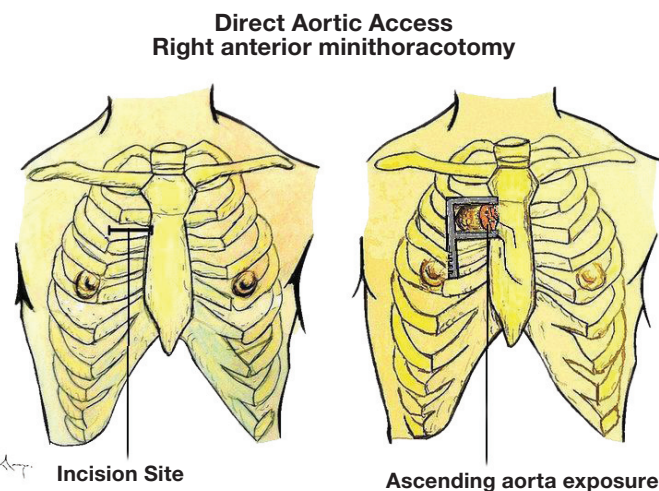


Figure 3. Direct aortic, right anterior minithoracotomy.

we have found it easier to insert and control the position of the device due to the proximity of the insertion site to the annulus. After the sheath is withdrawn at the end of the procedure, the purse-string suture is tied and additional sutures placed under direct vision as needed.

Two points should be noted when using the subclavian artery. Use of the right subclavian artery is possible but becomes technically difficult for device positioning if the aortic valve annulus is much more than 30 degrees off the horizontal plane. Additionally, if a patent internal mammary artery (IMA) graft is present, ischemia must be carefully watched for since sheath obstruction or artery injury can limit flow during or after device placement. (To access a video of the subclavian access approach, visit www.debakeyheartcenter.com/journal/video.)



Direct Aortic Access

When iliofemoral or subclavian access is not possible, a direct aortic approach can be carried out via a small right upper “J” hemisternotomy (Figure 2) or a small right anterior thoracotomy (Figure 3).^{6,7} Both approaches allow exposure of the proximal ascending thoracic aorta. The pericardium is opened and sutured to the skin edges to create a cradle in which to work and serve as retractors to keep lung and mediastinal tissues out of the working field. Two concentric pledgetted purse-string sutures of 3-0 polypropylene are placed at the intended insertion site. The center of these sutures is punctured with a standard needle; similar to subclavian access, a soft J-tip 0.035 wire is placed and a 6-Fr sheath placed over that. We then use an AL1 catheter and a soft straight-tip 0.035 wire to cross the aortic valve. The AL1 catheter is advanced into the left ventricle (LV) and a soft 0.035 J wire is placed. An angled 6-Fr pigtail catheter is then placed over this wire into the LV. A super-stiff Amplatz wire is then advanced over the pigtail catheter into the LV for support. The pigtail catheter is removed with the 6-Fr sheath, and the 18-Fr sheath is inserted. All currently available sheaths are intended for peripheral insertion and therefore have a long dilator segment and no “bumper” on the catheter to seat against the aortic wall, as have most aortic cannulae for cardiopulmonary bypass (CPB).

To insert a Medtronic CoreValve, we need 55 mm for the length of the valve itself and a planned 10 mm for the sheath in the aorta as the depth of sheath insertion into the aorta. Prior to sheath placement we obtain an arteriogram with a graduated pigtail catheter in the non coronary cusp of the aortic valve and a marker at the site of planned sheath insertion to assure that at least 65 mm of space exist from the planned depth of valve insertion to the sheath itself to allow for valve release. We currently modify a standard 18-Fr sheath by placing a silicone ring from an aortic cannula to mark the 1-cm mark, which controls insertion depth. Once inserted, one of the purse-string sutures is tightened with a tourniquet and tied to the cannula. The other is tightened with a tourniquet but not tied to the cannula to allow rapid tightening if the cannula is to dislodge in any way. With little cannula inside the aorta, we suture the cannula to the skin with a second suture for added security. Valve insertion tends to be relatively easy with this approach as the operator is close to the insertion site and has not had to come around the arch, so that much less tension builds within the catheter system. When finished, the purse strings are tied under direct vision similar to decannulation after CPB. Chest wall closure is in standard surgical fashion. The hemisternotomy

Direct Transapical Approach TAVR

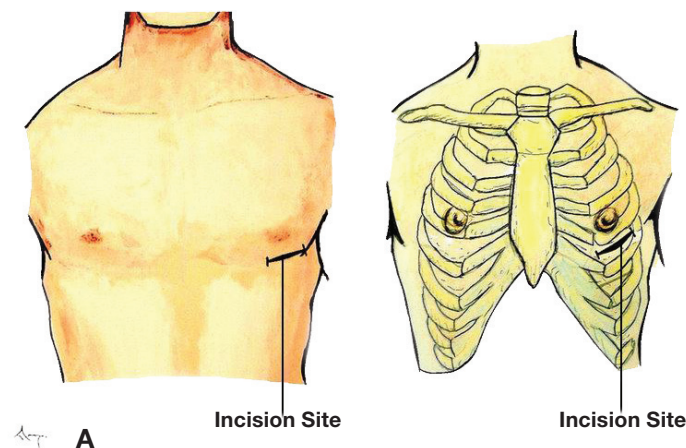
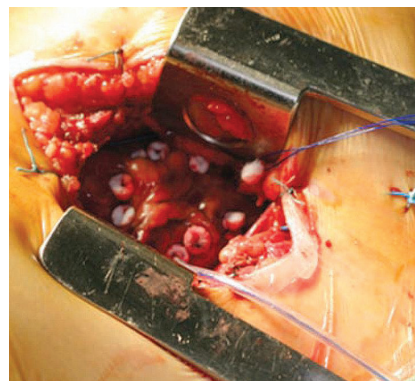


Figure 4. (A) Schematic drawing demonstrates the access site location for transapical approach. (B) Intraoperative picture.

Images courtesy of Dr. Thomas Walther.¹¹



approach has the advantage of not transgressing the pleura and usually gives a broader field of aorta to choose from for insertion. The thoracotomy approach has the advantage of avoiding patent coronary bypass grafts which are usually on the left side of the aorta, and in that future refinement could lead to a port-access approach. (To access videos of a direct aortic access mini sternotomy and right anterior mini thoracotomy, visit www.debakeyheartcenter.com/journal/video.)



Transapical

The Edwards SAPIEN valve has been inserted using a direct transapical approach in patients without suitable iliofemoral vessels. A small left anterior thoracotomy is made to expose the apex of the LV after opening the pericardium (Figures 4A, 4B). The pericardium can be sutured to the skin edges to expose and stabilize the heart. Two concentric purse-string polypropylene sutures are placed with generous bites of the ventricular wall. The 26-Fr transapical sheath can be inserted directly into the LV apex inside of these purse-string sutures. After valve deployment, rapid ventricular pacing is used during sheath removal and suture tying to reduce pressure until the repair is complete.

Transapical vs. Direct Aortic

Transapical and direct aortic have the disadvantage of both being “surgical” procedures that violate a body cavity. Neither destabilizes the chest wall as the thoracic cage is left intact. Both avoid crossing the aortic arch with the device during delivery and this has theoretical advantages in stroke prevention. Both allow delivery of the valve from an area much closer and without the tension inherent in a curved system such as the delivery system going around the aortic arch. Operators have generally found implantation to be easier and more accurate with these approaches. One significant difference is that the direct aortic approach can be used with both the CoreValve and the SAPIEN valve while the transapical can be used with the SAPIEN alone. Most cardiac surgeons have cannulated the ascending aorta hundreds to thousands of times in their careers for standard cardiac surgery and are very comfortable with this technique, whereas few have substantial experience with the cardiac apex.

Closure

All non-iliofemoral and open-access femoral approaches are closed under direct vision using standard surgical techniques. We use two ProGlide devices to close our percutaneous iliofemoral access cases. Technical aspects of closure and results have been previously reported and are not the subject of this manuscript.⁸ An arteriogram is obtained after femoral or subclavian closure to insure vessel patency without flow-limiting lesions prior to leaving the hybrid room.

Complications

TAVR is a complex procedure in high-risk patients, and a large number of complications are possible. The most common complications are vascular and related to access. Early papers on TAVR complications can be difficult to interpret due to a lack of uniform definitions for the complications. Recently, the Valve Academic Research Consortium (VARC) issued a consensus report suggesting definitions for vascular complications to allow standardization and comparison between studies.⁹ Major bleeding complications occurred in 16.2% of TAVR patients in the PARTNER B trial and 11.0% of TAVR patients in the PARTNER A trial.^{2,3} Bleeding complications tend to occur more frequently and be more severe in transapical cases. Follow-up of patients who experience and survive a major bleeding event shows that it has an adverse effect on midterm survival.¹⁰ Avoiding major vascular complications requires careful patient screening and selection. Since complications can never be completely eliminated, it is important for the TAVR implanter to ensure that large occlusion balloons, covered stents, surgical instruments, and blood are readily available and to inform ancillary staff of plans should complications arise. Most importantly, the operator should not hesitate to use non-iliofemoral access if the iliofemoral vessels are inadequate.

Conflict of Interest Disclosure: All authors have completed and submitted the *Methodist DeBakey Cardiovascular Journal* Conflict of Interest Statement and the following was reported: Dr. Reardon is a consultant for Medtronic and is a principal investigator for the CoreValve® US Pivotal Trial.

Funding/Support: The authors have no funding disclosures.

Keywords: transcatheter aortic valve replacement, TAVI, TAVI access, iliofemoral access, femoral access, aortic stenosis, PARTNER trial, Edwards SAPIEN valve, Medtronic CoreValve, ProGlide device

References

1. Bonow RO, Carabello BA, Chatterjee K, de Leon AC Jr, Faxon DP, Freed MD, et al. 2008 focused update incorporated into the ACC/AHA 2006 guidelines for the management of patients with valvular heart disease: a report of the American College of Cardiology/American Heart Association Task Force on Practice Guidelines (Writing Committee to revise the 1998 guidelines for the management of patients with valvular heart disease). Endorsed by the Society of Cardiovascular Anesthesiologists, Society for Cardiovascular Angiography and Interventions, and Society of Thoracic Surgeons. *J Am Coll Cardiol*. 2008 Sep 23;52(13):e1-142.
2. Leon MB, Smith CR, Mack M, Miller DC, Moses JW, Svensson LG, et al. Transcatheter aortic-valve implantation for aortic stenosis in patients who cannot undergo surgery. *N Engl J Med*. 2010 Oct 21;363(17):1597-607.
3. Smith CR, Leon MB, Mack MJ, Miller DC, Moses JW, Svensson LG, et al. Transcatheter versus surgical aortic-valve replacement in high-risk patients. *N Engl J Med*. 2011 Jun 9;364(23):2187-98.
4. Fraccaro C, Napodano M, Tarantini G, Gasparetto V, Gerosa G, Bianco R, et al. Expanding the eligibility for transcatheter aortic valve implantation the trans-subclavian retrograde approach using: the III generation CoreValve revalving system. *JACC Cardiovasc Interv*. 2009 Sep;2(9):828-33.
5. Petronio AS, De Carlo M, Bedogni F, Marzocchi A, Klugmann S, Maisano F, et al. Safety and efficacy of the subclavian approach for transcatheter aortic valve implantation with the CoreValve revalving system. *Circ Cardiovasc Interv*. 2010 Aug;3(4):359-66.
6. Latsios G, Gerckens U, Grube E. Transaortic transcatheter aortic valve implantation: a novel approach for the truly “no-access option” patients. *Catheter Cardiovasc Interv*. 2010 Jun 1;75(7):1129-36.
7. Bruschi G, De Marco F, Fratto P, Oreglia J, Colombo P, Paino R, et al. Direct aortic access through right minithoracotomy for implantation of self-expanding aortic bioprosthetic valves. *J Thorac Cardiovasc Surg*. 2010 Sep;140(3):715-7.
8. Lee WA, Brown MP, Nelson PR, Huber TS, Seeger JM. Midterm outcomes of femoral arteries after percutaneous endovascular aortic repair using the Preclose technique. *J Vasc Surg*. 2008 May;47(5):919-23.
9. Leon MB, Piazza N, Nikolsky E, Blackstone EH, Cutlip DE, Kappetein AP, et al. Standardized endpoint definitions for Transcatheter Aortic Valve Implantation clinical trials: a consensus report from the Valve Academic Research Consortium. *J Am Coll Cardiol*. 2011 Jan 18;57(3):253-69.
10. Amabile N, Jacquier A, Shuhab A, Gaudart J, Bartoli JM, Paganelli F, et al. Incidence and predictors of major bleeding with TAVI. Paper presented at: EuroPCR 2010. Proceedings of the European Association of Percutaneous Cardiovascular Interventions; 2011 May 17-20; Paris, France.
11. Walther T, Kempfert J, Dewey T. Transapical Aortic valve implantation — procedural steps. In: Serruys PW, Piazza N, Cribier A, Webb JG, Laborde JC, de Jaegere P, editors. *Transcatheter aortic valve implantation. Tips and tricks to avoid failure*. New York: Informa Healthcare USA, Inc.; 2010. p. 207-217.