Functional and Aesthetic Outcome Enhancement of Head and Neck Reconstruction through Secondary Procedures

Stefan O.P. Hofer, M.D., Ph.D., F.R.C.S.(C.),[1] and Caroline E. Payne, B.Sc., M.Sc., F.R.C.S.(Plast.)[1]

ABSTRACT

The foundation of head and neck reconstruction is based on two pillars: the restoration of function and the restoration of aesthetics. The objective of this article is to provide insight into how to prevent undesirable functional and aesthetic outcome after the initial procedure and also to provide solutions for enhancement of functional and aesthetic outcome with secondary procedures. Functional and aesthetic outcome enhancement is discussed in relation to the individual structures within the oral cavity, for the mandible, and for facial reconstruction. Normal prerequisites for all individual structures are described, and key points for restoration of these functional and aesthetic issues are proposed. In addition, further suggestions to improve suboptimal results after initial reconstructive surgery are presented. Understanding the function and aesthetics of the area to be reconstructed will allow appropriate planning and management of the initial reconstruction. Secondary enhancement should be attainable by minor procedures rather than a requirement to redo the initial reconstruction.

KEYWORDS: Facial reconstruction, mandible, oral cavity, outcome enhancement, secondary procedures

Head and neck reconstruction has gone through a major evolution in the past decades. Surgeons have used different flaps for many centuries but mostly without adequate knowledge of the vascular anatomy of the tissues they were using. Appreciation of the importance of the vascular anatomy of flaps has boosted reconstructive possibilities. One of the earliest surgeons to appreciate the importance of a designated blood supply to a flap was Esser in his book on artery flaps, which gives detailed descriptions of these concepts.[1] In addition, Manchot and later Salmon recognized the principle of a dedicated blood supply to specific areas of skin, which would only decades later be acknowledged as the basis for reliable flap transfer.[2] Head and neck as well as facial reconstruction evolved slowly over time with the development of different locoregional flaps specifically for cheek, eyelid, and nose reconstruction. This also incorporated the idea of "waltzing" flaps from a distance for reconstruction in the head and neck area. The larger intraoral and composite defect reconstructions of the head and neck area improved

[1]Division of Plastic Surgery, Department of Surgery and Department of Surgical Oncology, University Health Network, Toronto, Ontario, Canada.

Address for correspondence and reprint requests: Stefan O.P. Hofer, M.D., Ph.D., F.R.C.S.(C.), Chief, Division of Plastic Surgery, Department of Surgery and Surgical Oncology, University Health Network, 200 Elizabeth Street, 8N-865, Toronto, Ontario, Canada M5G 2C4 (e-mail: stefan.hofer@uhn.on.ca).

Advances in Head and Neck Reconstruction, Part II; Guest Editors, Samir Mardini, M.D., Christopher J. Salgado, M.D., and Hung-Chi Chen, M.D., F.A.C.S.

Semin Plast Surg 2010;24:309–318. Copyright © 2010 by Thieme Medical Publishers, Inc., 333 Seventh Avenue, New York, NY 10001, USA. Tel: +1(212) 584-4662.
DOI: http://dx.doi.org/10.1055/s-0030-1263072.
ISSN 1535-2188.

enormously through understanding and popularization of the pectoralis major musculocutaneous flap and the deltopectoral fasciocutaneous flap. As anatomic knowledge grew, the composition and use of these flaps became more sophisticated. Microsurgery led to a new era, which has enabled reconstruction of almost any defect as new flaps have been discovered and put to use.

The foundation of head and neck reconstruction rests on two pillars: the restoration of function and the restoration of aesthetics. The concept of a successful reconstruction with regard to function and aesthetics has changed over the past decades. Initially, achieving a defect closure was considered a functional success, and filling a hole was considered an aesthetic success. Obviously, the shortcomings of reconstruction were appreciated, and operative techniques were not a matter of choice but rather of fewer available options and slowly evolving techniques at that time. Many of the developments by innovative and brilliant minds in those days are now taken for granted and are being refined. Evidently, there are numerous examples of excellent reconstructions throughout the past decades and there remain many challenges, as a wide range of defects can still not be reconstructed in a totally satisfactory manner.

Functional enhancement of reconstruction in the various areas of the head and neck depends on precise appreciation of what the functional characteristics of the structures involved were and which of these characteristics were lost. For example, aesthetic enhancement of the cutaneous areas of the head and neck necessitates understanding of separate facial units. This has changed the focus from a hole that needs to be filled to the identification of the defect and appreciation of the different units that are involved. Optimal functional and aesthetic reconstruction requires meticulous preoperative planning, which in some cases requires multiple procedures to obtain an adequate end result.

In this article, different aspects of functional and aesthetic reconstruction will be discussed. The objective here is to provide insight into how to prevent undesirable functional and aesthetic outcome after the initial procedure and also to provide solutions for enhancement of functional and aesthetic outcome with secondary procedures. All separate aspects involved in optimal reconstructive outcome have been separated into individual descriptions but obviously need to be combined in daily practice to solve these reconstructive challenges. In functional and aesthetic reconstruction of the head and neck, many personal preferences and different approaches are possible and can give good results if basic principles are followed. Head and neck, including facial, reconstruction should always be individualized in each case. It will be impossible to be complete in a mere article as many adequate methods of management are available.

OUTCOME ENHANCEMENT IN ORAL CAVITY RECONSTRUCTION

The oral cavity contains several structures with very unique individual properties that inevitably will impact on each other's function in cases of ablative surgical therapy. In general, partial resection of multiple functional structures within the oral cavity is required for disease management. This makes reconstruction that can achieve preoperative function and aesthetics extremely challenging. Reconstructive outcomes are often further challenged by postoperative radiation therapy. In the following, functional and aesthetic outcome enhancement is discussed in relation to the individual structures within the oral cavity. Pharyngeal reconstruction will not be covered in this section, as it is such an extensive topic on its own. For comprehensive treatment, it is necessary to combine suggested strategies, and this will assist in enhancing total outcomes. It is imperative to follow-up patients and assess what was accomplished at the initial reconstructive procedure to be able to learn from good or poor results to improve outcomes.

Functional Outcome Enhancement

FLOOR OF MOUTH

The main issues in reconstructing the floor of the mouth are:

- Restoring a buccogingival and/or labiogingival sulcus of adequate depth.
- Avoiding excessive height of the floor of the mouth by a skin island sitting on top of the mandible or too high behind the teeth in a dentate patient.
- Allowing for optimal tongue mobility by restoring exactly what has been taken.

To restore the floor of the mouth, it is very important to be aware of all these interrelated issues. No single issue can be addressed without influencing the other. In the initial reconstruction, an exact assessment of what is missing is required. This will prevent reconstruction with too large a piece of tissue giving excessive bulk to the floor of the mouth or too small a piece of tissue giving excessive tightness. Both conditions will then limit tongue mobility and result in impaired oral intake and speech. In general, the flap needs to be a tight fit at initial placement, as the intraoral space will often diminish when the retracted tissues are put back into the oral cavity or a mandibular split is closed.

Primary reconstruction of the floor of the mouth requires a very thin flap to replace "like with like" with regard to thinness. The radial forearm flap is still the most popular flap for straightforward floor of mouth reconstructions giving good results with limited donor site morbidity. The anterolateral thigh flap has gained

popularity for these reconstructions; however, it can be bulky in patients who do not have thin legs. A different option is to reconstruct the defect with a fascial or muscle flap and let it re-epithelialize by the surrounding mucosal surface. In our experience, this type of approach is more suitable for reconstruction of the hard palate as the lack of underlying support in the floor of the mouth will result in considerable shrinkage due to wound-healing forces. It is also inappropriate in the patient requiring or having received radiotherapy as resurfacing by the mucosal surface may be so delayed that it can prevent timely postoperative radiation treatment or is so retarded after radiation it may never actually cover the reconstruction. In previously irradiated patients, considerable wound-healing complications can also occur with the increased likelihood of infection putting the flap at risk. A more elegant approach to restoring "like with like" is prefabricating a radial forearm fascia flap with mucosa and transplanting at a second stage, which is 3 weeks after fascial mucosa seeding (Fig. 1). In our experience, this technique needs further development by adding an adequate scaffold to prevent flap contraction by cicatricial forces.

Secondary enhancement of functional outcomes after floor of mouth reconstruction usually has one of two goals: either to reduce bulkiness or to add tissue to gain mobility or depth. Reduction of bulkiness is rather simple; however, it requires proper planning to prevent excessive tension and secondary dehiscence leading to intraoral bone exposure. Two important factors need to be considered: the vascular pedicle of a flap, even if the flap should be able to survive without this pedicle, and previous exposure to radiation therapy, which will make a flap more dependent on its pedicle in cases of tension.

When there is a shallow sulcus or limited tongue mobility due to tightness, additional tissue needs to be brought in. Correction of inadequate depth of the sulcus can be achieved by either an Esser inlay technique with a full-thickness skin graft, a gingivoplasty, or a local pedicled flap based on the facial artery. Flaps based on the facial artery can be performed when the proximal facial artery has been cut after neck dissection because of the abundant collateral blood supply in that region. Limited tongue mobility can also be improved by these measures. On occasion, additional freeing of scarred tissue of the tongue itself will achieve release. Great care should be taken to avoid damaging any intact lingual nerves. In selected patients, tongue release will result in diminished function, as part of the remaining tongue function is due to its slightly fixed position. Release of an impaired tongue can then result in a freed, nonfunctional tongue without any support from the surrounding oral structures. Proper antibiotic coverage is necessary for all these intraoral procedures.

TONGUE

There is no flap or reconstructive method that totally reproduces the function of the tongue. Resection of the tongue causes impairment in speech, impairment in swallowing, and impairment of chewing. The main issues in reconstruction of the tongue are achieving optimal mobility while limiting excessive bulk and tightness to enable normal swallowing. But, overall, poorer speech results if the reconstruction is simply placed or ends up in the plane of the floor of mouth, without vertical bulk that can contact the palate. Consequently, all these functional goals are therefore connected.

Primary reconstruction of the tongue requires accurate assessment of what is missing with regard to tissue as well as innervation. Smaller defects are often amenable to primary closure. Tongue tissue should never be used to close a defect in the floor of mouth, as this will significantly impair mobility. Anterior and lateral tongue defects often have limited bulk requirement and are easily reconstructed with, for example, a radial forearm flap. More posterior defects involving the base of the tongue will often require more bulk to enhance swallowing and prevent aspiration and are easily reconstructed with, for example, an anterolateral thigh flap. Patients requiring a total glossectomy need to be carefully evaluated before surgery with regard to their expected survival and quality of life after total glossectomy. These patients will often remain dependent on parenteral nutrition and are at significant risk of recurrent aspiration sequelae. In cases where chemoradiation with organ preservation is not a viable option and total glossectomy is indicated, reconstruction with large flaps is essential to try and achieve maximal bulk to assist in swallowing. These flaps can be designed with an innervated muscle to aid in the new swallowing process. Extensive wound healing and postoperative irradiation will limit maximal functionality of these reconstructions.

Secondary enhancement of functional outcomes after tongue reconstruction usually has one of two goals: either to further improve mobility or to reduce bulkiness. Improvement of mobility can be achieved by releasing the tongue from its scarred bed and addition of a skin graft (which may shrink again), local flaps (e.g., facial artery based flaps), or in rare cases a (new) free flap (which may be bulky). When releasing the tongue, great care should be taken to prevent (partial) denervation or taking away the stability that the impaired remaining tongue had from the surrounding scar tissue (as described earlier). Reduction of bulk is in general straightforward; however, it may not give the great functional improvement that the surgeon and patient were expecting, especially after major surgery and radiotherapy. Sometimes it is not possible to correct with surgery alone, and there is a requirement for prolonged assistance with specialists in rehabilitation, speech therapy,

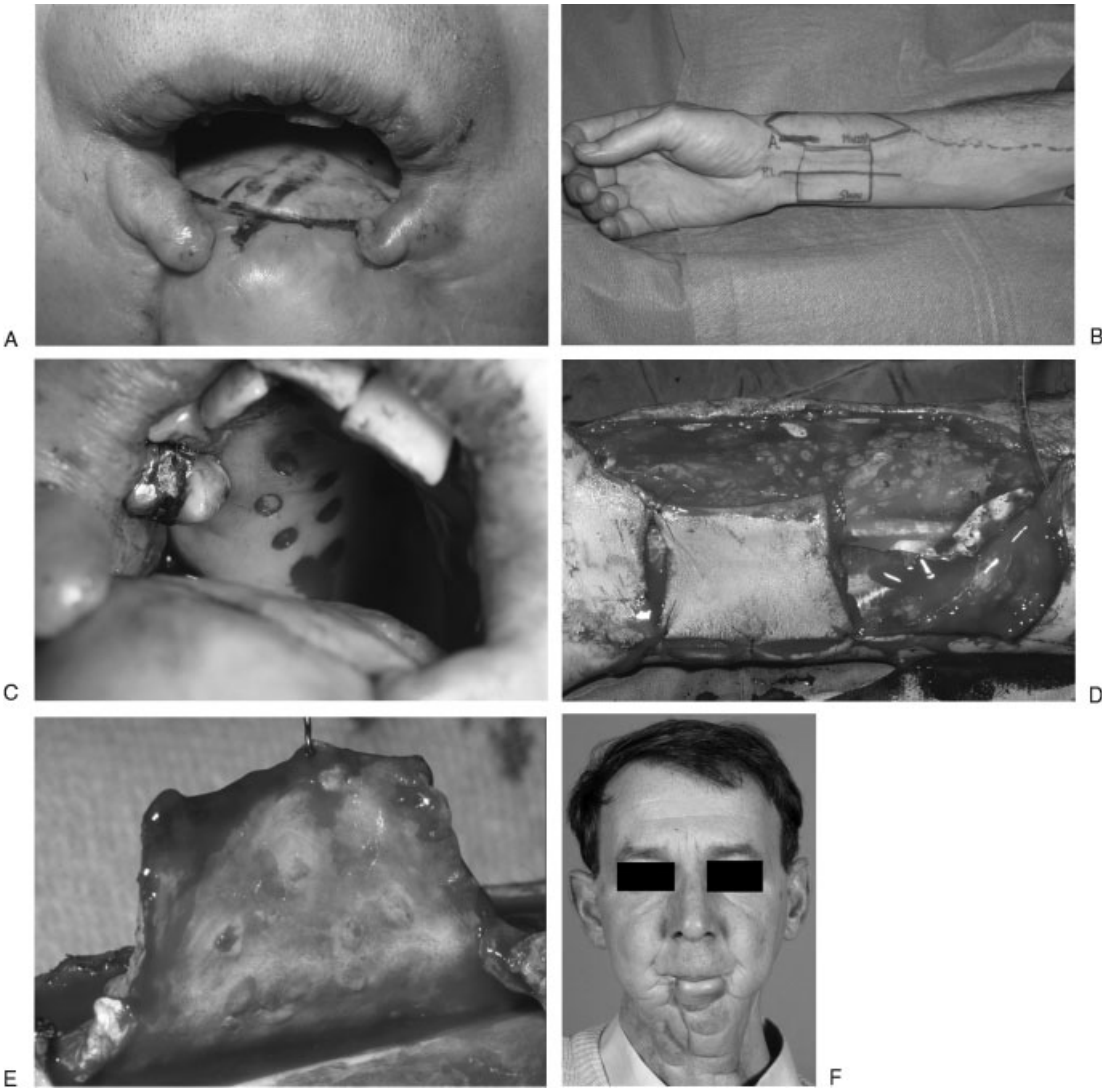

Figure 1 (A) The lower lip was lost in this 46-year-old man, who had previously undergone a composite central floor of mouth, subtotal glossectomy, mandible, and external skin resection for squamous cell carcinoma, followed by 66 Gy radiation therapy after his reconstruction plate was removed. He had been reconstructed with a large osteocutaneous fibula free flap and pectoralis major transposition flap. (B) Lower-lip reconstruction was planned with a prelaminated radial forearm flap. The skin part of the flap was planned for external skin and lip restoration. The mucosa part was planned with a subcutaneous fascial extension to be prelaminated on the undersurface with oral mucosa (P.L., palmaris longus; A, artery). (C) Hard palatal punch biopsies (3 mm diameter) are harvested for prelamination. (D) Intraoperative view of the raised and prelaminated flap. The square skin part was planned for external skin reconstruction. Above this skin, a sheet of silicone was placed below the adipofascial extension to prevent in-growth to the arm. The mucosal punch biopsies were placed on top of the adipofascial extension after which a second layer of silicone sheeting was placed on top of this to prevent in-growth into the skin that will be closed over the top of this construct. (E) View after 3 weeks with neomucosa formation. The round mucosa punch grafts can be seen. This side of the flap will be used for internal lining of the lower lip and creation of a new labiogingival sulcus. (F) Aspect 1 year after lower-lip reconstruction. Lower-lip reconstruction was successful; however, anticipated labiogingival sulcus height was limited due to strong wound-healing forces. Addition of a scaffold is recommended to help provide additional strength to this prelaminated flap.

and swallowing therapy as part of the overall specialist disciplinary approach.

PALATE

The main issues in reconstruction of the palate are related to whether the soft palate or hard palate has been removed in part or totally. In cases of the hard palate being (partially) removed, functional complaints develop from the open connection between the oral and nasal cavities, resulting in open nasal speech and leakage of oral intake through the nose. In cases whereby the soft palate has been (partially) removed, functional complaints can be similar to an isolated hard palate defect; however, open nasal speech is harder to treat as the

muscles in the soft palate have been resected. In ablative surgery, these muscles are now absent, and it is unlike the treatment of a cleft palate. In a cleft, these muscles are present although they are incorrectly oriented and not connected in the midline.

In primary reconstruction of hard palate defects, several options are available depending on the extent of the defect. A range of defects from a small isolated hole to an extensive deficiency after maxillectomy can be reconstructed by fitting a prosthetic device to act as an obturator. Smaller defects can be reconstructed with local flaps (Langenbeck, tongue), although for cancer ablative surgery in combination with radiation therapy distant flaps or free flaps are usually required. Use of distant flaps such as the temporoparietal fascia flap, with or without bone, is generally limited as the vascularity is not always predictable. Reconstruction with soft tissue free flaps, such as the radial forearm, anterolateral thigh, or rectus abdominis, will usually give the most reliable result. For more extensive defects, free iliac crest flap reconstruction has been used successfully. In primary reconstruction of soft palate, there are two main considerations. First, there is a need to keep the oral and nasal cavities separated; second, there is a need for sufficient bulk in the back of the oral cavity for the tongue to push against for swallowing. Smaller defects can be reconstructed satisfactorily with a radial forearm free flap, which preferentially should be folded to reconstruct the nasal as well as the oral surface. If the nasal surface is left raw, the flap will shrink significantly due to wound-healing forces and even more so in combination with radiation therapy. For larger defects, the anterolateral thigh flap will often supply the bulk required for decent postoperative swallowing. In our experience, all flaps positioned in the soft palate area will shrink in the postoperative months, due to the lack of surrounding support as normally present in the hard palate, and therefore should always be planned to reach close to or touch the posterior pharyngeal wall.

Secondary enhancement of functional outcome of reconstruction of the palate usually has one of two goals: either to reduce the amount of leakage of oral intake out through the nose or to reduce open nasal speech and improve intelligibility. In general, after hard palate reconstruction, these problems only occur in cases of a nonfitting obturator or flap dehiscence. Secondary enhancement can therefore be achieved by improving the obturator, changing from an obturator to a flap-based solution, or by repair of the area of flap dehiscence with local tissue advancement. This can be a local flap such as a tongue flap or in extreme cases a new free flap. After soft palate reconstruction, most patients will not have any issues with leakage of oral intake through the nose but will have slight to moderate open nasal speech. In selected cases, this condition can be improved with a cranially or caudally based pharyngoplasty. In those cases where severe open nasal speech is an expected complication at the time of primary reconstruction, it is advisable to perform a primary pharyngoplasty. In the secondary phase, this procedure can be hard due to difficult access, mild or moderate trismus, and in most patients the presence of irradiated local tissues.

Aesthetic Outcome Enhancement

It would seem that reconstruction of the floor of mouth, palate, and/or tongue has mainly functional rather than aesthetic implications, as none of these structures are readily visible at first glance. The imminent aesthetic concern appears secondary; however, inadequate reconstruction of the functionality will result in immediate stigmatization as these patients attempt communication and an oral diet. Not only will excessive bulk of the floor of mouth or tongue look unnatural as soon as the mouth is opened to speak or eat but will also cause drooling and difficultly with intelligible speech. The same holds true for an excessively tight reconstruction of the floor of the mouth or insufficient bulk for the tongue where social interaction of patients with their peers is severely affected. Palatal insufficiencies will have the same "social aesthetic" repercussions with eating and speech problems.

All solutions to improve function will in the end affect the total aesthetic and social acceptance and functioning of the patient. These considerations are extremely important, as patients will draw themselves into total social isolation if these aesthetic issues are unacceptable to them.

OUTCOME ENHANCEMENT IN MANDIBULAR RECONSTRUCTION

Functional Outcome Enhancement

The main issues in reconstruction of the mandible are to:

- Maintain the framework of support for the anterior oral cavity and neck structures.
- Enable mastication.
- Provide a basis for dental rehabilitation.

In restoring mandibular function, there are several general considerations. The main goal should be to restore the continuity of the mandible with well-vascularized bone. Nonvascularized bone will not tolerate radiation therapy reliably. Use of a bridging plate alone will mostly result in poorer outcomes due to the high incidence of plate exposure and should be reserved only for special circumstances. In selected edentulous patients, a lateral segment defect can be filled with soft tissue bulk as a simple solution.

Primary reconstruction of the mandible requires careful analysis of the defect. The exact mandibular

contour should be restored, as a change in the arc size will result in malocclusion in the dentulous patient and deterioration of function. Mandibular height restoration is often emphasized. Adequate bone height is important to allow implant-based dental rehabilitation. In general, bone height achieved with a free fibular flap after segmental mandibular resection is adequate. Greater height can be obtained by using the fibular as a double-barrel technique or with a vascularized iliac crest or scapular transfer. These osseous flaps are usually harvested with a skin paddle, the excessive thickness of which can be a problem. In selected cases, this can be circumvented by using muscle only with the bone and allowing repair of mucosal integrity by secondary healing. When resection of the temporomandibular joint (TMJ) is required, no fully satisfactory reconstructive solution is available. Isolated TMJ resection can be reconstructed with soft tissue interposition. When the TMJ is removed in conjunction with an extensive mandibular segment, the bone reconstruction can be fixed to the surrounding soft tissues. The considerable wound-healing reaction in this area will lead to stability, and early postoperative mandibular motion will help prevent trismus.

Secondary enhancement of functional outcomes after mandibular reconstruction deals mostly with some of the more common problems. These are related to excessive soft tissue bulk that was transferred with the bone flaps and ultimately prevent adequate dental rehabilitation. These corrective procedures encompass simple soft tissue debulking, inlays to deepen the buccogingival sulcus, or alternate gingivoplasty techniques.

Secondary bone corrections are uncommon as many of these patients receive postoperative irradiation making bony reoperations in this area unattractive. The major part of secondary bone corrections in patients after head and neck cancer is in those who have developed osteoradionecrosis of the mandible after radiation. Depending on the degree of osteoradionecrotic disease, this treatment can range from conservative measures via simple debridement up to mandibular reconstruction with free vascularized bone transfer with additional hyperbaric oxygen support.

Aesthetic Outcome Enhancement

Aesthetic outcome is very closely related to adequate mandibular reconstruction. When no bone reconstruction is performed or bone reconstruction fails in a central defect, it will result in total collapse of the remaining mandible with severe facial disfigurement. Correspondingly, when undertaking reconstruction, an exact reproduction of the mandibular contour is important to prevent an incorrect projection of the mandible and also an unacceptable aesthetic outcome.

Dental rehabilitation is only possible if the mandible is reconstructed adequately. It has been pointed out that dental rehabilitation will only be finished in a limited number of patients with mandibular reconstruction. In the patients who have achieved full dental rehabilitation, the most significant self-reported benefit is the aesthetic improvement of their appearance when compared with patients who have not had dental rehabilitation.[3] Dental rehabilitation not only allows wearing of dentures but also provides support for the lower lip, which gives a significant aesthetic benefit.

OUTCOME ENHANCEMENT IN FACIAL RECONSTRUCTION

Facial reconstruction has evolved over many centuries to the current concepts of aesthetic facial reconstruction. Options for facial reconstruction are countless, with techniques that have been described for all areas of the face. In the past, the general theme in facial reconstruction was to use a flap to close a hole. In contrast, the modern concept of aesthetic facial reconstruction makes use of the aesthetic facial units, which are governed by the transitions of light and shadow on the face as the facial surface changes from concave to convex surfaces. Scars are preferentially placed at the union of these aesthetic facial units as these are ideal locations to make scars the least conspicuous. Larger aesthetic facial units, such as nose or lips, can be subdivided into subunits to further refine facial reconstruction.[4]

Aesthetic facial reconstruction can only be achieved by meticulous defect analysis. With this analysis, the different aesthetic units involved as well as the quality of the tissues, the possible structural support needed by those tissues, and the ultimate functions can be evaluated. This essential analysis should indicate the use of the reconstructive elevator rather than the reconstructive ladder, where the flap or combination of flaps will be chosen that give the best functional and most aesthetically pleasing outcome.[5]

Reconstructive surgery has also evolved toward minimizing donor site morbidity. Functional donor site morbidity is reduced when perforator flaps are used. In facial reconstruction, the facial artery perforator (FAP) flap is the first flap identifying a single perforator and preserving facial musculature and innervation to reduce functional donor site morbidity.[6] When donor tissue is local to the defect, as in the FAP flap, the aesthetic side of minimizing donor site morbidity is accomplished by designing scars in the borders of these aesthetic units. When looking at a person's face, the gaze is fixed on the eyes, cheekbones, nose, and mouth. For surgical incision planning, this means that scars on the forehead and those lateral of a vertical line through the lateral canthus are less conspicuous and have less aesthetic donor site morbidity, even if they run through an aesthetic unit.

Aesthetic facial reconstruction is a highly challenging and very artistic discipline. For reliable good

outcomes, it is important to have detailed preoperative plans with back-up options. Proper planning is key to any good outcome. Often, consecutive stages need to be performed as part of the initial plan or as part of refinements after the first-stage operation. Perfect results will often need more than one operation.

In the following, some considerations for specific facial regions will be addressed with regard to initial planning and secondary procedures.

Functional and Aesthetic Outcome Enhancement

FOREHEAD AND SCALP

The aim of reconstruction to the forehead and scalp area is to cover exposed underlying skull bone and/or contents. Once a defect has been covered successfully, the main focus of the reconstruction has more of an aesthetic nature. Successful coverage will not always result in pleasant aesthetics for patients. The main concerns in general are coverage that is too bulky or too thin, incorrect skin color, no hair, and suboptimal scarring. All these issues can be dealt with by several solutions.

Excessive bulk after coverage of the forehead/scalp is usually a result of suboptimal flap selection. Myocutaneous flaps as well as thick (fascio)cutaneous flaps can result in bulky cover. Forehead/scalp skin and subcutaneous tissues are generally thinner than most standard skin flap areas. Excising the skin paddle of a myocutaneous flap and skin grafting the underlying muscle or alternatively resection or liposuction of subcutaneous fat can thin excessive bulk of skin and subcutis.

In cases where a muscle flap with skin graft is used for coverage, the muscle will thin over time, as it is no longer innervated. On the scalp this will usually not be of major concern, although these flaps are less sturdy to friction and can present with minor areas of skin graft breakdown in the longer term. On the forehead, the thinning of a muscle flap can result in a skeletonized appearance, which accentuates the contour of the skull. Correction of this aesthetic problem can be solved by reconstruction with a thin skin flap, which, if unavailable, can be generated by flap prefabrication (Fig. 2).

Commonly, the resulting color of the skin paddle used in the reconstruction is mostly a hit-or-miss affair. Skin grafts will often change to a different color, which in our experience is usually not the color of the surrounding skin. Good results have been reported for skin grafting of the facial area with scalp skin grafts. This is possible for forehead and facial skin reconstruction but not for larger scalp reconstructions. The adage that skin flaps taken closer to the face have a better color match has not always been our experience. Any skin areas that are primarily protected from the sun by clothes (e.g., (para)scapular flap skin) are generally unpredictable in the way they will color once transplanted to the facial area. For scalp reconstructions, it is often less important to have an exact color match as many of these patients will end up wearing hair pieces or wigs to cover the baldness.

Restoration of hair after scalp or forehead reconstruction can be addressed by hair transplantation for the smaller defects or eyebrows. Large hair-bearing scalp defects are usually handled by having a bald head in men or a wig. The smaller the scalp defect, the more likely the area will be covered with a hairpiece or remaining hair as the easiest options. Tissue expansion of remaining hair-bearing scalp to replace bald areas can be performed. A simpler solution for eyebrow restoration can be tattooing.

NOSE

The nose naturally attracts the eye, as it is the center of the facial appearance. Nasal function has to act as a guide for the reconstruction. The reconstruction has to permit unobstructed airflow for normal breathing, speech, and smell.

Nasal reconstruction, more specifically, requires the recognition of anatomic structural layers. The nose is divided into three main layers: the mucosal lining (inner lining), the osteocartilaginous framework (structural support), and the external soft tissue and skin (outer lining). It is the basic principle of restoration of each layer that is the foundation of each reconstruction.

Inner lining reconstruction is the first step in reconstructing the nose. A multitude of options for inner lining reconstruction are available. It is important that inner lining is thin so as not to obstruct the nasal passage. Also, nasal lining needs to be well vascularized to allow insertion of structural support in the process of nasal reconstruction. Inner lining materials range from skin grafts, turnover flaps, mucosal flaps, folded parts of regional flaps, to free flaps. When secondary enhancement is needed, if initial inner lining reconstruction did not prove satisfactory, improvement of outcome mostly concerns local tissue rearrangement or addition of skin grafts to add to the shortage of inner lining. In rare cases, the entire reconstruction has to be redone.

Structural support is required for nasal reconstruction to maintain projection and to restore the external and internal nasal valve and allow nasal air passage. Autologous materials such as auricular, septal, or costal cartilage and bone are preferred materials. These support materials are not only used to replace the missing support but are also added to previously unsupported areas such as the alar rim. It is important to supply extra support to most areas to withstand the forces of wound contraction. In secondary enhancement of structural support, addition of extra cartilage to insufficiently supported or unsatisfactorily projecting areas is generally undertaken.

Figure 2 (A, B) End result in a 37-year-old man after more than 80 surgical procedures for frontal sinusitis, which was finally treated by wide resection of forehead and scalp skin in combination with removal of the outer table of the skull followed by a rectus abdominis free flap with split-thickness skin graft. The patient did not like the skeletonized appearance of his forehead and had frequent skin graft breakdown. (C) The reconstructive plan consisted of prefabricating a thin skin flap to have perfect contour, as well as choosing skin close to the forehead for optimal color match. (*1*) For this purpose, neck skin was prefabricated with an adipofascial radial forearm flap. (*2*) The adipofascial radial forearm flap was placed on top of a silicone sheet in the left neck. The neck skin was placed on top of the adipofascial radial forearm flap. (*3*)This construct now allowed neovascularization into the overlying neck skin, which then developed into a new free flap. (D) After 10 weeks, the prefabricated neck skin free flap was harvested. A tube of silicone sheeting wrapped around the vascular pedicle facilitates pedicle dissection. (E, F) Transfer of the flap in combination with simultaneous tissue expansion of the scalp to advance the hairline resulted in this 3-year outcome.

The nose is given its external three-dimensional appearance by its convex and concave surfaces. The surface contours are the basis of the nine-aesthetic-subunit principle of Burget and Menick[7] and need to be considered when re-creating or adapting the defect. When providing the external skin cover, scars are placed in the boundaries of these units to make them less conspicuous. It is stated that if 50% or more of the subunit is deficient, the entire subunit should be excised and replaced. Distortion will be greatest above this percentage, so it is better to replace the unit than try to repair half or more of it. This should avoid conspicuous scars and replace correct contours so the visual line is not drawn to the reconstruction.

The forehead flap is the workhorse flap for nasal reconstruction. It is best regarded as a three-stage operation whether used to resurface a single-layer nasal defect or used in a complex three-layer nasal reconstruction. The sequence of procedures allows initial fine-tuning of the flap and extensive thinning at week 3. At this time, the flap is fully detached from the nose but left attached by its pedicle. Extensive thinning is tolerated by the fact that the vascularity of this "delayed" flap has improved over the first 3 weeks. The flap is still very pliable and moldable at this stage because wound healing is still in its early stages, and there has also been no surgical trauma to the posterior surface of the dermis as the flap was initially raised in the plane underneath the frontalis muscle.

At this second stage, loosely placed quilting sutures in the thinned area will prevent seroma and hematoma formation. Another 3 weeks after this second intermediate stage allows vascularization of the flap from the surrounding tissue so the division of the pedicle can occur 6 weeks from the original surgery. In secondary enhancement of outcomes, further touch-up operations will be postponed for at least 6 months to let wound healing occur, swelling disappear, and the nose soften. The procedures undertaken at that time are usually geared toward repositioning scars into the correct aesthetic units, thinning areas of excessive bulk, or adding tissue to areas of tightness or contraction.

LIPS

The lips are important from a functional as well as an aesthetic viewpoint. They play a vital role in facilitating speech and food intake, as well as being a focus point in the central face during social contact. Again, all the concepts of facial reconstruction play an equally important role in reconstructive surgery of the lips. Careful defect analysis is required to assess restorative options for function and loss of aesthetics. Any abnormality due to asymmetry in shape or movement will be picked up. This can be from extreme cases of complete facial nerve palsy or total lip resection to as small as a step deformity in the white roll.

As in any reconstruction, it holds true for lip defects, too, that it is important to try and replace "like" with "like" tissue. Small full-thickness lip defects up to one third of the lip can usually be closed primarily without significant problems. Slightly larger defects may require lip shave or buccal mucosal advancement flaps for vermillion reconstruction and lip switch flaps such as the Abbe and Estlander flaps for moderate-sized (less than one half) full-thickness lip reconstruction. If the defect lies centrally or more laterally with involvement of the commissure and no new lip tissue is required, the Karapandzic flap provides the ideal reconstruction because it preserves the neurovascular supply and the integrity of the oral sphincter. The need for new lip tissue and the necessity to avoid microstomia are the best indications for the modified Bernard-Burrow or fan flap procedure. For large lower-lip defects measuring more than two thirds of the lip without sufficient cheek tissue available to execute these perioral flaps, distant or free flaps such as a free radial forearm flap with palmaris longus sling or an innervated gracilis free flap are required. Patients should be educated that postoperative oral function can be compromised due to tightness and/or impaired lip sensation.

For secondary enhancement of functional and aesthetic outcomes after lip reconstruction, several problems can arise. With the Abbe flap, it is very important to design the flap in the middle of the lower lip. In this fashion, the scar will be right in the center, which will prevent asymmetric distortion of the lower lip. Secondary scar revisions to get the scar in the center will only give limited success. Abbe flaps in men need special consideration with regard to hair growth. By turning the lower-lip skin upside down, the direction of hair growth is incorrect. In addition, the hair growth on the lower-lip skin is often less than that on the upper-lip skin. In some cases, additional hair follicle transplants at a later date can be considered.

Incorrect realignment of the white roll at initial surgery will give step deformities that are very visible once everything is healed. Careful realignment after full wound healing will improve the white roll appearance. The lip vermillion can be touched up during the second operation if asymmetry due to bulkiness across a scar exists. Careful restoration of the continuity of the orbicularis oris muscle has to be performed to prevent a whistling deformity. The continuity of the orbicularis oris muscle can be restored secondarily if required. In the case of persistent commissural deformity, two opposing mucosal rhomboid flaps, which are transposed laterally to reconstruct the angle, may be best used. A tight lower lip with poor function and an overhanging upper lip results in less oral competence than is desirable. Unfortunately, there is no procedure that can adequately improve this situation. However, using an anterior-based tongue flap, which is divided after 10 to 14 days,

instead of buccal mucosa advancement may overcome the mucosal deficiency.

Microstomia can be particularly troublesome for patients who use dentures. They have to be instructed how to remove and insert these appliances so that the least amount of strain is put on the lip. A splinting device may be used for several months to treat microstomia.

CONCLUSION

Functional and aesthetic outcome enhancement of head and neck reconstructions through secondary procedures can be a very worthwhile undertaking. It is particularly important to understand the function and aesthetics of the area to be reconstructed to manage the reconstruction appropriately at the initial phase and obtain an outcome that is amenable to secondary enhancement by minor procedures rather than a requirement to redo the initial reconstruction. Careful study of the follow-up outcomes of reconstructed patients will help improve strategies for primary reconstruction and give an understanding of expected shortcomings and their management possibilities for enhancement through secondary procedures.

REFERENCES

1. Esser JSF. Artery Flaps. Rotterdam, The Netherlands: Erasmus Publishing; 2003
2. Taylor GI, Rasaboni RM. Michel Salmon Anatomical Studies. St. Louis, MO: Quality Medical Publishing Inc.; 1994
3. Hundepool AC, Dumans AG, Hofer SO, et al. Rehabilitation after mandibular reconstruction with fibula free-flap: clinical outcome and quality of life assessment. Int J Oral Maxillofac Surg 2008;37:1009–1013
4. Menick FJ. Facial reconstruction with local and distant tissue: the interface of aesthetic and reconstructive surgery. Plast Reconstr Surg 1998;102:1424–1433
5. Gottlieb LJ, Krieger LM. From the reconstructive ladder to the reconstructive elevator. (Editorial)Plast Reconstr Surg 1994;93:1503–1504
6. Hofer SO, Posch NA, Smit X. The facial artery perforator flap for reconstruction of perioral defects. Plast Reconstr Surg 2005;115:996–1003; discussion 1004–1005
7. Burget GC, Menick FJ. The subunit principle in nasal reconstruction. Plast Reconstr Surg 1985;76:239–247