CIHR Canadian Institutes of Health Research
IRSC Instituts de recherche en santé du Canada

Submitted by CIHR
Déposé par les IRSC

Biol Psychiatry. Author manuscript; available in PMC 2012 February 09.

Published in final edited form as:
Biol Psychiatry. 1999 November 15; 46(10): 1436–1442.

Qualitative MRI Findings in Adults with 22q11 Deletion Syndrome and Schizophrenia

Eva W.C. Chow, **David J. Mikulis**, **Robert B. Zipursky**, **Laura E. Scutt**, **Rosanna Weksberg**, and **Anne S. Bassett**

Centre for Addiction and Mental Health (EWCC, RBZ, LES, ASB), the Department of Psychiatry, University of Toronto (EWCC, RBZ, ASB), the Toronto Hospital, Western Division (DJM), the Department of Medical Imaging, University of Toronto (DJM), the Hospital for Sick Children (RW), and the Department of Genetics, University of Toronto (RW), Toronto, Canada

Abstract

Background—A genetic syndrome associated with schizophrenia, 22q11 deletion syndrome (22qDS), may represent a genetic subtype of schizophrenia (22qDS-Sz). Structural brain changes are common in schizophrenia and may involve developmental anomalies, but there are no data yet for 22qDS-Sz. The objective of this study was to assess brain structure in adults with 22qDS-Sz using magnetic resonance imaging (MRI).

Methods—Brain and arterial MRI scans of 11 adults with 22qDS-Sz (mean age = 28.4 years, SD = 6.5) were systematically assessed by a neuroradiologist for qualitative anomalies.

Results—A high frequency of abnormalities were found: T2 white matter bright foci (BF), 90%; developmental midline anomalies, 45%; cerebral atrophy or ventricular enlargement, 54%; mild cerebellar atrophy, 36%; skull base abnormalities, 55%; and minor vascular abnormalities, 36%.

Conclusions—BF and skull base abnormalities, especially in association with neurodevelopmental midline abnormalities, may be distinguishing MRI features for a genetic subtype of schizophrenia involving a deletion on chromosome 22.

Keywords

Schizophrenia; 22q11 deletion syndrome; velocardiofacial syndrome; MRI; MRA

Introduction

The term, 22q11 deletion syndrome (22qDS), refers to the congenital syndromes associated with interstitial deletions at chromosome 22q11.2, and includes velocardiofacial syndrome (VCFS), DiGeorge syndrome and conotruncal anomaly face syndrome (Bassett et al 1998; Thomas and Graham Jr. 1997). The 22qDS has a variable phenotype which involves multiple systems, including the central nervous system. Common features include congenital heart defects, palatal abnormalities, typical facial features, and central nervous system

Address reprint requests to Dr. Eva Chow, Schizophrenia Research Program, 1001 Queen Street West, Queen Street Division, CAMH, Toronto, Ontario, Canada M6J 1H4.

CIHR Author Manuscript
CIHR Author Manuscript
CIHR Author Manuscript

CIHR Author Manuscript CIHR Author Manuscript CIHR Author Manuscript

manifestations such as learning disabilities and mental retardation. Structural abnormalities of the brain and skull have also been associated with the syndrome (Altman et al 1995; Arvystas and Shprintzen 1984; Beemer et al 1986; Bingham et al 1997; Finkelstein et al 1993). In adulthood, approximately 25% of patients with 22qDS may suffer from a psychotic disorder, including schizophrenia (Murphy and Owen 1997; Pulver et al 1994; Shprintzen et al 1992). The 22qDS has been found in patients with schizophrenia (Bassett et al 1998; Chow et al 1994; Gothelf et al 1997; Karayiorgou et al 1995), and may involve as many as one in 50 patients (Karayiorgou et al 1995; Yan et al 1998). These early studies suggest that 22qDS-schizophrenia (22qDS-Sz) may be a genetic subtype of schizophrenia (Bassett et al 1998).

The most consistent structural neuroimaging finding in schizophrenia is enlargement of the lateral and third ventricles (Johnstone et al 1976; Pfefferbaum and Zipursky 1991; Shelton and Weinberger 1986), which is usually mild and overlaps with a continuum of normal anatomic variability (Daniel et al 1991). Quantitative studies using magnetic resonance imaging (MRI) show overall reductions in volumes of cortical and subcortical gray matter, but not white matter (Zipursky et al 1992, 1994). Volumetric changes in the subcortical structures (especially the basal ganglia and limbic system), cerebellar atrophy, and reduction in corpus callosum have also been described, but the findings are often inconsistent (Pearlson and Marsh 1993; Scott et al 1993; Shelton and Weinberger 1986). Reports that neurodevelopmental midline abnormalities, such as enlarged cavum septum pellucidum (CSP) or its more severe form, complete nonfusion of the septum pellucidum or cavum vergae (CV), occur more frequently in schizophrenia than in affective psychosis or normal control subjects (Degreef et al 1991, 1992; DeLisi et al 1993; Jurjus et al 1993; Kwon et al 1998; Lewis and Mezey 1985; Nopoulos et al 1997; Shioiri et al 1996; Weinberger 1987) have lent support to a neurodevelopmental model for the illness (Nasrallah et al 1990; Weinberger 1987).

There are few systematic neuroimaging studies of 22qDS, and prevalence of specific anomalies is generally unknown. There are reported minor midline defects, however, including CSP (Vataja and Elomaa 1998) or CV (Haapanen and Somer 1993), cysts of the septum pellucidum (Haapanen and Somer 1993) or cysts adjacent to the anterior horns (Mitnick et al 1994), hypoplastic corpus callosum (Conley et al 1979; McDonald-McGinn et al 1995; Ryan et al 1997), empty sella (Haapanen and Somer 1993), and small pituitary gland (Bingham et al 1997). Case studies and case series have described cerebral atrophy, enlargement of sulci and ventricles (Beemer et al 1986; Bingham et al 1997; Haapanen and Somer 1993; Ryan et al 1997), cerebellar atrophy, and small posterior fossa (Lynch et al 1995; Mitnick et al 1994; Ryan et al 1997). Severe developmental anomalies such as hydrocephalus (Bingham et al 1997; Nickel et al 1994; Ryan et al 1997), holoprosencephaly (Wraith et al 1985), and anencephaly (Strong 1968) have been reported. Focal white matter bright foci were noted in up to 30% of 22qDS patients on MRI T2 weighted images (Altman et al 1995; Bingham et al 1997; Lynch et al 1995; Mitnick et al 1994). Except for a recent case report (Vataja and Elomaa 1998), all these studies involved nonpsychotic, and mainly pediatric, patients. It is unclear how applicable these findings may be to adults with 22qDS and schizophrenia.

CIHR Author Manuscript CIHR Author Manuscript CIHR Author Manuscript

The current study investigated for MRI brain abnormalities in a case series of 11 adults with 22qDS and schizophrenia to begin to delineate the structural neuropathology of this genetic subtype of schizophrenia. Because of reported skull and vertebral abnormalities (Arvystas and Shprintzen 1984; Beemer et al 1986; Finkelstein et al 1993; Ming et al 1997; Ryan et al 1997), the skull base structures were assessed. In addition, cerebral and cervical arteries were also assessed using magnetic resonance angiography (MRA) because of a reported high prevalence of carotid and vertebral arterial anomalies in 22qDS (Goldberg et al 1993; MacKenzie-Stepner et al 1986; Mitnick et al 1996).

Methods and Materials

Eleven subjects (six men, five women) were referred by clinicians based on a set of 22qDS ascertainment criteria (Bassett et al 1998). All subjects provided informed consent and had MRI scanning of the brain and MRA of major cerebral and cervical blood vessels. They all had a chromosome 22q11 deletion confirmed by fluorescence-in-situ-hybridization testing using the N25 (Vysis Inc., Downers Grove, IL) probe. Subjects ranged in age from 21 to 38 years old (mean = 28.4 years, SD = 6.5). Axis I diagnoses were determined for the subjects by one of the authors (EC or AB) using SCID-IV (First et al 1997) based on a direct interview with each subject and a review of all available psychiatric records. Ten subjects met *DSM-IV* (American Psychiatric Association 1994) criteria for schizophrenia and one (subject 9) had schizoaffective disorder. The mean age of onset of psychotic illness was 19.9 years (SD = 4.32). Estimated IQ using Silverstein's two-subset method (Weschler Adult Intelligence Scale-Revised vocabulary and block design subtests) (Silverstein 1982) ranged from borderline to moderate mental retardation (mean = 69.8, SD = 9.1). Four subjects had ventricular septal defects (VSD) but only two (subjects 2 and 5) had corrective surgery. All subjects had a high arched palate, except subject 3 who had a repaired cleft palate, and subject 5 who had no palatal abnormality. The detailed phenotype of nine of the subjects has been described elsewhere (Bassett et al 1998); the remaining two subjects (subjects 5 and 8) had similar physical and psychiatric findings. No subject had a history of maternal alcohol abuse during pregnancy.

The subjects were scanned using a GE Signa 1.5 Tesla MRI scanner (General Electric Company, Milwaukee) according to a research protocol. Sagittal T1 spin echo, axial proton density, and T2 weight axial images were acquired, which yielded approximately 60 sections of 3 mm thickness for each subject. All axial images were oriented in an oblique plane that passed through the anterior and posterior commissures and was perpendicular to the sagittal plane. MRA using a three-dimensional time-of-flight technique was also performed to visualize the circle of Willis and the carotid and vertebral arteries in the neck. MRA for two subjects (1 and 5) was completed only on the circle of Willis. The MR images were systematically reviewed for clinically detectable qualitative anomalies in the brain, arteries, and skull, over a 4-month period, by a research neuroradiologist (DM) blind to the physical and behavioral status of the subjects. No intra- or inter-rater reliability was measured because each MRI scan was read by a single rater once. Cortical or cerebellar atrophy and ventricular enlargement, when present, were qualitatively rated as mild, moderate, or severe according to the neuroradiologist's own judgment. Nonfusion of the septum was rated as CSP (if incomplete) or CV (if complete). The location and number of bright foci, when

CIHR Author Manuscript

CIHR Author Manuscript

CIHR Author Manuscript

present, were noted for each subject. The skull base structures, including the C1 arch, the cisterna magna, the clivus, and the odontoid, were examined for anomalies as part of the protocol. On MRA, particular attention was paid to the size and location of neck and cranial arteries and their branches.

Results

The MRI and MRA findings are presented in Table 1 and illustrated in Figures 1 and 2. The most common findings (in 9 of 10 analysable scans) were T2 weighted white matter bright foci (BF). BF were found bilaterally, mainly in the frontal lobes in subcortical, cortical, and periventricular regions, in a distribution pattern that was not consistent with demylineating disease (see Figure 1, part 1 to part 3). The nine affected subjects had 2 to 63 BF, most of which were small (3 to 4 mm in diameter). Five (45%) subjects had developmental defects in midline brain structures, either CSP or CV. Four subjects had CV (see Figure 1, part 1 and part 2) and one had an enlarged CSP; there was no significant difference in median IQ between subjects with or without these midline defects (70 vs. 75; $Z = -1.01$; $p = .31$). Six subjects (54%) had detectable cerebral atrophy and/or enlargement of lateral ventricles (see Figure 1, part 1). Four (36%) subjects had cerebellar hypoplasia, one of which only involved the inferior vermis area. Three (27%) subjects had fourth ventricle enlargement. One subject had several additional structural brain anomalies, which included bilateral subcortical T2 hypointensities in the U fibers, a rare observation of signal dropout at the gray–white matter junction on MRI (see Figure 1, part 4) and signal changes consistent with mineral deposition in the basal ganglia and the thalamus (see Figure 1, part 5), likely related to known hypocalcemia in the subject. Only one subject (subject 8) had no structural brain findings on this systematic qualitative assessment.

Several anomalies of the skull base and upper vertebrae were noted. Six (55%) subjects had an enlarged C1 arch, three (27%) had a short clivus, three had a prominent cisterna magna, and two (18%) had a small odontoid. One subject had a hypoplastic skull base (see Figure 1, part 6).

On MRA, a few minor arterial anomalies were detected, none of which involved the carotid artery. Two subjects had hypoplastic A1 segments in the circle of Willis. Two other subjects had a hypoplastic or a smaller right posterior cerebral artery when compared to the left side (see Figure 2). One patient also had an atrophic right vertebral artery along its entire length.

Discussion

This initial descriptive study of brain structures in a 22qDS subtype of schizophrenia found a high prevalence of several anomalies. Consistent with previous studies of schizophrenia, which have found an increased prevalence of abnormal CSP or CV in schizophrenia compared to normal control subjects [25.4% vs. 18.9% (Jurjus et al 1993); 35% vs. 13%; 30 vs. 10% (Kwon et al 1998); 12.5% vs. 1% (Nopoulos et al 1998), depending on the criteria used to define an abnormal CSP], the current study also showed a particularly high rate of these midline developmental defects in 22qDS-Sz. The high prevalence of CSP or CV in the current study is not explained by fetal alcohol syndrome, which has been associated with

CIHR Author Manuscript CIHR Author Manuscript CIHR Author Manuscript

septum pellucidum abnormalities (Johnson et al 1996). CSP and CV have been suggested as evidence of disturbed midline development of the brain, and particularly of the limbic system, a brain area believed to be important in the development of schizophrenia (Bodensteiner and Schaefer 1990; Sarwar 1989; Schaefer et al 1994). CSP and CV may also be related to midline facial anomalies (Kjaer 1995), but the high prevalence of palatal anomalies in the current study precluded the detection of any specific relationship between palatal and septum pellucidum abnormalities.

The high prevalence of cortical atrophy, ventricular enlargement, and cerebellar atrophy in 22qDS-Sz is also consistent with findings in schizophrenia (Johnstone et al 1976; Pfefferbaum and Zipursky 1991; Shelton and Weinberger 1986). Similar findings have been reported, primarily in children, for 22qDS without schizophrenia (Bingham et al 1997; McDonald-McGinn et al 1995; Mitnick et al 1994). In schizophrenia, cortical atrophy or ventricular enlargement may be associated with a poorer outcome and increased cognitive and negative symptoms (Lieberman 1995). The relationship between psychiatric symptoms and neuropsychological functioning and the presence of cortical atrophy and ventricular enlargement will need to be investigated in future studies of 22qDS-Sz patients.

Periventricular and deep white matter BF are nonspecific abnormalities, sometimes found on MRI, which have no definitive anatomic correlates (Marsh et al 1996). BF may be associated with aging, demylineating disease, or cerebrovascular disease (Awad et al 1986; Brown et al 1992; Coffey et al 1987; Fazekas et al 1988). Higher than expected rates of BF have been reported in bipolar disorder and in major depression in the elderly (Brown et al 1992; Coffey et al 1988; Miller et al 1989; Swayze et al 1990). In schizophrenia, rates of BF were reported to be 5% to 10% of patients (Brown et al 1992, 1995), and were comparable to rates in control subjects (7% to 14% (Brown et al 1992, 1995). An increased prevalence of BF reported in congenital rubella patients with schizophrenia (Lane et al 1996; Lim et al 1995) was felt to be related to ischemic changes associated with congenital rubella but not with schizophrenia (Lane et al 1996). Ischemic changes may be responsible for the increased BF in 22qDS. However, none of the subjects in the current study had known cardiovascular risk factors for BF, such as hypertension, cerebrovascular accidents, vasculitis, or diabetes, and only subjects 2 and 5 had had surgical repair for congenital cardiac defects. Furthermore, the previously reported prevalence of BF in 22qDS patients was only 27% (Mitnick et al 1994), about one-third of the rate in the current study. This suggests that BF may be a more common feature in 22qDS then previously thought, and may be particularly prevalent in 22qDS-Sz.

In contrast to brain anomalies, vascular anomalies are rarely reported in schizophrenia (Aleem and Knesvich 1987; Remington and Jeffries 1984). They were also uncommon in this sample of adults with 22qDS-Sz, and less common than previously reported in children with 22qDS scanned prior to corrective palatal surgery (Finkelstein et al 1993; Goldberg et al 1993; Mitnick et al 1996). This may be due to self-correction of positional anomalies of soft tissue during development. For example, medial displacement of the carotid arteries in children may be reducible simply by hyperextension of the neck (Mitnick et al 1996). Alternatively, vascular anomalies in 22qDS may be especially associated with major palatal involvement, which appears to be uncommon in 22qDS-Sz adults (Bassett et al 1998).

CIHR Author Manuscript CIHR Author Manuscript CIHR Author Manuscript

The skull base anomalies were unexpected findings. They have not been previously reported in 22qDS or schizophrenia. However, they are consistent with other skeletal abnormalities and platybasia previously described in 22qDS (Arvystas and Shprintzen 1984; Finkelstein et al 1993; Ming et al 1997; Ryan et al 1997). One subject had a hypoplastic skull base, raising the question of structural stability of the cervical spine. The subject had no cervical or neurologic complaints. This type of radiologic observation, however, may be important, as unstable cervical vertebrate and skull base structures may lead to compression of the brain stem and are potentially dangerous. Further skeletal studies are needed to fully assess the clinical significance of these skull base abnormalities in 22qDS.

This descriptive study represented an initial MRI investigation on adults with 22qDS-Sz. It is limited by small sample size and lack of a control group, which prevent the determination of statistical significance of the findings of the current study. However, the results for this putative genetic subtype of schizophrenia indicate some overlap of structural brain anomalies with those consistently found in schizophrenia. This may be related to abnormal development of neural crest cells, which has been suggested as the pathogenesis of schizophrenia (Bogerts 1993) and for 22qDS (Thomas and Frias 1987; Van Mierop and Kutsche 1984). Thus, a shared pathogenetic process of abnormal neural crest cell development may account for the high association between 22qDS and neuropsychiatric disorders (Chow et al 1994). Therefore, 22qDS-Sz may provide a neurodevelopmental model of schizophrenia with a known etiology, suitable for further investigations into the pathogenesis of schizophrenia. Results from this study also suggest that MRI abnormalities likely to be more prevalent in 22qDS-Sz, such as BF and skull base abnormalities, may be features that could help clinicians and researchers identify patients with schizophrenia or related disorders who may be at increased risk of having 22qDS.

Acknowledgments

This study was supported by grants from the National Alliance for Research on Schizophrenia and Depression, the Scottish Rite Schizophrenia Research Program, and the Clarke Institute of Psychiatry Foundation Research Fund.

References

Aleem A, Knesvich MA. Schizophrenia-like psychosis associated with vein of Galen malformation: A case report. Can J Psychiatry. 1987; 32:226–227. [PubMed: 3567840]

Altman DH, Altman NR, Mitnick RJ, Shprintzen RJ. Further delineation of brain anomalies in velo-cardio-facial syndrome. Am J Med Genet. 1995; 60:174–175. [PubMed: 7485256]

American Psychiatric Association. Diagnostic and Statistical Manual of Mental Disorders. 4. Washington, DC: American Psychiatric Association; 1994.

Arvystas M, Shprintzen RJ. Craniofacial morphology in the velo-cardio-facial syndrome. J Craniofac Genet Dev Biol. 1984; 4:39–45. [PubMed: 6736220]

Awad IA, Spetzler RF, Hodak JA, Awad CA, Carey R. Identical subcortical lesions identified on magnetic resonance imaging in elderly. I. Correlation with age and cerebrovascular risk factors. Stroke. 1986; 17:1084–1089. [PubMed: 3810705]

Bassett AS, Hodgkinson K, Chow EWC, Correia S, Scutt L, Weksberg R. 22q11 deletion syndrome in adults with schizophrenia. Am J Med Genet (Neuropsychiatr Genet). 1998; 81:328–337.

Beemer FA, de Nef JJ, Delleman JW, Bleeker-Wagemakers EM, Shprintzen RJ. Additional eye findings in a girl with the velo-cardio-facial syndrome (letter). Am J Med Genet. 1986; 25:541–542.

CIHR Author Manuscript CIHR Author Manuscript CIHR Author Manuscript

Bingham PM, Zimmerman RA, McDonald-McGinn D, Driscoll D, Emanuel BS, Zackai E. Enlarged sylvian fissures in infants with interstitial deletion of chromosome 22q11. Am J Med Genet. 1997; 74:538–543. [PubMed: 9342208]

Bodensteiner J, Schaefer G. Wide cavum septum pellucidum: A marker of disturbed brain development. Pediatr Neurol. 1990; 6:391–394. [PubMed: 1705800]

Bogerts B. Recent advances in the neuropathology of schizophrenia. Schizophr Bull. 1993; 19:431–445. [PubMed: 8322039]

Brown FW, Lewine RRJ, Hudgins PA. White matter hyperintensity signals associated with vascular risk factors in schizophrenia. Prog Neuropsychopharmacol Biol Psychiatry. 1995; 19:39–45. [PubMed: 7708930]

Brown FW, Lewine RJ, Hudgins PA, Risch SC. White matter hyperintensity signals in psychiatric and nonpsychiatric subjects. Am J Psychiatry. 1992; 149:620–625. [PubMed: 1575251]

Chow EWC, Bassett AS, Weksberg R. Velo-cardio-facial syndrome and psychotic disorders: Implications for psychiatric genetics. Am J Med Genet (Neuropsychiatr Genet). 1994; 54:107–112.

Coffey CE, Figiel GS, Djang WT, Cress M, Saunders WB, Weiner RD. Leukoencephalopathy in elderly depressed patients referred for ECT. Biol Psychiatry. 1988; 24:1188–1196.

Coffey CE, Hinkle PE, Weiner RD, et al. Electroconvulsive therapy of depression in patients with white matter hyperintensity. Biol Psychiatry. 1987; 22:629–636. [PubMed: 3580437]

Conley ME, Beckwith JB, Mancer JFK, Tenckloff L. The spectrum of the DiGeorge syndrome. J Pediatr. 1979; 94:883–890. [PubMed: 448529]

Daniel DG, Goldberg TE, Gibbons RD, Weinberger DR. Lack of a bimodal distribution of ventricular size in schizophrenia—A gaussian mixture analysis of 1056 cases and controls. Biol Psychiatry. 1991; 30:887–903. [PubMed: 1747437]

Degreef G, Bogerts B, Falkai P, et al. Increased prevalence of the cavum septum pellucidum in magnetic resonance scans and post-mortem brains of schizophrenic patients. Psychiatry Res Neuroimaging. 1991; 45:1–13.

Degreef G, Lantos G, Bogerts B, Ashtari M, Lieberman J. Abnormalities of the septum pellucidum on MR scans in first-episode schizophrenic patients. Am J Neuroradiol. 1992; 13:835–840. [PubMed: 1590179]

DeLisi L, Hoff A, Kushner M, Degreef G. Increased prevalence of cavum septum pellucidum in schizophrenia. Psychiatry Res Neuroimaging. 1993; 50:193–199. [PubMed: 8272454]

Fazekas F, Niederkorn K, Schmidt R, et al. White matter signal abnormalities in normal individuals: Correlation with carotid ultrasonography, cerebral blood flow measurements and cerebrovascular risk factors. Stroke. 1988; 19:1285–1288. [PubMed: 3051534]

Finkelstein Y, Zohar Y, Nachmani A, et al. The otolaryngologist and the patient with velocardiofacial syndrome. Arch Otolaryngol Head Neck Surg. 1993; 119:563–569. [PubMed: 8484947]

First, MB., Spitzer, RL., Gibbon, M., Williams, JBW. Structured Clinical Interview for DSM-IV Axis I Disorders-Clinician Version (SCID-CV). Washington, DC: American Psychiatric Association; 1997.

Goldberg R, Motzkin B, Marion R, Scambler PJ, Shprintzen RJ. Velo-cardio-facial syndrome: A review of 120 patients. Am J Med Genet. 1993; 45:313–319. [PubMed: 8434617]

Gothelf D, Frisch A, Munitz H, et al. Velocardiofacial manifestations and microdeletions in schizophrenic patients. Am J Med Genet. 1997; 72:455–461. [PubMed: 9375731]

Haapanen ML, Somer M. Velocardiofacial syndrome: Analysis of phoniatric and other clinical findings. Folia Phoniatr. 1993; 45:239–246.

Johnson VP, Swayze VW, Sato Y, Andreasen NC. Fetal alcohol syndrome: craniofacial and central nervous system manifestations. Am J Med Genet. 1996; 61:329–339. [PubMed: 8834044]

Johnstone EC, Crow TJ, Frith DC, Husband J, Kreel L. Cerebral ventricular size and cognitive impairment in schizophrenia. Lancet. 1976; 2:924–926. [PubMed: 62160]

Jurjus GJ, Nasrallah HA, Olson SC, Schwarzkopf SB. Cavum septum pellucidum in schizophrenia, affective disorder and healthy controls: A magnetic resonance imaging study. Psychol Med. 1993; 23:319–322. [PubMed: 8332648]

CIHR Author Manuscript CIHR Author Manuscript CIHR Author Manuscript

Karayiorgou M, Morris MA, Morrow B, et al. Schizophrenia susceptibility associated with interstitial deletions of chromosome 22q11. Proceed Natl Acad Sci U S A. 1995; 92:7612–7616.

Kjaer I. Human prenatal craniofacial development related to brain development under normal and pathologic conditions. Acta Odontol Scan. 1995; 53:135–143.

Kwon JS, Shenton ME, Hirayasu Y, et al. MRI study of cavum septi pellucidi in schizophrenia, affective disorder, and schizotypal personality disorder. Am J Psychiatry. 1998; 155:509–515. [PubMed: 9545997]

Lane B, Sullivan E, Lim K, et al. White matter MR hyperintensities in adult patients with congenital rubella. Am J Neuroradiol. 1996; 17:99–103. [PubMed: 8770257]

Lewis S, Mezey G. Clinical correlates of septum pellucidum cavities—An unusual association with psychosis. Psychol Med. 1985; 15:43–54. [PubMed: 2581281]

Lieberman JA. Signs of symptoms: What can they tell us about the clinical course and pathophysiologic processes of schizophrenia? Arch Gen Psychiatry. 1995; 52:361–363. [PubMed: 7726716]

Lim K, Beal M, Harvey R Jr, et al. Brain dysmorphology in adults with congenital rubella plus schizophrenia-like symptoms. Biol Psychiatry. 1995; 37:764–776. [PubMed: 7647161]

Lynch DR, McDonald-McGinn DM, Zackai EH, et al. Cerebellar atrophy in a patient with velocardiofacial syndrome. J Med Genet. 1995; 32:561–563. [PubMed: 7562973]

MacKenzie-Stepner K, Witzel MA, Stringer DA, Lindsay WK, Munro IR, Hughes H. Abnormal carotid arteries in the velocardiofacial syndrome: A report of three cases. Plast Reconstr Surg. 1986; 80:347–351.

Marsh, L., Lauriello, J., Sullivan, E., Pfefferbaum, A. Neuro-imaging in psychiatric disorders. In: Bigler, ED., editor. Neuroimaging II: Clinical Applications. New York: Plenum Press; 1996. p. 73-125.

McDonald-McGinn DM, Driscoll DA, Bason L, et al. Autosomal dominant “Optiz” GBBB syndrome due to a 22q11.2 deletion. Am J Med Genet. 1995; 59:103–113. [PubMed: 8849001]

Miller B, Lesser I, Boone K, et al. Brain white-matter lesions and psychosis. Br J Psychiatry. 1989; 155:73–78. [PubMed: 2605435]

Ming JE, McDonald-McGinn DM, Megerian TE, et al. Skeletal anomalies and deformities in patients with deletions of 22q11. Am J Med Genet. 1997; 72:210–215. [PubMed: 9382145]

Mitnick RJ, Bello JA, Golding-Kushner KJ, Argamaso RV, Shprintzen RJ. The use of magnetic resonance angiography prior to pharyngeal flap surgery in patients with velocardiofacial syndrome. Plast Reconstr Surg. 1996; 97:908–919. [PubMed: 8618993]

Mitnick RJ, Bello JA, Shprintzen RJ. Brain anomalies in velo-cardio-facial syndrome. Am J Med Genet (Neuropsychiatr Gene). 1994; 54:100–106.

Murphy KC, Owen MJ. The behavioral phenotype in velo-cardio-facial-syndrome. Am J Hum Genet. 1997; 61:A5.

Nasrallah HA, Schwarzkopf SB, Olson SC, Coffman JA. Gender differences in schizophrenia on MRI brain scans. Schizophr Bull. 1990; 16:205–209. [PubMed: 2374881]

Nickel RE, Pillers DAM, Merkens M, et al. Velo-cardio-facial syndrome and DiGeorge sequence with meningomyelocele and deletions of the 22q11 region. Am J Med Genet. 1994; 52:445–449. [PubMed: 7747757]

Nopoulos P, Giedd J, Andreasen N, Rapoport J. Frequency and severity of enlarged cavum septi pellucidi in childhood-onset schizophrenia. Am J Psychiatry. 1998; 155:1074–1079. [PubMed: 9699696]

Nopoulos P, Swayze V, Flaum M, Ehrhardt J, Yuh W, Andreasen N. Cavum septi pellucidi in normals and patients with schizophrenia as detected by magnetic resonance imaging. Biol Psychiatry. 1997; 41:1102–1108. [PubMed: 9146821]

Pearlson, GD., Marsh, L. Magnetic resonance imaging in psychiatry. In: Oldham, JU.Riba, MB., Tasmas, A., editors. Annual Review of Psychiatry. Vol. 12. Washington DC: American Psychiatric Association Press; 1993. p. 347-381.

Pfefferbaum A, Zipursky RB. Neuroimaging studies of schizophrenia. Schizophr Res. 1991; 4:193–208. [PubMed: 2039761]

CIHR Author Manuscript CIHR Author Manuscript CIHR Author Manuscript

Pulver AE, Nestadt G, Goldberg R, et al. Psychotic illness in patients diagnosed with velo-cardio-facial syndrome and their relatives. J Nerv Ment Dis. 1994; 182:476–478. [PubMed: 8040660]

Remington G, Jeffries JJ. The role of cerebral arteriovenous malformations in psychiatric disturbances: Case Report. J Clin Psychiatry. 1984; 45:226–229. [PubMed: 6725213]

Ryan AK, Goodship JA, Wilson DI, et al. Spectrum of clinical features associated with interstitial chromosome 22q11 deletions: A European collaborative study. J Med Genet. 1997; 34:798–804. [PubMed: 9350810]

Sarwar M. The septum pellucidum: Normal and abnormal. Am J Neuroradiol. 1989; 10:989–1005. [PubMed: 2505543]

Schaefer G, Bodensteiner J, Thompson J. Subtle anomalies of the septum pellucidum and neurodevelopmental deficits. Dev Med Child Neurol. 1994; 36:554–559. [PubMed: 7516298]

Scott T, Price T, George M, Brillman J, Rothfus W. Midline cerebral malformations and schizophrenia. J Neuropsychiatry Clin Neurosci. 1993; 5:287–293. [PubMed: 8369638]

Shelton, RC., Weinberger, DR. X-ray computerized tomography studies in schizophrenia: A review and synthesis. In: Nasrallah, HA., Weinberger, D., editors. The Neurology of Schizophrenia. Amsterdam: Elsevier; 1986. p. 207-250.

Shioiri T, Oshitani Y, Kato T, et al. Prevalence of cavum septum pellucidum detected by MRI in patients with bipolar disorder, major depression and schizophrenia. Psychol Med. 1996; 26:431–434. [PubMed: 8685300]

Shprintzen RJ, Goldberg R, Golding-Kushner KJ, Marion RW. Late-onset psychosis in the velo-cardio-facial syndrome (letter). Am J Med Genet. 1992; 42:141–142. [PubMed: 1308357]

Silverstein AB. Two- and four-subtest short forms of the Wechsler Adult Intelligence Scale Revised. J Consult Clin Psychol. 1982; 50:415–418.

Strong WB. Familial syndrome of right-sided aortic arch, mental deficiency, and facial dysmorphism. J Pediatr. 1968; 73:882–888. [PubMed: 5696314]

Swayze VW, Andreason NC, Alliger RJ, Ehrhardt JC, Yuh WTC. Structural brain abnormalities in bipolar affective disorder—Ventricular enlargement and focal signal hyperintensities. Arch Gen Psychiatry. 1990; 47:1054–1059. [PubMed: 2241506]

Thomas IT, Frias JL. The heart in selected congenital malformations: A lesson in pathogenetic relationships. Ann Clin Lab Sci. 1987; 17:207–210. [PubMed: 3619396]

Thomas JA, Graham JM Jr. Chromosome 22q11 deletion syndrome: An update and review for the primary pediatrician. Clin Pediatr. 1997; 36:253–266.

Van Mierop LHS, Kutsche LM. Interruption of the aortic arch and coarctation of the aorta: Pathogenetic relations. Am J Cardiol. 1984; 54:829–834. [PubMed: 6486034]

Vataja R, Elomaa E. Midline brain anomalies and schizophrenia in people with CATCH 22 syndrome. Br J Psychiatry. 1998; 172:518–520. [PubMed: 9828993]

Weinberger DR. Implications of normal brain development for the pathogenesis of schizophrenia. Arch Gen Psychiatry. 1987; 44:660–669. [PubMed: 3606332]

Wraith JE, Super M, Watson GH, Phillips M. Velo-cardio-facial syndrome presenting as holoprosencephaly. Clin Genet. 1985; 27:408–410. [PubMed: 3995791]

Yan W, Jacobsen LK, Krasnewich DM, et al. Chromosome 22q11.2 interstitial deletions among childhood-onset schizophrenics and “multidimensionally impaired. Am J Med Genet (Neuropsychiatr Genet). 1998; 81:41–43.

Zipursky RB, Lim KO, Sullivan EV, Brown BW, Pfefferbaum A. Widespread cerebral gray matter volume deficits in schizophrenia. Arch Gen Psychiatry. 1992; 49:195–205. [PubMed: 1567274]

Zipursky RB, Marsh L, Lim KO, et al. Volumetric MRI assessment of temporal lobe structures in schizophrenia. Biol Psychiatry. 1994; 35:501–516. [PubMed: 8038294]

CIHR Author Manuscript

CIHR Author Manuscript

CIHR Author Manuscript

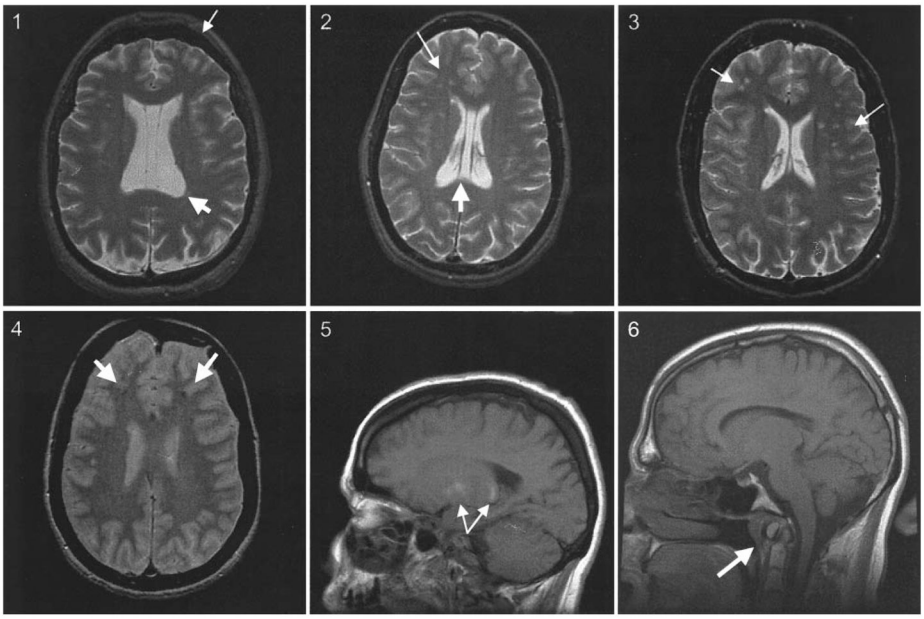

Figure 1.

Axial and sagittal magnetic resonance images from five different 22qDS-Sz subjects (**4** and **5** from the same subject). **(1)** Moderate enlargement of the lateral ventricles (large arrow) and mild cortical atrophy (small arrow). **(2)** A cavum vergae (large arrow) and multiple bright foci (small arrow). **(3)** Numerous bright foci. **(4)** Hypodensities in the "U" fibers bilaterally. **(5)** Signal changes consistent with calcifications in the basal ganglia and the thalamus. **(6)** The hypoplastic skull base.

CIHR Author Manuscript

CIHR Author Manuscript

CIHR Author Manuscript

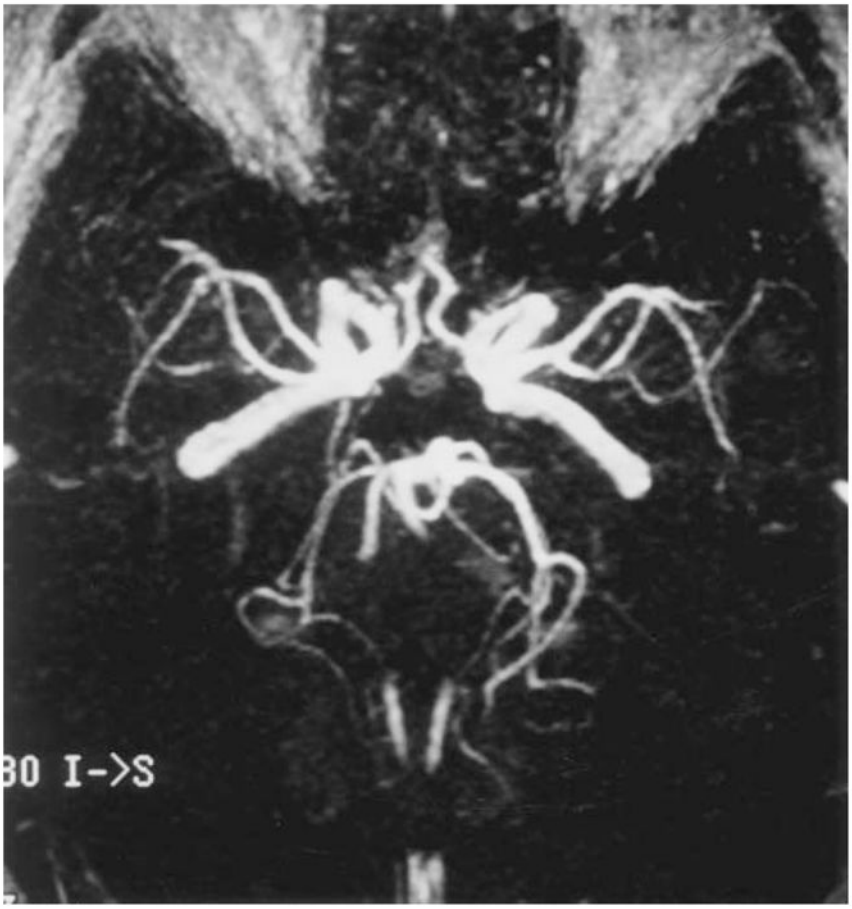

Figure 2.

Magnetic resonance angiography image of the circle of Willis, shown with the subject's right side on the reader's left. Note that the right posterior cerebral artery is smaller than its left counterpart.

CIHR Author Manuscript CIHR Author Manuscript CIHR Author Manuscript

Table 1

nd MRA Findings in 11 Subjects with 22qDS-Sz

				Structural brain anomalies				Skull base anomalies				
				Ventricular enlargement		Atrophy						
t number	Age, gender	Number of BF	CSP/CV	Lateral	4th	Cerebral	Cerebellar	Enlarged C1 arch	Prominent cisterna magna	Short clivus	Small odontoid	Vascular anomalies
1	23, F	4	CV	−	−	−	−	−	−	−	−	–[a]
2	29, F	14	CV	−	−	−	−	+	−	−	−	−
3	35, F	10	−	−	−	−	−	+	−	−	+	−
4	35, F	N/A[b]	CV	−	−	mod	mild	+	+	+	−	−
5	36, F	5	−	−	−	mild[c]	mild	−	−	−	−	Smaller R posterior cerebral artery in CW[a]
6	21, M	2	−	−	−	−	−	−	−	−	−	−
7	22, M	2	CSP	mod[d]	mod	−	−	−	−	−	−	−
8	22, M	0	−	−	−	−	−	+[e]	+	+	+	Hypoplastic A1 segment in CW
9	25, M	63	−	−	mild	−	mild[f]	+	−	+	−	−
10	26, M	2	−	mild	−	−	−	−	−	−	−	Hypoplastic R posterior cerebral artery in CW and small R vertebral artery
11	38, M	2	CV	mod	mod	mild[g]	Inferior vermis hypoplasia	+	+	−	−	Hypoplastic A1 segment in CW

ight foci; CSP, cavum septum pellucidum; CV, cavum vergae; CW, circle of Willis; +, present; −, absent; mod, moderate; R, right.

vailable only for the circle of Willis.

cause BF were not detectable due to motion artefact.

ndings include focal T2 hypointensities in U fibers at the gray-white matter junction, signal changes consistent with mineral deposition in the basal ganglia and the thalamus, a pineal cyst, and a npty sella.

third ventricle.

stic skull base.

ive ataxia in recent years.

[g]Empty sella.

CIHR Author Manuscript
CIHR Author Manuscript
CIHR Author Manuscript