NIH Public Access
Author Manuscript
*Vet Immunol Immunopathol*. Author manuscript; available in PMC 2013 January 15.

Published in final edited form as:
*Vet Immunol Immunopathol*. 2012 January 15; 145(1-2): 1–6. doi:10.1016/j.vetimm.2011.12.005.

# Crohn's disease and *Mycobacterium avium* subsp. *paratuberculosis*, the need for a study is long overdue

**William C. Davis** and **Sally A. Madsen-Bouterse**
Department of Veterinary Microbiology and Pathology, Washington State University, Pullman, WA 99164

## Abstract

The initial suggestion that *Mycobacterium avium* subsp. *paratuberculosis* (*Map*) might be involved in the pathogenesis of Crohn's (CD) disease was based on the apparent similarity of lesions in the intestine of patients with CD with those present in cattle infected with *Map*, the etiological agent of Johne's disease (JD). Recent investigations have now revealed the presence of *Map* or *Map* DNA in blood or lesions from adults and children with CD. Of special interest, *Map* has also been found in patients with other diseases as well as healthy subjects. The latter observations indicate all humans are susceptible to infection with *Map* and that, like with other mycobacterial pathogens such as *Mycobacterium tuberculosis*, infection does not invariably lead to development of clinical disease but rather development of a persistent latent stage of infection where an immune response controls but does not eliminate the pathogen. Limited information has been obtained on the immune response to *Map* in healthy subjects and patients with CD. Understanding how *Map* may be involved in the pathogenesis of CD will require a better understanding of the immune response to *Map* in one of its common hosts as well as healthy humans and patients with CD.

### Keywords

Crohn's disease; Johne's disease; *Mycobacterium avium* subsp. *paratuberculosis*; animal model; flow cytometry; cytokines

## Introduction

Extensive studies have been conducted to determine whether *Mycobacterium avium* subsp. *paratuberculosis* (*Map*) is involved in the pathogenesis of Crohn's disease (CD), a chronic inflammatory bowel disease that occurs in humans. The initial suggestion that *Map* may be involved was based on the apparent similarity in the clinical manifestations of CD with Johne's disease (JD) a chronic enteritis in cattle caused by *Map* (Dalziel, 1913; Crohn et al., 1932). A correlation in the increased incidence of CD worldwide during the past 100 plus

© 2011 Elsevier B.V. All rights reserved.

Corresponding author: William C. Davis, Phone: (509) 335-6051, Fax: (509) 335-8328, Department of Veterinary Microbiology and Pathology, PO 647040, College of Veterinary Medicine, Washington State University, Pullman Washington 99164-7040, davisw@vetmed.wsu.edu.

**Publisher's Disclaimer:** This is a PDF file of an unedited manuscript that has been accepted for publication. As a service to our customers we are providing this early version of the manuscript. The manuscript will undergo copyediting, typesetting, and review of the resulting proof before it is published in its final citable form. Please note that during the production process errors may be discovered which could affect the content, and all legal disclaimers that apply to the journal pertain.

The authors of this manuscript do not have any commercial or other associations that might pose a conflict of interest for this manuscript.

NIH-PA Author Manuscript
NIH-PA Author Manuscript
NIH-PA Author Manuscript

NIH-PA Author Manuscript

NIH-PA Author Manuscript

NIH-PA Author Manuscript

years with the increased incidence of JD in dairy cattle has provided indirect support for this supposition (reviewed in (Hermon-Taylor, 2009)). The isolation of *Map* from patients with CD during the 1980s provided the first direct evidence for a potential role of *Map* in CD pathogenesis (Chiodini et al., 1984a). However, until recently, it proved difficult to isolate *Map* from patients with CD, raising a question as to whether *Map* plays any role in CD pathogenesis. In addition, efforts to use genome wide analyses to show an association between *Map* and CD have suggested there is no clear association (Nacy and Buckley, 2008; Barrett et al., 2008; Over et al., 2011). Over 30 genes have been identified that show there is a genetic component associated with the occurrence of CD (Barrett et al., 2008), but a specific association with *Map* exposure has yet to be shown. Although the role of *Map* in the pathogenesis of CD remains to be elucidated, recent improvements in technology have overcome some of the difficulties in isolation of *Map* from patients with CD. Whereas detection of *Map* by standard microbiological staining methods has been a challenge in individuals with CD, investigations have now revealed the presence of *Map* or *Map* DNA in blood or lesions from many adults and children with CD (Naser et al., 2009; Autschbach et al., 2005; Bull et al., 2003; Kirkwood et al., 2009; Lee et al., 2011; Mendoza et al., 2010; Chiappini et al., 2009). Of special interest, *Map* has also been found in patients with other diseases as well as healthy subjects by several techniques (Juste et al., 2009; Tuci et al., 2011; Singh et al., 2008; Singh et al., 2011). These latter observations indicate a need to look at the role of *Map* in pathogenesis of CD in a broader context. The difficulty in finding an association between CD and *Map* may be lack of consideration of the characteristic features of pathogenesis of *Map* in one of the common host species, cattle.

Johne's disease is not an epidemic disease. It is characterized by a long latency period following exposure, with clinical disease developing in some animals two or more years post infection (PI). The infection is under immune control during the latency period. Environmental stress or other factors lead to dysregulation of protective immunity and development of disease, similar to events associated with a breakdown of immunity in tuberculosis. It is hypothesized to be the same situation for *Map* infection in humans (Mendoza et al., 2010; Tuci et al., 2011), but this possibility has not been explored. At this juncture, information on the characteristics of the immune response to *Map* have been obtained primarily from patients with CD (Olsen et al., 2009). Very little information has been obtained on the immune response in healthy latently infected subjects (Mendoza et al., 2010; Juste et al., 2009). If latent infection with *Map* is similar to latent infection observed in subjects persistently infected with *Mycobacterium tuberculosis* (*Mtb*), it would be expected that the majority of subjects exposed to *Map* would become latently infected and develop an immune response that controls infection. Some infected subjects, with or without reported risk factors, would be expected to develop disease (Barrett et al., 2008; Mendoza et al., 2010). The mechanisms leading to breakdown in protective immunity would be expected to be similar to those associated with a breakdown in protective immunity to *Mtb*. These events would also be the same as the events that occur in pathogenesis of JD.

## Bovine model of Crohn's disease

It is clear that much of the controversy on the role of *Map* in CD pathogenesis could be resolved if there were a better understanding of the immune response to *Map* in its common hosts and humans. The information would be useful in revealing similarities between the immune response to mycobacterial pathogens in humans and cattle in general and, specifically, the similarities in the immune response to *Map*. Recent studies show that the cytokine/chemokine network that regulates functional interaction of innate lymphoid cells (ILC) (Kleinschek et al., 2009) with effector cells (Brand, 2009; Kobayashi et al., 2008; Hue et al., 2006; Ahern et al., 2010) and regulatory T cells (Tr) (Eastaff-Leung et al., 2010) is involved in the pathogenesis of CD and TB (Khader and Cooper, 2008; Torrado and Cooper,

NIH-PA Author Manuscript

NIH-PA Author Manuscript

NIH-PA Author Manuscript

2010; Zeng et al., 2011; Scriba et al., 2008; Chen et al., 2007; Chen et al., 2010; Sharma et al., 2009). *Map* affords an opportunity to examine the immune response during the early and late stages of infection and obtain data that would provide insight into the cellular and molecular events that lead to dysregulation of protective immunity for both JD and TB (Davis et al., 2010). These data would also provide insight into how a mycobacterial pathogen could contribute to the pathogenesis of CD starting with initial interactions of *Map* with ILC and antigen presenting cells (APC) (Buonocore et al., 2010; Ahern et al., 2010; Sakuraba et al., 2009; Demangel and Britton, 2000; Jiao et al., 2002).

Various models have been developed to study the mechanisms of pathogenesis of JD. Terminal experimental model systems have shown *Map* is taken up by intestinal M cells and enterocytes (Momotani et al., 1988; Sigurðardóttir et al., 2004; Sigurðardóttir et al., 2005). Other experimental systems have shown *Map* can also be taken up by kidney cells (Bannantine et al., 2003) and enteric glial cells in vitro (Bannantine et al., 2003; Sechi et al., 2007). A surgical intervention model has shown *Map* introduced directly into the ileum are rapidly taken up and disseminated to lymph nodes and other tissues (Wu et al., 2007), results similar to dissemination following exposure by the oral route (Sweeney et al., 2006). Bacteria persist but at a low level, more readily detected by PCR than culture. Results obtained with neonatal model systems have shown a resilient, cell-mediated immune response (CMI) develops within the first months PI and is detectable with a flow cytometric assay (Koo et al., 2004). Exposure to large concentrations of Map (up to $10^{12}$ organisms) has not altered the immune response or accelerated disease progression (Stabel et al., 2009). Though less informative, a CMI response is also detectable with an IFN-γ assay (reviewed in (Rideout et al., 2003; Barrington et al., 2003). Initial studies by flow cytometry have shown a CMI response, dominated by CD4 T cells, develops by 5 to 6 months in calves inoculated orally with *Map* within a few days after birth. A less vigorous CD8 response is also detectable (Koo et al., 2004). In contrast, a humoral response to some *Map* antigens becomes detectable by 4 months PI (Waters et al., 2003; Bannantine et al., 2008).

Development of a cannulated ileum model has provided an opportunity to extend these initial observations and study the immune response to *Map* at all stages of infection (Fig. 1) (Allen et al., 2009). As noted previously, bacteria introduced directly into the ileum were cleared rapidly with no tissue-associated bacteremia (Wu et al., 2007). During the first weeks PI, bacteria were detected in ileal biopsies by PCR whereas detection by culture was more difficult. Endoscopic evaluation revealed instillation of bacteria once versus multiple times did not induce an inflammatory response in the mucosa. Histopathological examination of biopsies showed there was a transient eosinophilia. Giant cells, characteristic of early stages of development of granulomatous lesions, were not detected during the duration of the study. Further use of the model showed animals could be maintained for up to 15 months with no evidence of development of an inflammatory response (Allen et al., 2011). In addition, this study demonstrated that animals at the clinical stage of infection could be cannulated and maintained, allowing for ileum access to compare early and late stages of infection.

Two important observations resulted from the availability of the cannulated ileum model, 1) comparison of the infectivity and immunogenicity of the first isolates of *Map* obtained from patients with CD (Chiodini et al., 1984b) with isolates from cattle revealed passage through humans did not alter the capacity of the isolates to infect and establish a persistent infection or alter their capacity to elicit an immune response, and 2) comparison of the immune response during the early and late stages of infection ex vivo revealed that a CD4 T cell response to *Map* antigens in experimentally infected animals at four months PI is equivalent to the response in naturally infected animals at the clinical stage of infection. The CD8 T cell response is equivalent by eleven months PI (Fig. 2) (Allen et al., 2011). Examination

NIH-PA Author Manuscript

NIH-PA Author Manuscript

NIH-PA Author Manuscript

thus far has shown mRNAs encoding IFN-γ, IL-17, IL-22, and granulysin are up-regulated in calves following experimental infection with live *Map* and a relA deletion mutant (Fig. 3) (Park et al., 2011). Cells of the ileocecal and mesenteric lymph nodes from calves experimentally infected with *Map* and cows at the clinical stage of infection also revealed similar up-regulation of mRNA's that encode these cytokines (Fig. 4) (Allen et al., 2011) and thus, not revealing any difference related to dysregulation of protective immunity in experimental versus naturally infected animals. Together, these studies demonstrate the complexity of the immune response to *Map* showing that it includes combinations of T cell subsets secreting one or more of the newly identified proinflammatory IL-17 and IL-22 cytokines

## A study long overdue

The finding that healthy humans can become persistently infected with *Map* (Tuci et al., 2011) emphasizes the need to gain a better understanding of the immune response to *Map* in the common host species as well as humans. No information has been obtained on the immune response to *Map* during the latent stage of infection in healthy subjects. Studies in cattle suggest the early immune response may be similar to the immune response to *Mtb* during the latent stage of infection. Exposure to *Mtb* is controlled by development of CMI during this quiescent phase of infection. The response includes subsets of CD4 T cells with increased expression of IFN-γ, IL-17, IL-22 and granulysin. Extensive studies in humans infected with *Mtb* show discrete CD4 T cell subsets secreting one or more of these cytokines are up-regulated during the latent stage of infection and may contribute to maintaining protective immunity (Scriba et al., 2008). Subsets with Th1/Th17, Th17, and Th22 phenotypes have been identified in subjects latently infected with *Mtb*. Granulysin, a bactericidal peptide, has also been identified and may play a role in protective immunity (Tewary et al., 2010). Studies in mice and humans suggest loss of protection is attributable to development of regulatory T cells (Tr). Studies have revealed the presence of Tr cells in peripheral blood and lesions of patients with active TB (Ribeiro-Rodrigues et al., 2006; Sharma et al., 2009; Boussiotis et al., 2000; Chen et al., 2007; Sharma et al., 2009). Though limited, studies in cattle have shown $Foxp3^{+}$ cells may comprise 40% of CD4 T cells proliferating in response to *Map* antigens ex vivo (Fig. 5) (unpublished observation) indicating Tr cells might be involved in the pathogenesis of JD.

The similarities in the immune response during the latent stage of infection with *Mtb* and *Map* indicate more in depth studies will reveal common features of the immune responses associated with persistence of protective immunity and insight into changes associated with a breakdown of protective immunity, changes difficult to study in patients with active TB. The findings would also be useful for understanding the immune response to *Map* in humans. Detailed information in cattle would provide background information for comparing the immune response during the latent stage of *Map* infection in healthy subjects and in patients with CD. Recent studies show IL-23 plays a central role in driving the inflammatory response in CD (Ahern et al., 2010; Kobayashi et al., 2008; Sakuraba et al., 2009) and that the target effector cell population includes effector T cells subsets expressing CD161 (Kleinschek et al., 2009; Annunziato and Romagnani, 2009). Studies in cattle at the clinical stage of infection could reveal IL-23 also plays a central role and that it may be one of the factors involved in a breakdown in protective immunity. Additional studies could also reveal how Tr cells are involved. Analysis in CD suggests there is in imbalance in the ratio of Th17 cells and Tr cells associated with clinical disease (Eastaff-Leung et al., 2010). These cell populations are present in cattle and can be tracked at different stages of infection to reveal the triggering events that initiate breakdown in protective immunity. In lieu of a long overdue comparative study, these questions and more could be answered through the study of *Map* infection in its common host, studies not possible in humans.

NIH-PA Author Manuscript

NIH-PA Author Manuscript

NIH-PA Author Manuscript

## Acknowledgments

Financial support:

This project was funded in part with funds from the National Institute of Allergy and Infectious Diseases, National Institutes of Health, Department of Health and Human Services, under Contract No. N01-AI-30055, the JDIP program (USDA-CSREES-NRI-CAP Award No.2007-01019) awarded to WCD, USDA-NRI grant (2005-35204-16106) and the WSU Monoclonal Antibody Center.

## Reference List

Ahern PP, Schiering C, Buonocore S, McGeachy MJ, Cua DJ, Maloy KJ, Powrie F. Interleukin-23 drives intestinal inflammation through direct activity on T cells. Immunity. 2010; 33:279–288. [PubMed: 20732640]

Allen AJ, Park KT, Barrington GM, Hamilton MJ, Davis WC. Development of a bovine lleal cannulation model to study the immune response and mechanisms of pathogenesis paratuberculosis. Clin.Vaccine Immunol. 2009; 16:453–463. [PubMed: 19225077]

Allen AJ, Park KT, Barrington GM, Lahmers KK, Abdellrazeq GS, Rihan HM, Sreevatsan S, Davies C, Hamilton MJ, Davis WC. Experimental infection of a bovine model with human isolates of Mycobacterium avium subsp. paratuberculosis. Vet.Immunol.Immunpathol. 2011; 141:258–266.

Annunziato F, Romagnani S. Do studies in humans better depict Th17 cells? Blood. 2009; 114:2213–2219. [PubMed: 19494349]

Autschbach F, Eisold S, Hinz U, Zinser S, Linnebacher M, Giese T, Löffler T, Büchler MW, Schmidt J. High prevalence of Mycobacterium avium subspecies paratuberculosis IS900 DNA in gut tissues from individuals with Crohn's disease. Gut. 2005; 54:944–949. [PubMed: 15951539]

Bannantine JP, Huntley JFJ, Miltner E, Stabel JR, Bermudez LE. The Mycobacterium avium subsp. paratuberculosis 35 kDa protein plays a role in invasion of bovine epithelial cells. Microbiology. 2003; 149:2061–2069. [PubMed: 12904546]

Bannantine JP, Paustian ML, Waters WR, Stabel JR, Palmer MV, Li L, Kapur V. Profiling bovine antibody responses to Mycobacterium avium subsp. paratuberculosis infection by using protein arrays. Infect.Immun. 2008; 76:739–749. [PubMed: 18039835]

Barrett JC, Hansoul S, Nicolae DL, Cho JH, Duerr RH, Rioux JD, Brant SR, Silverberg MS, Taylor KD, Barmada MM, Bitton A, Dassopoulos T, Datta LW, Green T, Griffiths AM, Kistner EO, Murtha MT, Regueiro MD, Rotter JI, Schumm LP, Steinhart AH, Targan SR, Xavier RJ, NIDDK IND Genetics Consortium; Libioulle C, Sandor C, Lathrop M, Belaiche J, Dewitt O, Guy I, Heath S, Laukens D, Mni M, Rutgeerts P, Van Gossum A, Zelenika D, Franchimont D, Hugot J-P, de Vos M, Vermeire S, Louis E, Belgian-French IBD Consortium, Wellcome Trust Case Control Consortium. Cardon LR, Anderson CA, Drummond H, Nimmo E, Ahmad T, Prescott NJ, Onnie CM, Fisher SA, Marchini J, Ghori J, Bumpstead S, Gwilliam R, Tremelling M, Deloukas P, Manfield J, Jewell D, Satsangi J, Mathew CG, Parkes M, Georges M, Daly MJ. Genome-wide association defines more than 30 distinct susceptibility loci for Crohn's disease. Nat.Genet. 2008; 40:955–962. [PubMed: 18587394]

Barrington GM, Gay JM, Eriks IS, Davis WC, Evermann JF, Emerson C, O'Rourke JL, Hamilton MJ, Bradway DS. Temporal patterns of diagnostic results in serial samples from cattle with advanced paratuberclosis infections. J.Vet.Diagn.Invest. 2003; 15:195–200. [PubMed: 12661735]

Boussiotis VA, Tsai EY, Yunis EJ, Thim S, Delgado JC, Dascher CC, Berezovskaya A, Rousset D, Reynes J-M, Goldfeld AE. IL-10-producing T cells suppress immune responses in anergic tuberculosis patients. J.Clin.Invest. 2000; 105:1317–1325. [PubMed: 10792007]

Brand S. Crohn's disease: Th1, TH17 or both? The change of a paradigm: new immunological and genetic insights implicate Th17 cells in the pathogenesis of Crohn's disease. Gut. 2009; 58:1152–1167. [PubMed: 19592695]

Bull TJ, McMinn EJ, Sidi-Boumedine K, Skull A, Durkin D, Neild P, Rhodes G, Pickup R, Hermon-Taylor J. Detection and verification of Mycobacterium avium subsp. paratuberculosis in fresh ileocolonic mucosal biopsy specimens from individuals with and without Crohn's disease. J.Clin.Microbiol. 2003; 41:2915–2923. [PubMed: 12843021]

NIH-PA Author Manuscript NIH-PA Author Manuscript NIH-PA Author Manuscript

Buonocore S, Ahern PP, Uhlig HH, Ivanov II, Littman DR, Maloy KJ, Powrie F. Innate lymphoid cells drive interleukin-23-dependent innate intestinal pathology. Nature. 2010; 464:1371–1375. [PubMed: 20393462]

Chen X, Zhang M, Liao M, Graner MW, Wu C, Yang Q, Liu H, Zhou B. Reduced TH17 response in patients with tuberculosis correlates with IL-6R expression on CD4+ T cells. Am.J.Respir.Crit.Care Med. 2010; 181:734–742. [PubMed: 20019339]

Chen X, Zhou B, Li M, Deng Q, Wu X, Le X, Wu C, Larmonier N, Zhang W, Zhang H, Wang H, Katsanis E. CD4+CD25+FoxP3+ regulatory T cells suppress Mycobacterium tuberculosis immunity in patients with active disease. Clin.Immunol. 2007; 123:50–59. [PubMed: 17234458]

Chiappini E, de Martino M, Mangiantini F, Lionetti P. Crohn's disease and mycobacterial infection in children: an intriguing relationship. J.Pediatr.Gasterenterol.Nutr. 2009; 49:550–558.

Chiodini RJ, Van Kruiningen HJ, Merkal RS, Thayer WR Jr. Coutu JA. Characteristics of an unclassified Mycobacterium species isolated from patients with Crohn's disease. J.Clin.Microbiol. 1984a; 20:966–971. [PubMed: 6511878]

Chiodini RJ, Van Kruiningen HJ, Thayer WR, Coutu JA, Merkal RS. Possible role of mycobacteria in inflammatory bowel disease. I. An unclassified Mycobacterium species isolated from patients with Crohn's disease. Dig.Dis.Sci. 1984b; 29:1073–1079. [PubMed: 6499624]

Crohn BB, Ginzburg L, Oppenheimer G. Regional ileitis: a pathologic and clinical entity. JAMA. 1932; 99:1323–1329.

Dalziel TK. Chronic interstitial enteritis. Br Med J. 1913; ii:1068–1070.

Davis WC, Park JT, Hamilton MJ, Waters WR. Understanding the mechanisms of immunopathogenesis of human and bovine tuberculosis. J.Zoonoses. 2010; 1:17–23.

Demangel C, Britton WJ. Interaction of dendritic cells with mycobacteria: where the action starts. Immunol.Cell Biol. 2000; 78:318–324. [PubMed: 10947855]

Eastaff-Leung N, Mabarrack N, Barbour A, Cummins A, Barry S. Foxp3+ regulatory T cells, Th17 effector cells, and cytokine environment in inflammatory bowel disease. J.Clin.Immunol. 2010; 30:80–89. [PubMed: 19936899]

Hermon-Taylor J. Mycobacterium avium subspecies paratuberculosis, Crohn's disease and the doomsday scenario. Gut Pathog. 2009; 1:6. [PubMed: 19338686]

Hue S, Ahern P, Buonocore S, Kullberg MC, Cua DJ, McKenzie BS, Powrie F, Maloy KJ. Interleukin-23 drive innate and T cell-mediated intestinal inflammation. J.Exp.Med. 2006; 203:2473–2483. [PubMed: 17030949]

Jiao X, Lo-Man R, Guermonprez P, Fiette L, Dériaud E, Burgaud S, Gicquel B, Winter N, Leclerc C. Dendritic cells are host cells for Mycobacteria in vivo that trigger innate and acquired immunity. J.Immunol. 2002; 168:1294–1301. [PubMed: 11801668]

Juste RA, Elguezabal N, Pavón A, Garrido JM, Geijo M, Sevilla I, Cabriada JL, Tejada A, García-Campos F, Casado R, Ochotorena I, Izeta A. Asssociation between Mycobacterium avium subsp. paratuberculosis DNA in blood and cellular and humoral immune response in inflammatory bowel disease patients and controls. Int.J.Infect.Dis. 2009; 13:247–254. [PubMed: 18922720]

Khader SA, Cooper AM. IL-23 and IL-17 in tuberculosis. Cytokine. 2008; 41:79–83. [PubMed: 18218322]

Kirkwood CD, Wagner J, Boniface K, Vaughn J, Michalski WP, Catto-Smith A, Cameron DJS, Bishop RF. Mycobacterium avium subspecies paratuberculosis in children with early-onset Crohn's disease. Inflamm.Bowel Dis. 2009; 15:1643–1655. [PubMed: 19462429]

Kleinschek MA, Boniface K, Sadekova S, Grein J, Murphy EE, Turner SP, Raskin L, Desai B, Faubion WA, de Waal Malefy R, Pierce RH, McClanahan T, Kastelein RA. Cirulating and gut-residemt human Th17 cells express CD161 and promote intestinal inflammation. J.Exp.Med. 2009; 206:525–534. [PubMed: 19273624]

Kobayashi T, Okamoto S, Hisamatsu T, Kamada N, Chinen H, Saito R, Kitazume MT, Nakazawa A, Sugit A, Koganei K, Isobe K, Hibi T. IL23 differentially regulates the Th1/Th17 balance in ulcerative colitis and Crohn's disease. Gut. 2008; 57:1682–1689. [PubMed: 18653729]

Koo HC, Park YH, Hamilton MJ, Barrington GM, Davies CJ, Kim JB, Dahl JL, Waters WR, Davis WC. Analysis of the immune response to Mycobacterium avium subsp. paratuberculosis in experimentally infected calves. Infect.Immun. 2004; 72:6870–6883. [PubMed: 15557608]

NIH-PA Author Manuscript NIH-PA Author Manuscript NIH-PA Author Manuscript

Lee A, Griffiths TA, Parab RS, King RK, Dubinsky MC, Urbanski SJ, Wrobel I, Rioux KP. Association of Mycobacterium avium subspecies paratuberculosis with Crohn's disease in pediatric patients. J.Pediatr.Gastroenterol.Nutr. 2011; 2011:174.

Mendoza JL, San-Pedro A, Culebras E, Cies R, Taxonera C, Lana R, Urcelay E, de la Torre F, Picazo JJ, Diaz-Rubio M. High prevalence of viable Mycobacterium avium subspecies paratuberculosis in Crohn's disease. World J.Gastroenterol. 2010; 16:4558–4563. [PubMed: 20857526]

Momotani E, Whipple DL, Thiermann AB, Cheville NF. Role of M cells and macrophages in the entrance of Mycobacterium paratuberculosis into domes of ileal Peyer's patches in calves. Vet.Pathol. 1988; 25:131–137. [PubMed: 3363791]

Nacy, C.; Buckley, M. Mycobacterium avium paratuberculosis: infrequent human pathogen or public health threat?. American Academy of Microbiology; Washington DC: 2008. p. 1-37.(GENERIC) Ref Type: Report

Naser SA, Collins MT, Crawford JT, Valentine JF. Culture of Mycobacterium avium subspecies paratuberculosis (MAP) from the blood of patients with Crohn's disease: a follow-up blind multi center investigation. The Open Inflamm.J. 2009; 2:22–23.

Olsen I, Tollefsen S, Aagaard C, Reitan LJ, Bannantine JP, Andersen P, Sollid LM, Lundin KEA. Isolation of Mycobacterium avium subspecies paratuberculosis reactive CD4 T cells from intestinal biopsies of Crohn's disease patients. PLoS ONE. 2009; 4:e5641. [PubMed: 19479064]

Over K, Crandall PG, O'Bryan CA, Ricke SC. Current perspectives on Mycobacterium avium subsp. paratuberculosis, Johne's disease, and Crohn's disease: a review. Crit.Rev.Microbiol. 2011; 37:141–156. [PubMed: 21254832]

Park KT, Allen AJ, Bannantine JP, Seo KS, Hamilton MJ, Abdellrazeq GS, Rihan HM, Grimm A, Davis WC. Development of attenuated mutants of Mycobacterium avium subsp. paratuberculosis: evaluation of mutants as potential live vaccines for Johne's disease. Vaccine. 2011; 29:4709–4719. [PubMed: 21565243]

Ribeiro-Rodrigues R, Resende Co T, Rojas R, Toossi Z, Dietze R, Boom WH, Maciel E, Hirsch CS. A role for CD4+CD25+ T cells in regulation of the immune response during human tuverculosis. Clin.Exp.Immunol. 2006; 144:25–34. [PubMed: 16542361]

Rideout, BA.; Brown, ST.; Davis, WC.; Gay, JM.; Giannella, RA.; Hines, ME.; Hueston, WD.; Hutchinson, LJ. Diagnosis and control of Johne's disease. The National Academy Press; Washington,D.C.: 2003. p. 1-229.

Sakuraba A, Sato T, Kamada N, Kitazume M, Sugita A, Hibi T. Th1/Th17 immune response is induced by mesenteric lymph node dendritic cells in Crohn's disease. Gastroenterology. 2009; 137:1736–1745. [PubMed: 19632232]

Scriba TJ, Kalsdorf B, Abrahams D-A, Isaacs F, Hofmeister J, Black G, Hassan HY, Wilkinson RJ, Walzl G, Gelderbloem SJ, Mahomed H, Hussey GD, Hanekom WA. Distinct, specific IL-17 and IL-22 producing CD4+ T cell subsets contribute to the human anti-mycobacterial immune response. J.Immunol. 2008; 180:1962–1970. [PubMed: 18209095]

Sechi LA, Ruegl A, Ahmed N, Usai D, Paccagnini D, Felis GE, Zanetti S. Mycobacterium avium subspecies paratuberculosis infects and multiplies in enteric glial cells. World J.Gastroenterol. 2007; 13:5731–5735. [PubMed: 17963299]

Seo KS, Davis WC, Hamilton MJ, Park YH, Bohach GA. Development of monoclonal antibodies to detect bovine FOXP3 in PBMCs exposed to a staphylococcal superantigen. Vet.Immunol.Immunopathol. 2009; 128:30–36. [PubMed: 19054574]

Sharma PK, Saha PK, Singh A, Sharma SK, Ghosh B, Mitra DK. FoxP3+ regulatory T cells suppress effector T cell function at pathologic sites in miliary tuberculosis. Am.J.Respir.Crit.Care Med. 2009; 179:1061–1070. [PubMed: 19246720]

Sigurðardóttir ÓG, Bakke-McKellep AM, Djønne B, Evensen Ø. Mycobacterium avium subsp. paratuberculosis enters the small intestinal mucosa of goat kids in areas with and without Peyer's patches as demonstrated with the everted sleeve method. Comp.Immunol.Microbiol.Infect.Dis. 2005; 28:223–230. [PubMed: 15857661]

Sigurðardóttir ÓG, Valheim M, Press CM. Establishment of Mycobacterium avium subsp. paratuberculosis infection in the intestine of ruminants. Adv.Drug Delivery Rev. 2004; 56:819–834.

NIH-PA Author Manuscript

NIH-PA Author Manuscript

NIH-PA Author Manuscript

Singh AV, Singh SV, Makharia GK, Singh PK, Schal JS. Presence and characterization of Mycobacterium avium subspecies paratuberculosis from clinical and suspected cases of Crohn's disease and in healthy human population in India. Int.J.Infect.Dis. 2008; 12:190–197. [PubMed: 17913536]

Singh AV, Singh SV, Singh PK, Sohal JS, Singh MK. High prevalence of Mycobacterium avium subspecies paratuberculosis ('Indian bison type') in animal attendants suffering from gastrointestinal complaints who work with goat herds endemic for Johne's disease in India. Int.J.Infect.Dis. 2011; 10:e677–e683. [PubMed: 21703899]

Stabel JR, Palmer MV, Harris B, Plattner B, Hostetter J, Robbe-Austerman S. Pathogenesis of Mycobacterium avium subsp. paratuberculosis in neonatal calves after oral or intraperitoneal experimental infection. Vet.Microbiol. 2009; 136:306–313. [PubMed: 19135813]

Sweeney RW, Uzonna J, Whitlock RH, Habecker PL, Chilton P, Scott P. Tissue predilection sites and effect of dose on Mycobacterium avium subs. paratuberculosis organism recovery in a short-term bovine experimental oral infection model. Res.Vet.Sci. 2006; 80:253–259. [PubMed: 16165171]

Tewary P, Wang D, de la Rosa G, Li Y, Finn MW, Krensky AM, Clayberger C, Oppenheim JJ. Granulysin activates antigen-presenting cells through TLR4 and acts as an immune alarmin. Blood. 2010; 116:3465–3474. [PubMed: 20660289]

Torrado E, Cooper AM. IL-17 and TH17 cells in tuberculosis. Cytokine & Growth Factor Rev. 2010; 21:455–462. [PubMed: 21075039]

Tuci A, Tonon F, Castellani L, Sartini A, Roda G, Marocchi M, Caponi A, Munarini A, Rosati G, Ugolini G, Fuccio L, Scagliarini M, Bazzoli F, Belluzzi A. Fecal detection of Mycobacterium avium paratuberculosis using the IS900 DNA sequence in Crohn's disease and ulcerative colitis patients and healthy subjects. Dig.Dis.Sci. 2011; 10:2957–2962. [PubMed: 21484317]

Waters WR, Miller JM, Palmer MV, Stabel JR, Jones DE, Koistinen KA, Steadham EM, Hamilton MJ, Davis WC, Bannantine JP. Early induction of humoral and cellular immune responses during experimental Mycobacterium avium subsp. paratuberculosis infection of calves. Infect.Immun. 2003; 71:5130–5138. [PubMed: 12933856]

Wu CW, Livesey M, Schmoller SK, Manning EJ, Steinberg H, Davis WC, Hamilton MJ, Talaat AM. Invasion and persistence of Mycobacterium avium subsp. paratuberculosis during early stages of Johne's disease in calves. Infect.Immun. 2007; 75:2110–2119. [PubMed: 17296749]

Zeng G, Chen CY, Huang D, Yao S, Wang RC, Chen ZW. Membrane-bound IL-22 after de novo production in tuberculosos and anti-Mycobacterium tuberculosis effector function of IL-22+ CD4+ T cells. J.Immunol. 2011; 187:190–199. [PubMed: 21632708]

NIH-PA Author Manuscript

NIH-PA Author Manuscript

NIH-PA Author Manuscript

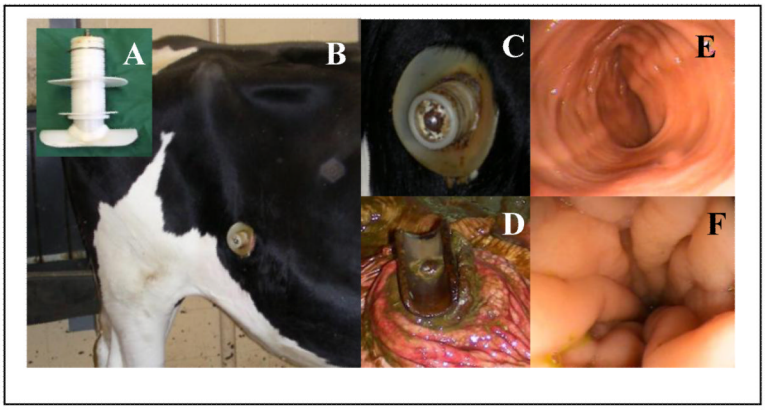


**Figure 1.**

Pictures showing the modified cannula used in the studies (A). Picture of cannula 8 months after surgery in an animal experimentally infected with *Map* (B). Close up picture showing the condition of the exterior of the cannula 8 months after surgery (C). Close up picture showing the condition of ileal mucosa 8 months following infection with *Map* (D). Endoscopic field taken before necropsy showing no inflammation in the ileal mucosa (E). Endoscopic field taken before necropsy of a naturally infected animal showing the characteristic swelling and corrugation of the ileal mucosa that occurs at the clinical stage of infection (F). Modified from (Allen et al., 2009; Allen et al., 2011).

NIH-PA Author Manuscript

NIH-PA Author Manuscript

NIH-PA Author Manuscript

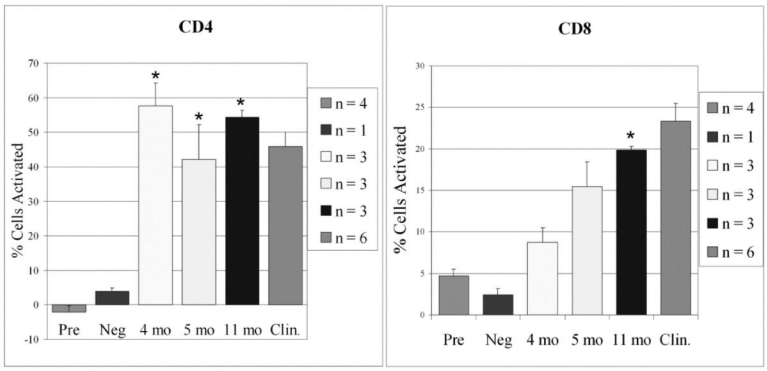


**Figure 2.**

Comparison of the expression of CD25 on CD4 and CD8 memory cells stimulated with soluble antigen extract from *Map* (SAg). Peripheral blood mononuclear cells were collected at the times indicated and stimulated with SAg for 6 days and then processed for flow cytometric analysis (Allen et al., 2009). Electronic gates were set to isolate CD4 and CD8 cells for analysis. The first bar shows pre-inoculation samples that were taken from all of the calves. The second bar shows the mean of the control negative calf sampled over 3 time points and bars 3-5 show the means of the inoculated calves at 4, 5 and 11 months PI. Bar 6 shows expression of CD25 on cells from clinical cows was similar to the expression on cells from experimentally inoculated calves. Asterisks indicate a statistically significance difference $P < .05$ compared to pre inoculation results. Results from clinical cows were not significantly different from results from calves 11 months PI. From (Allen et al., 2011).

NIH-PA Author Manuscript

NIH-PA Author Manuscript

NIH-PA Author Manuscript

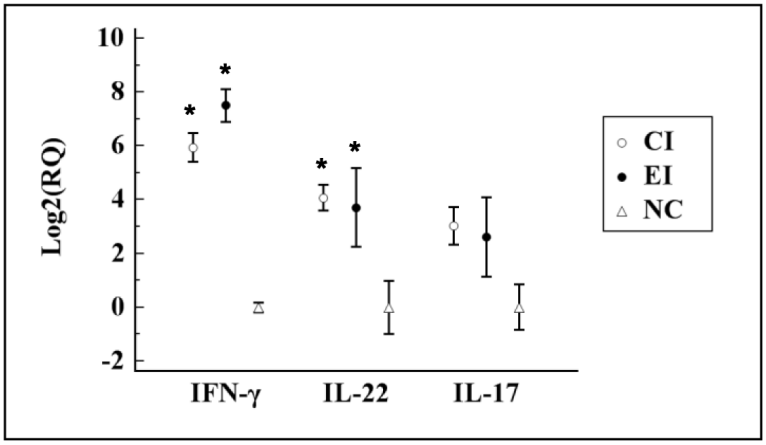


**Figure 3.**

Cytokine gene expression measured by qRT-PCR in lymphocytes from ileocecal lymph nodes from clinical naturally infected cows (CI, n = 3) and experimentally inoculated calves (EI, n = 2) compared to negative controls (NC, n = 3). Control negative values were set at 0. IFN-γ and IL-22 are statistically significant with a $P < .05$. RQ, relative quantification. From (Allen et al., 2011).

NIH-PA Author Manuscript

NIH-PA Author Manuscript

NIH-PA Author Manuscript

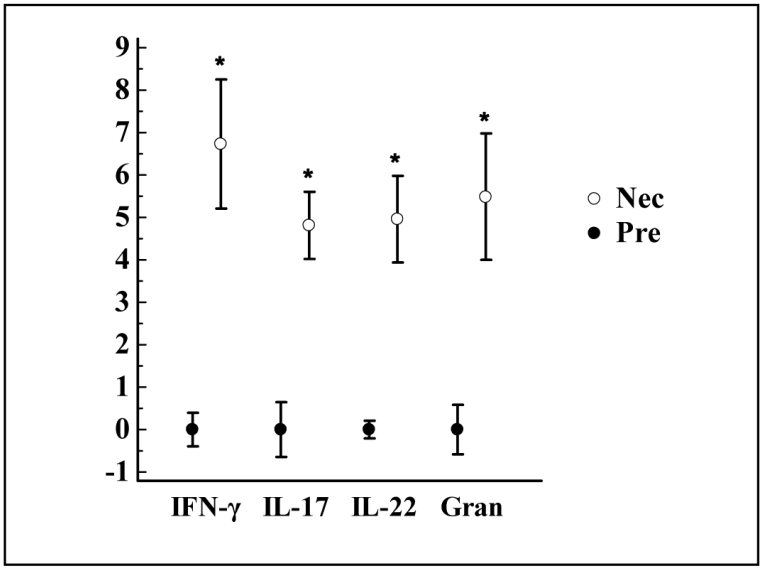


**Figure 4.**

Cytokine gene expression measured by qRT-PCR in PBMCs from control calves (n = 3) and calves experimentally infected with a relA deletion mutant (n = 4) following stimulation with live *Map*. PBMCs isolated at pre-infection and necropsy were stimulated with live *Map* for 3 days. The relative transcription was calculated using the value at pre-infection as the calibrator with two housekeeping genes ($\beta$-actin and GAPDH). Data are presented as the mean value of each group with error bar (SD). RQ, relative quantification; *, significant difference compared to the value at pre-infection ($P < 0.05$).

NIH-PA Author Manuscript

NIH-PA Author Manuscript

NIH-PA Author Manuscript

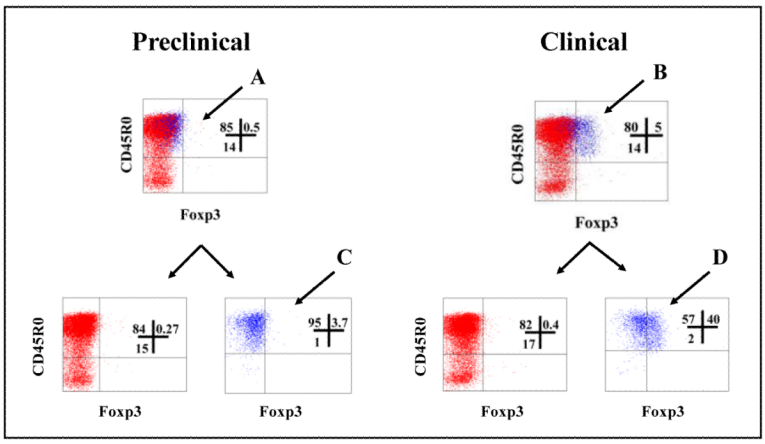


**Figure 5.**

Flow cytometric dot plot profiles comparing the expression of Foxp3 in CD4 T cells from a cow at the pre-clinical stage of infection with CD4 T cells from a cow at the clinical stage of infection. Peripheral blood mononuclear cells from the cows were stimulated with SAg from *Map* for 6 days. The cells were labeled, with mAbs specific for CD4 (ILA11A, IgG2a), memory T cells (CD45R0, IgG3) then fixed, permeabilized and labeled with a mAb specific for Foxp3 (FOX5A, IgG1) (Seo et al., 2009). Electronic gates were set using side light scatter vs forward light scatter to color code resting, unstimulated cells (red) and activated proliferating cells (blue) (Allen et al., 2009). An additional electronic gate was placed on CD4 T cells (side light scatter vs fluorescence) to isolate CD4 cells for analysis (not shown). As shown in the first profiles (A and B), including the electronic gates containing resting (red) and activated (blue) cells, a subset of activated memory CD4 T cells from the clinical cow expressed Foxp3. In contrast, very few activated cells from the preclinical cow expressed Foxp3. Further analysis of the cells present in the electronic gate only containing activated cells (profiles C and D) revealed a large proportion of the activated cells from the clinical cow expressed Foxp3, showing a potential correlation with disease progression with an increase in CD4 Foxp3 positive T cells.