

## Unusual presentation of more common disease/injury

## Isolated anaemia as a manifestation of Rh isoimmunisation

Juliana Roda,<sup>1</sup> Gabriela Mimoso,<sup>1</sup> Manuela Benedito,<sup>2</sup> Dolores Faria Pereira<sup>1</sup><sup>1</sup>Neonatal Intensive Care Unit, Maternidade Bissaya Barreto-CHC, Coimbra, Portugal;<sup>2</sup>Haematology Department, Hospital Pediátrico de Coimbra-CHC, Coimbra, Portugal

Correspondence to Dr Juliana Roda, juroda@hotmail.com

## Summary

Rh isoimmunisation leads to haemolytic anaemia and hyperbilirubinaemia in the first h of life. Isolated early onset neonatal anaemia has rarely been reported. The authors describe the case of a term infant, born to an 'A' negative, second gravida mother. On the second day of life, pallor was noticed. His haemoglobin (Hb) was 6.8 g/dl, he had reticulocytosis and a positive direct antiglobulin test. However, he did not have a high total serum bilirubin (TSB) (87.2  $\mu$ mol/l). He was transfused with red blood cells and kept under phototherapy for 3 days. Three weeks later, he received another transfusion for severe anaemia (Hb 6.5 g/dl). During this period, he was never jaundiced and the maximum level of TSB was 122  $\mu$ mol/l. On follow-up, his Hb stabilised and he had no further problems. This report highlights the possibility of early onset anaemia without jaundice as the sole manifestation of Rh isoimmunisation.

## BACKGROUND

Haemolysis after Rh isoimmunisation primarily causes anaemia in the intrauterine period but leads to jaundice and anaemia of variable intensity after birth.<sup>1</sup> This is the second article in the literature describing cases of Rh isoimmunisation presenting in the early newborn period primarily as anaemia without clinically significant jaundice.<sup>2</sup>

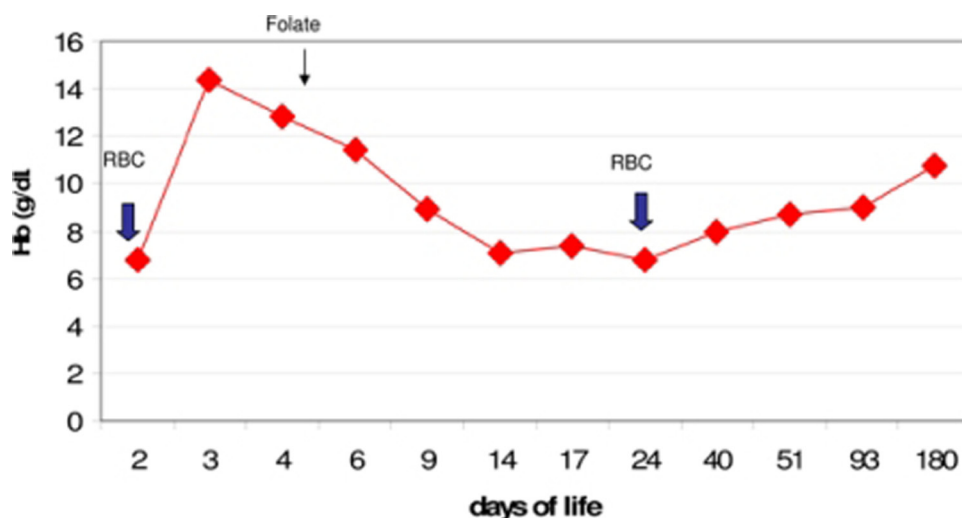
Routine anti-D prophylaxis after delivery and at 28 weeks of gestation has reduced the immunisation rate by 90%, transforming the haemolytic disease of the newborn in a rare disease.<sup>3 4</sup>

## CASE PRESENTATION

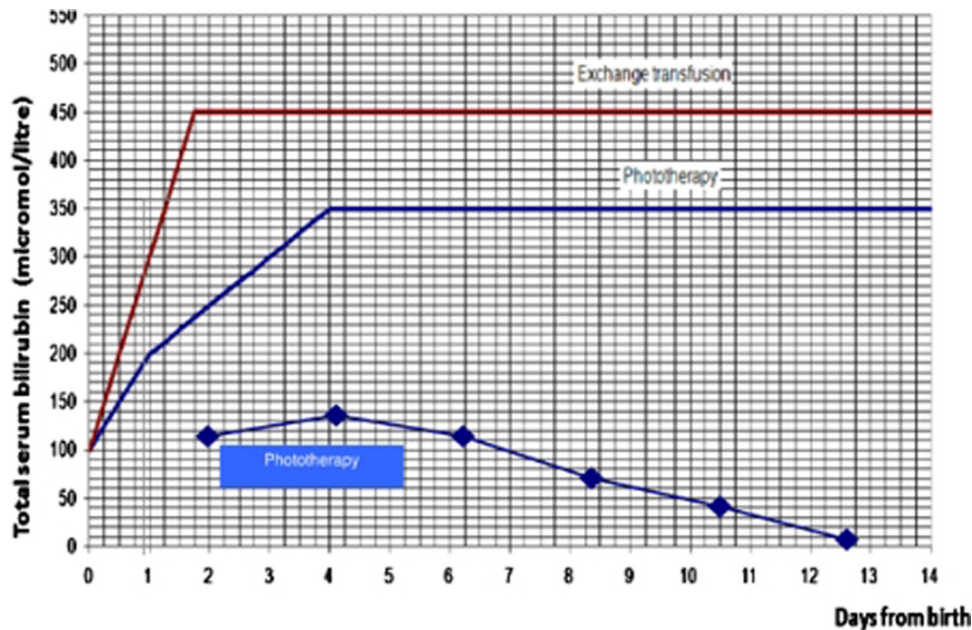
We present the case of a term infant, born to a 'B' positive father and an 'A' negative second gravida mother. The mother received anti-D immune prophylaxis after the first delivery, but did not receive it during this second gestation.

Her indirect antiglobulin tests in the second and third trimester were negative.

The baby was born well, by normal vaginal delivery, without oedema, pallor, jaundice or hepatosplenomegaly. His birth weight was 4040 g. In the first day of life, he seemed to be a healthy baby, feeding well and without fatigue. On day 2 of life, he was found to be pale and the mother's indirect antiglobulin test was positive. He had a severe macrocytic anaemia, with 6.8 g/dl of haemoglobin (Hb) and a mean globular volume of 123 fL. The peripheral blood smear showed anisopoikilocytosis and frequent erythroblasts. His reticulocyte count was 8.8% (normal value is 2–3%) and the lactic dehydrogenase level was elevated (5372 U/l; for a normal range of 500–920 U/l). However, total serum bilirubin (TSB) was 87.2  $\mu$ mol/l and the unconjugated fraction was 3  $\mu$ mol/l. The direct antiglobulin test was positive. The baby's blood group was 'A' positive.



**Figure 1** Progression of haemoglobin values after the first red blood cell (RBC) transfusion, haemolysis persisted requiring a second RBC transfusion.



**Figure 2** The blue line shows the bilirubin values, always under the recommended level to start phototherapy.<sup>7</sup>

Phenotyping of Rh antigens revealed absence of antigens C, E and Kell (K), confirming an anti-D alloimmunisation.

### TREATMENT

He was admitted in the Neonatal Intensive Care Unit for red blood cells (RBC) transfusion and he was started on prophylactic phototherapy for 3 days. On day 3, he had an unremarkable transfontanellar ultrasound and was started on oral folate three times a week. He was discharged home on day 9. During the hospital stay, he was never jaundiced and the maximum level of TSB was 122  $\mu\text{mol/l}$ .

### OUTCOME AND FOLLOW-UP

Two weeks later, in a follow-up evaluation, he presented with pallor, his Hb was 6.5 g/dl and there was no appreciable increase in TSB. He received another RBC transfusion and was discharged home. He was followed in the haematology clinic for 6 months and had no more signs of haemolysis. At this time folic acid supplements were stopped.

He is now 2 years old and has got a normal growth and mental development.

Figures 1 and 2 describe the progression of the values of Hb and bilirubin since birth and after discharge.

### DISCUSSION

With this case we emphasise that Rh isoimmunisation in neonates can be presented as isolated anaemia without significant hyperbilirubinaemia.

Rh isoimmunisation occurs when fetal RBCs from an Rh D positive fetus cross the placenta into the circulation of an Rh D negative mother.<sup>2</sup> Once sensitisation has taken place, considerably smaller doses of antigen can stimulate an increase in antibody titre. Initially, a rise in IgM antibody occurs, which is later replaced by IgG antibody; the latter readily crosses the placenta and causes haemolytic manifestations.<sup>1</sup>

The severity of the disease may range from only laboratory evidence of mild haemolysis (15% of cases) to severe anaemia with compensatory hyperplasia of erythropoietic tissue leading to massive enlargement of the liver and the spleen. When the compensatory capacity is exceeded, profound anaemia occurs and results in pallor, cardiac decompensation, massive anasarca and circulatory collapse.<sup>1</sup> This clinical picture is termed hydrops fetalis and occurs in 20 to 25% of Rh isoimmunisation cases.<sup>2</sup>

Jaundice may be absent at birth because of placental clearance of unconjugated bilirubin.<sup>1</sup> However, it is generally evident on the first day of life because the infant's bilirubin-conjugating and excretory systems are unable to cope with the load resulting from massive haemolysis. Therefore, unconjugated bilirubin accumulates postnatally and may rapidly reach high levels.<sup>1</sup> About 25 to 30% will require treatment with phototherapy or exchange transfusion.<sup>2</sup>

Studies have shown that severe inutero haemolysis owing to Rh isoimmunisation and postnatal RBC transfusions can lead to bone marrow suppression and may exaggerate anaemia.<sup>5</sup> The onset of this anaemia is late and is commonly seen after 2 weeks of age. Recent studies suggest that the anaemia is most likely caused by the persistence of anti-D antibodies and destruction of RBC.<sup>6</sup>

As shown in reported cases, this infant required a repeated blood transfusion. This could be owing to the effect of circulating maternal anti-D antibodies, known to persist up to 6 to 8 weeks.<sup>2</sup>

The clinical presentation of isolated anaemia in our report was early, severe and unassociated with jaundice. In the literature, we found the description of three cases with similar characteristics.<sup>2</sup> Louis D *et al* explained that this could be possible after a low-to-moderate grade haemolysis with the bilirubin production balanced by an enhanced hepatic capacity to conjugate and excrete, leaving behind anaemia as the predominant clinical manifestation.<sup>2</sup> Red cell breakdown produces unconjugated (or

'indirect') bilirubin, which is mostly bound to albumin. Unconjugated bilirubin is metabolised in the liver, by glucuronil-transferase enzyme, to produce conjugated (or 'direct') bilirubin, which then passes through the gut and is excreted in the stool. Bilirubin can be reabsorbed again from stools remaining in the gut.<sup>7</sup> We hypothesise that the absence of jaundice in this case may be related to an increased activation of the glucuronil-transferase enzyme allowing a fast conjugation of bilirubin.

Severe anaemia without hyperbilirubinaemia has been reported after anti-K isoimmunisation in which the anti-K antibodies cause bone marrow suppression.<sup>8</sup> In our report, the newborn was screened for C, E and K antibodies and was negative for all.

Intravenous immunoglobulin (IVIg) is a standard intervention for preventing and reducing the severity of haemolysis in isoimmunised infants.<sup>5</sup> However, in most studies, the neonates presented with significant jaundice in the early postnatal period. There have been no studies until this date, that have shown the beneficial role of IVIg in reducing haemolysis in infants presenting with severe anaemia without hyperbilirubinaemia.<sup>2</sup> In this case, IVIg was not administered and the outcome was favourable.

### Learning points

- ▶ Anaemia may be the only manifestation of Rh isoimmunisation.
- ▶ The absence of jaundice or hyperbilirubinaemia does not exclude haemolytic disease of the newborn.

**Competing interests** None.

**Patient consent** Obtained.

### REFERENCES

1. **Stoll B.** Blood Disorders. In: Kliegman, Behrman, Jenson, Stanton, eds. *Nelson Textbook of Pediatrics*. 18th Edition. Philadelphia, PA: Saunders Elsevier 2007:766–72.
2. **Louis D,** Oberoi S, Sundaram V, *et al.* Isolated early onset anemia after rh isoimmunization: a unique presentation in 3 neonates. *J Pediatr Hematol Oncol* 2010;**32**:e230–2.
3. **Bowman J.** Rh-immunoglobulin: Rh prophylaxis. *Best Pract Res Clin Haematol* 2006;**19**:27–34.
4. **Kumpel BM,** Elson CJ. Mechanism of anti-D-mediated immune suppression—a paradox awaiting resolution? *Trends Immunol* 2001;**22**:26–31.
5. **Mentzer WC,** Glader BE. Erythrocyte disorders in infancy. In: Taeusch WH, Ballard RA, Gleason CA, eds. *Avery's Diseases of the Newborn*. Eight Edition. Philadelphia, PA: Elsevier, Mosby, Inc 2005:1188–91.
6. **Dallacasa P,** Ancora G, Miniero R, *et al.* Erythropoietin course in newborns with Rh hemolytic disease transfused and not transfused in utero. *Pediatr Res* 1996;**40**:357–60.
7. National Collaborating Centre for Women's and Children's Health. Commissioned by the National Institute for Health and Clinical Excellence (NICE). *Neonatal jaundice* 2010:33–52.
8. **Vaughan JI,** Manning M, Warwick RM, *et al.* Inhibition of erythroid progenitor cells by anti-Kell antibodies in fetal alloimmune anemia. *N Engl J Med* 1998;**338**:798–803.

This pdf has been created automatically from the final edited text and images.

Copyright 2012 BMJ Publishing Group. All rights reserved. For permission to reuse any of this content visit <http://group.bmj.com/group/rights-licensing/permissions>.  
BMJ Case Report Fellows may re-use this article for personal use and teaching without any further permission.

Please cite this article as follows (you will need to access the article online to obtain the date of publication).

Roda J, Mimoso G, Benedito M, Pereira DF. Isolated anaemia as a manifestation of Rh isoimmunisation. *BMJ Case Reports* 2012; 10.1136/bcr.11.2011.5101, Published XXX

Become a Fellow of BMJ Case Reports today and you can:

- ▶ Submit as many cases as you like
- ▶ Enjoy fast sympathetic peer review and rapid publication of accepted articles
- ▶ Access all the published articles
- ▶ Re-use any of the published material for personal use and teaching without further permission

For information on Institutional Fellowships contact [consortiasales@bmjgroup.com](mailto:consortiasales@bmjgroup.com)

Visit [casereports.bmj.com](http://casereports.bmj.com) for more articles like this and to become a Fellow