BMJ Case Reports

Other full case

Three cases of primary small vessel vasculitis of the skeletal muscle–an own entity

Nadja Benz,[1] Thomas Daikeler,[2] Stephan Frank,[3] Matthias Mehling,[4] Alan Tyndall,[2] Marten Trendelenburg[1]

[1]Clinic for Internal Medicine, University Hospital, Basel, Switzerland;
[2]Clinic for Rheumatology, University Hospital, Basel, Switzerland;
[3]Division of Neuropathology, Institute of Pathology, University Hospital, Basel, Switzerland;
[4]Medical Outpatient Clinic and Neurology Department, University Hospital, Basel, Switzerland

Correspondence to Dr Nadja Benz, benzn@uhbs.ch

Summary

Whereas systemic vasculitis is the most common form of vasculitis, vasculitis restricted to a single organ system is rare. Primary vasculitis restricted to striated skeletal muscle has been described in few case reports for polyarteritis nodosa and leucocytoclastic vasculitis, but not for small vessel vasculitis, type microscopic polyangiitis. The authors describe three patients with primary small vessel vasculitis of the skeletal muscle without evidence of other major organ involvement. All three patients presented with myalgias and highly elevated acute phase reactants while muscle weakness and elevated creatine kinase levels were not consistently present. Diagnoses were established by muscle biopsy and extensive search for potential causes of secondary vasculitis. Complete remission could be accomplished by steroids alone in only one case, while additional immunosuppressants were needed in the other two cases. Primary small vessel vasculitis of the skeletal muscle should be considered in patients presenting with myalgia and signs of systemic inflammation in the absence of other organ manifestations. Once diagnosed, aggressive systemic immunosuppression is appropriate.

BACKGROUND

Systemic vasculitis by definition affects multiple organ systems. It is the most common form of vasculitis and usually requires prolonged, aggressive immunosuppressive therapy. In contrast, vasculitis limited to a single organ system is rare. It may occur in a focal or diffuse pattern. While the first may be cured by simple excision, the latter has a less favourable prognosis usually requiring systemic therapy.[1] The gastrointestinal tract, urogenital tract, breast and aorta have all been described to be affected.[1] Primary vasculitis affecting solely striated skeletal muscle, most often in a focal pattern, has been described for polyarteritis nodosa,[2–15] but to our knowledge not for primary small vessel vasculitis, type microscopic polyangiitis. Below, we describe three patients with primary small vessel vasculitis of skeletal muscle without evidence of other major organ involvement.

CASE PRESENTATION

Case 1 An 80-year-old previously healthy woman was referred to our hospital by her primary care physician for evaluation of new-onset myalgia, proximal tetraparesis, fatigue and a persistent elevation of acute phase reactants despite antibiotic treatment prescribed for suspected pulmonary infection. Medical history included hypertension and nephrectomy for a renal tumour 20 years ago (no relapse). Laboratory findings revealed elevated C-reactive protein (289 mg/l) and eightfold elevated creatine kinase levels. Extensive investigations including viral serology (including HIV, parvovirus, hepatitis B and C), PCR for hepatitis C, cytomegalovirus and Epstein-Barr virus, repeated cultures of blood and urine as well as CT scans of chest and abdomen showed no evidence of infection. An MRI of the limbs for suspected polymyositis revealed diffuse oedematous changes affecting nearly the entire skeletal muscle system. Antinuclear antibody (ANA), anti-neutrophil cytoplasmic antibody (ANCA) (including proteinase 3 (PR3)- and myeloperoxidase-specific ANCA (MPO-ANCA)), myositis antibodies (anti-PM- Scl, anti-Mi-2, anti-Jo-1, anti-PL7, anti-PL12, anti-signal recognition particle (SRP), anti-Ku) and cryoglobulins were negative. Muscle biopsy revealed ischemic infarct-like necrotic changes due to small vessel vasculitis, compatible with microscopic polyangiitis (figure 1). Additional immunohistochemical studies showed a sarcolemmal expression of complement C5b-9, a finding usually restricted to anti-SRP myopathies.[16] Within the first days of hospitalisation, the patient also developed a fluctuating livedo-like rash on both arms. However, putative skin involvement could not be confirmed by skin biopsy, and no other organs were found to be affected.

CT and positron emission tomography-CT scans plus a gynaecological examination excluded malignant disease. Treatment with prednisone (10 mg per kg body weight) was initiated, and creatine kinase levels normalised within days. In addition, skin changes disappeared and the patient reported progressive clinical improvement. However, whereas inflammatory parameters declined, C-reactive protein remained elevated at 70–100 mg/l suggesting ongoing systemic inflammation. Therefore, additional treatment with cyclophosphamide 500 mg/m^2 monthly was initiated with normalisation of inflammatory markers after 5 pulses. With additional intense rehabilitation, the patient regained strength and was able to return home with a

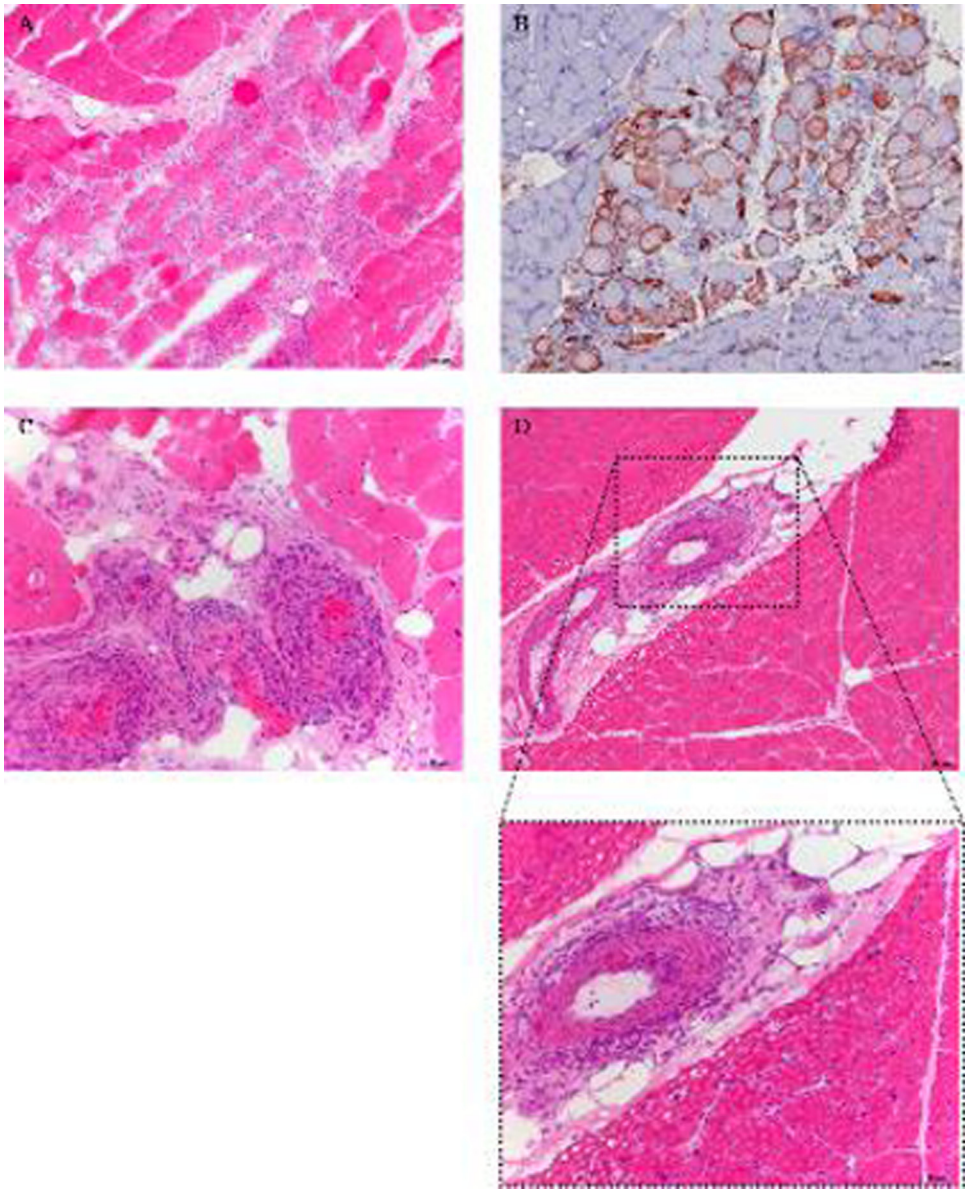

Figure 1 (A-C) (Patient 1): HE-stained sections of the deltoid muscle reveal circumscribed, ischemic infarct-like necrotic changes (A). In other areas of the same biopsy fibrinoid necrosis of vessel wall structures confirmed vasculitis (C). Anti-MAC staining showed sarcolemma-associated immunoreactivity for anti-MAC within necrotising muscle fibers in the infarct-like areas (B). D (Patient 3): very focal fibrinoid necrotic changes (arrows) prompted the diagnosis of vasculitis (HE staining).

walking aid. She has been well since under a maintenance treatment with low-dose cortisone and methotrexate (10 mg sc weekly).

Case 2 A 79-year-old female patient was admitted to the hospital for new-onset myalgia in her proximal lower and upper extremities, fatigue and general weakness. Creatine kinase (4000 U/l) and C-reactive protein (380 mg/ml) levels were highly elevated. An MRI scan showed lipomatous involution and atrophy of the muscles suggesting polymyositis. However, muscle biopsy revealed a necrotising small vessel vasculitis, compatible with microscopic polyangiitis. ANA and cryoglobulins were negative, while ANCAs were weakly positive by immunofluorescence (1:40, norm <1:20), but negative in ELISA for myeloperoxidase and PR3. No other organs were found to be involved, and there was no evidence of malignancy. Response to intravenous application of methylprednisolone 500 mg per day was insufficient, thus three cycles of cyclophosphamide (1000 mg intravenously) were administered at monthly intervals. Clinical symptoms resolved, and creatine kinase as well as inflammatory markers normalised. Prednisone was tapered and a maintenance therapy with azathioprine (150 mg daily) was started and continued for 12 months.

Four years later, a first relapse with fever and elevated acute phase proteins occurred. This time, complete remission was achieved with high-dose steroids. Under a maintenance dose of prednisone another relapse occurred 1 year later presenting with dyspnoea and elevated acute phase reactants, again requiring high-dose systemic steroids and four additional cycles of cyclophosphamide (1000 mg intravenous monthly). The patient currently remains in remission for her fourth year.

BMJ Case Reports 2011; doi:10.1136/bcr.08.2011.4631

Case 3 A 64-year-old male patient was admitted for fever and new-onset, progressive myalgias of the lower limbs. C-reactive protein was elevated at 330 mg/l, while creatine kinase levels were below normal range. There was no evidence of infection, and repeated cultures of blood and urine were negative. A MRI scan demonstrated diffuse inflammatory changes of the pelvic floor and both thighs. Myositis specific autoantibodies were negative. Biopsy of the left quadriceps muscle revealed a focal fibrinoid necrotising vasculitis, compatible with microscopic polyangiitis (figure 1). There was no evidence of other organ systems being involved or of underlying malignancy, although an extensive assessment for malignancy was not conducted at the time of diagnosis. ANA, ANCA, cryoglobulins, complement C3 and C4 and serology for hepatitis B and C were all negative. Under treatment with systemic steroids, C-reactive protein values declined three fold within 1 day and symptoms resolved. While tapering steroids, a maintenance treatment with azathioprine (100 mg daily) was started. Because of the side effects (symptomatic anaemia), maintenance treatment was changed from azathioprine to low-dose prednisone (5 mg daily) 1 year later. Concerning vasculitis, the patient has remained symptom-free during 2.5 years of observation and no signs of malignancy have appeared.

DISCUSSION

We describe three patients with primary small vessel vasculitis of the skeletal muscle without evidence of multisystem disease. Clinically, all three patients presented with myalgias accompanied by highly elevated C-reactive protein levels while muscle weakness and elevated creatine kinase levels were not consistently present. Diagnoses were established by muscle biopsy and extensive search for potential causes of secondary vasculitis in all cases. No underlying diseases or further organ affection were found during the observation periods ranging from 7 months (case 1) to 7 years (case 2). However, both may present at a later date,[1] particularly in those patients with highly elevated acute phase reactants. Thus, a definite diagnosis of single organ vasculitis can often only be made after years of observation. In this respect, the diagnosis of single organ vasculitis in case 1 cannot be considered as being definite at the moment, although this patient had an extensive investigation.

Primary single organ vasculitis of the skeletal muscle has been described for patients with polyarteritis nodosa[2–15] and leucocytoclastic vasculitis[2] with some also describing small vessel vasculitis.[11 12] In our patients, biopsies of skeletal muscle clearly showed small vessel vasculitis in all. Furthermore, ANCA-associated vasculitis may clinically present similarly[17] but systemic manifestations are usually present. None of our patients had positive MPO-/or PR3-ANCA or evidence of further organ involvement.

Previous case reports and small case series of patients with primary single organ vasculitis of the skeletal muscle, type polyarteritis nodosa, showed a good response to systemic steroids.[2 5 9 11] However, a relapse rate of up to 90% was observed when the dose was tapered, requiring additional immunosuppressive agents in a significant subset of patients.[2 15] In our patient series, complete remission could be accomplished with steroids alone in only one case (case 3), requiring additional immunosuppressive therapy in the other two patients. Patient 2 experienced two relapses each time requiring intensive immunosuppressive treatment. Thus, according to our observations primary small vessel vasculitis of the skeletal muscle has to be considered as a serious entity requiring intensive treatment and long-term monitoring.

Learning points

- In conclusion, primary small vessel vasculitis of the skeletal muscle should be considered in patients presenting with myalgia and signs of systemic inflammation in the absence of other organ manifestations. Once diagnosed, intensive systemic immunosuppression is appropriate.

Competing interests None.

Patient consent Obtained.

REFERENCES

1. **Hernández-Rodríguez J,** Molloy ES, Hoffman GS. Single-organ vasculitis. *Curr Opin Rheumatol* 2008;**20**:40–6.
2. **Khellaf M,** Hamidou M, Pagnoux C, *et al*. Vasculitis restricted to the lower limbs: a clinical and histopathological study. *Ann Rheum Dis* 2007;**66**:554–6.
3. **Ferreiro JE,** Saldana MJ, Azevedo SJ. Polyarteritis manifesting as calf myositis and fever. *Am J Med* 1986;**80**:312–5.
4. **Gallien S,** Mahr A, Réty F, *et al*. Magnetic resonance imaging of skeletal muscle involvement in limb restricted vasculitis. *Ann Rheum Dis* 2002;**61**:1107–9.
5. **García F,** Pedrol E, Casademont J, *et al*. Polyarteritis nodosa confined to calf muscles. *J Rheumatol* 1992;**19**:303–5.
6. **Garcia-Porrua C,** Mate A, Duran-Mariño JL, *et al*. Localized vasculitis in the calf mimicking deep venous thrombosis. *Rheumatology (Oxford)* 2002;**41**:944–5.
7. **Gardner GC,** Lawrence MK. Polyarteritis nodosa confined to calf muscles. *J Rheumatol* 1993;**20**:908–9.
8. **Golding DN**. Polyarteritis presenting with leg pains. *Br Med J* 1970;**1**:277–8.
9. **Hall C,** Mongey AB. Unusual presentation of polyarteritis nodosa. *J Rheumatol* 2001;**28**:871–3.
10. **Hatakeyama M,** Torigoe K, Nara H, *et al*. Muscular polyarteritis nodosa as a cause of fever of undetermined origin: a case report and review of the literature. *Rheumatol Int* 2005;**25**:394–7.
11. **Reading PJ,** Hudgson P, Johnson MA, *et al*. A sartorial challenge. *Lancet* 1999;**354**:996.
12. **Nakamura T,** Tomoda K, Yamamura Y, *et al*. Polyarteritis nodosa limited to calf muscles: a case report and review of the literature. *Clin Rheumatol* 2003;**22**:149–53.
13. **Lupoli S,** Gargiulo A, Rossi R, *et al*. Myositis as a presenting feature of polyarteritis nodosa. *Clin Exp Rheumatol* 2004;**22**:507–8.
14. **Prayson RA**. Skeletal muscle vasculitis exclusive of inflammatory myopathic conditions: a clinicopathologic study of 40 patients. *Hum Pathol* 2002;**33**:989–95.
15. **Balbir-Gurman A,** Nahir AM, Braun-Moscovici Y. Intravenous immunoglobulins in polyarteritis nodosa restricted to the limbs: case reports and review of the literature. *Clin Exp Rheumatol* 2007;**25**(1 Suppl 44):S28–30.
16. **Louboutin JP,** Navenot JM, Rouger K, *et al*. S-protein is expressed in necrotic fibers in Duchenne muscular dystrophy and polymyositis. *Muscle Nerve* 2003;**27**:575–81.
17. **Kim MY,** Bae SY, Lee M, *et al*. A case of ANCA-associated vasculitis presenting with calf claudication. *Rheumatol Int* 2010 doi:10.1007/s00296-010-1469-3.

This pdf has been created automatically from the final edited text and images.

Copyright 2011 BMJ Publishing Group. All rights reserved. For permission to reuse any of this content visit
http://group.bmj.com/group/rights-licensing/permissions.
BMJ Case Report Fellows may re-use this article for personal use and teaching without any further permission.

Please cite this article as follows (you will need to access the article online to obtain the date of publication).

Benz N, Daikeler T, Frank S, Mehling M, Tyndall A, Trendelenburg M. Three cases of primary small vessel vasculitis of the skeletal muscle–an own entity. *BMJ Case Reports* 2011;10.1136/bcr.08.2011.4631, date of publication

Become a Fellow of BMJ Case Reports today and you can:
- Submit as many cases as you like
- Enjoy fast sympathetic peer review and rapid publication of accepted articles
- Access all the published articles
- Re-use any of the published material for personal use and teaching without further permission

For information on Institutional Fellowships contact consortiasales@bmjgroup.com

Visit casereports.bmj.com for more articles like this and to become a Fellow