The Challenges of Diagnosing Primary Ciliary Dyskinesia

Margaret W. Leigh[1], Christopher O'Callaghan[2], and Michael R. Knowles[3]

[1]Department of Pediatrics, University of North Carolina, Chapel Hill, North Carolina; [2]Department of Paediatrics, University of Leicester, Leicester, United Kingdom; and [3]Department of Medicine, University of North Carolina, Chapel Hill, North Carolina

Primary ciliary dyskinesia (PCD) is a rare genetic disorder of ciliary structure and function. The diagnosis can be challenging, particularly when using nongenetic assays. The "gold standard" diagnostic test is ultrastructural analysis of respiratory cilia obtained by nasal scrape or brush biopsy. A few specialized centers use high-speed videomicroscopy to examine ciliary beat. Certain beat patterns correlate with ultrastructural defects, and, in some cases, subtle alterations in beat pattern can be seen when ultrastructure is normal. Recent studies have shown that nasal nitric oxide (NO) is very low in patients with PCD compared with healthy control subjects; therefore, this assay may be a useful screening or adjunctive test for PCD. Because acute respiratory illnesses may yield alterations in ciliary ultrastructure, ciliary beat, and nasal NO values, these tests should be performed during a stable baseline period. Identification of an array of PCD genes has provided the opportunity for making a definitive genetic diagnosis for PCD in some cases. All of these approaches have a role in diagnosing PCD. For example, PCD has been confirmed by identifying disease-causing mutations in a heavy dynein chain gene in individuals with normal ciliary ultrastructure but subtle defects in ciliary beat and low nasal NO. Priorities to improve nongenetic diagnostic capability include standardization of nasal NO as a screening test and the development of specialized centers using uniform approaches for the analysis of ciliary ultrastructure and ciliary beat pattern. Another chapter in this issue (*see* Zariwala and colleagues, pp. 430) addresses the progress toward improved capabilities for definitive genetic testing.

Keywords: primary ciliary dyskinesia; nitric oxide; ciliary ultrastructure; ciliary beat pattern

Primary ciliary dyskinesia (PCD) is a rare, inherited, usually autosomal recessive disorder with impaired ciliary function leading to unexplained neonatal respiratory distress, recurrent otitis media, chronic nasal drainage and sinusitis, chronic bronchitis leading to bronchiectasis, and, in approximately 50% of cases, situs inversus totalis or other laterality defect. Clinically available genetic testing identifies only a subset of individuals with PCD. In most cases, the diagnosis of PCD requires a compatible clinical phenotype and a confirmatory laboratory test such as electron microscopy (EM) to define ciliary ultrastructural defects or high-speed video microscopy to identify abnormal ciliary function (1, 2). Because these tests are not readily available or standardized, the diagnosis is often delayed, missed, or made incorrectly. Nasal nitric oxide (NO) is extremely low (10–15% of normal) in patients with PCD, and nasal NO measurement is evolving as a useful screening test or adjunctive diagnostic test for PCD (1, 2). Because the respiratory ciliated epithelium is exposed continuously to the external environment, which may include pathogens, pollutants, and other irritants, it is important to validate that abnormalities in ciliary structure or function are "primary" (genetic), and not "secondary," nonspecific effects.

This session, "The Challenges of Diagnosing PCD," focused on nongenetic approaches for diagnosis. The session began with a presentation by Dr. Michael Knowles from the University of North Carolina, who reviewed the present use of ciliary ultrastructural analysis to accurately diagnose PCD and discussed limitations in using this approach as the "gold standard" diagnostic test. Dr. Christopher O'Callaghan from University of Leicester reviewed advances in the assessment of ciliary motility using high-speed videomicroscopy to assess alterations in ciliary beat pattern and demonstrated that specific alterations in ciliary motility correlated with distinct ultrastructural defects. Assessment of ciliary beat pattern holds promise as a diagnostic test; however, this approach requires specialized expertise and equipment that is limited to a few sites in the world. Finally, Dr. Margaret Leigh from the University of North Carolina at Chapel Hill reviewed the usefulness of nasal NO as a screening or adjunctive test for diagnosing PCD. A subsequent break-out session addressed optimizing the diagnosis of PCD through standardization of these diagnostic tests.

ANALYSIS OF CILIARY ULTRASTRUCTURE

The ciliary axoneme has a 9+2 configuration (i.e., nine peripheral microtubular doublets surrounding a central pair of microtubules) (Figure 1). Outer dynein arms (ODAs) and inner dynein arms (IDAs) are attached to each of the peripheral doublets at distinct intervals along the length of the cilium. The dynein arms are composed of multimers of dynein chains (heavy, intermediate, and light chains) and contain the ATPase to provide energy for ciliary motility. The central pair is important for directing the direction of ciliary beat because the beat is perpendicular to the plane of the central pair. Identification of ultrastructural defects by EM has traditionally been the gold standard test for PCD. The most common EM defects are missing (or shortened) ODAs or IDAs; less common EM defects are abnormalities of radial spokes, transposition defects, and microtubular disorganization. There are multiple factors that limit the use of ciliary EMs as a diagnostic test in PCD, including (*1*) ciliated airway cells may be affected by local inflammation or infection, which cause "secondary" changes; (*2*) optimal fixation and processing of the ciliated cells is critical; (*3*) processing these small samples requires multiple specialized technical steps, including obtaining ultrathin sections and examination by transmission EM; (*4*) the evaluation requires an adequate (>20) number of interpretable images; and (*5*) interpretation requires recognition of normal variability and nonspecific changes. For example, even in healthy individuals, the ODAs may be missing in approximately 10% of the peripheral doublets, and the IDAs may be missing in more than half of the doublets.

A 20-year experience for using EM (>1,400 samples) to support the diagnosis of PCD showed less success in analyzing samples from children versus adults (60% of the samples from children were adequate versus 87% from adults) (3). The

(*Received in original form March 17, 2011; accepted in final form June 16, 2011*)

Supported by National Institutes of Health grants U54 HL096458 R01HL071798 and by the Primary Ciliary Dyskinesia Foundation.

Correspondence and requests for reprints should be addressed to Margaret W. Leigh, M.D., Department of Pediatrics, University of North Carolina, 5131 Bioinformatics Bldg, Chapel Hill, NC 27516. E-mail: mleigh@med.unc.edu

Proc Am Thorac Soc Vol 8. pp 434–437, 2011
DOI: 10.1513/pats.201103-028SD
Internet address: www.atsjournals.org

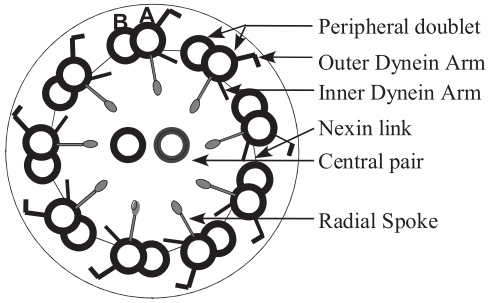

Figure 1. Diagrammatic representation of a normal cilium in cross-section. The nine outer doublet microtubules and the central pair of microtubules are interconnected by radial spokes and nexin links. Outer and inner dynein arms are attached to the A subunit of the peripheral doublets.

ODA analysis was most reliable, but there were many interpretive problems for the IDA (3). Indeed, a recent publication showed that 5 of 21 patients who had IDA defects on their initial sample were found to have normal IDAs (and normal cilia function) when retested (4). The IDAs are difficult to see because of poor contrast on EMs, and IDAs may appear (falsely) to be missing due to nonspecific biological or technical artifacts. The use of ciliary EMs as a diagnostic test for PCD was recently evaluated by the Genetic Disorders of Mucociliary Clearance Consortium. Of 394 nasal biopsies that gave adequate samples, 155 patients had hallmark ciliary EM defects, whereas 43 patients had indeterminate results (5). Thus, there are limitations to obtaining samples that are adequate for interpretation even in a Consortium with standardized operating procedures. Of more concern, the Consortium noted inaccuracy in EM study results in patients referred to the Consortium with a prior diagnosis of PCD based on EM studies. Specifically, repeat studies by the Consortium's standardized approach found that 25% of the 153 reportedly abnormal EM studies had normal ciliary ultrastructure (5).

For many years, PCD investigators have proposed that some individuals with classic clinical features of PCD but with normal ciliary ultrastructure may have a defect that impairs ciliary function without an apparent ultrastructural defect. This concept has been confirmed in a subset of PCD cases that have disease-causing mutations in an ODA heavy chain (DNAH11) but normal ciliary ultrastructure. These individuals had low nasal NO and a subtle alteration in ciliary motility. A recent evaluation of patients with a strong clinical phenotype for PCD and a low nasal NO but normal ciliary EMs showed that more than 20% of these patients have loss-of-function mutations in an ODA heavy chain (*DNAH11*) (6). Thus, PCD cannot be confirmed in such patients by ciliary EM studies because the EMs are normal.

In summary, ciliary EM studies have served as a gold standard diagnostic test for a subset of patients with PCD for many years; however, those studies must be performed in a specialized center with high-quality technical and interpretive expertise. As demonstrated by recent genetic studies, normal ciliary ultrastructure does not rule out PCD. Therefore, additional testing, including ciliary beat analysis, nasal NO testing, and genetic testing may be needed in some cases for comprehensive diagnostic testing for PCD.

ANALYSIS OF CILIARY FUNCTION

Historically, assessment of ciliary beat frequency by light microscopy was used as a screening test for PCD. Specifically, a ciliary beat frequency of less than 11 Hz was used as a cut-off value to decide which samples should be processed for EM, which is regarded as the gold standard diagnostic test for PCD (7). Recent research has shown that use of such a cut-off results in a number of false negatives and that analysis of ciliary beat pattern using high-speed video imaging is more informative and should be adopted as a diagnostic test (8). Ciliated strips of epithelium obtained from the nose by simple brushing or scraping (8, 9) can be observed within the next few hours under a ×100 oil immersion lens. Biopsy samples should be obtained during a clinically stable baseline period because ciliary dyskinesia is much more common in samples if the patient has had an upper respiratory tract infection within the previous month. Occasionally, repeated biopsies are required because the ciliated epithelium obtained can have a huge amount of secondary damage, making it very difficult to interpret findings (10). Biopsy samples may be cultured to allow redifferentiation to a ciliated phenotype after a few weeks (11). This culture approach may decrease the amount of secondary damage in the initial sample and aid in the identification of unusual phenotypes of PCD (12); however, only highly specialized centers have the capabilities to perform this type of cell culture. Repeat testing of positive cases of PCD is also frequently performed to confirm the diagnosis, especially in patients in whom an inner arm defect or radial spoke defect is suspected. Repeat testing in some of these patients has been unable to confirm the original diagnosis (4).

To evaluate beat pattern, cilia can be observed, in a simple slide and cover slip chamber, in three different planes: (*1*) from the side, allowing the full sweep of the cilia to be seen; (*2*) from above; and (*3*) beating directly toward the observer (13). High-speed video imaging has shown that respiratory cilia beat with a simple backward and forward motion (13) without a sideways recovery sweep. Its use has also allowed the development of reference ranges and scoring systems to be developed to assess the degree of dyskinesia and the percentage of edges that have cilia beating dyskinetically (8, 14, 15).

Primary ciliary dyskinesia is caused by a number of different ultrastructural defects. High-speed imaging has revealed that specific defects seen on EM have a characteristic abnormality of beat pattern (14). In an ODA defect or in a combined ODA and IDA defect, the majority of the cilia are immotile, and the cilia that do move only flicker. Cilia with an isolated IDA defect or a radial spoke defect, where IDAs are also absent, appear stiff and have reduced beat amplitude. In ciliary transposition defects, a circular beat pattern, which can only be appreciated by observing cilia from above, is seen throughout the sample. This study also found that, although ciliary beat frequency is very low in patients with an ODA or combined ODA and IDA arm defect, some patients with an IDA defect and transposition defect have a beat frequency above the suggested cut-off value of 11 Hz (7).

A subsequent study confirmed the benefit of high-speed video analysis of ciliary beat pattern as one of the diagnostic tests for primary ciliary dyskinesia (8). A total of 371 patients referred for diagnostic testing were reviewed, and a diagnosis of PCD was confirmed in 70 patients by EM. Ciliary beat pattern analysis was found to be more sensitive and specific and to have a greater positive and negative predictive factor than the previously recommended beat frequency cut-off value of 11 Hz (8). If ciliary beat frequency alone was used to screen which biopsies should be examined by EM, then 12.9% of patients with PCD would have their diagnosis missed, compared with 2.9% when beat pattern analysis was used. The study confirmed that ciliary transposition defects and defects with abnormalities of the central microtubular pairs, where cilia had a circular beat pattern (12, 14), were more likely to have a high ciliary beat

frequency and to be missed if only ciliary beat frequency was used in the evaluation. Although EM is often thought of as the gold standard test for PCD, a phenotype with genetic basis (DNAH11) exists in some patients where there is no ultrastructural defect (6). This phenotype may be recognized using beat pattern analysis and is usually associated with a very high beat frequency.

In summary, the use of ciliary beat frequency alone to screen which patient samples should undergo EM results in the diagnosis of PCD being missed in a significant number of patients. Analysis of ciliary beat pattern is a more sensitive and specific test for PCD, with higher positive and negative predictive values.

NASAL NO

NO is a small, diffusible gas molecule that mediates multiple functions throughout the body. Within the nose and respiratory tract, postulated functions for NO include regulation of ciliary motility (16, 17) and antimicrobial activity (18). A family of NO synthase (NOS) enzymes catalyzes the formation of NO in the presence of appropriate substrates (L-arginine and oxygen) and cofactors, including tetrahydrobiopterin. Three mammalian NOS isoforms have been identified: nNOS (neuronal NOS or NOS I), iNOS (inducible NOS or NOS II), and eNOS (endothelial NOS or NOS III). iNOS and eNOS have been localized in nasal epithelium (19, 20). The specific roles and regulation of these enzymes in the nose and paranasal sinuses have not been defined. Immunolocalization studies have shown that eNOS is localized close to the base of cilia (20) and hence is thought to play a role in regulating ciliary beat. Expression of iNOS is increased in allergic rhinitis, suggesting that this enzyme may play a role in the inflammatory processes (19).

Since the first report that children with Kartagener syndrome (situs inversus, sinusitis, and bronchiectasis) produced very little nasal NO (21), several studies have demonstrated that nasal NO during palate closure is extremely low (10–20% of normal) in patients with PCD, suggesting that the nasal NO test may be a useful screening test for PCD (2, 22–24). Because low nasal NO levels have been reported in a limited number of other disorders with overlapping clinical features (e.g., cystic fibrosis [9, 23, 25], panbronchiolitis [26], and nasal polyposis [27]), confirmatory ciliary ultrastructural or functional studies or genetic analysis is needed for a firm diagnosis of PCD. In addition, transiently low nasal NO values have been reported during acute viral infections or during acute sinusitis; therefore, measurements should be taken during a baseline healthy period and repeated on a separate day for confirmation.

Nasal NO can be measured by a noninvasive approach (21, 28). Nasal air, aspirated through a catheter placed at the orifice of one nostril, is directed to an NO analyzer that typically uses ozone/NO_2–based chemiluminescence for direct on-line measurement of NO. The nasal catheter is inserted through a foam sleeve or olive that is wedged at the opening of the nostril to limit contamination of nasal air by ambient air. During the measurement, several maneuvers may be used to close the soft palate and thereby limit contamination of nasal air by air exhaled by the lower airways (exhaled NO from lower airways is typically much lower than nasal NO). These techniques have been used reproducibly in children over 5 years of age but often are not possible in younger children who cannot cooperate with palate closure maneuvers. As an alternative, some centers have measured nasal NO during tidal breathing in infants and young children who are unable to cooperate with palate closure maneuvers. Recent efforts have focused on further standardization of nasal NO measurement during palate closure and during tidal breathing to develop a clinically applicable test with appropriate cut-off values for use as a screening or adjunctive test for PCD.

A few recent studies have evaluated nasal NO during tidal breathing in infants and young children. Nasal NO values obtained during tidal breathing are approximately 40% lower than values obtained at plateau during palate closure when measured in the same healthy subjects. In addition, young children have lower nasal NO values than older children and adults. Nasal NO production is very low in newborn infants and increases with age over the first 5 years of life in healthy children but remains low in children with PCD. Therefore, age-specific cut-off values are needed when using nasal NO as a screening test for PCD in young children.

CHALLENGES IN THE CLINICAL SETTING

The first level of diagnostic evaluation is assessment for clinical features of PCD, including chronic daily wet cough, chronic nasal congestion, history of neonatal respiratory distress despite term gestation, persistent otitis media, bronchiectasis, and a laterality defect (situs inversus totalis or heterotaxy) (1, 2, 9, 29). The clinical phenotype is strengthened by the identification of most of these features and by a family history of PCD, situs inversus totalis, or other phenotypic features of PCD. The next level of evaluation depends on the availability of diagnostic tests. Few clinical centers have access to reliable transmission EM to evaluate ciliary ultrastructure, and even fewer have access to high-speed videomicroscosopy. Several centers are performing nasal NO measurements; however, the methodologies vary, and there is no standardized cut-off point for use as a widely applicable clinical test. The rapidly expanding list of genes that may be involved in PCD (*see* section on genetics, pp. 430) is enhancing our ability to define PCD in individuals who do not have the classic ultrastructural defects or the classic ciliary motility defects or very low nasal NO. Therefore, we propose that the optimal approach involves all three of the nongenetic tests (analyses of nasal NO, ciliary ultrastructure, and ciliary beat pattern) to validate the diagnosis. In the presence of a strong clinical phenotype, none of these tests alone can rule out PCD; however, if all test results are normal, the diagnosis is very unlikely. In the absence of a classic ultrastructural defect, low nasal NO or altered ciliary beat pattern make PCD more likely and should direct research evaluation for DNAH11 or other genetic mutations. There is no absolute level of nasal NO that eliminates the possibility of PCD; however, identification of a nasal NO in the normal range ($>$ 200 nl/min) should prompt close scrutiny of the diagnosis, including repeat nasal NO measurement and nasal biopsy. A normal nasal NO can be strong supportive evidence against PCD in individuals with an incomplete clinical phenotype for PCD.

FUTURE DIRECTIONS

Optimizing and expanding access to these nongenetic diagnostic tests is critical for ensuring a timely and accurate diagnosis of PCD. A high priority is to standardize nasal NO testing for a broad-scale use as a screening test for PCD in the clinical arena. Presently, nasal NO testing is available only on a research basis in the United States. Steps needed to develop as a clinical test include defining (*1*) uniform protocol for testing, (*2*) calibration of equipment, (*3*) acceptable maneuvers, (*4*) limits for allowable ambient NO, and (*5*) correction for different flow rates in different analyzers. In addition, data from large populations of patients with PCD and healthy control subjects are needed to define and validate cut-off values (including age-specific cut-off values in young children). These definitions and data are needed

to complete applications for approval for the use of NO analyzers in the clinical setting. Because EM and videomicroscopy are highly specialized procedures, we propose the development of highly specialized PCD diagnostic centers that use a uniform approach for processing and interpreting respiratory ciliary ultrastructure by EM and a uniform, objective analysis of ciliary beat pattern by high-speed videomicroscopy.

Author Disclosure: M.L. received institutional grant support from the Cystic Fibrosis Foundation. C.O. received support for travel from the PCD Foundation, USA. M.K. received institutional grant and support for travel. He was a consultant for Inspire Pharmaceutical and is employed by the University of North Carolina, Chapel Hill. He owns a patent through and receives royalties from the University of North Carolina, Chapel Hill. He receives royalties from and owns stocks of Inspire Pharmaceutical.

References

1. Leigh MW, Zariwala MA, Knowles MR. Primary ciliary dyskinesia: improving the diagnostic approach. *Curr Opin Pediatr* 2009;21:320–325.
2. Barbato A, Frischer T, Kuehni CE, Snijders D, Azevedo I, Baktai G, Bartoloni L, Eber E, Escribano A, Haarman E, *et al*. Primary ciliary dyskinesia: a consensus statement on diagnostic and treatment approaches in children. *Eur Respir J* 2009;34:1264–1276.
3. Papon JF, Coste A, Roudot-Thoraval F, Boucherat M, Roger G, Tamalet A, Vojtek AM, Amselem S, Escudier E. A 20-year experience of electron microscopy in the diagnosis of primary ciliary dyskinesia. *Eur Respir J* 2010;35:1057–1063.
4. O'Callaghan C, Rutman A, Williams GM, Hirst RA. Inner dynein arm defects causing primary ciliary dyskinesia: repeat testing required. *Eur Respir J* (In press)
5. Daniels MLA, Baker B, Minnix S, Dell S, Ferkol T, Milla CE, Olivier KN, Rosenfeld M, Sagel S, Carson JL, *et al*. The diagnostic dilemma of primary ciliary dyskinesia: Findings and experience of the Genetic Disorders of Mucociliary Clearance Consortium [abstract]. *Am J Respir Crit Care Med* 2011;183:A1217.
6. Schwabe GC, Hoffmann K, Loges NT, Birker D, Rossier C, de Santi MM, Olbrich H, Fliegauf M, Failly M, Liebers U, *et al*. Primary ciliary dyskinesia associated with normal axoneme ultrastructure is caused by DNAH11 mutations. *Hum Mutat* 2008;29:289–298.
7. Bush A, Cole P, Hariri M, Mackay I, Phillips G, O'Callaghan C, Wilson R, Warner JO. Primary ciliary dyskinesia: diagnosis and standards of care. *Eur Respir J* 1998;12:982–988.
8. Stannard W, Chilvers M, Rutman A, Williams CD, O'Callaghan C. Diagnostic testing of patients suspected of primary ciliary dyskinesia. *Am J Respir Crit Care Med* 2010;181:307–314.
9. Noone PG, Leigh MW, Sannuti A, Minnix SL, Carson JL, Hazucha M, Zariwala MA, Knowles MR. Primary ciliary dyskinesia: diagnostic and phenotypic features. *Am J Respir Crit Care Med* 2004;169:459–467.
10. Thomas B, Rutman A, O'Callaghan C. Disrupted ciliated epithelium shows slower ciliary beat frequency and increased dyskinesa. *Eur Respir J* 2009;34:1–4.
11. Hirst RA, Rutman A, Williams G, O'Callaghan C. Ciliated air-liquid cultures as an aid to diagnostic testing of primary ciliary dyskinesia (PCD). *Chest* 2010;138:1441–1447.
12. Stannard W, Rutman A, Wallis C, O'Callaghan C. Central microtubular agenesis causing primary ciliary dyskinesia. *Am J Respir Crit Care Med* 2004;169:634–637.
13. Chilvers MA, O'Callaghan C. Analysis of ciliary beat pattern and beat frequency using digital high speed imaging: comparison with the photomultiplier and photodiode methods. *Thorax* 2000;55:314–317.
14. Chilvers MA, Rutman A, O'Callaghan C. Ciliary beat pattern is associated with specific ultrastructural defects in primary ciliary dyskinesia. *J Allergy Clin Immunol* 2003;112:518–524.
15. Chilvers MA, Rutman A, O'Callaghan C. Functional analysis of cilia and ciliated epithelial ultrastructure in healthy children and young adults. *Thorax* 2003;58:333–338.
16. Li D, Shirakami G, Zhan X, Johns RA. Regulation of ciliary beat frequency by the nitric oxide-cyclic guanosine monophosphate signaling pathway in rat airway epithelial cells. *Am J Respir Cell Mol Biol* 2000; 23:175–181.
17. Jain B, Rubinstein I, Robbins RA, Leise KL, Sisson JH. Modulation of airway epithelial cell ciliary beat frequency by nitric oxide. *Biochem Biophys Res Commun* 1993;191:83–88.
18. Hibbs JB Jr. Synthesis of nitric oxide from L-arginine: a recently discovered pathway induced by cytokines with antitumour and antimicrobial activity. *Res Immunol* 1991;142:565–569.
19. Kawamoto H, Takeno S, Yajin K. Increased expression of inducible nitric oxide synthase in nasal epithelial cells in patients with allergic rhinitis. *Laryngoscope* 1999;109:2015–2020.
20. Xue C, Botkin SJ, Johns RA. Localization of endothelial NOS at the basal microtubule membrane in ciliated epithelium of rat lung. *J Histochem Cytochem* 1996;44:463–471.
21. Lundberg JON, Weitzberg E, Nordvall SL, Kuylenstierna R, Lundberg JM, Alving K. Primarily nasal origin of exhaled nitric oxide and absence in Kartagener's syndrome. *Eur Respir J* 1994;7:1501–1504.
22. Narang I, Ersu R, Wilson NM, Bush A. Nitric oxide in chronic airway inflammation in children: diagnostic use and pathophysiological significance. *Thorax* 2002;57:586–589.
23. Wodehouse T, Kharitonov SA, Mackay IS, Barnes PJ, Wilson R, Cole PJ. Nasal nitric oxide measurements for the screening of primary ciliary dyskinesia. *Eur Respir J* 2003;21:43–47.
24. Corbelli R, Bringolf-Isler B, Amacher A, Sasse B, Spycher M, Hammer J. Nasal nitric oxide measurements to screen children for primary ciliary dyskinesia. *Chest* 2004;126:1054–1059.
25. Balfour-Lynn IM, Laverty A, Dinwiddie R. Reduced upper airway nitric oxide in cystic fibrosis. *Arch Dis Child* 1996;75:319–322.
26. Nakano H, Ide H, Imada M, Osanai S, Takahashi T, Kikuchi K, Iwamoto J. Reduced nasal nitric oxide in diffuse panbronchiolitis. *Am J Respir Crit Care Med* 2000;162:2218–2220.
27. Colantonio D, Brouillette L, Parikh A, Scadding GK. Paradoxical low nasal nitric oxide in nasal polyposis. *Clin Exp Allergy* 2002;32:698–701.
28. ATS/ERS. Recommendations for standardized procedures for the online and offline measurement of exhaled lower respiratory nitric oxide and nasal nitric oxide. *Am J Respir Crit Care Med* 2005;171:912–930.
29. Kennedy MP, Omran H, Leigh MW, Dell S, Morgan L, Molina PL, Robinson BV, Minnix SL, Olbrich H, Severin T, *et al*. Congenital heart disease and other heterotaxic defects in a large cohort of patients with primary ciliary dyskinesia. *Circulation* 2007;115:2814–2821.