BMJ Case Reports

Rare disease

Primary adenoid cystic carcinoma of the bronchus in a female teenager

I Masih,[1] G Porter,[2] S Porter,[3] R Clarke,[4] P Sidhu,[5] J Harney,[6] A McCarthy,[7] R Convery[1]

[1] Department of Respiratory Medicine, Craigavon Area Hospital, Port down, Craigavon, UK
[2] Department of Accident and Emergency, Craigavon Area Hospital, Portadown, Craigavon, UK
[3] Department of Radiology, Craigavon Area Hospital, Portadown, Craigavon, UK
[4] Department of Pathology, Craigavon Area Hospital, Portadown, Craigavon, UK
[5] Department of Thoracic Surgery, Royal Victoria Hospital, Belfast, UK
[6] Department of Clinical Oncology, Belfast City Hospital, Belfast, UK
[7] Department of Paediatric Oncology, Royal Victoria Hospital, Belfast, UK

Correspondence to I Masih, izhaq@doctors.net.uk

Summary

Primary adenoid cystic carcinoma (ACC) of the lung is an extremely rare malignant lung neoplasm. ACC of salivary glands of the head and neck, lachrymal glands, breast, skin, vulva and trachea have been frequently reported disease patterns in the literature, but it is unique to see this rare lung tumour in a patient as young as 14 years old. No double blind placebo, multicentre treatment data are available. Surgery is considered as the cornerstone of the treatment. Prognosis is variable and adjuvant radiotherapy has been found beneficial for prolonged survival.

Our report of primary lung ACC in a young girl is a complex case due to young age, a different way of presentation and staging on diagnosis. It has been a quite challenging clinical scenario for the multidisciplinary lung cancer treating team involved in the clinical care. Prognosis remains unpredictable and uncertain despite the best present day evidence-based treatment.

BACKGROUND

Adenoid cystic carcinoma (ACC) has been described in different organs of the body. ACC of the lung is a very rare primary lung tumour and ACC in a patient as young as 14 years of age is even rarer. Chest and shoulder pain has not been described as the presenting symptoms before and there are no recognised treatment trials available in the literature. Management can be even more challenging in the younger age group of patients.

CASE PRESENTATION

A 14-year-old female lifelong non-smoker presented with recurrent chest and right shoulder pain over a period of 6 weeks. She had no cough, haemoptysis and shortness of breath, upper airway symptoms or weight loss. She had no preceding illnesses. She played hockey without any problems up until the day of her presentation. Cervical lymphadenopathy was not noticed. Respiratory examination was normal.

Full blood count and blood biochemistry were normal. Chest x-ray revealed a large right middle and upper zone soft tissue mass. Obliteration of inferior aspect of right paratracheal line and right hilar structures indicated anterior and middle mediastinal involvement (figure 1). CT chest demonstrated a 10.7×12.9 cm mass with pleural involvement but no visible hilar or subcarinal lymph nodes. Major

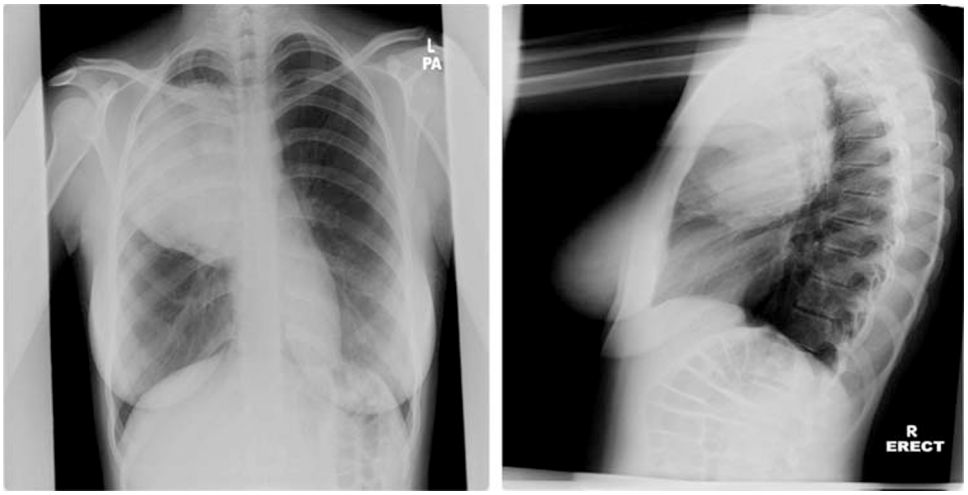

Figure 1 Plain x-ray films showing a large mass extending the anterior and middle mediastinum.

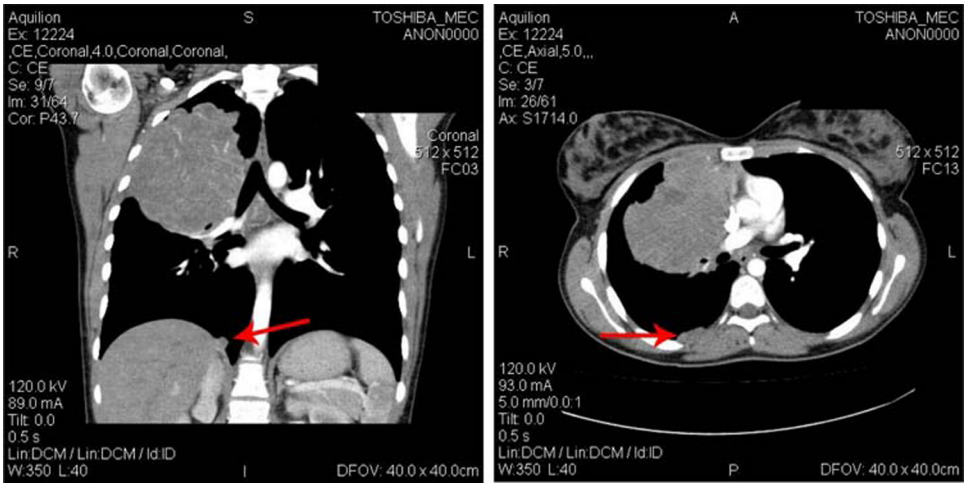

Figure 2 CT scan of chest demonstrating a 10.7×12.9 cm mass and pleural involvement.

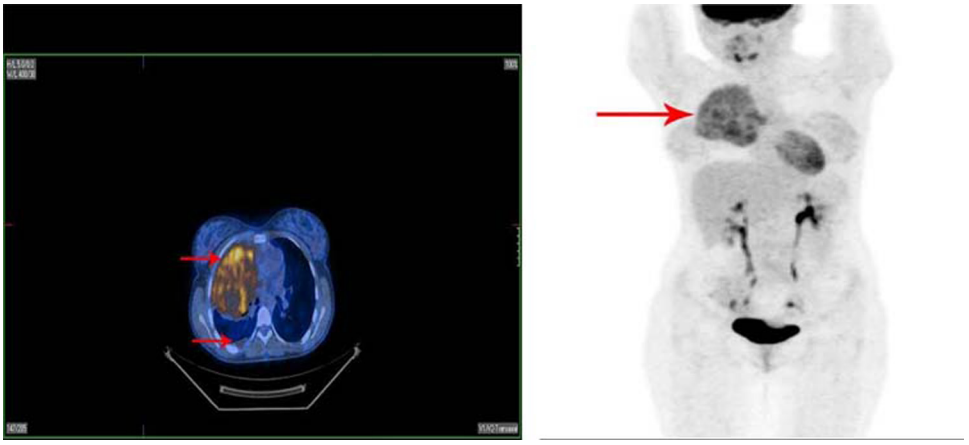

Figure 3 ^{18}F-fluorodeoxyglucose (FDG) positron emission tomography CT illustrated high metabolic activity in the tumour and pleural deposits.

vascular structures were normal. Several small pleural nodules were identified representing pleural-based metastases (figure 2). Primary lung tumour, thymoma, teratoma and lymphoma were the important differentials.

CT-guided needle biopsies using Temno Evolution18 (Carefusion, Voisins le BretonneuxFrance) gauge coaxial biopsy system were obtained. The positron emission tomography (PET) scan with ^{18}F-fluorodeoxyglucose showed high metabolic activity in the tumour and pleural deposits but the disease extension was not noted in any further areas of the body (figure 3). Histopathological analysis revealed a cribriform and punched-out pattern with glandular spaces, typical picture of ACC (figure 4) showing strong positive stain for actin and myosin but negative for carcinoembryonic antigen, neuroendocrine marker CD56 and chromogranin. Further immunoperoxidase studies for epithelial markers AE1/AE3 and CAM 5.2 showed strong positivity. This was in keeping with the diagnosis of ACC.

Bronchoscopy showed no visible endobronchial mass lesions. External auditory canals and tympanic membranes were normal. Nasendoscopy showed normal nasal cavity and postnasal space. Oral cavity, pharynx and larynx, submandibular and parotid glands were normal. Flexible larngopharyngoscopy was unremarkable.

After multidisciplinary lung cancer workup, right pneumonectomy and patch repair of the superior vena cava along with pleural resection for metastatic disease was carried out. Postsurgical resection sample confirmed ACC of bronchial origin infiltrating the pleural surface with pretracheal and tracheobronchial lymph node invasion. Thymic tissue did not show any signs of malignancy. Overall staging after surgery was pT3N2. After further consultation and careful consideration by the multidisciplinary lung cancer team, she received postoperative adjuvant radiotherapy to a dose of 60 Gy in 30 fractions over the period of 6 weeks using a conformal three-dimensional CT planning technique with a boost of a further 6 Gy to PET positive areas. She tolerated radiotherapy with very minimal toxicity. The patient remained clinically stable at clinic 18 months after the initial presentation and follow-up PET scan shows significant response to radiotherapy with ongoing clinical surveillance.

BMJ Case Reports 2010; doi:10.1136/bcr.08.2010.3252

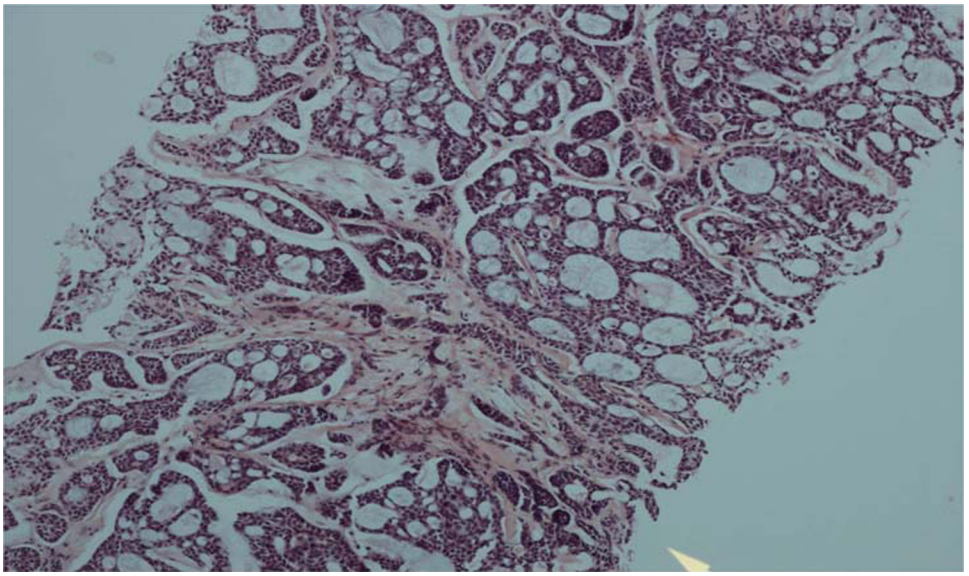

Figure 4 Histology typical of adenoid cystic carcinoma showing a cribriform, punched-out pattern with glandular spaces. Magnification ×200.

INVESTIGATIONS

Chest x-ray, CT chest, PET scan, CT-guided lung biopsy, and histopathology and immunocytochemistry.

DIFFERENTIAL DIAGNOSIS

Primary lung tumour, lymphoma, thymoma and teratoma.

TREATMENT

Pneumonectomy and radical radiotherapy.

OUTCOME AND FOLLOW-UP

Successful treatment with pneumonectomy and adjunct radiotherapy with good clinical response and ongoing follow-up.

DISCUSSION

Primary ACC of the lung is an extremely rare malignant neoplasm. In large cancer reviews, it is found to constitute around 0.2% of all lung tumours.[1] ACCs may arise from salivary glands of the head and neck, lachrymal glands, breast, skin, vulva and trachea but primary ACC of the lung is very uncommon.[2] There is no association with smoking. Common presentations are cough, haemoptysis, wheeze and shortness of breath.[3] It progresses in an infiltrative manner and is locally invasive. In 10–20% of cases, regional lymph nodes can be involved at the time of presentation but later distant involvement of the lymph nodes, liver, bones and brain can occur.[4 5] Mutation of the *P53* suppressor gene has been mentioned as an association but it is not clearly defined.[6] Histopathology, cribriform, solid and tubular patterns are typical. Staging at the time of presentation has a strong correlation with the prognosis.[7] The mainstay of the treatment is surgical resection.[8] Complete resection may not be possible due to local dissemination. Some patients may not be fit for surgery; hence, recurrence is a potential threat. Adjuvant radiotherapy is commonly recommended. The clinical course is variable but there is often prolonged survival despite residual tumour. Most ACCs are radiosensitive and the presence of lymph node involvement may not necessarily decrease survival.[9] There is some literature advocating dose–response radiotherapy as a primary treatment.[10] However, no robust data are available to support such claims of long-term survival benefits.[11] Therefore, the sensible approach is to rationalise the treatment on individual patient-based assessments.

This is the first report of ACC in a patient as young as 14 years old. Previously, chest and shoulder pain have not been recorded as the presenting symptoms. This difficult presentation of ACC, young age and staging on diagnosis proved to be extremely challenging for the multidisciplinary lung cancer team. In spite of receiving the best available evidence-based treatment, her prognostic outcome remains unpredictable.

Learning points

- Rare presentation of chest and shoulder pain, which could have been easily overlooked in accident and emergency at the time of presentation.
- Rare primary lung tumour diagnosis at a young age with normal clinical examination can be an extremely rare differential diagnosis for a physician.
- This is a very challenging case for a multidisciplinary team to rationalise the treatment of a primary but rare lung tumour in a young patient with advanced disease.
- Ongoing clinical follow-up of the case is required with unpredictable long-term outcome.

Competing interests None.

Patient consent Obtained.

REFERENCES

1. **Sweeney WB,** Thomas JM. Adenoid cystic carcinoma of the lung. *Contemp Surg* 1986;**28**:97–100

2. **Chin HW,** DeMeester T, Chin RY, *et al*. Endobronchial adenoid cystic carcinoma. *Chest* 1991;**100**:1464–5.
3. **Moran CA,** Ssuster S, Koss MN. Primary adenoid cystic carcinoma of the lung. *Cancer* 1994;**73**:1390–7.
4. **Kim BK.** Palliative radiotherapy in a patient with pulmonary adenoid cystic carcinoma. *Cancer Res Treat* 2007;**39**:185–8.
5. **Orozco AIB,** Cañamaque AG, Navarro JMS, *et al*. Adenoid cystic carcinoma of respiratory airways: course and treatment. *Arch Bronconeumol* 1999;**35**:257–60
6. **Yamamoto Y,** Wistuba LI, Kishimoto Y, *et al*. DNA analysis at p53 locus in adenoid cystic carcinoma: Comparison of molecular study and p53 immunostaining. *Pathol Int* 2008;**48**:273–280.
7. **Fletcher CDM.** Adenoid cystic carcinoma. *Diagnostic Histopathology of Tumours*. Philadelphia, Pennsylvania, USA: Elsevier 2007;**3**:190–1.
8. **Kanematsu T,** Yohena T, Uehara T, *et al*. Treatment outcome of resected and non-resected primary adenoid cystic carcinoma of the lung. *Ann Thorac CardioVasc Surg* 2002;**8**:74–7.
9. **Pearson FG,** Todd TRJ, Cooper JD. Experience with primary neoplasms of the trachea and carina. *J Thorac CardioVasc Surg* 1984; **88**:511–18.
10. **Müller A,** Stockamp B, Schnabel T. Successful primary radiation therapy of adenoid cystic carcinoma of the lung. *Oncology*2000;**58**:15–17.
11. **Gelder CM,** Hetzel MR. Primary tracheal tumours. A national survey. *Thorax* 1993;**48**:688–692.

This pdf has been created automatically from the final edited text and images.

Copyright 2010 BMJ Publishing Group. All rights reserved. For permission to reuse any of this content visit
http://group.bmj.com/group/rights-licensing/permissions.
BMJ Case Report Fellows may re-use this article for personal use and teaching without any further permission.

Please cite this article as follows (you will need to access the article online to obtain the date of publication).

Masih I, Porter G, Porter S, Clarke R, Sidhu P, Harney J, McCarthy A, Convery R. Primary adenoid cystic carcinoma of the bronchus in a female teenager. *BMJ Case Reports* 2010;10.1136/bcr.08.2010.3252, date of publication

Become a Fellow of BMJ Case Reports today and you can:
- Submit as many cases as you like
- Enjoy fast sympathetic peer review and rapid publication of accepted articles
- Access all the published articles
- Re-use any of the published material for personal use and teaching without further permission

For information on Institutional Fellowships contact consortiasales@bmjgroup.com

Visit casereports.bmj.com for more articles like this and to become a Fellow