NIH Public Access
Author Manuscript
Muscle Nerve. Author manuscript; available in PMC 2011 August 1.

Published in final edited form as:
Muscle Nerve. 2010 August ; 42(2): 170–176. doi:10.1002/mus.21665.

FUS GENE MUTATIONS IN FAMILIAL AND SPORADIC AMYOTROPHIC LATERAL SCLEROSIS

Rosa Rademakers, PhD[1], **Heather Stewart, PhD**[2], **Mariely DeJesus-Hernandez, BSc**[1], **Charles Krieger, MD**[2], **Neill Graff-Radford, MD**[3], **Marife Fabros, RN**[2], **Hannah Briemberg, MD**[2], **Neil Cashman, MD**[2], **Andrew Eisen, MD**[2], and **Ian R. A. Mackenzie, MD**[4]

[1]Department of Neuroscience, Mayo Clinic, Jacksonville, Florida, USA

[2]Division of Neurology, University of British Columbia, Vancouver, British Columbia, Canada

[3]Department of Neurology, Mayo Clinic, Jacksonville, Florida, USA

[4]Department of Pathology, University of British Columbia, Vancouver, British Columbia, Canada

Abstract

Introduction—Mutations in the fused in sarcoma (FUS) gene have recently been found to cause familial amyotrophic lateral sclerosis (FALS).

Methods—We screened *FUS* in a cohort of 200 ALS patients [32 FALS and 168 sporadic ALS (SALS)].

Results—In one FALS proband, we identified a mutation (p.R521C) that was also present in her affected daughter. Their clinical phenotype was remarkably similar and atypical of classic ALS, with symmetric proximal pelvic and pectoral weakness. Distal weakness and upper motor neuron features only developed late. Neuropathological examination demonstrated FUS-immunoreactive neuronal and glial inclusions in the spinal cord and many extramotor regions, but no TDP-43 pathology. We also identified a novel mutation (p.G187S) in one SALS patient. Overall, FUS mutations accounted for 3% of our non-*SOD1*, non-*TARDBP* FALS cases and 0.6% of SALS.

Discussion—This study demonstrates that the phenotype with *FUS* mutations extends beyond classical ALS. It suggests there are specific clinicogenetic correlations and provides the first detailed neuropathological description.

Keywords

amyotrophic lateral sclerosis; fused in sarcoma; FUS; translocated in liposarcoma; TLS

INTRODUCTION

Amyotrophic lateral sclerosis (ALS) is the classical form of motor neuron disease in which degeneration of upper and lower motor neurons results in progressive weakness and death typically within 2 to 5 years. Although most cases of ALS are sporadic (SALS), approximately 10% have a positive family history (FALS), often with an autosomal dominant pattern of inheritance.1,2 Familial, adult-onset, classical ALS may be caused by mutations in the genes that encode copper/zinc superoxide dismutase 1 (*SOD1*), angiogenin (*ANG*) or the transactive response (TAR) DNA binding protein with M^r 43 kD, TDP-43 (*TARDBP*), and a number of other genetic loci have been linked to FALS.1,2

Correspondence to: Dr. Ian R. Mackenzie, Department of Pathology, Vancouver General Hospital, 855 West 12th Avenue, Vancouver, British Columbia, Canada, V5Z 1M9 ian.mackenzie@vch.ca.

NIH-PA Author Manuscript
NIH-PA Author Manuscript
NIH-PA Author Manuscript

NIH-PA Author Manuscript

NIH-PA Author Manuscript

NIH-PA Author Manuscript

Recently, two studies identified mutations in the gene that encodes the *fused in sarcoma* (FUS) protein (also known as *translocated in liposarcoma*, TLS), as the cause of FALS type 6.[3,4] FUS is a DNA/RNA binding protein with striking functional homology to TDP-43.[5] These studies reported a total of 14 different mutations in 26 unrelated families, representing approximately 4% of FALS in their combined series. Most were missense mutations affecting highly conserved regions in exon 15 that encodes the C-terminus. With the exception of one family with autosomal recessive disease, caused by the c.1551C>G mutation,[3] all other mutations produced autosomal dominant ALS, although with incomplete penetrance. No mutations were found in 293 SALS cases screened in one study.[3] The associated clinical phenotype was described only as classical ALS, and there was very limited description of the post mortem findings.[3,4] Since then, additional studies have reported *FUS* mutations in ALS patients from Italy, Belgium and in a combined French and French-Canadian cohort.[6-10]

In this study, we performed genetic analysis of *FUS* in a cohort of 200 patients with ALS, including 32 FALS and 168 SALS index cases, all of whom had been evaluated at the ALS Clinic at the University of British Columbia, Vancouver, Canada. We identified two *FUS* mutations, including a novel mutation in a case of SALS. We provide detailed description of the clinical features and neuropathological findings in the affected patients.

MATERIALS AND METHODS

Cases

Peripheral blood samples for DNA were collected from 32 index cases with FALS and 168 SALS patients from the ALS Clinic at the University of British Columbia, Vancouver, Canada, between 1997 and 2006. All cases had a diagnosis of definite or probable ALS according to El Escorial criteria.[11] Family history was considered positive for ALS if the proband had at least one affected relative within three generations. Cases in which mutations in *SOD1* or *TARDBP* had previously been identified were excluded.[12] Control samples from neurologically normal individuals (N=678) were obtained at the Mayo Clinic in Jacksonville, Florida. Approval for the study was granted by the local institutional ethics review board, and all subjects provided informed written consent.

Molecular genetic analysis

Genomic DNA was extracted from peripheral blood using standard procedures. Due to the limited quantity and quality of DNA available in some of the samples, sequencing was restricted to those exons in which pathogenic *FUS* mutations had previously been reported.[6-10] The FALS DNA samples were subsequently whole genome amplified in triplicate using the REPLI-g kit (Qiagen, Valencia, CA, USA). For all FALS and SALS patients, PCR of *FUS* exons 5, 6, 14 and 15 was performed with Qiagen products using primers located in adjacent introns. To facilitate sequencing of exons 5 and 6, the M13 forward primer sequence and the M13 reverse primer sequence were attached to the FUS primers. PCR primers are listed in Table 1. PCR products were purified using the Ampure system (Bioscience Corporation, Beverly, MA) and sequenced using Big dye terminator V.3.1 products. Sequencing products were purified using the CleanSEQ method (Agencourt) and analyzed on an ABI 3730 DNA analyzer (Applied Biosystems, Foster City, CA, USA). Sequence analysis was performed using Sequencher software (Gene Codes, Ann Arbor, MI, USA). All identified mutations were confirmed by sequencing of the original gDNA sample. The screening of c.559G>A (p.G187S) and c.404G>A (p.S135N; rs617332970) was performed using custom Taqman SNP genotyping assays with the File Builder 3.1 software (Applied Biosystems) and analyzed on an ABI7900 genetic analyzer using SDS2.2.2 software. To identify small insertions and deletions (indels) in the glycine-rich region in

NIH-PA Author Manuscript

NIH-PA Author Manuscript

NIH-PA Author Manuscript

exon 5, we PCR amplified exon 5 using one fluorescently labeled primer and performed fragment length analysis on an automated ABI3730 DNA-analyzer (Applied Biosystems) (Table 1). Allele identification and scoring was performed using GENESCAN and GENOTYPER software (Applied Biosystems).

Histology and immunohistochemistry

Sections of formalin-fixed, paraffin-embedded material were stained using hematoxylin and eosin (HE) alone or in combination with luxol fast blue (HE/LFB). All immunohistochemistry (IHC) was performed using the Ventana BenchMark® XT automated staining system (Ventana, Tuscon, AZ) and developed with aminoethylcarbizole. The primary antibodies employed recognized FUS (Sigma-Aldrich, 1:25 - 1:200 with initial overnight incubation at room temperature, following microwave antigen retrieval), ubiquitin (DAKO, 1:500, following microwave antigen retrieval), TDP-43 (ProteinTech Group, 1:1,000 following microwave antigen retrieval), glial fibrillary acidic protein (DAKO, 1:4,000) and CD68 (DAKO, 1:800). FUS IHC was also performed on control sections of spinal cord from 6 SALS and 3 FALS cases with known *SOD-1* mutations.

RESULTS

FUS gene analysis

We performed mutation analysis of FUS exons 5, 6, 14 and 15 in a population of 32 FALS probands and 168 SALS patients. In the FALS patients, we identified one proband carrying the known heterozygous missense mutation c.1561C>T (p.R521C) in exon 15 (Fig. 1A).[3,4,6,8,10] Further analysis demonstrated the same mutation in a DNA sample from the proband's affected daughter, confirming segregation of the mutation with disease in this family. In the SALS patients, we identified a novel missense mutation (c.559G>A, p.G187S) in FUS exon 6 in a single patient (Fig. 1A). This mutation was not present in our 678 control samples. A second missense mutation (c.404G>A; p.S135N) was found in another of our SALS patients. Although this mutation was also absent in our control series, it is reported in the public SNP database (dbSNP, http://www.ncbi.nlm.nih.gov/projects/SNP/), suggesting it may be a rare benign variant. Finally, we identified four SALS patients who carry a previously reported 6-bp deletion in the glycine-stretch encoded by the end of exon 5 (c. 521_523+3delGAGGTG; p.G173_G174del).[3] This same 6-bp deletion was also identified in 3/678 samples in our control series.

Clinical Descriptions

FALS patients with FUS mutation—The proband was a recently retired 62-year old woman who presented with difficulty climbing stairs, requiring the use of the handrail. She had previously been in excellent health and on no medications. Her only complaint was some aching of her leg muscles. She had fallen on several occasions and had difficulty getting up from a squatting position. A few months later, she developed left arm weakness, making it difficult for her to perform tasks that required her to lift her arm above her head. Examination showed her to have a waddling gait. She was not able to walk on her heels or toes and had problems stepping up onto a low stool. There was considerable pelvic girdle weakness with symmetric, bilateral wasting of the quadriceps. Both shoulder girdles were also weak, and there was mild weakness of neck flexors. Cranial nerve function and cognition were normal. Initial electromyography (EMG) studies were suggestive of a myopathy but later showed evidence of denervation. Nerve conduction studies found no motor conduction slowing or conduction block, and sensory nerve action potentials were of normal amplitude. Creatine kinase was normal, and a muscle biopsy was suggestive of a neurogenic process. MRI of the brain was normal. Only later in the disease course did she

NIH-PA Author Manuscript

NIH-PA Author Manuscript

NIH-PA Author Manuscript

develop brisk tendon reflexes and diffuse fasciculation. She died approximately 3.5 years after developing her initial symptoms.

Her daughter was a 39-year old school teacher who developed similar symptoms at almost the same time as her mother. She had been a competitive volleyball player and become aware of difficulty playing because of problems moving her legs. She also had difficulty climbing stairs and rising from a crouched position. Her weakness progressed, and three months later she required assistance walking. One month later, she noticed difficulty using her left arm to dry her hair. She developed trouble swallowing, and her weight dropped from 170 to 140 pounds. On examination she was alert and intelligent. She had lingual fasciculation, but otherwise cranial nerve function was normal. There was weakness of both deltoids against resistance, but the biceps and triceps were strong. There was no weakness or wasting in the hands. She had a waddling gait and was unable to walk on her heels or toes. She had to push with her arms to rise from a standard chair. The quadriceps muscles were symmetrically wasted, but distal leg muscles were strong. Tendon reflexes were present but not overactive in the arms and knees, and ankle jerks were depressed. The toes were down-going. Over the following six months the right upper limb tendon reflexes became brisk, but the leg tendon reflexes remained difficult to obtain. EMG was neurogenic and showed denervation in the upper and lower limbs with recruitment of complex motor unit potentials. Motor conduction studies were normal with no conduction block. MRI of the brain and spinal cord were normal. Serum creatine kinase was slightly elevated (211). A muscle biopsy was consistent with a neurogenic process, and there was no evidence of a glycogen storage disease. Acid maltase assays were also normal. Like her mother, disease duration was approximately 3.5 years

The family pedigree is provided in Figure 1B. The grandparents and parents of the proband had no known neurological disease, however their age and cause of death are not known. Her four siblings were believed to be asymptomatic, but she had been estranged from them for several years. The affected daughter was her only child, and she had two healthy young children.

SALS patient with FUS mutation—This woman was born in Canada of Dutch parents. She presented at age 79 with speech difficulties and also complained of some muscle cramping and emotional lability. Medical history included thyroid disease, hypertension and hypercholesterolemia. When examined by a neurologist, five months after onset of symptoms, she was found to have dysarthria, diffuse muscle wasting, fasciculations and exaggerated deep tendon reflexes. Neurophysiological testing, including electromyography and motor and sensory nerve conduction studies, further supported the diagnosis of ALS. She progressed rapidly and died 14 months after onset. Autopsy was not performed. There was no family history of neurological disease.

Neuropathology

Post mortem examination was performed on the proband of the family with the c.1561C>T (p.R521C) mutation. The brain weighed 1250 grams and appeared grossly normal. The spinal cord was of small calibre, and the motor nerve roots were atrophic. Microscopic examination of the primary motor cortex failed to demonstrate any appreciable loss of primary motor neurons, and the only suggestion of chronic degeneration was mild reactive gliosis and microglial activation. Sections of spinal cord showed normal myelination of the corticospinal tracts (Fig. 2A). There was severe loss of lower motor neurons (LMN) at all levels, and the remaining cells were often shrunken. There were no Bunina bodies or hyaline inclusions visible with HE stain, however some LMN contained ill-defined basophilic

NIH-PA Author Manuscript

NIH-PA Author Manuscript

NIH-PA Author Manuscript

cytoplasmic masses. The motor nerve roots were atrophic with severe loss of myelin staining.

IHC for FUS demonstrated numerous neuronal cytoplasmic inclusions (NCI) in the remaining LMN (Fig. 2B-D). These appeared as diffusely distributed fine granules, more focal collections of coarse granules, collections of thick filaments and compact globular masses that appeared to be a composite of coarse granules and filaments. At least some neurons with NCI showed retention of the normal physiological FUS staining of the nucleus (Fig. 2B). Ubiquitin staining of NCI was weak and inconsistent, and no abnormality was seen with TDP-43 IHC. In addition to NCI, FUS IHC demonstrated numerous glial cytoplasmic inclusions (GCI) and thread-like structures in the ventral grey matter (Fig. 2E). Cells with small round nuclei, typical of oligodendrocytes, often contained small flame-shaped masses or single short processes, while some cells with oval nuclei were associated with more complex FUS-immunoreactive (ir) processes, consistent with astrocytic morphology. While some of the smaller FUS-ir threads could have been of glial origin, larger ones were clearly neuritic. The dorsal grey matter of the spinal cord also contained numerous FUS-ir NCI, GCI and threads. GCI and thread pathology was moderate in the corticospinal tracts and mild in other white matter funiculi. Motor nuclei of the brainstem, including the hypoglossal nucleus and trigeminal motor nucleus, also showed loss of neurons and FUS-ir NCI, GCI and threads.

Despite not showing any evidence of chronic degeneration, several other subcortical nuclei contained mild-to-moderate FUS-ir neuronal and glial pathology, including the striatum, thalamus, substantia nigra, superior colliculus, red nucleus and reticular formation (Fig. 2F), and occasional GCI and threads were present in many brainstem white matter tracts. There was some anatomical specificity to the FUS-ir pathology, as many regions showed no involvement, including the occulomotor nucleus, pontine nuclei, inferior olive, cerebellum. No FUS-ir pathology was found in the primary motor cortex, other neocortical regions or hippocampus.

FUS IHC performed on spinal cord sections from SALS control cases and FALS patients with *SOD-1* mutations demonstrated the normal physiological staining pattern but no FUS-ir pathology.

Discussion

The *FUS* gene, located on chromosome 16, consists of 15 exons that encode a 526 amino acid protein.14 The C-terminus region contains multiple domains involved in RNA-protein interactions while the N-terminus functions in transcriptional activation.15 FUS is a ubiquitously expressed protein14,16 that binds to RNA17,18 and DNA19 and is involved in diverse cellular processes including cell proliferation,20 DNA repair,21 transcription regulation, RNA splicing22 and the transport of RNA between intracellular compartments.18 In most cell types, FUS is present in both the nucleus and cytoplasm, however in neurons there is proportionally more in the nucleus and expression in glia is exclusively nuclear.16 FUS may be involved in neuronal plasticity and maintenance of dendritic integrity by transporting mRNA, including those encoding actin-related proteins, to dendritic spines for local translation in response to synaptic stimulation.23,24 In contrast, FUS deficient neurons show decreased spine arborization and morphology.23 Chromosomal translocation of the 5′ portion of *FUS* results in several fusion oncogenes that are each associated with specific types of human cancer, including myxoid liposarcoma, Ewing's sarcoma and acute myeloid leukemia.25 FUS knock out mice show perinatal mortality.26 The finding that *FUS* mutations cause FALS was the first association between this protein and a neurodegenerative condition.

NIH-PA Author Manuscript

NIH-PA Author Manuscript

NIH-PA Author Manuscript

We identified a single *FUS* mutation in our cohort of 32 index cases with *SOD1*-negative, *TARDBP*-negative FALS. This represents a frequency of 3%, which is very similar to what has been reported in all the previous studies with the exception of Belzil *et al*., who found a much lower frequency of 1.25%.3,4,6-10 The specific mutation (c.1561C>T; p.R521C) is the most common one reported to date. It has been identified in 11 families and in two sporadic cases.3,4,6,8,10 As in several of the previous studies, the mutation segregated with disease in our family.

We also identified a novel *FUS* mutation in one of our ALS cases in which there was no family history. However, the late age at onset of this patient, combined with the lack of information regarding the ages at which her parents died, means we cannot be certain that this case was truly sporadic. This c.559G>A (p.G187S) mutation is located in exon 6 that encodes a portion of the glycine-rich region of the protein. Due to the absence of other affected family members, segregation of the mutation with disease could not be studied and, unfortunately, we did not have autopsy confirmation that this case had FUS pathology. We believe this mutation is likely pathogenic, since it was not identified in 678 controls (1356 chromosomes), affects a highly conserved element in a functionally crucial region of the protein (Fig. 1C) and involves an exon (6) where other mutations have been reported in FALS patients.3,8,10 In addition, we identified four SALS patients who carry the known c. 521_523+3delGAGGTG 6-bp deletion in exon 5.3,8 This mutation is predicted to result in the deletion of two glycine residues (p.G173_G174del) from a glycine stretch which is located in a highly conserved region of the FUS protein; however, the number of glycine residues in this region is not well conserved (Fig. 1D). Although this deletion was first reported as a pathogenic mutation in a FALS patient, segregation of this mutation with disease was not performed.3 In our study, we identified this same deletion in 3 of 678 samples in our control series. These findings, together with recent reports of deletions in glycine stretches encoded by *FUS* exons 5 and 6, in both ALS patients and controls, suggest that c.521_523+3delGAGGTG does not represent a pathogenic mutation.6,8

Three previous studies have evaluated *FUS* mutations in SALS patients.3,6,8 Kwiatkowski *et al*. sequenced all 15 exons in 293 SALS cases and failed to identify any genetic variants of significance.3 Belzil *et al*. screened all exons in 120 SALS cases and only exon 15 in an additional 285 cases.6 They identified one novel mutation in exon 3 and two mutations in exon 15 that have also been reported in several FALS cases. Most recently, Corrado *et al*. screened exons 5, 6, 14 and 15 in 964 SALS cases and extended the analysis to the entire coding sequence in 293 of these.8 They identified 6 different missense mutations in 7 SALS cases (0.7%), including the common c.1561C>T (p.R521C) mutation in one case and 5 novel mutations in exons 14 (N=1) and 6 (N=4). The finding of a single case with a mutation of probable pathogenicity in our SALS cohort represents a *FUS* mutation frequency in SALS of 0.6% and is consistent with the low frequency (0 – 0.7 %) identified in the previous studies.3,6,8 Although the selective genetic screening in our study and those of Belzil *et al*. and Corrado *et al*. could have resulted in some mutations being missed, overall these results suggest FUS mutations are probably an uncommon cause of SALS.

Most of the previous reports have provided minimal description of the clinical phenotype associated with *FUS* mutations, indicating only that it is usually classical ALS.3,4,6 One of the two Italian kindreds described by Chio *et al*., had a notably young onset and rapid course.7 The report by Ticozzi *et al*. provided greater detail of the clinical features of their three probands, one of whom also developed frontotemporal dementia (FTD) while the other two had an unusual presentation with symmetric proximal and axial weakness.10 Corrado *et al*. also described one FALS and one SALS patient with predominant symmetric proximal and axial weakness.8 Our *FUS* mutation family had a number of unusual clinical features, including synchronous onset in the proband and her daughter with a 23-year age difference.

NIH-PA Author Manuscript

NIH-PA Author Manuscript

NIH-PA Author Manuscript

The fact they were living together at the time raised the suspicion of some environmental trigger for their disease. Their course was remarkably similar and atypical, with initial involvement of pelvic and shoulder girdles, late involvement of distal muscles and minimal evidence of upper motor neuron involvement. Interestingly, the c.1561C>T (p.R521C) mutation that was found in our family is the same as in both families reported by Ticozzi *et al*. and both patients reported by Corrado *et al*. who also presented with symmetric proximal weakness.8,10 This raises the possibility that certain *FUS* mutations may be associated with a specific clinical phenotype. Although several other families have been reported with this mutation, they are not described in sufficient detail to allow confirmation of this association.3,4,6

Prior assessment of the neuropathology associated with *FUS* mutations has been extremely limited. The two initial reports described the autopsy findings in a small number of affected individuals as including loss of LMN and inconsistent myelin pallor of the corticospinal tracts.3,4 The one case reported by Kwiatkoski *et al*. was felt to show increased cytoplasmic FUS immunoreactivity in neurons,3 while Vance *et al.* described the presence of FUS-ir dystrophic neurites and globular NCI in LMN, in the absence of TDP-43 pathology.4 None of the more recent publications has included pathological assessment.6-10 In this study, we provide the first detailed description of the neuropathology in an ALS patient with *FUS* mutation. The much greater involvement of lower compared with upper motor neurons correlated with the clinical phenotype in our patient. We confirmed the presence of FUS-ir, TDP-43-negative NCI in LMN and describe their variable morphology. Importantly, we found at least some preservation of normal physiological nuclear FUS immunoreactivity in neurons containing NCI. This finding is consistent with previous *in vitro* studies showing that although *FUS* mutations result in an increase in cytoplasmic localization of the protein, there is still some retention of FUS in the nucleus.3,4 This is in striking contrast to the complete nuclear-to-cytoplasmic redistribution of TDP-43 that occurs in sporadic ALS and is of potential functional significance.27 We also found significant FUS pathology in several anatomical sites outside the pyramidal motor system; the significance of these findings must await future clinico-pathological correlative studies. Our finding of FUS-ir inclusions in glial cells is similar to what is found with TDP-43 IHC in sporadic ALS and supports the concept that the pathogenesis of ALS may involve glia as well as neurons. Although the finding of normal FUS IHC in our ALS control cases suggests that FUS pathology may be a specific feature of ALS with *FUS* mutations, this result requires confirmation in a larger series of cases. Finally, the absence of pathological TDP-43 in cases with *FUS* mutations is similar to what is found with *SOD-1* mutations and suggests that the pathogenesis of some genetically based forms of ALS may be different from the majority of SALS.27

In summary, we identified two *FUS* mutations in our cohort, representing 3% of non-*SOD1*, non-*TARDBP* FALS and 0.6% of SALS cases. Although the relatively small size of our cohort and the fact we did not screen the entire gene in all of our samples means that these frequencies cannot be considered definite; they are very similar to those reported in previous studies.6-10 The mutation in our SALS patient has not been reported previously. The clinical features of our affected family show that the phenotype associated with *FUS* mutations extends beyond classical ALS and, together with previous reports, suggest that there may be specific clinico-genetic correlations. Our neuropathological findings demonstrate that ALS with *FUS* mutations is characterized by abundant and anatomically widespread FUS pathology in the absence of abnormalities of TDP-43 and with retention of at least some of the normal cellular distribution of FUS protein. Finally, the report of a *FUS* mutation in one patient with a combination of ALS and FTD,10 combined with our recent studies demonstrating that several subtypes of sporadic FTD are characterized by FUS pathology,27-29 suggest that FUS and TDP-43 may represent dichotomous biochemical pathways that result in a similar spectrum of neurodegenerative disease.

NIH-PA Author Manuscript

NIH-PA Author Manuscript

NIH-PA Author Manuscript

Acknowledgments

We thank Margaret Luk, Matt Baker, NiCole Finch, Nicola Rutherford and Richard Crook for their excellent technical assistance. This work was supported by grants from Canadian Institutes of Health Research (grant number 74580, IM), Pacific Alzheimer Research Foundation (IM, RR), the ALS association (RR) and the NIH/NIA (AG26251-03A1, RR).

Abbreviations

ALS	amyotrophic lateral sclerosis
ANG	angiogenin
DNA	deoxyribonucleic acid
EMG	electromyography
FALS	familial amyotrophic lateral sclerosis
FUS	fused in sarcoma
GCI	glial cytoplasmic inclusion
HE	hematoxylin and eosin
IHC	immunohistochemistry
ir	immunoreactive
LFB	luxol fast blue
LMN	lower motor neuron
MRI	magnetic resonance imaging
NCI	neuronal cytoplasmic inclusion
PCR	polymerase chain reaction
RNA	ribonucleic acid
ALS	sporadic amyotrophic lateral sclerosis
OD1	copper/zinc superoxide dismutase 1
TARDBP	transactive response DNA binding protein
TDP-43	transactive response DNA binding protein with M_r 43 kD
TLS	translocated in liposarcoma

REFERENCES

1. Gros-Louis F, Gaspar C, Rouleau GA. Genetics of familial and sporadic amyotrophic lateral sclerosis. Biochim Biophys Acta. 2006; 1762:956–972. [PubMed: 16503123]
2. Valdmanis PN, Daoud H, Dion PA, Rouleau GA. Recent advances in the genetics of amyotrophic lateral sclerosis. Curr Neurol Neurosci Rep. 2009; 9:198–205. [PubMed: 19348708]
3. Kwiatkowski TJ, Bosco DA, LeClerc AL, Tamrazian E, Vanderburg CR, Russ C, et al. Mutations in the FUS/TLS gene on chromosome 16 cause familial amyotrophic lateral sclerosis. Science. 2009; 323:1205–1208. [PubMed: 19251627]
4. Vance C, Rogelj B, Hortobagyi T, de Vos KJ, Nishimura AL, Sreedharan J, et al. Mutations in FUS, an RNA processing protein, cause familial amyotrophic lateral sclerosis type 6. Science. 2009; 323:1208–1211. [PubMed: 19251628]
5. Lagier-Tourenne C, Cleveland DW. Rethinking ALS: the FUS about TDP-43. Cell. 2009; 136:1001–1004. [PubMed: 19303844]

NIH-PA Author Manuscript

NIH-PA Author Manuscript

NIH-PA Author Manuscript

6. Belzil VV, Valdmanis PN, Dion PA, Daoud H, Kabashi E, Noreau A, et al. Mutations in *FUS* cause FALS and SALS in French and French Canadian populations. Neurology. 2009; 73:1176–1179. [PubMed: 19741216]
7. Chio A, Restagno G, Brunetti M, Ossola M, Calvo A, Mora G, et al. Two Italian kindreds with familial amyotrophic lateral sclerosis due to FUS mutation. Neurobiol Aging. 2009; 30:1272–1275. [PubMed: 19450904]
8. Corrado L, Del Bo R, Castellotti B, Ratti A, Cereda C, Penco S, et al. Mutations in *FUS* gene in sporadic amyotrophic lateral sclerosis. J Med Genet. to be published.
9. Damme PV, Goris A, Race V, Hersmus N, Dubois B, Bosch LV, et al. The occurrence of mutations in FUS in a Belgian cohort of patients with familial ALS. Eur J Neurol. to be published.
10. Ticozzi N, Silani V, LeClerc AL, Keagle P, Gellera C, Ratti A, et al. Analysis of *FUS* gene mutation in familial amyotrophic lateral sclerosis within an Italian cohort. Neurology. 2009; 73:1180–1185. [PubMed: 19741215]
11. Brooks BR, Miller RG, Swash M, Munsat TL. World Federation of Neurology Research Group on Motor Neuron Diseases. El Escorial revisited: revised criteria for the diagnosis of amyotrophic lateral sclerosis. Amytroph Latera Scler Other Motor Neuron Disord. 2000; 1:293–299.
12. Rutherford NR, Zhang YJ, Baker MC, Gass JM, Finch N, Xu F, et al. Novel Mutations in *TARDBP* (TDP-43) in Patients with Familial Amyotrophic Lateral Sclerosis. PLoS Genet Sep. 2008; 194:e1000193.
13. Edgar RC. MUSCLE: multiple sequence alignment with high accuracy and high throughput. Nuc Acid Res. 2004; 32:1792–1797.
14. Aman P, Panagopoulos I, Lassen C, Fioretos T, Mencinger M, Toresson H, et al. Expression patterns of the human sarcoma-associated genes FUS and EWS and the genomic structure of FUS. Genomics. 1996; 37:1–8. [PubMed: 8921363]
15. Prasad DD, Ouchida M, Lee L, Rao VN, Reddy ES. TLS/FUS fusion domain of TLS/FUS-erg chimeric protein resulting from the t(16;21) chromosomal translocation in human myeloid leukemia functions as a transcriptional activation domain. Oncogene. 1994; 9:3717–3729. [PubMed: 7970732]
16. Andersson MK, Stahlberg A, Arvidsson Y, Olofsson A, Semb H, Stenman G, et al. The multifunctional FUS, EWS, and TAF15 proto-oncoproteins show cell type-specific expression patterns and involvement in cell spreading and stress response. BMC Cell Biol. 2008; 9:37. [PubMed: 18620564]
17. Crozat A, Aman P, Mandahl N, Ron D. Fusion of CHOP to a novel RNA-binding protein in human myxoid liposarcoma. Nature. 1993; 363:640–644. [PubMed: 8510758]
18. Zinszner H, Sok J, Immanuel D, Yin Y, Ron D. TLD (FUS) binds RNA in vivo and engages in nucleo-cytoplasmic shuttling. J Cell Sci. 1997; 110:1741–1750. [PubMed: 9264461]
19. Perrotti D, Bonatti S, Trotta R, Martinez R, Skorski T, Salomoni P, et al. TLS/FUS, a pro-oncogene involved in multiple chromosomal translocations, is a novel regulator of BCR/ABL-mediated leukemogenesis. EMBO J. 1998; 17:4442–4455. [PubMed: 9687511]
20. Bertrand P, Akhmedov AT, Delacote F, Durrbach A, Lopez BS. Human POMp75 is identified as the pro-oncoprotein TLS/FUS: both POMp75 and POMp100 DNA homologous pairing activities are associated with cell proliferation. Oncogene. 1999; 18:4515–4521. [PubMed: 10442642]
21. Baechtold H, Kuroda M, Sok J, Ron D, Lopez BS, Akhmedov AT. Human 75-kDa DNA-pairing protein is identical to the pro-oncoprotein TLD/FUS and is able to promote D-loop formation. J Biol Chem. 1999; 274:34337–34342. [PubMed: 10567410]
22. Yang L, Embree LJ, Tsai S, Hickstein DD. Oncoprotein TLS interacts with serine-arginine proteins involved in RNA splicing. J Biol Chem. 1998; 273:27761–27764. [PubMed: 9774382]
23. Fujii R, Okabe S, Urushido T, Inoue K, Yoshimura A, Tachibana T, et al. The RNA binding protein TLS is translocated to dendritic spines by mGluR5 activation and regulates spine morphology. Curr Biol. 2005a; 15:587–593. [PubMed: 15797031]
24. Fujii R, Takumi T. TLS facilitates transport of mRNA encoding an actin-stabilizing protein to dendritic spines. J Cell Sci. 2005b; 118:5755–5765. [PubMed: 16317045]
25. Law WJ, Cann KL, Hicks GG. TLS, EWS, and TAF15: a model for transcriptional integration of gene expression. Brief Funct Genomic Proteomic. 2006; 5:8–14. [PubMed: 16769671]

NIH-PA Author Manuscript

NIH-PA Author Manuscript

NIH-PA Author Manuscript

26. Hicks GG, Singh N, Nashabi A, Mai S, Bozek G, Klewes L, et al. FUS deficiency in mice results in defective B-lymphocyte development and activation, high levels of chromosomal instability and perinatal death. Nat Genet. 2000; 24:175–179. [PubMed: 10655065]

27. Mackenzie IRA, Bigio EH, Ince PG, Geser F, Neumann M, Cairns NJ, et al. Pathological TDP-43 distinguishes sporadic ALS from ALS with *SOD-1* mutations. Ann Neurol. 2007; 61:427–434. [PubMed: 17469116]

28. Munoz DG, Neumann M, Kusaka H, Yokota O, Ishihara K, Terada S, et al. FUS pathology in Basophilic Inclusion Body disease (BIBD). Acta Neuropathol. 2009; 118:617–627. [PubMed: 19830439]

29. Neumann M, Roeber S, Kretzschmar HA, Rademakers R, Baker M, Mackenzie IRA. Abundant FUS-immunoreactive pathology in neuronal intermediate filament inclusion disease. Acta Neuropathol. 2009; 118:605–616. [PubMed: 19669651]

30. Neumann M, Rademakers R, Roeber R, Baker M, Kretzschmar HA, Mackenzie IRA. Frontotemporal lobar degeneration with FUS pathology. Brain. 2009; 132:2922–2931. [PubMed: 19674978]

NIH-PA Author Manuscript

NIH-PA Author Manuscript

NIH-PA Author Manuscript

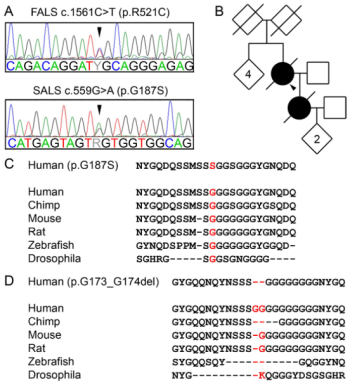

FIGURE 1.

Sequence chromatograms of the c.1561C>T (p.R521C) and c.559G>A (p.G187S) mutations (**A**). Pedigree of the family carrying the c.1561C>T (p.R521C) mutation in *FUS* (**B**). Evolutionary conservation of the p.G187S mutation (**C**) and p.G173_G174del deletion (**D**) in FUS generated by MUSCLE.13 The mutated amino acids are shown in red.

NIH-PA Author Manuscript

NIH-PA Author Manuscript

NIH-PA Author Manuscript

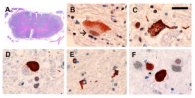

FIGURE 2.

Post-mortem neuropathology in a case of familial ALS with a *FUS* mutation. Normal myelin staining of corticospinal tracts (**A**). Lower motor neurons contained FUS-immunoreactive cytoplasmic inclusions with granular (**B**), filamentous (**C**) or compact (**D**) morphology. Note that some neurons with inclusions retained normal nuclear FUS staining (arrow, **B**). Many glial cells also contained FUS-immunoreactive cytoplasmic inclusions (**E**). FUS-immunoreactive pathology was present in many neuroanatomical regions other than the pyramidal motor system, such as the substantia nigra (**F**). (**A**) Hematoxylin and eosin/luxol fast blue, (**B**-**F**) FUS immunohistochemistry. Scale bar: **A**, 250 μm; **B**, **C** and **F**, 30 μm; **D** and **E**, 20 μm.

NIH-PA Author Manuscript

NIH-PA Author Manuscript

NIH-PA Author Manuscript

Table 1

Primers used for FUS mutation analysis.

Fragment	Direction	Primer sequence
FUS Exon 5	Forward	CACGACGTTGTAAAACGACTGTTGGGTACAGAGAATGGACTCCAC
	Reverse	GGATAACAATTTCACACAGGAAAATGGGCTGCAGACAAAG
FUS Exon 6	Forward	CACGACGTTGTAAAACGACTGCTACTTTACAATCTTTTTGTTTTT
	Reverse	GGATAACAATTTCACACAGGGCACTAGGGACTGGCTTCAG
FUS Exon 14	Forward	CTCACATGGGTAAGAAAGGCAG
	Reverse	TCCTACCTAACCCAGCGAGTATC
FUS Exon 15	Forward	CAGTAGTGGAGAGGGAAGGAA
	Reverse	GACATCGATCTTCCAGGAAAG
Fluorescent assay		
Exon 5	Forward	TGTTGGGTACAGAGAATGG (FAM)
	Reverse	TGCAGACAAAGCTGAAGAC

FUS, fused in sarcoma.