Journal of Cerebral Blood Flow & Metabolism (2010) 30, 510–515
© 2010 ISCBFM All rights reserved 0271-678X/10 $32.00
www.jcbfm.com

Brief Communication

Assessment of regional differences in tariquidar-induced P-glycoprotein modulation at the human blood–brain barrier

Martin Bauer[1], Rudolf Karch[2], Friederike Neumann[2], Claudia C Wagner[1], Kurt Kletter[3], Markus Müller[1], Wolfgang Löscher[4], Markus Zeitlinger[1] and Oliver Langer[1,5]

[1]*Department of Clinical Pharmacology, Medical University of Vienna, Vienna, Austria;* [2]*Department of Medical Statistics and Informatics, Medical University of Vienna, Vienna, Austria;* [3]*Department of Nuclear Medicine, Medical University of Vienna, Vienna, Austria;* [4]*Department of Pharmacology, Toxicology, and Pharmacy, University of Veterinary Medicine Hanover and Centre for Systems Neuroscience, Hanover, Germany;* [5]*Molecular Medicine, AIT Austrian Institute of Technology GmbH, Seibersdorf, Austria*

We attempted to assess regional differences in cerebral P-glycoprotein (P-gp) function by performing paired positron emission tomography (PET) scans with the P-gp substrate (*R*)-[^{11}C]verapamil in five healthy subjects before and after i.v. infusion of tariquidar (2 mg/kg). Comparison of tariquidar-induced changes in distribution volumes (*DVs*) in 42 brain regions of interest (ROIs) failed to detect significant differences among brain ROIs. Statistical parametric mapping analysis of parametric *DV* images visualized symmetrical bilateral clusters with moderately higher *DV* increases in response to tariquidar administration in cerebellum, parahippocampal gyrus, olfactory gyrus, and middle temporal lobe and cortex, which might reflect moderately decreased P-gp function and expression.
Journal of Cerebral Blood Flow & Metabolism (2010) **30,** 510–515; doi:10.1038/jcbfm.2009.265; published online 16 December 2009

Keywords: blood–brain barrier; P-glycoprotein; positron emission tomography (PET); (*R*)-[^{11}C]verapamil; regional; tariquidar

Introduction

The multidrug efflux transporter P-glycoprotein (P-gp, ABCB1), which is highly expressed in the luminal endothelium of the human blood–brain barrier (BBB), limits entry into the brain for a large number of endogenous and exogenous compounds (Löscher and Potschka, 2005). Changes in cerebral P-gp function and expression are thought to be implicated in several neurologic disorders, such as epilepsy, depression, and Parkinson's and Alzheimer's disease (Löscher and Potschka, 2005). Positron emission tomography (PET) with the radiolabeled P-gp substrate (*R*)-[^{11}C]verapamil (VPM) is an appropriate method to measure P-gp function in the BBB (Lubberink *et al*, 2007). Studies using pharmacologic P-gp inhibition in rats have shown that the brain distribution volume (*DV*) of VPM is inversely related to cerebral P-gp activity (Bankstahl *et al*, 2008).

Verapamil is very effectively transported by P-gp in the BBB, thereby possessing low brain uptake, which affords low counting statistics and hampers the mapping of regional differences in cerebral P-gp function (Langer *et al*, 2007). Assessment of regional differences in cerebral P-gp function and expression is currently of high interest, as, for instance, regional overexpression of P-gp in epileptic brain tissue is thought to contribute to the phenomenon of drug resistance in epilepsy by impeding access of anti-epileptic drugs to their sites of action (Löscher and Potschka, 2005).

A promising strategy to overcome the limitation of low brain uptake of VPM is to perform VPM PET scans after P-gp modulation with P-gp inhibiting drugs, at doses that do not completely inhibit the P-gp pump. Two P-gp inhibitors have so far been used in human PET studies, cyclosporine A (Sasongko *et al*, 2005) and tariquidar (Wagner *et al*, 2009). The third-generation P-gp inhibitor tariquidar (Fox and Bates, 2007) is safer than cyclosporine A for use in human subjects and was shown to lack interactions

Correspondence: Dr O Langer, Division of Pharmacogenetics and Imaging, Department of Clinical Pharmacology, Medical University of Vienna, Währinger-Gürtel 18-20, Vienna 1090, Austria.
E-mail: oliver.langer@meduniwien.ac.at
Received 28 September 2009; revised 19 November 2009; accepted 26 November 2009; published online 16 December 2009

with metabolism and plasma protein binding of VPM (Wagner *et al*, 2009). We have previously performed paired VPM PET scans in healthy volunteers, before and after intravenous administration of tariquidar at a dose of 2 mg/kg (Wagner *et al*, 2009). Tariquidar administration was shown to result in a mean 24% increase in VPM *DV*s in whole-brain gray matter.

In this study, we assessed regional differences in tariquidar-induced modulation of VPM brain uptake, which might be indicative of regional differences in cerebral P-gp function and expression.

Materials and methods

This study was performed at the Department of Clinical Pharmacology at the Medical University of Vienna. The study protocol was approved by the local Ethics Committee. All subjects were given a detailed description of the study and their written consent was obtained before enrolment in the study. Five healthy male subjects (mean age ± s.d., 32 ± 8) were included into the study. The study was conducted as a pilot study, so no *a priori* sample size calculation was performed.

Each study participant underwent two 40-min dynamic VPM PET scans (mean injected dose: 384 ± 13 MBq) at an interval of 200 mins, and serial arterial blood sampling *via* the radial artery as described earlier (Langer *et al*, 2007). At the end of the first PET scan, tariquidar was administered at a dose of 2 mg/kg body weight as an i.v. infusion over 30 mins. For formulation, vials containing 7.5 mg/mL of tariquidar free base in 10 mL of 20% ethanol/80% propylene glycol (AzaTrius Pharmaceuticals Pvt Ltd, London, UK) were diluted with aqueous dextrose solution (5%, w/v) to yield a final volume of 250 mL. Three venous blood samples were collected at the beginning, in the middle and at the end of the second PET scan to measure plasma concentrations of tariquidar by an earlier described liquid chromatography tandem mass-spectrometry assay (Wagner *et al*, 2009). For image acquisition, PET and magnetic resonance imaging protocols as described earlier were used (Langer *et al*, 2007).

Arterial plasma samples were analyzed for polar [^{11}C]metabolites of VPM using an earlier described assay (Abrahim *et al*, 2008). An arterial input function was constructed by correcting total activity counts in arterial plasma for polar [^{11}C]metabolites of VPM as described earlier (Langer *et al*, 2007).

For data analysis, both a voxel-based parametric imaging approach and a region of interest (ROI)-based approach were used. Parametric *DV* maps were created for PET and metabolite-corrected arterial blood activity data using the *DV* (*Classic Logan Plot*) routine in PMOD v2.6 (PMOD Technologies, Ltd, Zurich, Switzerland). Parametric *DV* maps of scan 1 and 2 were analyzed by statistical parametric mapping (SPM) using a paired *t*-test. Using SPM8, *DV* maps were spatially normalized to Montreal Neurological Institute space and smoothed by a Gaussian kernel of 8 mm. For visualization, a probability threshold of $P < 0.005$ was applied.

Imaging data for ROI analysis were processed following previously published procedures (Langer *et al*, 2007). A maximum probability atlas based on 30 subjects and containing 83 regions (Hammers *et al*, 2003) was used to define 41 different brain ROIs, whereby regional data from the left and right hemispheres were averaged. In addition, the choroid plexus ROI was manually defined. A 1-tissue-2-rate-constant compartment model was used to estimate the influx and efflux rate constants of activity across the BBB. For estimation of *DV* values in different brain ROIs, Logan graphical analysis was applied to the PET and arterial plasma data (corrected for polar [^{11}C]metabolites of VPM) as described earlier (Langer *et al*, 2007).

Individual regional *DV* increase after tariquidar administration was expressed as percent increase relative to the *DV* value of the first scan in each ROI. The differences in *DV* increase in 42 ROIs were statistically evaluated for the five study participants in an analysis of variance, followed by Duncan's multiple range test for multiple comparisons. For statistical computations, the SAS System V9.2 (SAS Institute Inc, Cary, NC, USA) was used and the level of significance was set to 5%.

Limitations

In theory, regional brain uptake of VPM could become dependent on regional cerebral blood flow under conditions of P-gp modulation (Liow *et al*, 2009). These differences could bias regional differences in *DV* increases measured in scan 2 relative to scan 1. However, because VPM is a low-extraction radiotracer, even under conditions of moderate P-gp modulation as used in this study (mean influx rate constant K_1 of activity into whole brain after tariquidar administration: 0.049 ± 0.009), brain uptake of VPM can be considered to be insensitive to changes in cerebral blood flow.

Another limitation of the methodology used with regard to a possible application in epilepsy patients is the fact that the hippocampus, an important brain structure in epilepsy, could not be analyzed due to spill in of activity from the adjacent choroid plexus. However, this problem might at least partly be overcome by using higher-resolution PET cameras than in this study.

Results and discussion

Up to now only little is known about the regional distribution pattern of P-gp in the human brain. Most animal studies conducted to date have focused on describing expression levels of P-gp in epileptic brain tissue relative to nonepileptic brain tissue without comparing P-gp expression levels across different brain regions (Löscher and Potschka, 2005). In one recent study, regional brain uptake of the P-gp substrate radiotracer ^{11}C-*N*-desmethyl-loperamide was studied in monkeys following administration of a novel P-gp modulator, DCPQ, that is structurally related to zosuquidar (Liow *et al*, 2009). In that study,

regional differences in brain activity uptake were found to be entirely accounted for by regional differences in cerebral blood flow. A limitation of this study, however, was the fact that a very high dose of the P-gp inhibitor drug was used, which can be expected to completely inhibit P-gp across different brain regions as reflected by 5-fold increases in radiotracer uptake compared with baseline scans. Moreover, the high inhibitor dose administered caused radiotracer kinetics in brain to become dependent on cerebral blood flow.

In our study, we used a novel human brain imaging protocol that included the performance of paired brain PET scans with the validated P-gp probe VPM, before and after administration of a moderate dose (i.e., one that does not completely inhibit P-gp) of the third-generation P-gp inhibitor tariquidar (2 mg/kg body weight) (Wagner *et al*, 2009). The 2 mg/kg dose was chosen because this has been the maximum dose given to human subjects in earlier clinical studies (Fox and Bates, 2007). An earlier study had shown excellent (about 4% for *DV* values) test–retest variability of VPM baseline PET scans like those used in this study (Lubberink *et al*, 2007).

In rats, the half-maximum effect dose of tariquidar for increasing VPM brain *DVs* was established at 3.0 ± 0.2 mg/kg (given i.v. 2 h before the PET scan), corresponding to tariquidar plasma levels of 545 ± 30 ng/mL at the time of the PET scan (Kuntner *et al*, 2009). In rats, half-maximum and maximum P-gp inhibition resulted in about 4-fold and 10-fold increases, respectively, in VPM *DV* values as compared with baseline scans. In this study in humans, tariquidar plasma levels of 490 ± 203 ng/mL were attained at the time of the PET scan, resulting in a 1.24-fold increase in VPM *DV* values in whole brain, which can be considered to be far from complete P-gp blockade. Moreover, the different VPM *DV* increases achieved in rats and humans at similar tariquidar plasma concentrations point to pronounced species differences in tariquidar-induced cerebral P-gp inhibition or to differences in P-gp function and expression between rats and humans.

Statistical parametric mapping analysis revealed clusters that showed higher response to tariquidar treatment in terms of VPM *DV* increases in scan 2 relative to other brain regions (Figures 1A and 1B). The most pronounced differences were seen in

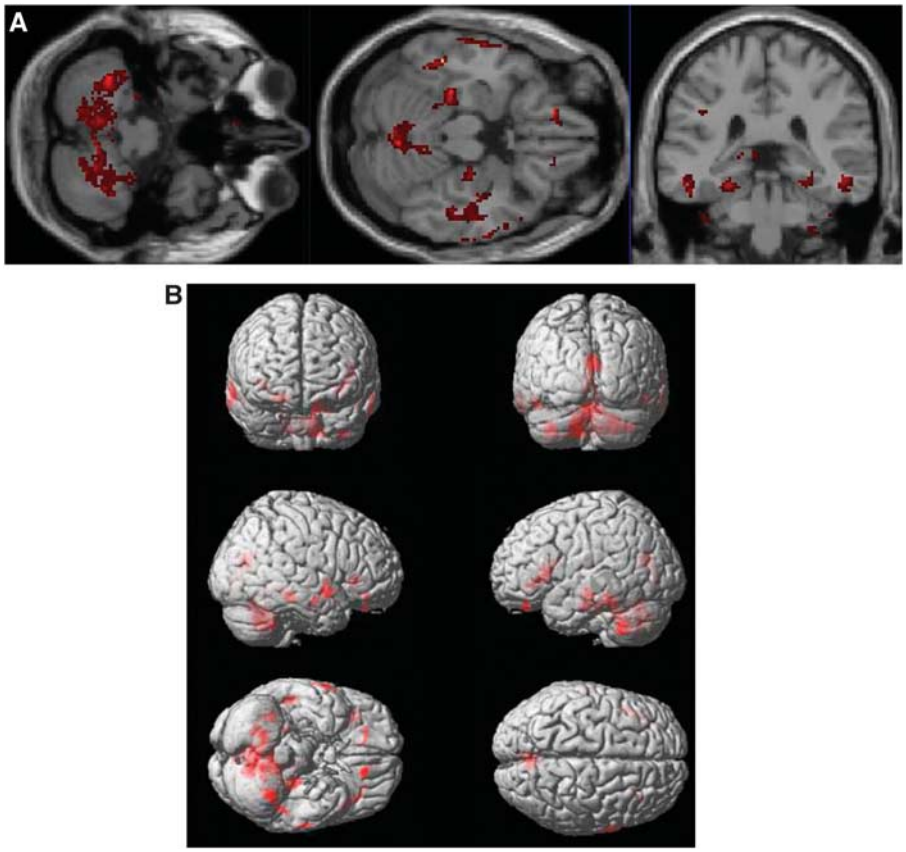

Figure 1 Axial and cortical surface rendering (**B**) of statistical parametric mapping analysis of paired comparisons of VPM *DV* maps before (scan 1) and after (scan 2) administration of the P-gp modulator tariquidar (paired *t*-test, $n = 5$). Red color indicates regions with $P < 0.005$. Merged with a normalized magnetic resonance imaging significantly higher *DV* increases in scan 2 can be located in cerebellum, temporal lobe regions (e.g., parahippocampal gyrus, middle temporal lobe and cortex) and olfactory gyrus.

cerebellum, temporal lobe regions (parahippocampal gyrus, structures in middle temporal lobe and cortex), and olfactory gyrus of the frontal lobe and were located rather symmetrically in both brain hemispheres. Statistical parametric mapping analysis of VPM *DV* maps has been reported by other investigators before (Bartels *et al*, 2009), but not for paired scans including administration of a P-gp inhibitor.

We hypothesize that an increased response to tariquidar treatment reflects lower functionality and density of P-gp. In baseline experiments (i.e., before administration of tariquidar, scan 1), *DV* values of VPM in different brain regions were very similar (Supplementary Table 1), which suggests that VPM is very effectively kept out of brain parenchyma by P-gp-mediated efflux, mostly independent of possible regional differences in P-gp function and expression. However, following administration of tariquidar at a dose that does not completely inhibit P-gp, brain regions with higher P-gp functionality/density presumably showed a lower response in terms of *DV* increases as compared with brain regions with lower P-gp functionality/density. In other words, for regions with higher P-gp functionality/density, a higher tariquidar dose may be needed to overcome the P-gp-mediated diffusion barrier as compared with regions with lower functionality/density. Regional differences in cerebral P-gp function and expression might make some brain areas more vulnerable than others to the accumulation of P-gp substrates, such as toxins and therapeutic drugs.

By using the ROI-based analysis approach with a standardized maximum probability brain atlas, time–activity curves of 42 ROIs were generated. *DV* values of scans 1 and 2 in brain ROIs of all five subjects are shown in Supplementary Table 1. In Figure 2, percent *DV* increases in scan 2 relative to scan 1 of all 5 subjects in 42 brain regions are plotted according to a rank order sorted by mean increase, where small increases are depicted on the left end and high increases on the right end of the graph. The ROI analysis identified lateral ventricle or anatomically adjacent structures (e.g., frontal horn, choroid plexus, temporal horn, corpus callosum), which showed lower *DV* increases. The different behavior of the choroid plexus and the ventricle system in response to tariquidar administration might be related to the fact that P-gp-mediated transport in the epithelium of the choroid plexus is in the opposite direction as compared with the BBB, i.e.,

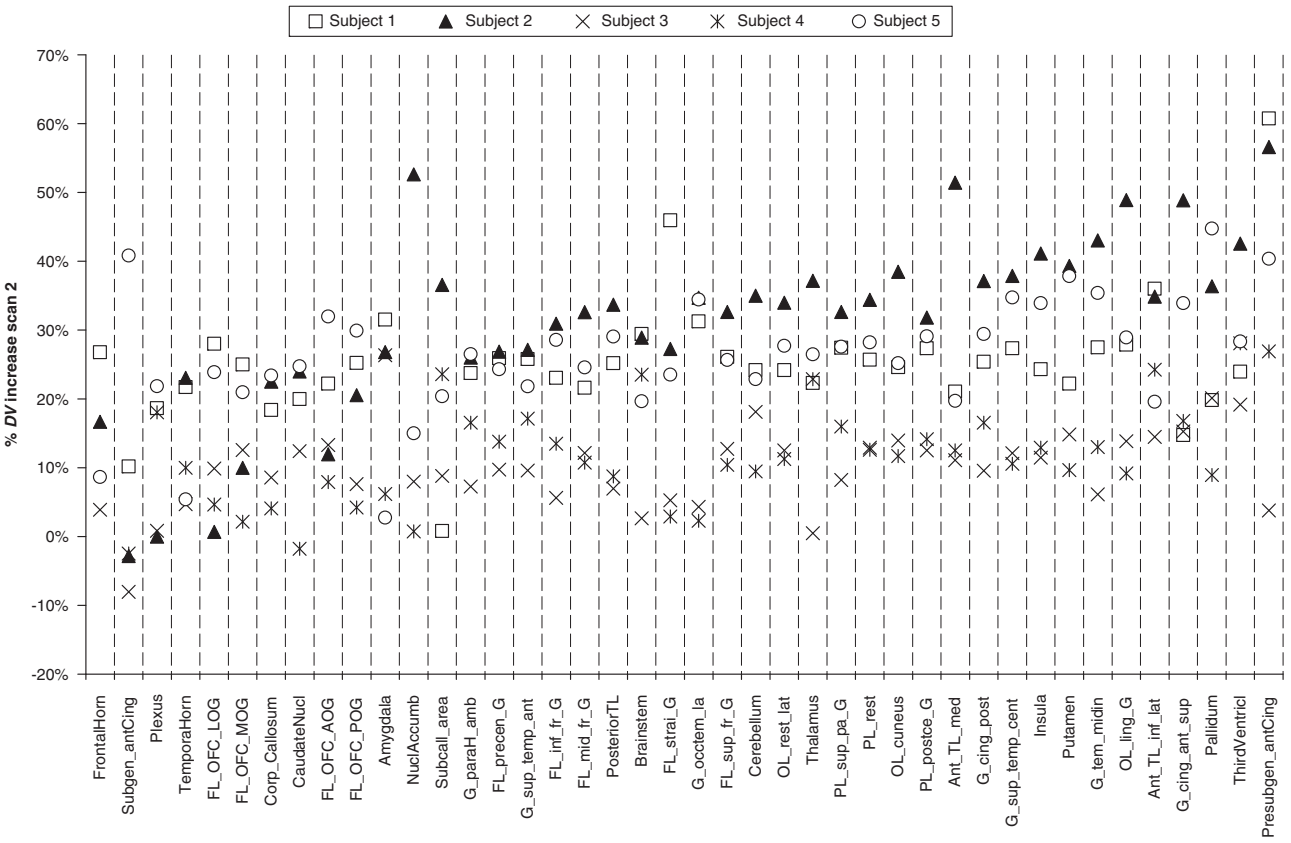

Figure 2 Plot of percent increases in VPM *DV*s after tariquidar administration (scan 2) in individual subjects in 42 different brain ROIs. Regions with small increases are depicted on the left end of the graph and ROIs with large increases are on the right end of the graph. Full ROI names are given in Supplementary Table 2.

from blood into cerebral spinal fluid (de Lange, 2004). Structures forming the basal ganglia (putamen, pallidum, most parts of the gyrus cinguli) showed higher *DV* increases after P-gp modulation indicating lower P-gp functionality/density. However, statistically different *DV* increases were detected in none of the analyzed ROIs (analysis of variance).

The different results of ROI analysis and SPM analysis might be related to the fact that (1) only parts of individual brain ROIs displayed moderately higher *DV* increases as shown by SPM analysis and (2) there is considerable interindividual variability in *DV* changes. Part of this interindividual variability might be related to different tariquidar plasma levels and hence different degrees of P-gp inhibition in individual subjects. Tariquidar plasma levels during the second PET scan (mean ± s.d. of three time points per subject) were 410 ± 124, 821 ± 132, 493 ± 105, 272 ± 56, and 456 ± 10 ng/mL for subjects 1, 2, 3, 4, and 5, respectively. We had shown before that the *DV* increases seen in the second PET scan were positively correlated with tariquidar plasma exposure in individual subjects (Wagner *et al*, 2009). However, when *DV* increases in individual subjects were weighted by the area under the concentration–time curve of tariquidar in plasma (data not shown), differences between brain ROIs were still not statistically different.

Overall, our data point to only moderate, if any, regional differences in P-gp function and expression in the healthy human brain, which might be related to a lack of up-regulation of the ABCB1 gene in response to cellular stress triggered by drugs, toxins, or environmental factors (Löscher and Potschka, 2005). In patients, on the other hand, regional transporter expression may be markedly increased, which has been shown for patients with medically intractable epilepsy (Löscher and Potschka, 2005). The setting used in this study might be better suited than VPM baseline scans alone to studying regional differences in cerebral P-gp function and expression in such patients.

Acknowledgements

The research leading to these results has received funding from the European Community's Seventh Framework Programme (FP7/2007-2013) under grant agreement number 201380 (Euripides) and from the Austrian Science Fund (FWF) project 'Transmembrane Transporters in Health and Disease' (SFB F35). This study would not have been possible without the excellent support of Rainer Bartosch (Department of Nuclear Medicine), Edith Lackner, Johann Stanek, and Richard Schwameis (Department of Clinical Pharmacology), and Thomas Foki (Department of Neurology). The authors thank Alexander Hammers from the MRC Clinical Sciences Centre (London, UK), and Marie-Claude Asselin and Rainer Hinz from the Wolfson Molecular Imaging Centre (Manchester, UK) for providing help in establishing the brain atlas analysis approach. Divya Maheshwari from AzaTrius Pharmaceuticals Pvt Ltd (London, UK) is gratefully acknowledged for providing vials of tariquidar for i.v. infusion.

Conflict of interest

The authors declare no conflict of interest.

References

Abrahim A, Luurtsema G, Bauer M, Karch R, Lubberink M, Pataraia E, Joukhadar C, Kletter K, Lammertsma AA, Baumgartner C, Müller M, Langer O (2008) Peripheral metabolism of (*R*)-[^{11}C]verapamil in epilepsy patients. *Eur J Nucl Med Mol Imaging* 35:116–23

Bankstahl JP, Kuntner C, Abrahim A, Karch R, Stanek J, Wanek T, Wadsak W, Kletter K, Müller M, Löscher W, Langer O (2008) Tariquidar-induced P-glycoprotein inhibition at the rat blood-brain barrier studied with (*R*)-^{11}C-verapamil and PET. *J Nucl Med* 49:1328–35

Bartels AL, Kortekaas R, Bart J, Willemsen AT, de Klerk OL, de Vries JJ, van Oostrom JC, Leenders KL (2009) Blood-brain barrier P-glycoprotein function decreases in specific brain regions with aging: a possible role in progressive neurodegeneration. *Neurobiol Aging* 30: 1818–24

de Lange EC (2004) Potential role of ABC transporters as a detoxification system at the blood-CSF barrier. *Adv Drug Deliv Rev* 56:1793–809

Fox E, Bates SE (2007) Tariquidar (XR9576): a P-glycoprotein drug efflux pump inhibitor. *Expert Rev Anticancer Ther* 7:447–59

Hammers A, Allom R, Koepp MJ, Free SL, Myers R, Lemieux L, Mitchell TN, Brooks DJ, Duncan JS (2003) Three-dimensional maximum probability atlas of the human brain, with particular reference to the temporal lobe. *Hum Brain Mapp* 19:224–47

Kuntner C, Bankstahl JP, Bankstahl M, Stanek J, Wanek T, Stundner G, Karch R, Brauner R, Meier M, Ding XQ, Müller M, Löscher W, Langer O (2009) Dose-response assessment of tariquidar and elacridar and regional quantification of P-glycoprotein inhibition at the rat blood-brain barrier using (*R*)-[^{11}C]verapamil PET. *Eur J Nucl Med Mol Imaging* (in press)

Langer O, Bauer M, Hammers A, Karch R, Pataraia E, Koepp MJ, Abrahim A, Luurtsema G, Brunner M, Sunder-Plassmann R, Zimprich F, Joukhadar C, Gentzsch S, Dudczak R, Kletter K, Müller M, Baumgartner C (2007) Pharmacoresistance in epilepsy: a pilot PET study with the P-glycoprotein substrate *R*-[^{11}C]verapamil. *Epilepsia* 48:1774–84

Liow JS, Kreisl W, Zoghbi SS, Lazarova N, Seneca N, Gladding RL, Taku A, Herscovitch P, Pike VW, Innis RB (2009) P-glycoprotein function at the blood-brain barrier imaged using ^{11}C-N-desmethyl-loperamide in monkeys. *J Nucl Med* 50:108–15

Löscher W, Potschka H (2005) Role of drug efflux transporters in the brain for drug disposition and treatment of brain diseases. *Prog Neurobiol* 76:22–76

Lubberink M, Luurtsema G, van Berckel BN, Boellaard R, Toornvliet R, Windhorst AD, Franssen EJ, Lammertsma

AA (2007) Evaluation of tracer kinetic models for quantification of P-glycoprotein function using (*R*)-[^{11}C]verapamil and PET. *J Cereb Blood Flow Metab* 27:424–33

Sasongko L, Link JM, Muzi M, Mankoff DA, Yang X, Collier AC, Shoner SC, Unadkat JD (2005) Imaging P-glycoprotein transport activity at the human blood-brain barrier with positron emission tomography. *Clin Pharmacol Ther* 77:503–14

Wagner CC, Bauer M, Karch R, Feurstein T, Kopp S, Chiba P, Kletter K, Löscher W, Müller M, Zeitlinger M, Langer O (2009) A pilot study to assess the efficacy of tariquidar to inhibit P-glycoprotein at the human blood-brain barrier with (*R*)-^{11}C-verapamil and PET. *J Nucl Med* 50:1954–61

Supplementary Information accompanies the paper on the Journal of Cerebral Blood Flow & Metabolism website (http://www.nature.com/jcbfm)