

Published in final edited form as:

Curr Opin Allergy Clin Immunol. 2010 October ; 10(5): 505–510. doi:10.1097/ACI.0b013e32833df9f4.

Pathogenic role of *Demodex* mites in blepharitis

Jingbo Liu^{a,b}, Hosam Sheha^a, and Scheffer C.G. Tseng^a

^aOcular Surface Center, and Ocular Surface Research & Education Foundation, Miami, Florida, USA

^bEye Hospital, Wenzhou Medical College, Wenzhou, Zhejiang, China

Abstract

Purpose of review—To summarize the key literature and our research experience regarding *Demodex* infestation as a potential cause of ocular inflammatory diseases with a special emphasis on *Demodex* blepharitis.

Recent findings—Two distinct *Demodex* species have been confirmed as a cause of blepharitis: *Demodex folliculorum* can cause anterior blepharitis associated with disorders of eyelashes, and *D. brevis* can cause posterior blepharitis with meibomian gland dysfunction and keratoconjunctivitis. Tea tree oil treatments with either 50% lid scrubs or 5% lid massages are effective in eradicating mites and reducing ocular surface inflammation.

Summary—*Demodex* blepharitis is a common but overlooked external eye disease. The pathogenesis of *Demodex* blepharitis in eliciting ocular surface inflammation has been further clarified. The modified eyelash sampling and counting method makes it easier and more accurate to diagnose *Demodex* infestation. Tea tree oil shows promising potential to treat *Demodex* blepharitis by reducing *Demodex* counts with additional antibacterial, antifungal, and anti-inflammatory actions.

Keywords

blepharitis; *Demodex* mites; meibomian gland dysfunction; ocular surface inflammation; tea tree oil

Introduction

Demodex mites are the most common microscopic ectoparasite found in the human skin. The rate of *Demodex* infestation increases with age, being observed in 84% of the population at age 60 and in 100% of those older than 70 years [1]. Apart from its higher density in patients with rosacea [2–5], *Demodex* mites have also been suggested as a cause of other skin diseases such as pityriasis folliculorum, perioral dermatitis [6], scabies-like eruptions, facial pigmentation, eruptions of the bald scalp, demodicosis gravis, and even basal cell carcinoma [7]. Because the eye is surrounded by such protruding body parts as the nose, the brow, and the cheek, the eyelid is not as accessible as the face to daily cleansing hygiene. Therefore, once *Demodex* infestation establishes in the face, it is likely to spread and flourish in the eyelids leading to blepharitis [8–11]. Despite this, the clinical significance of *Demodex* infestation remains debatable in part because it can be found in asymptomatic subjects. As a result, *Demodex* blepharitis is often overlooked in differential diagnosis of corneal and external diseases let alone therapeutic options are considered. Herein, we would like to summarize the

key literature and our research experience regarding the pathogenic potential of *Demodex* mites in causing ocular surface inflammation with a special emphasis on blepharitis.

Life of *Demodex* mites in human

Two distinct species have been identified in human: *Demodex folliculorum* and *D. brevis* (Fig. 1). In the eyelids, *D. folliculorum* can be found in the lash follicle, whereas *D. brevis* burrows deep into sebaceous glands and meibomian glands looking for sebum which is thought to be their main food source. It has also been proposed that these mites might feed on follicular and glandular epithelial cells leading to direct damage of the lid margin. The life cycle of the *Demodex* mite is approximately 14–18 days from the egg to the larval stage followed by 5 days in the adult stage. Females may live an additional 5 days after oviposition [12]. Because of the limited life span of the adult mites, mating plays an important role in perpetuating *Demodex* infestation. Furthermore, *Demodex*'s life span is limited outside the living body, thus, direct contact is required for transmission of mites. Accordingly, it is important to prevent mating of mites and avoid direct transmission as an indispensable treatment strategy.

Risk factors of *Demodex* blepharitis

Recently, we have demonstrated a close correlation between the severity of rosacea and *Demodex* blepharitis [13••]. Rosacea predisposes patients to blepharitis mainly by creating an environment on the skin that congests all the oil-producing glands necessary for a healthy dermis and epidermis. Other factors may change the environment to encourage mites' proliferation, such as the skin phototype, sunlight exposure, alcohol intake, smoking, stress, hot beverages, spicy food, and abrupt changes in temperature [14,15]. Because of the anatomic feature of the face, eyelids are not accessible to routine cleansing hygiene providing a favorable environment for *Demodex* mites to spread and flourish. Infestation of *Demodex* mites is prone to develop in patients whose local or systemic immune status is compromised by topical or systemic administration of steroids or other immunosuppressive agents or by diseases such as leukemia and HIV [16].

Pathogenesis

Demodex blepharitis can be divided anatomically into anterior and posterior blepharitis. The former refers to infestation of eyelashes and follicles by *D. folliculorum*, clustering to the root of the lashes, whereas the latter involves infestation of the meibomian gland preferentially by *D. brevis*. The following action mechanisms have been proposed to explain the pathogenic role of *Demodex* in blepharitis.

Direct damage

Demodex mites, especially *folliculorum*, consume epithelial cells at the hair follicle resulting in follicular distention, which may contribute to formation of loose or misdirected lashes. Micro-abrasions caused by the mite's claws can induce epithelial hyperplasia and reactive hyperkeratinization around the base of the lashes, forming cylindrical dandruff [17,18]. On the other hand, *D. brevis* can mechanically block the orifices of meibomian glands, giving rise to meibomian gland dysfunction with lipid tear deficiency [19]. *D. brevis* usually burrows deep into the meibomian glands and its chitinous exoskeleton may act as a foreign body causing granulomatous reaction. *D. brevis* has been observed in the center of meibomian granulomas, surrounded by epithelioid cells, histocytes fibroblasts, lymphocytes, and plasma cells [20,21]. Thus, *Demodex* mites may be a potential cause of recurrent and refractory chalazia.

Vector for bacteria

Demodex mite can cause blepharitis by carrying bacteria on its surface including *Streptococci* and *Staphylococci*. Superantigens produced by these bacteria are also implicated in the induction of rosacea [22]. In addition, bacterium inside *Demodex* mites has been found important to trigger the host immune reaction. *Bacillus oleronius*, which was recently detected inside *Demodex* mites, can stimulate proliferation of peripheral blood mononuclear cells in patients with rosacea [23]. Our collaborative and prospective study further disclosed a strong correlation among positive serum immunoreactivity to the 83-kDa and 62-kDa *bacillus* proteins, ocular *Demodex* infestation, facial rosacea, and blepharitis [13••]. Even the dying mites in the follicles or glands may increase the release of these two bacterial antigens loading to a critical level to trigger a cascade of host inflammatory responses [18].

Hypersensitivity reaction

The protein inside the *Demodex* mites as mentioned above, and their debris or wastes may elicit host's inflammatory responses via a delayed hypersensitivity or an innate immune response [18]. By studying 92 consecutive cases of papulopustular rosacea and 92 age- and sex-matched controls, Georgala *et al.* [5] found that hair follicle infestation was associated with intense perifollicular infiltrate of predominantly (90–95%) CD4 helper or inducer T cells. An increased number of macrophages and Langerhans cells were observed only in those subjects with a positive *D. folliculorum* finding.

Clinical manifestation

The main symptoms are itching, burning, foreign body sensation, crusting and redness of the lid margin, and blurry vision. Signs include cylindrical dandruff, disorders of eyelashes, lid margin inflammation, meibomian gland dysfunction, blepharoconjunctivitis, and blepharokeratitis.

Disorders of eyelashes

In addition to cylindrical dandruff found in *Demodex* blepharitis (Fig. 2a), persistent infestation of the lash follicles may lead to malalignment, trichiasis or madarosis (Fig. 2b). Trichiasis may induce trauma to the corneal epithelium causing punctate epithelial erosions followed by corneal ulceration and pannus formation in severe longstanding cases.

Meibomian gland dysfunction

Blockage of the meibomian gland orifice may lead to filling, swelling, and much enlarged glands (a cyst) or even infection which prevents the spread of the lipid over the tear film [19] (Fig. 2c). Furthermore, granulomatous responses in meibomian glands may lead to hordeolum or chalazion. In order to detect the changes in the time and pattern of lipid spread and stability of resultant lipid thickness, DR1 that detects the tear interference images can be used in patients with meibomian gland dysfunction. Our previous study showed that vertical streaking was obvious in eyes with lipid tear deficiency dry eye, where the lipid layer is much thinner and the spreading time is delayed [19,24].

Lid margin inflammation

The mechanical blockage and the delayed host immune hypersensitive reaction can result in the severe lid margin inflammation. Our previous study [13••] has already shown that there is a close correlation between facial rosacea and lid margin inflammation. Therefore, infrared photography can be used to proportionally correlate the skin temperature with the severity of inflammation caused by *Demodex* infestation, demonstrating 'fire-red' *Demodex* face [19].

Conjunctival inflammation

Without proper hygiene, lid margin inflammation (Fig. 2d) may spread over to the conjunctiva producing a condition known as blepharoconjunctivitis (Fig. 2e). This misdiagnosed *Demodex*-related conjunctivitis is usually refractory to conventional medications.

Our clinical experience reveals that successful treatment of ocular demodicosis resolves blepharoconjunctivitis in adults when traditional therapies have failed [19,25]. Although *Demodex* has been implicated as a potential cause of blepharoconjunctivitis in adults [8,10,11,19,25,26], its role in children remains unclear. Recently, we reported ocular demodicosis in 12 healthy pediatric patients with a history of recurrent blepharoconjunctivitis refractory to conventional treatments. All patients had notable conjunctivitis as evidenced by redness involving bulbar conjunctiva and papillary follicular reaction involving the tarsal conjunctiva [27]. Using the lid scrubs or massage to eradicate mites, all patients showed dramatic resolution of ocular irritation and inflammation but *Demodex* counts dropped. These results suggest that demodicosis may be an over-looked cause of refractory pediatric blepharoconjunctivitis.

Corneal manifestation

Inflammation derived from the lid margin, especially meibomian glands, may also spread to the cornea, depending on its severity. *Demodex* infestation may cause various sight threatening corneal lesions including superficial corneal vascularization, marginal infiltration, a phlyctenule-like lesion, superficial opacity, and nodular scar [19,25] (Fig. 2f). Interestingly, *D. brevis* is more often associated with such corneal manifestation although the chance of detecting *D. brevis*, normally thought to reside singly in the sebaceous and meibomian glands, in epilated lashes is rather rare in the general patient population. Future studies are needed to determine whether such an unusually high infestation rate of *D. brevis* may play a causative role in inducing these corneal manifestations.

Diagnosis

The potential criteria for diagnosis of *Demodex* blepharitis are summarized below:

1. Clinical history: high index of suspicion when blepharitis, conjunctivitis or keratitis in adult patients or blepharoconjunctivitis or recurrent chalazia in young patients are refractory to conventional treatments, or when there is madarosis or recurrent trichiasis.
2. Slit-lamp examination: typical cylindrical dandruff at the root of eyelashes.
3. Microscopic confirmation: detection and counting of *Demodex* eggs, larvae and adult mites in epilated lashes.

Previously, there had been argument regarding whether cylindrical dandruff in eyelashes, a common finding in some patients with blepharitis, is pathognomonic of *Demodex* infestation or not. Our previous study has provided strong evidence to support that prior controversy has resulted from random lash epilation and miscounting. Using a modified sampling and counting method, we show that eyelashes with cylindrical dandruff indeed have significantly higher *Demodex* infestation [17].

In brief, under a slit-lamp microscope at a magnification of $\times 25$, two lashes, one from each half of each lid, are removed by fine forceps and placed separately on each end of glass slides. A coverslip is mounted onto each lash before slowly pipetting 20 μ l of saline to the edge of the coverslip to surround the lash. This maneuver results in preservation of the *Demodex* that has a loose contact with the lash at the tip. Under the microscope, the number of *Demodex* is counted in a conventional manner. If a compacted cylindrical dandruff is preserved, 20 μ l of

100% alcohol or 0.25% fluorescein drops is pipetted into the edge of the coverslip, and the counting time is prolonged up to 20 min to allow the embedded *Demodex* to migrate from the cylindrical dandruff (Fig. 3) [28].

Treatment regimen

Various treatments have been used to control *Demodex* mites such as mercury oxide 1% ointment, pilocarpine gel, sulfur ointment, and camphorated oil. Most of them involve spreading an ointment at the base of the eyelashes at night to trap mites as they emerge from their burrow and/or move from one follicle to another. However, using an in-vitro microscopic observation for a period of 150 min, we found that adult *D. folliculorum* is resistant to a wide range of common antiseptic solutions including 75% alcohol and 10% povidone-iodine, and such antimicrobials as erythromycin and metronidazole but can dose-dependently be killed by tea tree oil (TTO) [29]. Unlike Baby shampoo, lid scrub with TTO not only cleanses cylindrical dandruff from the lash root but also stimulates embedded mites to migrate out to the skin. As a result, daily lid scrub with 50% TTO and lid massage with 5% TTO ointment are effective in eradicating ocular *Demodex* infestation *in vivo*, as evidenced by bringing the *Demodex* count down to zero in 4 weeks in a majority of patients [19,25,30] (Fig. 4). The two treatments were equally effective in eradicating mites although we presume they may act differently. The 50% TTO has direct killing effect on the mites, whereas the 5% may interrupt their life cycle by preventing mating. Apart from *Demodex* eradication, TTO treatments resulted in dramatic alleviation of symptoms and marked resolution of inflammation in the lid margin, conjunctiva, and cornea [19]. Because TTO also may exert antibacterial [25,31,32] antifungal [33-37], and anti-inflammatory actions [38,39], we cannot attribute its therapeutic benefit in treating the above eye diseases solely to its effect of killing mites. As the *Demodex* also serves as the vector of the skin organisms, the comorbidity based on a symbiotic relationship of *B. oleronius* in *Demodex* mites also justifies the consideration of a therapeutic strategy directed to killing the symbiotic bacterium via oral antibiotics such as tetracycline.

Conclusion

Demodex mite plays an important role in the occurrence of a series of ocular surface diseases such as *Demodex* blepharitis, meibomian gland dysfunction, conjunctival inflammation, and corneal lesions. Ocular infestation has a close relationship with the systemic infestation. Further studies are needed for developing easy and sensitive diagnostic methods and more effective and specific treating regimens.

Acknowledgments

A part of the studies described in this article is supported by a research grant 1R43 EY019586-01 from National Institutes of Health, National Eye Institute. The content is solely the responsibility of the authors and does not necessarily represent the official views of the National Institutes of Health.

References and recommended reading

Papers of particular interest, published within the annual period of review, have been highlighted as:

- of special interest
- of outstanding interest

Additional references related to this topic can also be found in the Current World Literature section in this issue (p. 514).

1. Post CF, Juhlin E. *Demodex folliculorum* and blepharitis. Arch Dermatol 1963;88:298–302. [PubMed: 14043622]
2. Basta-Juzbasic A, Subic JS, Ljubojevic S. *Demodex folliculorum* in development of dermatitis rosaceiformis steroidica and rosacea-related diseases. Clin Dermatol 2002;20:135–140. [PubMed: 11973047]
3. Erbagci Z, Ozgoztasi O. The significance of *Demodex folliculorum* density in rosacea. Int J Dermatol 1998;37:421–425. [PubMed: 9646125]
4. Forton F, Germaux MA, Brasseur T, et al. Demodicosis and rosacea: epidemiology and significance in daily dermatologic practice. J Am Acad Dermatol 2005;52:74–87. [PubMed: 15627084]
5. Georgala S, Katoulis AC, Kylafis GD, et al. Increased density of *Demodex folliculorum* and evidence of delayed hypersensitivity reaction in subjects with papulopustular rosacea. J Eur Acad Dermatol Venereol 2001;15:441–444. [PubMed: 11763386]
6. Morras PG, Santos SP, Imedio IL, et al. Rosacea-like demodicidosis in an immunocompromised child. Pediatr Dermatol 2003;20:28–30. [PubMed: 12558842]
7. Erbagci Z, Erbagci I, Erkilic S. High incidence of demodicidosis in eyelid basal cell carcinomas. Int J Dermatol 2003;42:567–571. [PubMed: 12839614]
8. Kamoun B, Fourati M, Feki J, et al. Blepharitis due to *Demodex*: myth or reality? J Fr Ophtalmol 1999;22:525–527. [PubMed: 10417910]
9. Humiczewska M. *Demodex folliculorum* and *Demodex brevis* (Acarida) as the factors of chronic marginal blepharitis. Wiad Parazytol 1991;37:127–130. [PubMed: 1823473]
10. Coston TO. *Demodex folliculorum* blepharitis. Trans Am Ophthalmol Soc 1967;65:361–392. [PubMed: 4229846]
11. Heacock CE. Clinical manifestations of demodicosis. J Am Optom Assoc 1986;57:914–919. [PubMed: 3794168]
12. Ruffli T, Mumcuoglu Y. The hair follicle mites *Demodex folliculorum* and *Demodex brevis*: biology and medical importance: a review. Dermatologica 1981;162:1–11. [PubMed: 6453029]
- 13•. Li J, O'Reilly N, Sheha H, et al. Correlation between ocular *Demodex* infestation and serum immunoreactivity to bacillus proteins in patients with facial rosacea. Ophthalmology 2010;117:870–877. [PubMed: 20079929] . Shedding light on a novel diagnostic technique.
14. Wilkin JK. Oral thermal-induced flushing in erythematotelangiectatic rosacea. J Invest Dermatol 1981;76:15–18. [PubMed: 6450809]
15. Bernstein JE. Rosacea flushing. Int J Dermatol 1982;21:24. [PubMed: 6460713]
16. Kulac M, Ciftci IH, Karaca S, Cetinkaya Z. Clinical importance of *Demodex folliculorum* in patients receiving phototherapy. Int J Dermatol 2008;47:72–77. [PubMed: 18173609]
17. Gao Y-Y, Di Pascuale MA, Li W, et al. High prevalence of ocular *Demodex* in lashes with cylindrical dandruffs. Invest Ophthalmol Vis Sci 2005;46:3089–3094. [PubMed: 16123406]
18. Bevins CL, Liu FT. Rosacea: skin innate immunity gone awry? Nat Med 2007;13:904–906. [PubMed: 17680001]
19. Gao YY, Di Pascuale MA, Elizondo A, Tseng SC. Clinical treatment of ocular demodecosis by lid scrub with tea tree oil. Cornea 2007;26:136–143. [PubMed: 17251800]
20. English FP, Cohn D, Groeneveld ER. Demodectic mites and chalazion. Am J Ophthalmol 1985;100:482–483. [PubMed: 3898856]
21. Koksai M, Kargi S, Taysi BN, Ugurbas SH. A rare agent of chalazion: demodectic mites. Can J Ophthalmol 2003;38:605–606. [PubMed: 14740805]
22. Wolf R, Ophir J, Avigad J, et al. The hair follicle mites (*Demodex* spp.). Could they be vectors of pathogenic microorganisms? Acta Derm Venereol 1988;68:535–537. [PubMed: 2467494]
23. Lacey N, Delaney S, Kavanagh K, Powell FC. Mite-related bacterial antigens stimulate inflammatory cells in rosacea. Br J Dermatol 2007;157:474–481. [PubMed: 17596156]
24. Goto E, Tseng SC. Kinetic analysis of tear interference images in aqueous tear deficiency dry eye before and after punctal occlusion. Invest Ophthalmol Vis Sci 2003;44:1897–1905. [PubMed: 12714621]
25. Kheirkhah A, Casas V, Li W, et al. Corneal manifestations of ocular *Demodex* infestation. Am J Ophthalmol 2007;143:743–749. [PubMed: 17376393]

26. Turk M, Ozturk I, Sener AG, et al. Comparison of incidence of *Demodex folliculorum* on the eyelash follicle in normal people and blepharitis patients. *Turkiye Parazitol Derg* 2007;31:296–297. [PubMed: 18224620]
27. Liang L, Safran S, Gao Y-Y, et al. Ocular demodicosis as a potential cause of pediatric blepharoconjunctivitis. *Cornea*. in press.
28. Kheirkhah A, Blanco G, Casas V, Tseng SC. Fluorescein dye improves microscopic evaluation and counting of *Demodex* in blepharitis with cylindrical dandruff. *Cornea* 2007;26:697–700. [PubMed: 17592319]
29. Gao Y-Y, Di Pascuale MA, Li W, et al. In vitro and in vivo killing of ocular *Demodex* by tea tree oil. *Br J Ophthalmol* 2005;89:1468–1473. [PubMed: 16234455]
30. Messager S, Hammer KA, Carson CF, Riley TV. Assessment of the antibacterial activity of tea tree oil using the European EN 1276 and EN 12054 standard suspension tests. *J Hosp Infect* 2005;59:113–125. [PubMed: 15620445]
31. Edwards-Jones V, Buck R, Shawcross SG, et al. The effect of essential oils on methicillin-resistant *Staphylococcus aureus* using a dressing model. *Burns* 2004;30:772–777. [PubMed: 15555788]
32. Halcon L, Milkus K. *Staphylococcus aureus* and wounds: a review of tea tree oil as a promising antimicrobial. *Am J Infect Control* 2004;32:402–408. [PubMed: 15525915]
33. Oliva B, Piccirilli E, Ceddia T, et al. Antimycotic activity of *Melaleuca alternifolia* essential oil and its major components. *Lett Appl Microbiol* 2003;37:185–187. [PubMed: 12859665]
34. Gupta AK, Nicol K, Batra R. Role of antifungal agents in the treatment of seborrheic dermatitis. *Am J Clin Dermatol* 2004;5:417–422. [PubMed: 15663338]
35. Hammer KA, Carson CF, Riley TV. Antifungal effects of *Melaleuca alternifolia* (tea tree) oil and its components on *Candida albicans*, *Candida glabrata* and *Saccharomyces cerevisiae*. *J Antimicrob Chemother* 2004;53:1081–1085. [PubMed: 15140856]
36. Martin KW, Ernst E. Herbal medicines for treatment of fungal infections: a systematic review of controlled clinical trials. *Mycoses* 2004;47:87–92. [PubMed: 15078424]
37. Hammer KA, Carson CF, Riley TV. Antifungal activity of the components of *Melaleuca alternifolia* (tea tree) oil. *J Appl Microbiol* 2003;95:853–860. [PubMed: 12969301]
38. Caldefie-Chezet F, Guerry M, Chalchat JC, et al. Anti-inflammatory effects of *Melaleuca alternifolia* essential oil on human polymorphonuclear neutrophils and monocytes. *Free Radic Res* 2004;38:805–811. [PubMed: 15493453]
39. Carson CF, Riley TV. Safety, efficacy and provenance of tea tree (*Melaleuca alternifolia*) oil. *Contact Dermatitis* 2001;45:65–67. [PubMed: 11553113]

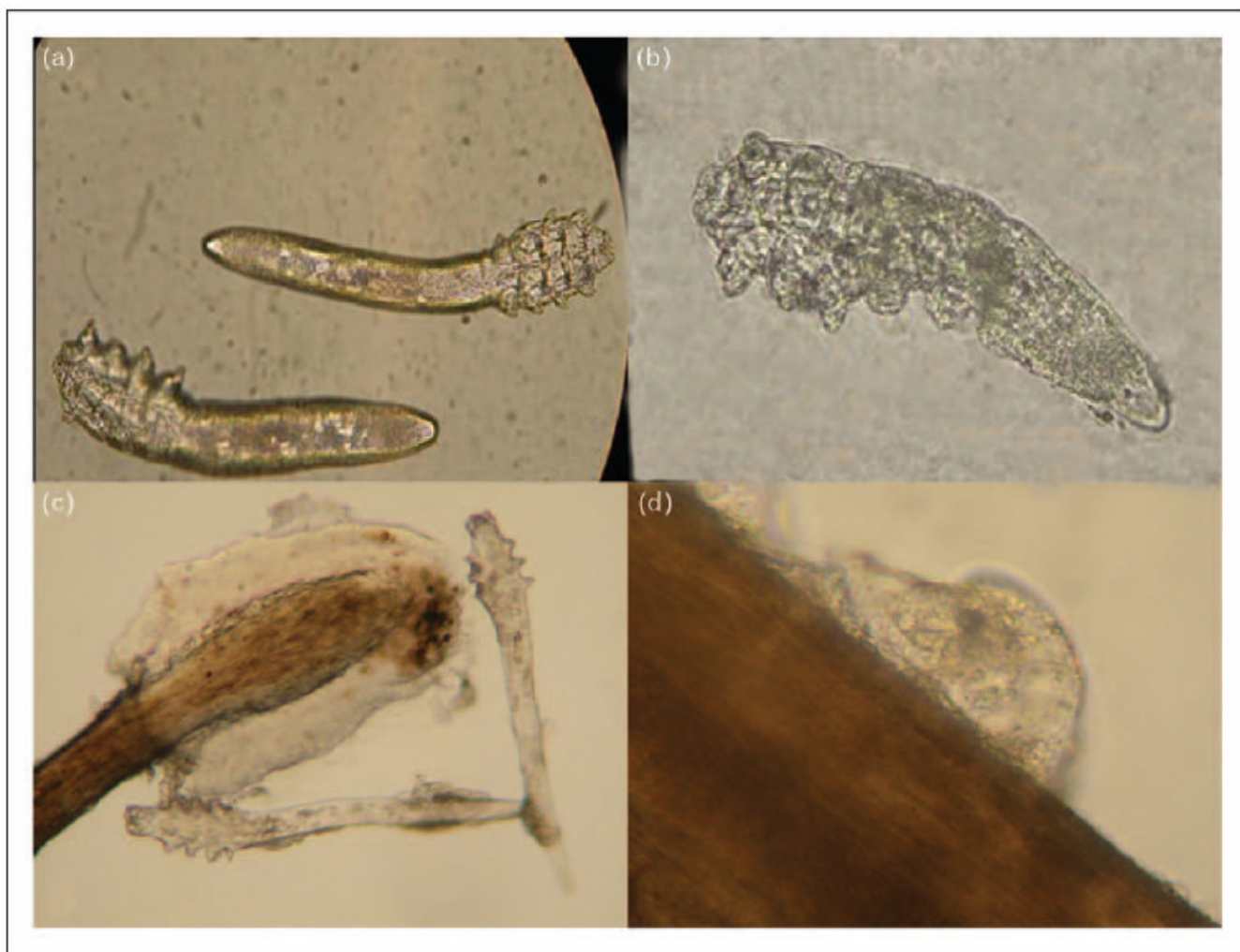


Figure 1. Microscopic photograph of *Demodex* mites
Demodex folliculorum (a), *Demodex brevis* (b), *Demodex* larva with three pairs of poorly developed legs (c) and *Demodex* egg (d).

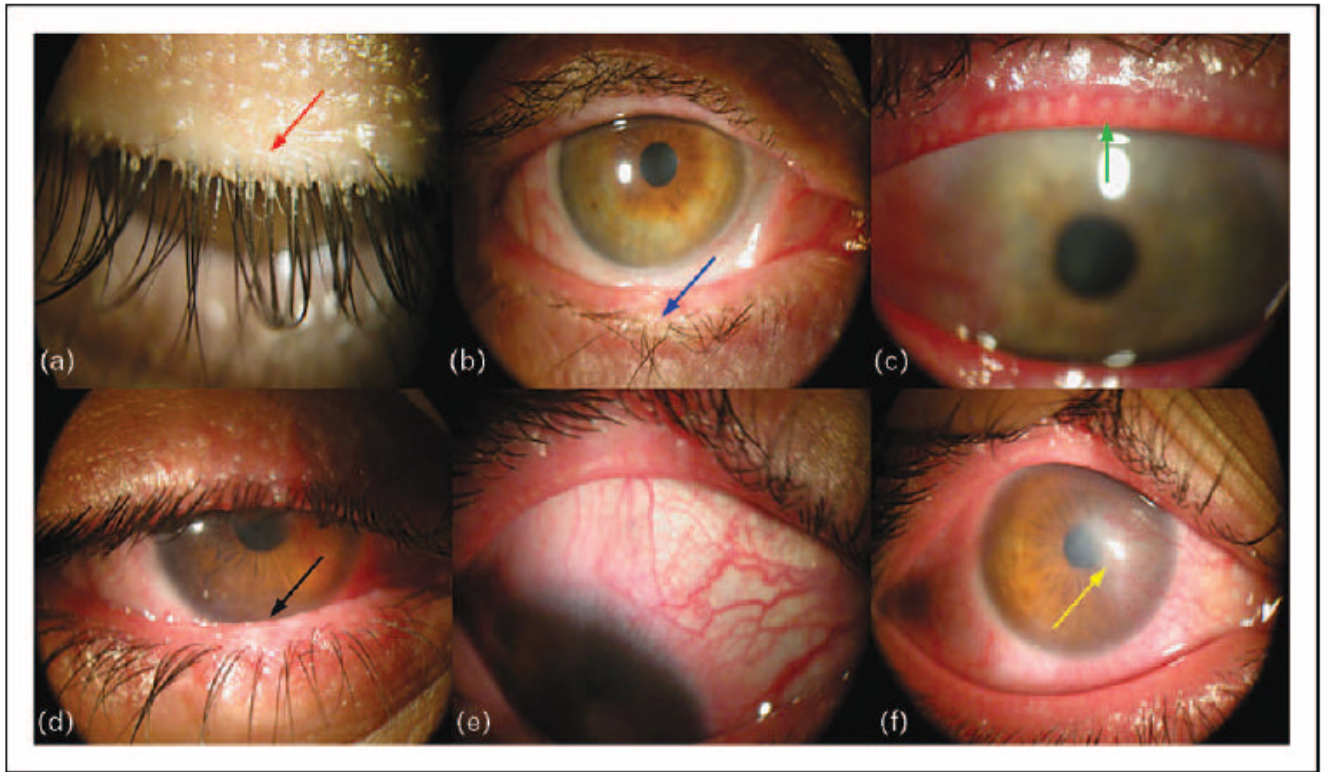


Figure 2. Ocular manifestations of *Demodex* infestation

Photographs demonstrating the typical cylindrical dandruff at the root of the eyelashes (a, red arrow); misdirected lashes (b, blue arrow); meibomian gland dysfunction (c, green arrow); lid margin inflammation (d, black arrow); bulbar conjunctiva inflammation (e); corneal infiltration and pannus (f, yellow arrow).




Figure 3. Microscopic examination of lashes

Obscured Demodex mites in a compact dandruff (a, green arrows) were easily detected after adding 0.25% fluorescein solution (b, blue arrows). Reproduced from [28].

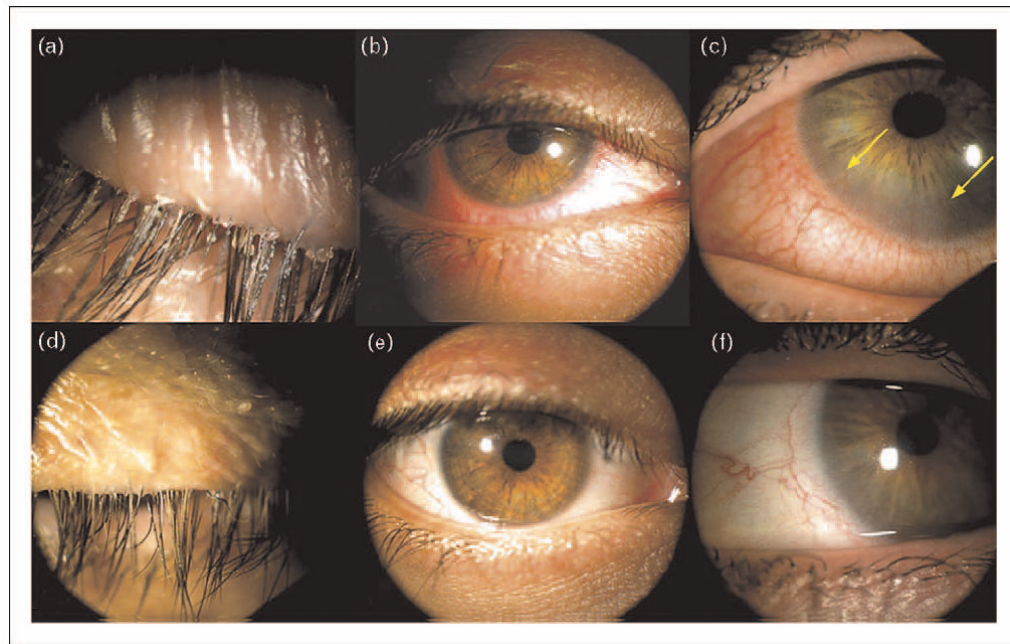


Figure 4. Photographs before and after TTO treatments

Cylindrical dandruff (a), lid margin inflammation and bulbar conjunctival injection (b) and marginal corneal vascularization (c; yellow arrows) were resolved with TTO regimen (d–f), respectively. Reproduced from [25].