

# Anteromedial portal versus transtibial drilling techniques in ACL reconstruction: a blinded cross-sectional study at two- to five-year follow-up

Eduard Alentorn-Geli · Gonzalo Samitier ·  
Pedro Álvarez · Gilbert Steinbacher · Ramón Cugat

Received: 9 January 2010 / Revised: 5 March 2010 / Accepted: 6 March 2010 / Published online: 20 April 2010  
© Springer-Verlag 2010

**Abstract** Drilling of the femoral tunnel with the transtibial (TT) technique is widely used in bone-patellar tendon-bone (BPTB) anterior cruciate ligament (ACL) reconstruction. Recent studies suggest higher knee stability with the use of the anteromedial portal (AMP). The purpose of this study was to compare functional and clinical outcomes of BPTB ACL reconstruction using the TT or the AMP technique for drilling the femoral tunnel. All ACL reconstructions between January 2003 and April 2006 were approached for eligibility. Forty-seven patients met inclusion criteria (21 TT group and 26 AMP group). Blinded assessments of IKDC score, knee stability and range of motion, one-leg hop test, mid-quadriceps circumference, VAS for satisfaction with surgery, Lysholm and Tegner scores, and SF-12 questionnaire were

obtained for both groups. Data on preoperative and postoperative surgical timing were retrospectively reviewed through the charts. The AMP group demonstrated a significantly lower recovery time from surgery to walking without crutches ( $p<0.01$ ), to return to normal life ( $p<0.03$ ), to return jogging ( $p<0.03$ ), to return training ( $p<0.03$ ), and to return to play ( $p<0.03$ ). Knee stability values measured with KT-1000, Lachman test, pivot-shift sign, and objective IKDC score assessments were significantly better for the AMP compared to TT group ( $p<0.002$ ,  $p<0.03$ ,  $p<0.02$ ,  $p<0.015$ , respectively). No differences were found for VAS for satisfaction with surgery, Lysholm, Tegner, and SF-12 between both groups. The use of the AMP technique significantly improved the anterior-posterior and rotational knee stability, IKDC scores, and recovery time from surgery compared to the TT technique.

Level of evidence: Level III (cross-sectional comparative study).

Eduard Alentorn-Geli and Gonzalo Samitier contributed equally to this work.

No conflict of interest is declared.

E. Alentorn-Geli · P. Álvarez · R. Cugat  
Artroscopia García-Cugat, Hospital Quirón,  
Barcelona, Spain

G. Samitier  
Hospital 9 de Octubre,  
Valencia, Spain

P. Álvarez · G. Steinbacher · R. Cugat  
Mutualidad de Futbolistas,  
Federación Española de Fútbol - Delegación Cataluña,  
Barcelona, Spain

R. Cugat (✉)  
Department of Orthopaedics, Hospital Quirón,  
Plaza Alfonso Comín 5–7,  
08023 Barcelona, Spain  
e-mail: ramon.cugat@sporttrauma.com

## Introduction

The autograft or allograft arthroscopic single-bundle (SB) is the “gold standard” technique for anterior cruciate ligament (ACL) reconstruction [15]. Initially, the most popular femoral drilling method was the two-incision technique, where the femoral tunnel is created outside-in [5]. The transtibial (TT) technique was the subsequent method of choice for the femoral tunnel placement [23]. Although there is no definitive evidence to support a clear benefit of the one-incision over the two-incision technique [17], the TT drilling method was adopted to obviate the necessity for the lateral incision and to, potentially, reduce operative time and surgical morbidity. Moreover, good clinical outcomes were reported with the TT technique [55]. However, recently it has been postulated that the SB TT ACL reconstruction places the graft in a non-anatomical femoral insertion site [3, 11, 18,

21, 27, 35, 41, 46]. Given that the most common cause of ACL reconstruction failure has been the non-anatomical femoral tunnel placement [32, 33, 46, 54], the double-bundle (anatomical) ACL reconstruction emerged in the surgical scenario as a potential solution for non-anatomical reconstructions. It was suggested that the double-bundle technique would better restore knee stability than other procedures [40, 56]. However, it has not been convincingly demonstrated that the anatomical ACL reconstruction is better than the SB technique [39]. Moreover, it remains unclear whether the theoretical advantages of the double-bundle reconstruction compensates for the higher complexity of this surgical procedure [39]. The use of the anteromedial portal (AMP) for drilling the femoral tunnel in the SB technique was suggested as a method to place the graft in an anatomical position and improve rotational stability, without increased complexity [3, 8, 10, 16, 25, 35, 46, 49]. With the TT technique, the position of the femoral tunnel is dictated by the tibial tunnel, whereas the AMP technique provides the surgeon with a greater freedom to place the graft in the anatomical position [8, 25]. Conversely, other authors have demonstrated that a relatively independent femoral tunnel placement is possible with TT drilling of the femoral tunnel [18, 44].

The purpose of this study was to compare the outcomes of arthroscopic SB autologous bone-patellar tendon-bone (BPTB) ACL reconstruction using the TT or the AMP technique for drilling the femoral tunnel in a homogeneous sample of soccer players. It was postulated that the SB AMP technique would produce better outcomes than the SB TT technique.

## Patients and methods

### Study design

An observational cross-sectional study was designed to compare the outcomes of arthroscopic ACL reconstruction using TT or AMP techniques in active soccer players. The medical records of all patients undergoing operation between January 2003 and April 2006 were reviewed, and eligible patients were appointed for a single follow-up visit in which objective and subjective clinical and functional outcomes were assessed (Fig. 1). Other preoperative and postoperative data were retrospectively collected from the patient's medical history. The physician performing all assessments was blinded as to the surgical technique.

### Patients

As previously mentioned, consecutive active soccer players who underwent unilateral ACL reconstruction between

January 2003 and April 2006 were eligible. All operations were performed by the senior surgeon (R.C.) at a single institution and differed only in the drilling technique of the femoral tunnel. The SB AMP technique was adopted from September 2004, whereas all ACL operations before this date were performed using the SB TT technique. A four-month period between September and December 2004 were excluded from the study in order to avoid the learning curve effect.

Inclusion criteria were as follows: active male soccer players, age between 16 and 35 years old, isolated primary ACL injury treated operatively through an arthroscopic ACL reconstruction with BPTB autograft, a two- to five-year follow-up, and healthy contralateral knee. The strict inclusion criteria were rigorously applied to minimise potential confounding factors and to compare a highly homogeneous sample.

The study protocol was approved by the Institutional Review Board and written informed consent was obtained from all participants.

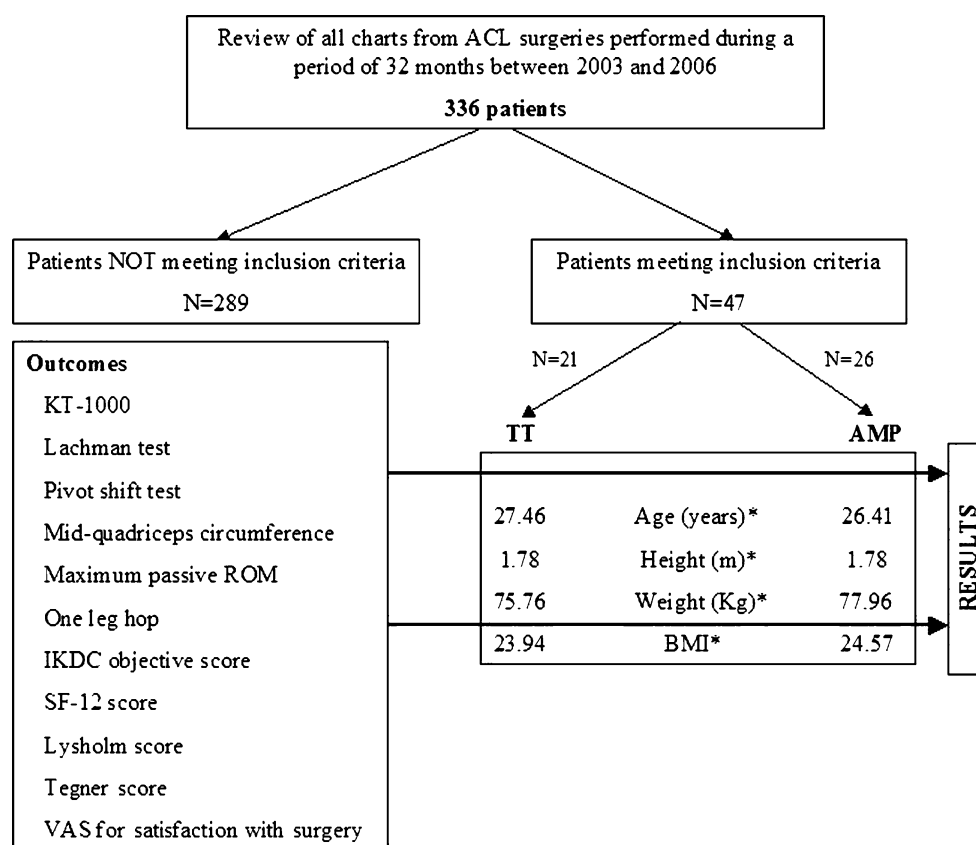
### Surgical technique

The SB TT technique we performed before September 2004 was previously reported in detail [22]. Although we were satisfied with our clinical results, the concerns regarding a non-anatomical femoral tunnel placement lead us switch to the SB AMP technique [8, 10, 25].

A standard one-incision arthroscopic ACL reconstruction procedure with autologous BPTB graft and interference screws was routinely used in both procedures [57]. For the SB TT technique, the knee was flexed to 90° and a tibial guide frame was distally placed medial and proximal to the tibial tuberosity in a tibial angle of 20° in the frontal plane. In the sagittal plane, the tibial angle was set at 50°. A guide pin was introduced through the tibia and was considered correctly placed when its exit point was continuous with a line marking the posterior edge of the lateral meniscus and the medial tibial spine. The guide pin was over-drilled by 9 mm using a cannulated reamer. A standard aiming instrument with a 7-mm offset was placed through the tibial tunnel at a desirable position and a guide pin was advanced into the femoral ACL footprint under arthroscopic view. An 8- or 9-mm cannulated reamer was introduced transtibially and the femoral tunnel was created to a depth of 30 mm.

The SB AMP technique places the posterior tibial landmark to a more anterior and medial location in comparison to that of the SB TT technique. The ideal tibial tunnel exit position should be in the posteromedial portion of the ACL footprint [12]. The tibial tunnel should be inclined posteriorly towards the Blumensaat's line on full extension to prevent graft-notch impingement [2, 24, 28–30, 43, 51]. The ACL tibial guide is set to an angle of 55° and placed medial to the centre of the remaining tibial stump

**Fig. 1** Study design. \*Indicates non significant differences between groups ( $p>0.05$ ). *ACL* anterior cruciate ligament, *TT* transtibial drilling technique, *AMP* anteromedial portal drilling technique, *BMI* body mass index, *ROM* range of motion, *IKDC* International Knee Documentation Committee, *SF-12* short form-12, *VAS* visual analogue scale



of the native ACL through an accessory central portal just medial to the patellar tendon. The guide wire is then passed and the tibial tunnel is created with a cannulated drill.

The femoral tunnel is positioned with the 7- or 8-mm “over the top” femoral guide and a guide wire with eyelet is passed through an accessory AMP created 1.5 cm medial to the patellar tendon using the central incision. It is important to keep a security distance from the cartilage of the medial femoral condyle once the drill passes through this portal. The knee is then hyperflexed at least 110° before drilling the lateral femoral condyle. The centre of the tunnel is marked depending on the graft size (normally 8–9 mm diameter and 25-mm depth), and a remaining posterior wall of 2–3 mm is recommended. This femoral insertion site represents a SB anatomical position between the anatomical AM and PL tunnel positions at the 2 o’clock position on a left knee and the 10 o’clock position on a right knee. After the graft is placed in the tibial and femoral tunnels, isometry and graft impingement is tested, graft tension is checked with the hook, and manual tension is applied to the graft at 30–90° of knee flexion.

#### Follow-up evaluation

All patients were evaluated two to five years after the surgical procedure. Clinical examination was performed according to the objective International Knee Documentation Committee (IKDC) evaluation form [26]. The primary clinical outcome,

also included in the IKDC, was the anterior-posterior knee laxity, which was measured with a KT-1000 arthrometer (Medmetric, San Diego, CA, USA) at 25° of knee flexion. The maximum manual and 133 N load displacements were measured in both knees. The secondary clinical outcome measures included a manual Lachman test and the pivot-shift sign. Other data from physical examination included side-to-side mid-quadriceps circumference differences expressed in millimeters. Functional outcomes and symptoms were assessed using the Lysholm knee score and the Tegner activity level. Patient’s satisfaction was assessed through a visual analogue scale (VAS) asking for general satisfaction with surgery graded also on a 0 (completely unsatisfied) to 10 (completely satisfied) scale. Finally, estimates of quality of life were reported using the short form-12 (SF-12) health survey [53]. All questionnaires were administered to all patients by the same blinded investigator to ensure standard instructions and thus minimise potential confounding variables.

#### Statistical analysis

Descriptive statistics were used to summarise the characteristics of both groups. An unpaired *t*-test was used to compare both groups with respect to demographic characteristics, and subjective (VAS for satisfaction with surgery, SF-12, and Lysholm and Tegner scores) and objective (KT-1000 measurements, mid-quadriceps circumference, one-leg hop,

and ROM) outcomes. A Mann-Whitney U-test was employed to compare preoperative and postoperative surgical timing between groups. Categorical variables were compared using a Chi-square test (Lachman and Pivot shift-sign tests) or a Fisher's exact test (level of current physical activity, currently playing soccer, and the IKDC score) between both groups. For all statistical tests, the alpha level was set at 0.05. Statistical analyses were performed with SPSS v.15.0 (SPSS Inc., Chicago, IL, USA).

## Results

The medical records of 379 patients were reviewed. Forty-three patients were excluded from this study to avoid the potential effect of the learning curve. Out of 336 patients approached for eligibility, 47 met inclusion criteria (13.99%). Reasons for exclusion included: females (11.61%), other than BPTB autograft employed (1.49%), associated meniscal injuries (49.69%), past history of contralateral ACL repair (4.76%), other ligamentous injuries to contralateral knee (2.98%), revision surgery (8.33%), graft rupture (1.19%), work schedule incompatibility (5.95%), and unanswered calls (4.76%). An unpaired *t*-tests demonstrated no significant differences in demographic data between both groups (Fig. 1). The four graft rupture cases (1.19%) were produced during soccer games through a contact mechanism. Of all 28 cases of revision surgery (8.33%), 24 were performed on patients not operated upon by the senior surgeon. Of all 336 patients, the rate of isolated unilateral ACL tear was 43% (143 out of 336).

Table 1 summarises data on preoperative and postoperative timing, and Tables 2 and 3 summarise data on subjective and objective measurements, respectively. We found a significant reduction in recovery time from surgery (Table 1), but no differences on subjective functional questionnaires (Table 2). Statistical analysis also revealed a significantly reduced anterior-posterior knee laxity at the maximum manual force assessed with the KT-1000 arthrometer in the AMP compared to the TT group ( $p<0.002$ ). Objective IKDC score, Lachman test, and pivot-shift sign assess-

ments were significantly better for the AMP compared to TT group ( $p<0.009$ ,  $p<0.03$ ,  $p<0.02$ , respectively). Ten out of all 16 patients not currently playing soccer (Table 2) were able to play a game, but they reported not enough time during daily life.

## Discussion

The purpose of this study was to compare the functional and clinical outcomes of arthroscopic SB autologous BPTB ACL reconstruction using the TT or AMP techniques for drilling the femoral tunnel in a homogeneous sample of soccer players. Several authors have discussed the use of the TT versus the AMP techniques for ACL reconstruction [6, 8, 10, 16, 21, 25, 27, 36, 41], but it remains unclear which one provides better results. To our knowledge, this is the first study “in vivo” comparing clinical and functional outcomes with the use of the TT or the AMP method for drilling the femoral tunnel in the SB autologous BPTB ACL reconstruction. The principal findings of this investigation were that the use of the AMP technique significantly improved the anterior-posterior and rotational knee stability, and overall IKDC scores compared to the TT technique. Also, a significant reduction in the recovery time from surgery was found for the AMP technique, whereas no differences were demonstrated for VAS, SF-12, Lysholm, and Tegner scores. Values for KT-1000-measured knee laxity, Lachman and Pivot shift sign tests, and Lysholm and IKDC scores at two- to five-year follow-up in the AMP group were similar than those reported by other authors using the AMP as well [1, 7, 42, 45, 47, 52].

There may be several limitations to this study. First, the SB TT group had a longer follow-up compared to the SB AMP group. However, we are confident on the limited impact of these differences on the outcome comparisons, since the minimum two-year follow-up period established in this study is considered enough time to return to normal life and sports [9, 14]. In addition, longer follow-ups do not necessarily imply worse results if we take into account the

**Table 1** Preoperative and postoperative surgical timing

Parameter measured	TT	AMP	<i>p</i> -value
Time from injury to surgery	2 (2–3.75)	3 (2–6)	0.19
Time from surgery to discharge from hospitalisation	10 (7.5–13.5)	8.5 (7–12)	0.37
Time from surgery to walk without crutches	2 (1.12–2)	1.5 (1–1.5)	0.01
Time from surgery to return to normal life <sup>a</sup>	3 (2–3.5)	2 (1.5–3)	0.04
Time from surgery to return jogging	5 (3–5)	3.5 (2.5–4)	0.03
Time from surgery to return training	7 (5.75–8)	6 (5–7)	0.03
Time from surgery to return to play	8 (9–11.5)	7 (7–8.75)	0.01

TT transtibial drilling technique, AMP anteromedial portal drilling technique

Values for TT and AMP are given in months; median (percentile25–percentile75)

<sup>a</sup> Time to return to work and undertaking daily life activities

**Table 2** Subjective assessment in both groups

Parameter assessed	TT	AMP	p-value
Level of current physical activity <sup>a</sup>			0.04
Vigorous	5 (10.6)	10 (21.2)	
Moderate	4 (8.5)	9 (19.1)	
Light	7 (14.9)	7 (14.9)	
Sedentary	5 (10.6)	0 (0)	
Currently playing soccer <sup>a</sup>			0.007
Competitive soccer	5 (10.6)	14 (29.7)	
Recreational soccer	10 (21.2)	2 (4.2)	
Not playing	6 (12.7)	10 (21.2)	
VAS for satisfaction with surgery <sup>b</sup>	8.6 (1.6)	9.1 (1.3)	0.35
Short Form-12 <sup>b</sup>	90.1 (9.9)	91.8 (8.2)	0.52
Lysholm <sup>b</sup>	97.1 (7.2)	99.3 (2.3)	0.148
Tegner <sup>b</sup>	7.1 (1.3)	7.8 (1.6)	0.09

TT transtibial drilling technique, AMP anteromedial portal drilling technique, VAS visual analogue scale

<sup>a</sup> Values are number of patients with percentage of total patients reviewed in parentheses

<sup>b</sup> Values are mean with standard deviation (SD) in parentheses

existing literature for TT technique [1, 4, 20, 38]. Moreover, the same rehabilitation instructions were given to all patients and physical therapists. Nonetheless, we think that the “level of current physical activity” (Table 2), and “currently playing soccer” (Table 2) items might possibly be affected by this limitation. Second, the strict inclusion criteria may decrease external validity and

compromise the generalisation of the results. Considering the lack of comparison studies between both techniques, investigations with high internal validity are evidently warranted. Third, the causal-effect relationship between the surgical technique and the main outcomes (data from Tables 2 and 3) may be questioned given the observational cross-sectional nature of this study. However, because both

**Table 3** Physical examination in both groups

Assessment	TT	AMP	p-value
Objective assessments (mean ± SD)			
KT-1000 at 134° N (mm) <sup>a</sup>	−0.3±1.2	−0.6±1.3	0.4
KT-1000 manual maximum (mm) <sup>a</sup>	1.9±1.8	0.2±1.6	0.002
Mid-quadriceps circumference (mm) <sup>b</sup>	8.5±12.5	5±13.5	0.35
One leg hop (cm) <sup>b</sup>	6.6±15.61	1.9±6.5	0.18
Maximum passive ROM <sup>b</sup>			
Flexion (°)	−0.2±3.2	−0.3±3.9	0.98
Extension (°)	0.2±1.1	0.1±0.3	0.48
IKDC <sup>a</sup> , n (%)			0.009
A	7 (14.9%)	19 (40.4%)	
B	12 (25.5%)	7 (14.9%)	
C	2 (4.2%)	0 (0%)	
D	0 (0%)	0 (0%)	
Specific assessments <sup>c</sup>			
Lachman test			0.03
0	11	21	
1+	10	5	
2+	0	0	
3+	0	0	
Pivot shift test			0.02
0	7	19	
1+	8	5	
2+	2	0	
3+	0	0	

TT transtibial drilling technique, AMP anteromedial portal drilling technique, ROM range of motion, IKDC International Knee Documentation Committee, SD standard deviation

<sup>a</sup> Values expressed as operated-healthy knee differences

<sup>b</sup> Values expressed as healthy-operated knee differences

<sup>c</sup> Graded as number of patients with no differences (0), mild differences (1+), moderate differences (2+), or severe differences (3+) between knees



groups were highly homogeneous, discrepancies between groups can be attributed to differences in surgical technique. Overall, a small sample size may not be considered a limitation as 47 patients were an adequate sample size to detect significant differences in main clinical outcomes (knee stability and IKDC values). Following the same reasoning, subjective variables (which were not significantly different) may be affected by a small sample size.

The success in ACL reconstruction surgery is mainly determined by similarities between the graft morphology, tension, position, and orientation compared to the native ACL. An anteriorly placed graft in the femur results in an anterior-posterior instability of the knee [37], whereas a vertically oriented graft in the coronal plane results in an increased internal rotation and positive pivot shift sign [34, 46]. It was found that the SB TT technique placed the femoral tunnel anteriorly and higher in the intercondylar notch compared to the native femoral ACL insertion site [3, 13, 41]. However, other authors demonstrated that a posteriorly located graft in the femur can be achieved through both the SB TT and AMP techniques, partially restoring anterior-posterior knee stability [18, 35]. A posterior location using the TT technique may be achievable due to a posterior tibial tunnel, as no independent drilling may be possible with this technique. A recent radiographic study concluded that drilling the femoral tunnel through the AMP resulted in a graft position more posterior and closer to the anatomical position compared to the TT technique [13]. It might be argued that the higher anterior-posterior knee stability values in the AMP group were explained by a more posterior femoral tunnel.

In the frontal plane, it was found that the drilling of the femoral tunnel through the AMP technique produced a more oblique position (towards the lateral cortex of the lateral femoral condyle) compared to the TT technique [13]. In fact, according to a biomechanical investigation performed by Loh et al. [35], femoral graft placement more lateral and close to the 10 o'clock position would better resist rotational loads when compared to the 11 o'clock position using a SB reconstruction technique [46]. Although Rue et al. demonstrated that a 10:20 position was achievable with the TT technique [44], most studies report that only an 11 o'clock position is possible with the TT drilling, whereas a 10 o'clock position can be achieved easily with the AMP technique [21, 46]. The results of our study support the findings of Loh et al. [35], since the AMP group demonstrated better rotational knee stability values compared to the TT technique. It must be noted that the tibial tunnel may not be exactly the same between groups. Therefore, the existing differences are not purely attributed to the femoral tunnel position.

In an attempt to improve graft placement, Golish et al. suggested centering the femoral tunnel into the ACL

footprints via TT technique with a far medial entry in tibia [19]. Controversially, several authors concluded that attempting an anatomical femoral tunnel positioning through the TT technique would require a starting point too close to the tibial joint line, resulting in a relatively short and medial tibial tunnel and a tunnel length-graft length mismatch. This might compromise the medial collateral ligament, graft fixation and graft incorporation and, in many cases, could result in a loss of the femoral and/or tibial footprints [3, 27, 50]. Therefore, drilling the femoral tunnel through a low AMP is recommended. It must be noted that a recent method to independently drill the femoral tunnel (the retrograde femoral drilling technique) has been reported [48]. This method would not require knee flexion angles above 100°, thus being advantageous over the AMP technique.

The advantages that can therefore be attributed to the AMP technique are: (1) the femoral and tibial tunnels are placed independently of each other [8, 10, 21, 25]; (2) the femoral tunnel can be drilled with knee in hyperflexion reducing the risk of posterior wall blow out [6, 10]; (3) the femoral tunnel is placed more anatomically on the ACL femoral insertion site [8, 10, 16, 21, 25]; (4) the AMP technique allows for easy augmentation by preserving the remaining ACL fibres [10]; (5) the easy parallel placement of the interference screw to the bone plug with no lateral incisions [36]; (6) the tunnel placement is independent of graft type or tunnel guides [10]; and (7) it is flexible enough so that SB, double-bundle, and revision procedures may be easily performed [36]. On the other hand, several limitations do exist when using the AMP technique: (1) the femoral tunnel needs to be created with 110–120° of knee flexion to avoid injury to the posterolateral structures and posterior “blow-out”; (2) visualisation is challenging when a leg holder is used [50]; (3) several graft fixation techniques require guide instruments designed for TT insertion that may not be appropriate for the AMP technique.

The higher anterior-posterior and rotational knee stability values in the AMP group may explain a faster recovery time from surgery compared to the TT group. Greater activity levels after ACL reconstruction with an oblique femoral tunnel placement were also found by Jensen et al. [31], who conducted a randomised controlled trial comparing “high tunnel” (1 o'clock position) and “low tunnel” (2 o'clock position) ACL reconstructions. The “low tunnel” group demonstrated greater activity level and ability to jump and land compared to the high tunnel group.

Prospective randomised clinical trials comparing the use of the AMP versus the TT technique for drilling the femoral tunnel in the BPTB ACL reconstruction are warranted to better elucidate the clinical implications of varying the drilling technique of the femoral tunnel.

**Acknowledgements** This study was made possible by Mutuallidad de Futbolistas, Federación Española de Fútbol - Delegación Cataluña. We also thank Marta Pulido, MD for the contributions in the edition of the manuscript and editorial assistance, and Sergi Mojal, PhD for statistical review.

## References

- Alentorn-Geli E, Lajara F, Samitier G, Cugat R (2009) The transtibial versus the anteromedial portal technique in the arthroscopic bone-patellar tendon-bone anterior cruciate ligament reconstruction. *Knee Surg Sports Traum Arthrosc*. Nov. 10 [Epub ahead of print] doi:10.1007/s00167-009-0964-0
- Allen CR, Giffin JR, Harner CD (2003) Revision anterior cruciate ligament reconstruction. *Orthop Clin North Am* 34:79–98
- Arnold MP, Kooloos J, van Kampen A (2001) Single-incision technique misses the anatomical femoral anterior cruciate ligament insertion: a cadaver study. *Knee Surg Sports Traumatol Arthrosc* 9:194–199
- Aune AK, Holm I, Risberg MA, Jensen HK, Steen H (2001) Four-strand hamstring tendon autograft compared with patellar tendon-bone autograft for anterior cruciate ligament reconstruction. A randomized study with two-year follow-up. *Am J Sports Med* 29:722–728
- Bach BR (1989) Arthroscopy assisted patellar tendon substitution for anterior cruciate ligament reconstruction. *Am J Knee Surg* 2:3–20
- Basdekis G, Abisafi C, Christel P (2008) Influence of knee flexion angle on femoral tunnel characteristics when drilled through the anteromedial portal during anterior cruciate ligament reconstruction. *Arthroscopy* 24:459–464
- Beard DJ, Anderson JL, Davies S, Price AJ, Dodd CAF (2001) Hamstrings versus patella tendon for anterior cruciate ligament reconstruction: a randomised controlled trial. *Knee* 8:45–50
- Bottoni CR, Rooney RC, Harpstrite JK, Kan DM (1998) Ensuring accurate femoral guide pin placement in anterior cruciate ligament reconstruction. *Am J Orthop* 27:764–766
- Cascio BM, Culp L, Cosgarea AJ (2004) Return to play after anterior cruciate ligament reconstruction. *Clin Sports Med* 23:395–408
- Cha PS, Chhabra A, Harner CD (2005) Single-bundle anterior cruciate ligament reconstruction using the medial portal technique. *Oper Tech Orthop* 15:89–95
- Chhabra A, Kline AJ, Nilles KM, Harner CD (2006) Tunnel expansion after anterior cruciate ligament reconstruction with autogenous hamstrings: a comparison of the medial portal and transtibial techniques. *Arthroscopy* 22:1107–1112
- Clancy WG, Nelson DA, Reider B, Narechania RG (1982) Anterior cruciate ligament reconstruction using one-third of the patellar ligament, augmented by extra-articular tendon transfers. *J Bone Joint Surg Am* 64:352–359
- Dargel J, Schmidt-Wiethoff R, Mader K, Koebke J, Schneider T (2009) Femoral bone tunnel placement using the transtibial tunnel for the anteromedial portal in ACL reconstruction: a radiographic evaluation. *Knee Surg Sports Traum Arthrosc* 17:220–227
- Delay BS (2001) Current practices and opinion in ACL reconstruction and rehabilitation: results of a survey of the American Orthopaedic Society for Sports Medicine. *Am J Knee Surg* 14:85–91
- Duquin TR, Wind WM, Fineberg MS, Smolinski RJ, Buyea CM (2009) Current trends in anterior cruciate ligament reconstruction. *J Knee Surg* 22:7–12
- Gavrilidis I, Mosis EK, Pakos EE, Georgoulis AD, Mitsionis G, Xenakis TA (2008) Transtibial versus anteromedial portal of the femoral tunnel in ACL reconstruction: a cadaveric study. *Knee* 15:364–367
- George MS, Huston LJ, Spindler KP (2007) Endoscopic versus rear-entry anterior cruciate ligament reconstruction: a systematic review. *Clin Orthop Rel Res* 455:158–161
- Giron F, Buzzi R, Aglietti P (1999) Femoral tunnel position in anterior cruciate ligament reconstruction using three techniques. A cadaver study. *Arthroscopy* 15:750–756
- Golish SR, Baumfeld JA, Schoderbek RJ, Miller MD (2007) The effect of femoral tunnel starting position on tunnel length in anterior cruciate ligament reconstruction: a cadaveric study. *Arthroscopy* 23:1187–1192
- Gorschewsky O, Klakow A, Riechert K, Pitzl M, Becker R (2005) Clinical comparison of the Tutoplast allograft and autologous patellar tendon (bone-patellar tendon-bone) for the reconstruction of the anterior cruciate ligament. Two- and 6-year results. *Am J Sports Med* 33:1202–1209
- Hantes ME, Zachos VC, Liantis A, Venouziou A, Karantanas AH, Malizos KN (2009) Differences in graft orientation using the transtibial and anteromedial portal technique in anterior cruciate ligament reconstruction: a magnetic resonance imaging study. *Knee Surg Sports Traum Arthrosc* 17(8):880–886
- Hardin GT, Bach BR, Bush-Joseph CA, Farr J (1992) Endoscopic single-incision anterior cruciate ligament reconstruction using patellar tendon autograft. *Am J Knee Surg* 5:144–155
- Harner CD, Fu F, Irrgang JJ, Vogrin TM (2001) Anterior and posterior cruciate ligament reconstruction in the new millennium: a global perspective. *Knee Surg Sports Traum Arthrosc* 9:330–336
- Harner CD, Giffin JR, Duntzman RC, Annunziata CC, Friedman MJ (2001) Evaluation and treatment of recurrent instability after anterior cruciate ligament reconstruction. *Instr Course Lect* 50:463–474
- Harner CD, Honkamp NJ, Ranawat AS (2008) Anteromedial portal technique for creating the anterior cruciate ligament femoral tunnel. *Arthroscopy* 24:113–115
- Hefti F, Muller W, Jakob RP, Staubli HU (1993) Evaluation of knee ligament injuries with the IKDC form. *Knee Surg Sports Traumatol Arthrosc* 1:226–234
- Heming JF, Rand J, Steiner ME (2007) Anatomical limitations of transtibial drilling in anterior cruciate ligament reconstruction. *Am J Sports Med* 35:1708–1715
- Howell SM, Clark JA (1992) Tibial tunnel placement in anterior cruciate ligament reconstructions and graft impingement. *Clin Orthop* 283:187–195
- Howell SM, Clark JA, Farley TE (1992) Serial magnetic resonance study assessing the effects of impingement on the MR image of the patellar tendon graft. *Arthroscopy* 8:350–358
- Howell SM, Taylor MA (1993) Failure of reconstruction of the anterior cruciate ligament due to impingement by the intercondylar roof. *J Bone Joint Surg Am* 75:1044–1055
- Jepsen CF, Lundberg-Jensen AK, Faunoe P (2007) Does the position of the femoral tunnel affect the laxity or clinical outcome of the anterior cruciate ligament-reconstructed knee? A clinical, prospective, randomized, double-blind study. *Arthroscopy* 23:1326–1333
- Johnson DL, Swenson TM, Irrgang JJ, Fu FH, Harner CD (1996) Revision anterior cruciate ligament surgery: experience from Pittsburgh. *Clin Orthop Relat Res* 325:100–109
- Kohn D, Busche T, Carls J (1998) Drill hole position in endoscopic anterior cruciate ligament reconstruction. *Knee Surg Sports Traumatol Arthrosc* 6:S13–S15
- Lee MC, Seong SC, Lee S, Chang CB, Park YK, Jo H, Kim CH (2007) Vertical femoral tunnel placement results in rotational knee laxity after anterior cruciate ligament reconstruction. *Arthroscopy* 23:771–778
- Loh JC, Fukuda Y, Tsuda E, Steadman RJ, Fu FH, Woo SL (2003) Knee stability and graft function following anterior cruciate ligament reconstruction: comparison between 11 o'clock and 10 o'clock femoral tunnel placement. *Arthroscopy* 19:297–304

36. Lubowitz JH (2009) Anteromedial portal technique for the anterior cruciate ligament femoral socket: pitfalls and solutions. *Arthroscopy* 25:95–101
37. Markolf KL, Hame SL, Hunter DM, Oakes DA, Zoric B, Gause P, Finerman GAM (2002) Effects of femoral tunnel placement on knee laxity and forces in an anterior cruciate ligament graft. *J Orthop Res* 20:1016–1024
38. Matsumoto A, Yoshiya S, Muratsu H, Yagi M, Iwasaki Y, Kurosaka M, Kuroda R (2006) A comparison of bone-patellar tendon-bone and bone-hamstring tendon-bone autografts for anterior cruciate ligament reconstruction. *Am J Sports Med* 34:213–219
39. Meredick RB, Vance KJ, Appleby D, Lubowitz JH (2008) Outcome of single-bundle versus double-bundle reconstruction of the anterior cruciate ligament: a meta-analysis. *Am J Sports Med* 36:1414–1421
40. Muneta T, Sekiya I, Yagishita K, Ogiuchi T, Yamamoto H, Shinomiya K (1999) Two-bundle reconstruction of the anterior cruciate ligament using a semitendinosus tendon with EndoButton: operative technique and preliminary results. *Arthroscopy* 15:618–624
41. Paessler H, Rossis J, Mastrokalos D, Kotsovolos I (2004) Anteromedial versus transtibial technique for correct femoral tunnel placement during arthroscopic ACL reconstruction with hamstrings: an in vivo study. *J Bone Joint Surg Br* 86:S234
42. Pinczewski LA, Lyman J, Salmon LJ, Russell VJ, Roe J, Linklater J (2007) A 10-year comparison of anterior cruciate ligament reconstructions with hamstring tendon and patellar tendon autograft: a controlled, prospective trial. *Am J Sports Med* 35:564–574
43. Romano VM, Graf BK, Keene JS, Lange RH (1993) Anterior cruciate ligament reconstruction: the effect of tibial tunnel placement on range of motion. *Am J Sports Med* 21:415–418
44. Rue JP, Ghodadra N, Lewis PB, Bach BR (2008) Femoral and tibial tunnel position using a transtibial drilled anterior cruciate ligament reconstruction technique. *J Knee Surg* 21:246–249
45. Sajovic M, Vengust V, Komadina R, Tavcar R, Skaza K (2006) A prospective, randomized comparison of semitendinosus and gracilis tendon versus patellar tendon autografts for anterior cruciate ligament reconstruction. Five-year follow-up. *Am J Sports Med* 34:1933–1940
46. Scopp JM, Jasper LE, Belkoff SM, Moorman CT (2004) The effect of oblique femoral tunnel placement on rotational constraint of the knee reconstructed using patellar tendon autografts. *Arthroscopy* 20:294–299
47. Shaieb MD, Kan DM, Chang SK, Marumoto JM, Richardson AB (2002) A prospective randomized comparison of patellar tendon versus semitendinosus and gracilis tendon autografts for anterior cruciate ligament reconstruction. *Am J Sports Med* 30:214–220
48. Sohn DH, Garrett WE (2009) Transitioning to anatomic anterior cruciate ligament graft placement. *J Knee Surg* 22:155–160
49. Steiner ME (2009) Independent drilling of tibial and femoral tunnels in anterior cruciate ligament reconstruction. *J Knee Surg* 22:171–176
50. Steiner ME, Murray MM, Rodeo SA (2008) Strategies to improve anterior cruciate ligament healing and graft placement. *Am J Sports Med* 36:176–189
51. Tanzer M, Lenczner E (1990) The relationship of intercondylar notch size and content to notchplasty requirement in anterior cruciate ligament surgery. *Arthroscopy* 6:89–93
52. Wagner M, Kääh MJ, Schallock J, Haas NP, Weiler A (2005) Hamstring tendon versus patellar tendon anterior cruciate ligament reconstruction using biodegradable interference fit fixation. A prospective matched-group analysis. *Am J Sports Med* 33:1327–1336
53. Ware JE, Kosinski M, Keller SD (1996) A 12-item Short-Form health survey: construction of scales and preliminary tests of reliability and validity. *Med Care* 34:220–233
54. Wetzler MJ, Getelman MH, Friedman MJ, Bartolozzi AR (1998) Revision anterior cruciate ligament surgery: etiology of failures. *Op Tech Sports Med* 6:64–70
55. Williams RJ, Hyman J, Petrigliano F, Rozental T, Wickiewicz TL (2004) Anterior cruciate ligament reconstruction with a fourstrand hamstring tendon autograft. *J Bone Joint Surg Am* 86:225–232
56. Zaricznyj B (1987) Reconstruction of the anterior cruciate ligament of the knee using a doubled tendon graft. *Clin Orthop* 220:162–175
57. Zarins B, Sweeney HJ (1993) Técnica artroscópica. In: Zarins B, Cugat R (eds) *Principios de artroscopia y cirugía artroscópica*. Springer-Verlag Ibérica, Barcelona, pp 39–49