NIH Public Access
Author Manuscript
Clin Immunol. Author manuscript; available in PMC 2009 October 1.

Published in final edited form as:
Clin Immunol. 2008 October ; 129(1): 3–9. doi:10.1016/j.clim.2008.07.001.

Cutaneous vasculitis in breast cancer treated with chemotherapy

Maida Wong[*], **Jennifer Grossman**, **Bevra H. Hahn**, and **Antonio La Cava**
Department of Medicine, Division of Rheumatology, University of California Los Angeles FOCiS Center of Excellence, U.S.A

Abstract

A patient from the University of California Los Angeles Medical Center who developed cutaneous vasculitis during the course of treatment for metastatic breast cancer is presented (status: post-lumpectomy and radiation therapy). Since the onset of vasculitis occurred during the course of therapy for the neoplasm, it was difficult to differentiate between drug-induced vasculitis and paraneoplastic vasculitis. The patient had been exposed to medications including gabapentin, methimazole, trastuzumab, fulvestrant, and letrozole - which could cause endothelial cell toxicity. Drug-induced small vessel vasculitis usually attacks the skin or subcutaneous parts of the skin. In cancer therapy, there have been case reports that hormonal drugs such as estrogen receptor antagonists, aromatase inhibitors, and epidermal growth factor receptor (EGFR) inhibitors can induce cutaneous vasculitis. On the other hand, paraneoplastic syndromes manifested as cutaneous vasculitis have been documented, possibly mediated by unknown immunological mechanisms associated with the tumor such as formation of immune complexes, direct antibody-mediated effects on endothelial cells, or direct effects of tumor cells on the vascular wall. Some patients with drug-induced cutaneous vasculitis have antineutrophil cytoplasm antibodies (ANCA) directed to one or more neutrophil cytoplasm antigens - the most common being granule protein myeloperoxidase (MPO), human leukocyte elastase (HLE), cathepsin G and lactoferrin. Some patients also have antibodies against histones and antiphospholipid. Serologic testing and measurements suggest an influence of therapy on vasculitis, yet the lack of sensitivity and specificity for a biomarker in endothelial injury indicate the need to search and evaluate new markers for improved predictive value of the tests, and to provide guidance in therapy.

Case presentation

A 63 year old black female with a history of breast cancer presented to the UCLA Medical Center in 2004 with a rash in her lower extremities for two months. She had been diagnosed with intraductal breast carcinoma in 1992. Her status post left lumpectomy with radiation therapy and tamoxifen therapy for two years showed no signs of relapse. She had also been diagnosed with toxic multinodular goiter in 1996, and following treatment with ^{131}I therapy and methimazole, she had been euthyroid since then. She had previously been on estrogen replacement therapy until her diagnosis with breast carcinoma in 1992, and had past history of idiopathic thrombocytopenia.

Her symptoms in 2004 began as a draining wound in her right lower extremity, which rapidly progressed to large ulcerations at both lower extremities. Systemic symptoms included mild

*Corresponding author. Division of Rheumatology at the University of California Los Angeles, 1000 Veteran Avenue 32-59, Los Angeles, CA 90095-1670, USA. Tel.: 1 310 206 5114; Fax: 1 310 206 8606; E-mail: maidawong@mednet.ucla.edu.

Publisher's Disclaimer: This is a PDF file of an unedited manuscript that has been accepted for publication. As a service to our customers we are providing this early version of the manuscript. The manuscript will undergo copyediting, typesetting, and review of the resulting proof before it is published in its final citable form. Please note that during the production process errors may be discovered which could affect the content, and all legal disclaimers that apply to the journal pertain.

NIH-PA Author Manuscript
NIH-PA Author Manuscript
NIH-PA Author Manuscript

NIH-PA Author Manuscript

NIH-PA Author Manuscript

NIH-PA Author Manuscript

weight loss, but no fever or joint problems. She had not used over-the-counter medications or herbal supplements in the recent past, and had not been exposed to corticosteroids. On exam, diffuse superficial, irregular, indurated purpura was localized in her lower extremities. Those lesions were painful, raised, confluent, erythematous patches with a burning sensation.

Blood exams indicated an erythrocyte sedimentation rate (ESR) of 96 mm/h. Positive serological tests included: anti-cardiolipin IgM antibody (Ab): 19 MPL (normal: <10), β2-glycoprotein IgA: 10 U/ml (normal: <10), immunofluorescent perinuclear ANCA (p-ANCA): 1:80 (she was negative for myeloperoxidase), thyroglobulin (TG) Ab: 40.5 IU/ml (normal: <2.5), thyroperoxidase (TPO) Ab): 675.7 IU/ml (normal: <2.0), parietal cell Ab: 1:80. The cytokine profile was unremarkable: tumor necrosis factor (TNF)-α: < 0.1 pg/ml (normal is 1.2–15.3), interleukin (IL)-1β: < 3.9 pg/ml (normal is <3.9), IL-2 receptor: 716 U/ml (normal is 406–1100), IL-6: 3.81 pg/ml (normal is 0.31–5.0). Tests for rheumatoid factor, antinuclear Ab (ANA), antihistone Ab were negative. The carcinoembryonic antigen (CEA) level was 2.0 ng/ml (normal range is 0–2.5 ng/ml in non-smokers).

Full thickness biopsy of the skin on the right calf showed vacuolar alteration of the dermoepidermal junction, with superficial and deep perivascular and peradnexal lymphocytic infiltrate extending to the subcutis in a lobular pattern, consistent with a connective tissue disease (Figure 1).

The medication gabapentin that had been started a month before the onset of her lesions was discontinued, and her lesions stopped progression and improved gradually, the ulcerations resolving with wound care.

In the tumor surveillance exam taken in 2006, whole-body PET CT scan revealed a focus of increased 18-fluro-2-deoxyglucose (FDG) activity in the medial segment of the left lobe of the liver (Figure 2). MRI of the abdomen showed two ill-defined lesions in the left lobe of the liver - which were hypointense to the normal liver tissue on precontrast T1-weighted images, isointense on early postcontrast images with portal venous phase enhancement (that persisted on delayed images), and increased T2 signal (Figure 3). At the same time, cystoscopy was done because of a persistent bladder infection, and a bladder mass was found. After bladder biopsy, fluorescence *in situ* hybridization (FISH) for the expression of the HER-2/neu gene showed an abnormal signal pattern, with a HER-2/D17z1 ratio of 6.3 (a ratio ≥2 indicates a gene amplification) (Figure 4).

The patient was diagnosed with a stage IV estrogen receptor-positive (ER+), HER2+ breast cancer, and she was immediately started on anastrazole. Since she developed arthralgia with this medication, therapy was switched to letrozole. However, arthralgia persisted and, at the same time, skin lesions recurred in both lower extremities. Letrozole was discontinued and the patient was started on trastuzumab and fulvestrant, but the skin lesions continued to progress in both number and size over the next six months, during which she received chemotherapy. During this time of progression of the lesions, her CEA remained low at <2.5 ng/ml, and her level of CA27.29 was unremarkable. A full thickness skin biopsy at her right shin showed parakeratosis and vacuolar alteration along the dermoepidermal junction, with superficial and deep perivascular and interstitial mixed infiltrate composed of lymphocytes, eosinophils and neutrophils. Both lymphocytes and neutrophils were present within the vessel walls, with signs of leukocytoclasis, suggesting a drug eruption.

The patient was started on colchicine 0.6 mg/ml bid while she remained on trastuzumab, and her skin lesions gradually improved. Glucocorticoid was not given due to concerns of negative interactions with ongoing cancer treatment. Her subsequent tumor surveillance exams were unremarkable.

NIH-PA Author Manuscript

NIH-PA Author Manuscript

NIH-PA Author Manuscript

Discussion

Cutaneous vasculitis is a small-vessel systemic vasculitis characterized by the involvement of the skin as palpable purpura. It can range in severity from benign, self-limited, short-lived cutaneous eruption to a life-threatening disease with multiple organ failure. Systemic manifestations include, most frequently, fever, arthralgias and arthritis and, less commonly, renal, neurological or gastrointestinal involvement [1,2]. The disorder is caused by mechanisms of hypersensitivity associated with reactivity to antigens provided by infection, drugs, or autoantigens of connective tissue diseases [2].

The nature of cutaneous vasculitis associated with malignant diseases may be paraneoplastic, or it can be caused by drugs or infection [3,4]. It is often difficult to distinguish among those conditions because the chronology of the events often overlaps, and there are many variations in the time between onset of vasculitis and malignancy, or type of therapy.

The patient in question had exposure to several drugs that could have caused a drug-induced vasculitis (DIV). She had been treated with methimazole for her toxic multimodular goiter, and for the treatment of breast cancer she had been exposed to drugs such as tamoxifen and fulvestrant (ER inhibitors), anastrazole and letrozole (aromatase inhibitors), all of which have been associated in case reports of vasculitis. On the other hand, a breast cancer patient with metastatic relapse also is at risk for paraneoplastic vasculitis.

Drug-induced vasculitis (DIV)

Approximately 20% of cases of cutaneous vasculitis represent an adverse drug eruption. 63% of the patients with DIV present as cutaneous vasculitis. Most of these cases present as hypersensitivity vasculitis, and exhibit superficial dermal small-vessel neutrophilic vasculitis [5]. Arthralgia and skin vasculitis are the most common features in these patients, which have good long-term prognosis because of limited renal involvement. When there is multi-organ involvement, the disease can be life-threatening. The interval between the first exposure and appearance of symptoms for DIV can be extremely variable, i.e. from hours to years, with the vasculitis commencing after the drug dosage increases, and/or after re-exposure.

In DIV positive for ANCA, it is likely that the drug induces damage to neutrophils [6,7]. The most common antibodies are directed against the granule proteins MPO, HLE, cathepsin G and lactoferrin. There are often cases of patients being positive on ANCA screen, but negative for proteinase-3 and MPO. Generally, ANCA positivity (especially anti-MPO Ab) in DIV patients can be associated with a severe disease course.

Occasionally, DIV can be confused with lupus because of the presence of multiple autoantibodies including ANA and anti-histone Ab, anticardiolipin IgM, and low complement C4 (low C4 values suggest complement consumption by immune complexes, as supported by the slightly higher cryoglobulin values in those patients). In cases which anticardiolipin Ab are elevated, the prognosis can be worse because of the development of extensive lesions.

The exact pathogenic mechanisms involved in DIV are unknown, although it appears that both cell-mediated and humoral immunity play important roles. In the case of ANCA-positive cutaneous vasculitis, it is suspected that the ANCA antigen increases neutrophil vessel-wall adherence and transmigration, which can trigger ROI production, neutrophil degranulation and release of proteolytic enzymes, and ultimately vasculitis.

The withdrawal of the offending agent usually leads to a resolution of the clinical manifestations, without further need of therapy. Nevertheless, some patients progress to serious, life-threatening vasculitic manifestations if the offending drug therapy is not stopped

NIH-PA Author Manuscript

NIH-PA Author Manuscript

NIH-PA Author Manuscript

[8], and may require treatment with steroids, cyclophosphamide, plasmapheresis, or hemodialysis. Death may occur in about 10% of the cases, predominantly in patients with multiple-organ involvement [9].

Antithyroid therapy

Lupus-like DIV can develop as a result of antithyroid drug therapy [10]. Patients with Graves' disease who develop DIV with propylthiouracil or methimazole therapy are likely to do so because of a genetic predisposition [11], and a positive correlation is generally found between MPO-ANCA and the level of thyroglobulin Ab, suggesting that the severity of Graves' disease may be responsible for MPO-ANCA positivity [12].

Trastuzumab

HER2 (erb/neu) is a member of the epidermal growth factor receptor (EGFR) family of the receptor tyrosine kinases, and is unique in that it does not have a known ligand. It is overexpressed in 25–30% of human breast cancers [13,14].

Activation of EGFR stimulates cellular responses. However, aberrant signaling of EGFR results in neoplastic cell proliferation, abnormal differentiation, migration, stromal invasion, resistance to apoptosis, and angiogenesis [15–17].

HER2 intracellular signals involve a direct activation of the PI3K pathway -associated with cell growth, proliferation, cell survival, angiogenesis and cell motility [18,19]. HER2 overexpression results in excessive HER2 signaling, which leads to deregulation of cell proliferation and survival, causing in turn uncontrolled cell proliferation or tumorigenesis [20]. High levels of HER2 are associated with poor prognosis and high resistance to chemotherapy and hormone therapy, high relapse rate, and reduced survival [21,22].

Notably, EGFR inhibition in EGFR+ tumors impairs tumor growth. Because of the high frequency of abnormalities of EGFR signaling in human carcinomas, therapies targeting EGFR have been developed. Those therapies have a lower overall toxicity and a higher therapeutic index than conventional cytotoxic drugs [23], but often cause skin toxicity - typically acneiform eruptions [24–26] - and also cutaneous vasculitis [27]. Such skin lesions often correlated in a dose dependent fashion to the EGFR inhibitor antitumor activity [17,26]. There have been no report of skin toxicity for trastuzumab, of the EGFR family. Trastuzumab is a recombinant humanized anti-p185 (HER2) monoclonal Ab directed against the extracellular domain of HER2 [13], and is used as an adjuvant treatment of HER-2/neu overexpressing breast cancers. It effectively inhibits the growth of HER2-overexpressing breast cancer cells both *in vivo* and *in vitro*. By downregulating the HER2 receptor, trastuzumab inhibits the PI3K pathway, hence decreasing the expression of vascular endothelial growth factor (VEGF) and interleukin-8 (IL-8), and upregulates the antiangiogenic factor thrombospondin-1 (TSP-1), and p38 [28]. This in turn accumulates cyclin-dependent kinase inhibitor $p27^{Kip1}$, downregulates CDK2, CDK6, cyclin A and cyclin D through transcriptional and post-transcriptional mechanisms, and leads to cell cycle arrest at the G_1 phase [20,28]. *In vivo*, trastuzumab induces Ab-dependent cellular cytotoxicity and inhibits constitutive HER2 cleavage/shedding mediated by metalloproteases.

EGFR is expressed in the skin, primarily in proliferating, undifferentiated keratinocytes of the basal layers of the epidermis and the outer root sheath of the hair follicle [26]. Eruption is a direct consequence of EGFR blockade which increases expression of $p27^{Kip1}$, increases apoptosis, and promotes keratinocyte differentiation [24,29]. Although trastuzumab is HER2-specific and does not block other members of the EGFR family, it stabilizes $p27^{Kip1}$ in the

NIH-PA Author Manuscript

NIH-PA Author Manuscript

NIH-PA Author Manuscript

nucleus to increase inhibitory effects on CDK2 -possibly explaining the effects on skin cells and/or cutaneous vasculitis.

Tamoxifen and anastrozole

Approximately two-thirds of primary breast cancers express the estrogen receptor α isoform (ER). Tamoxifen is a competitive inhibitor of estrogen that binds to ER, and induces a receptor conformational change inhibiting the estradiol binding to ER, so that ER transcriptional activity is repressed with resulting decreased tumor cell proliferation and cell death. In addition, tamoxifen can exert antiangiogenic effects, and is effective in ER-positive cancers [30,31].

The aromatase enzyme is responsible for estrogen biosynthesis from androgens in postmenopausal women. Aromatase inhibitors[30] reduce estrogen levels by decreasing aromatase activity, and are beneficial in postmenopausal women with advanced hormone-dependent breast cancer [32].

Development of skin changes, including cutaneous vasculitis, due to tamoxifen were reported in 19% of tamoxifen treated patients, and has also been reported in a breast cancer patient undergoing anatrazole treatment [33,34]. For both drugs, vasculitis disappeared after the medication was withdrawn, and in the case of tamoxifen, the vasculitis reappeared when the drug was reintroduced. Quick resolution of toxicity after discontinuation of the medication supports a drug-induced effect - suggesting that the inhibition of the estrogen effect that should prevent vasculitis might paradoxically induce vasculitis.

Paraneoplastic vasculitis

Paraneoplastic vasculitis is an inflammation of the vessels arising from hypersensitivity to malignant cells [3]. There are two criteria to define paraneoplastic vasculitis: 1) the simultaneous appearance of both vasculitis and neoplasms, and 2) their parallel course [35].

The prevalence of malignancies in adult patients with vasculitis has been estimated in 3 to 8% of all patients with vasculitis [36], with a majority of patients being over 50 years of age [37, 38]. Vasculitis manifestations vary from 25 months before to 9 months after cancer diagnosis [36]. The most frequently described vasculitides in these cases are leukocytoclastic vasculitis, which constitutes 30–40% of all paraneoplastic vasculitis [1,39], and paraneoplastic vasculitis only represents less than 5% of all cases of cutaneous vasculitis [5]. Most patients have associated hematological malignancy (90%), and only 10% of the cases are related to solid tumors [39].

Malignancy-associated vasculitis syndromes can be grouped into vasculitis-associated malignancies, vasculitis masquerading as malignancies, and malignancies masquerading as vasculitides [40–42]. Most paraneoplastic cutaneous vasculitic syndromes are the result of paraproteinemia secondary to lymphoproliferative disorders, typically cryoglobulins. Other unusual associations of malignancy involving systemic vasculitides include polyarteritis nodosa.

In general, the signs and symptoms of paraneoplastic vasculitis are similar to those in patients who do not suffer from an underlying cancer. The “red flags” for possible malignancy in individuals with vasculitis are a decline in general health, weight loss, or a chronic relapse course of skin purpura [43]. Complementary studies do not usually show specific abnormalities to suggest the neoplasm; sometimes an increased in ESR, anemia or lymphocytosis may be found. Positive tests for rheumatoid factor or decrease in complement levels can also be detected [39]. Histological features of leukocytoclastic paraneoplastic vasculitis do not differ from those identified in vasculitis of different etiology [1].

NIH-PA Author Manuscript

NIH-PA Author Manuscript

NIH-PA Author Manuscript

The etiopathogenesis of paraneoplastic vasculitis is unclear. It was suggested that malignant cells might produce antigens and consequently cause paraneoplastic vasculitis [44]. It has been postulated that the coexistence of neoplasms and vasculitis is associated with the type of treatment, the tumor antigen leading to immune complex formation and subsequent release of lymphokines and other vasoactive substances. Malignant cells might act, directly or indirectly, as sensitizing agents, or release some cytokines that damage the vascular endothelium [1,45].

The prognosis of paraneoplastic vasculitis depends primarily on the availability of effective treatment for the underlying malignancy. Treatment of malignancy often results in regression of the cutaneous lesions, and symptoms may recur between chemotherapy courses [41,46]. However, when a curative treatment of the neoplasm is not possible, paraneoplastic vasculitis responds to treatment with glucocorticoids alone or in combination with immunosuppressive agents [2].

Conclusions

In our patient, it may be not possible to distinguish between a case of drug-induced cutaneous vasculitis and paraneoplastic cutaneous vasculitis, due to overlap of events and confounding factors. The two factors that might suggest a paraneoplastic etiology of the vasculitis could be the outbreak of vasculitis during the year before the diagnosis of the relapse of her stage IV breast cancer - which fits with the mean time necessary to develop the disease, and the age of the patient and onset of skin lesions. The vasculitis and neoplasm followed somewhat a parallel course, with improvement in both disorders when treatment was started. However, during the recurrence of her cutaneous lesions, the CEA level remained low, and her surveillance exams were all unremarkable.

On the other hand, the elevated sedimentation rate, p-ANCA positivity, and onset of arthralgia closely preceding cutaneous vasculitis soon after the use of aromatase inhibitors supported a case of DIV. However, the persistence of disease symptoms with progression after discontinuation of the medication was atypical for a drug eruption. The patient was placed on other medications (fulvestrant and trastuzumab) which might induce or sustain cutaneous vasculitis. This is the first report of an association of trastuzumab and cutaneous vasculitis.

Her p-ANCA positivity raises the suspicion of ANCA-related vasculitis with cutaneous manifestations. Although our patient was MPO negative, the test was performed when her skin lesions had resolved and, in acute settings, ANCA seroconversion has been shown to be temporally related to a change of clinical course. Thus, the patient’s ANCA profile cannot exclude the possibility of MPO positivity, and the possibility remains of more than one neutrophil cytoplasm antigen to support a diagnosis of DIV.

We suggest thorough investigation of apparently idiopathic cutaneous leukocytoclastic vasculitis - especially in patients aged over 50. Also, in cases in which DIV is suspected, laboratory tests should include ANCA, ANA and anticardiolipin Ab. For ANCA screening, testing of other protein markers such as HLE, cathepsin G and lactoferrin should be available to aid diagnosis. This combined approach may lead to better understanding, recognition and cure of vasculitic presentations.

Acknowledgements

Supported in part by the National Institutes of Health (NIH) grants AR53463 (to M.W.), AI 46776 (to B.H.H.), and AR53239 (to A.L.C.). The contents of this work are solely responsibility of the authors and do not necessarily represent the official views of the NIH.

NIH-PA Author Manuscript

NIH-PA Author Manuscript

NIH-PA Author Manuscript

References

1. Kurzrock R, Cohen P. Vasculitis and cancer. Clin Dermatol 1993;11(1):175– 187. [PubMed: 8339194]
2. Kurzrock R, Cohen P, Markowitz A. Clinical manifestations of vasculitis in patients with solid tumors. Arch Intern Medical 1994;154(3):334– 340.
3. Cabuk M, et al. Cyclic lymphocytic vasculitis associated with chronic lymphocytic leukemia. Leuk Lymphoma 2004;45(4):811–813. [PubMed: 15160961]
4. Desch J, Smoller B. The spectrum of cutaneous disease in leukemias. J Cutan Pathol 1993;20(5):407–410. [PubMed: 8300925]
5. Carlson J, Ng B, Chen K. Cutaneous vasculitis update: diagnostic criteria, classification, epidemiology, etiology, pathogenesis, evaluation and prognosis. Am J Dermatopathol 2005;27(6):504–528. [PubMed: 16314707]
6. Choi H, et al. Drug-associated antineutrophil cytoplasmic antibody-positive vasculitis: prevalence among patients with high titers of antimyeloperoxidase antibodies. Arthritis Rheum 2000;43(2):405–413. [PubMed: 10693882]
7. Kitahara T, et al. Case of propylthiouracil-induced vasculitis associated with anti-neutrophil cytoplasmic antibody (ANCA); review of literature. Clin Nephrol 1997;47(5):336–340. [PubMed: 9181282]
8. Wiik A. Dug-induced vasculitis. Curr Opin Rheumatol 2008;20:35–39. [PubMed: 18281855]
9. ten Holder S, Joy M, Falk R. Cutaneous and systemic manifestations of drug-induced vasculitis. Ann Pharmacother 2002;36(1):130–147. [PubMed: 11816242]
10. Thong H, Chu C, Chiu H. Methimazole-induced antineutrophil cytoplasmic antibody (ANCA)-associated vasculitis and lupus-like syndrome with a cutaneous feature of vesiculo-bullous systemic lupus erythematosus. Acta Derm Venereol 2002;82(3):206–208. [PubMed: 12353714]
11. Herlin T, et al. Anti-neutrophil cytoplasmic autoantibody (ANCA) profiles in propylthiouracil-induced lupus-like manifestations in monozygotic triplets with hyperthyroidism. Scand J Rheumatol 2002;31(1):46–49. [PubMed: 11924649]
12. Sato H, et al. High prevalence of antineutrophil cytoplasmic antibody positivity in childhood onset Graves' disease treated with propylthiouracil. J Clin Endocrinol Metab 2000;85(11):4270–3. [PubMed: 11095466]
13. Slamon D, et al. Studies of the HER-2/neu proto-oncogene in human breast and ovarian cancer. Science 1989;244(4905):707–712. [PubMed: 2470152]
14. Cooke T, et al. HER2 as a prognostic and predictive marker for breast cancer. Ann Oncol 2001;12 (Suppl 1):S23–28. [PubMed: 11521717]
15. Castillo L, et al. Pharmacological background of EGFR targeting. Ann Oncol 2004;15(7):1007–1112. [PubMed: 15205192]
16. Yarden Y. The EGFR family and its ligands in human cancer. signalling mechanisms and therapeutic opportunities. Eur J Cancer 2001;37(Suppl 4):S3–8. [PubMed: 11597398]
17. Ciardiello F, Tortora G. EGFR antagonists in cancer treatment. N Engl J Med 2008;358(11):1160–1174. [PubMed: 18337605]
18. Pagano M, et al. Cyclin A is required at two points in the human cell cycle. EMBO J 1992;11(3): 961–971. [PubMed: 1312467]
19. Ridgway P, Almouzni G. Chromatin assembly and organization. J Cell Sci 2001;114(Pt 15):2711–2712. [PubMed: 11683405]
20. Le X, et al. Anti-HER2 antibody trastuzumab inhibits CDK2-mediated NPAT and histone H4 expression via the PI3K pathway. Cell Cycle 2006;5(15):1654–1661. [PubMed: 16861913]
21. Zhao J, et al. NPAT links cyclin E-Cdk2 to the regulation of replication-dependent histone gene transcription. Genes Dev 2000;14(18):2283–2297. [PubMed: 10995386]
22. Sherr C, Roberts J. Living with or without cyclins and cyclin-dependent kinases. Genes Dev 2004;18 (22):2699–2711. [PubMed: 15545627]
23. Baselga J. A review of EGFR targeted therapy. Clin Adv Hematol Oncol 2003;1(14):218–219. [PubMed: 16224409]

NIH-PA Author Manuscript NIH-PA Author Manuscript NIH-PA Author Manuscript

24. Busam K, et al. Cutaneous side-effects in cancer patients treated with the antiepidermal growth factor receptor antibody C225. Br J Dermatol 2001;144(6):1169–76. [PubMed: 11422037]
25. Van Doorn R, et al. Follicular and epidermal alterations in patients treated with ZD1839 (Iressa), an inhibitor of the epidermal growth factor receptor. Br J Dermatol 2002;147(3):598–601. [PubMed: 12207609]
26. Segaert S, et al. Management of EGFR-inhibiotr-related skin reactions. J Dtsch Dermatol Ges 2005;3 (8):599–606. [PubMed: 16033478]
27. Boeck S, Wollenberg A, Heinemann V. Leukocytoclastic vasculitis during treatment with the oral EGFR tyrosine kinase inhibitor erlotinib. Ann Oncol 2007;18(9):1582–1583. [PubMed: 17761714]
28. Wen X, et al. HER2 signaling modulates the equilibrium between pro- and ntiangiogenic factors via distinct pathways: implications for HER2-targeted antibody therapy. Oncogene 2006;2(25):6986–6996. [PubMed: 16715132]
29. Albanell J, et al. Pharmacodynamic studies of the epidermal growth factor receptor inhibitor ZD1839 in skin from cancer patients: histopathologic and molecular consequences of receptor inhibition. J Clin Oncol 2002;1(20)
30. Jones K, Buzdar A. A review of adjuvant hormonal therapy in breast cancer. Endocrine-related Cancer 2004;11:392–406.
31. Candelaria M, et al. Tamoxifen-associated vasculitis in a breast cancer patient. World J Surg Oncol 2007;23(5):9, 5. [PubMed: 17244373]
32. Conti-Beltraminelli M, et al. Henoch–Schönlein purpura (HSP) during treatment with anastrozole. Annals of Oncology 2007;18(1):205–207. [PubMed: 17043095]
33. Drago F, Arditi M, Rebora A. Tamoxifen and purpuric vasculitis. Ann Intern Med 1990;112(12): 965–966. [PubMed: 2140253]
34. Shoda H, et al. Cutaneous vasculitis developed in a patient with breast cancer undergoing aromatase inhibitor treatment. Ann Rheum Dis 2005;64:651–652. [PubMed: 15769928]
35. McLean D. Cutaneous paraneoplastic syndromes. Arch Dermatol 1986;122:765– 767. [PubMed: 3729508]
36. Pelajo C, et al. Cutaneous vasculitis as a paraneoplastic syndrome in childhood. Acta Reumatol Port 2007;32(2):181–183. [PubMed: 17572653]
37. Sánchez-Guerrero J, et al. Vasculitis as a paraneoplastic syndrome. Report of 11 cases and review of the literature. J Rheumatol 1990;17(11):1458–1462. [PubMed: 2273485]
38. Greer J, et al. Vasculitis associated with malignancy. Experience with 13 patients and literature review. Medicine (Baltimore) 1988;67(4):220–230. [PubMed: 3292873]
39. Hayem G, et al. Systemic vasculitis and epithelioma. Rev Rhum Engl Ed 1997;64(12):816– 824. [PubMed: 9476271]
40. Fortin P. Paraneoplastic rheumatic syndromes. Curr Opin Rheumatol 1996;8(1):30–33. [PubMed: 8867536]
41. Hutson T, Hoffman G. Temporal concurrence of vasculitis and cancer: a report of 12 cases. Arthritis Care Res 2000;13(6):417–423. [PubMed: 14635319]
42. González-Gay M, et al. Cutaneous vasculitis and cancer: a clinical approach. Clin Exp Rheumatol 2000;18(3):305–307. [PubMed: 10895365]
43. Bayer-Garner I, Smoller B. The spectrum of cutaneous disease in multiple myeloma. J Am Acad Dermatol 2003;48(4):497–507. [PubMed: 12664010]
44. Longley S, Caldwell J, Panush R. Paraneoplastic vasculitis. Unique syndrome of cutaneous angiitis and arthritis associated with myeloproliferative disorders. Am J Med 1986;80:1027– 1031. [PubMed: 3728500]
45. Cohen P, Kurzrock R. Mucocutaneous paraneoplastic syndromes. Semin Oncol 1997;24(3):334–359. [PubMed: 9208889]
46. Fam A. Paraneoplastic rheumatic syndromes. 1: Baillieres. Best Pract Res Clin Rheumatol 2000;14 (3):515–533.

NIH-PA Author Manuscript

NIH-PA Author Manuscript

NIH-PA Author Manuscript

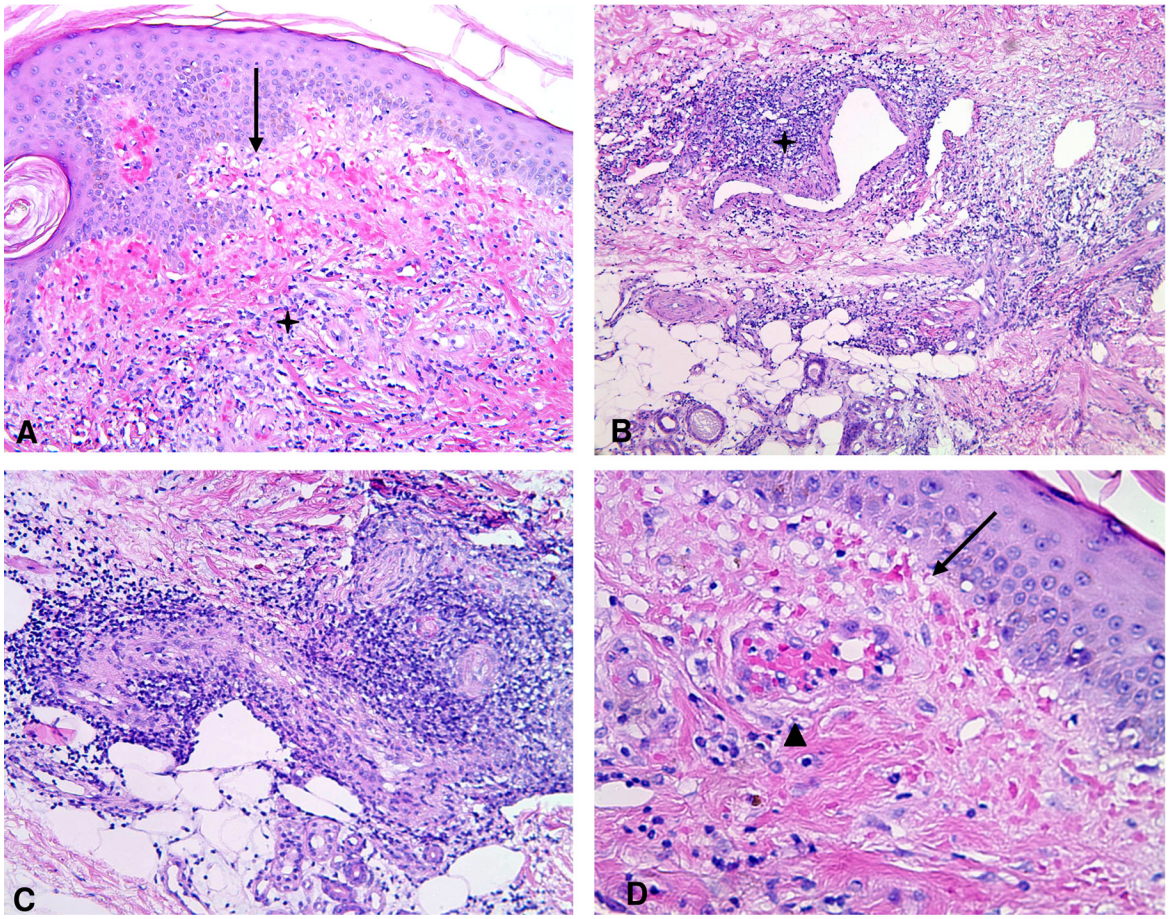

Figure 1.

Hematoxylin/eosin staining of full-thickness skin biopsy at the right calf. A. Parakeratosis and vacuolar alteration along the dermoepidermal junction (arrow), with superficial perivascular and mixed infiltrate composed of neutrophils, eosinophils and lymphocytes (star). B. Deep perivascular and interstitial lymphocytic infiltrates (star). C. Lymphocytic infiltration into the medium size vessel wall, with occlusion. A-C: magnification: 100x. D. Fibrin thrombi in a superficial small size vessel (triangle), vacuolar alteration in the dermoepidermal junction (arrow). Magnification: 400x.

NIH-PA Author Manuscript

NIH-PA Author Manuscript

NIH-PA Author Manuscript

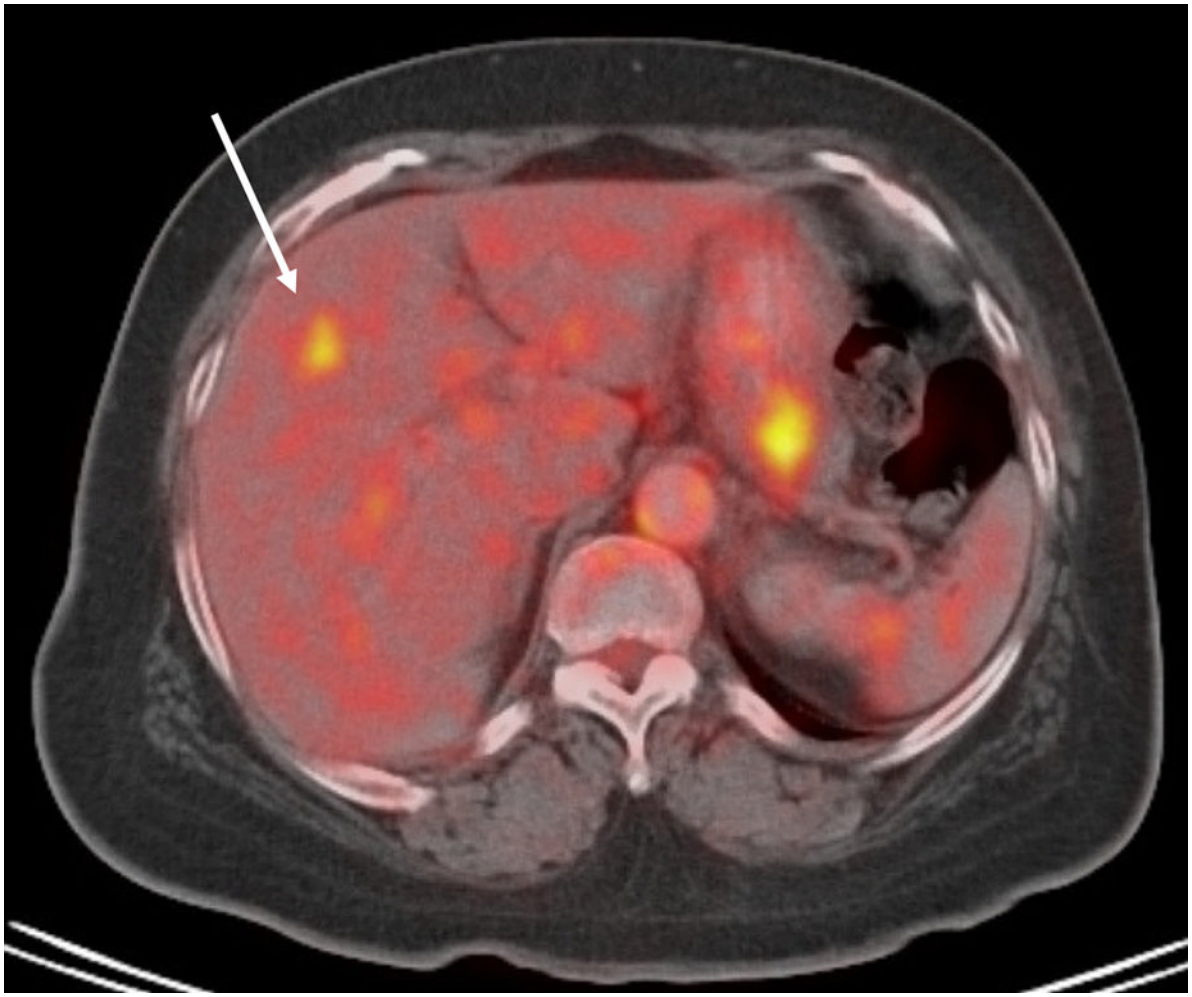

Figure 2.
PET CT scan of the abdomen shows an increased 18-fluro-2-deoxyglucose (FDG) activity in the medial segment of the left lobe of the liver (white arrow). The brightness on the right side at the gallbladder is an artifact (as found in the presence of inflammatory conditions).

NIH-PA Author Manuscript

NIH-PA Author Manuscript

NIH-PA Author Manuscript

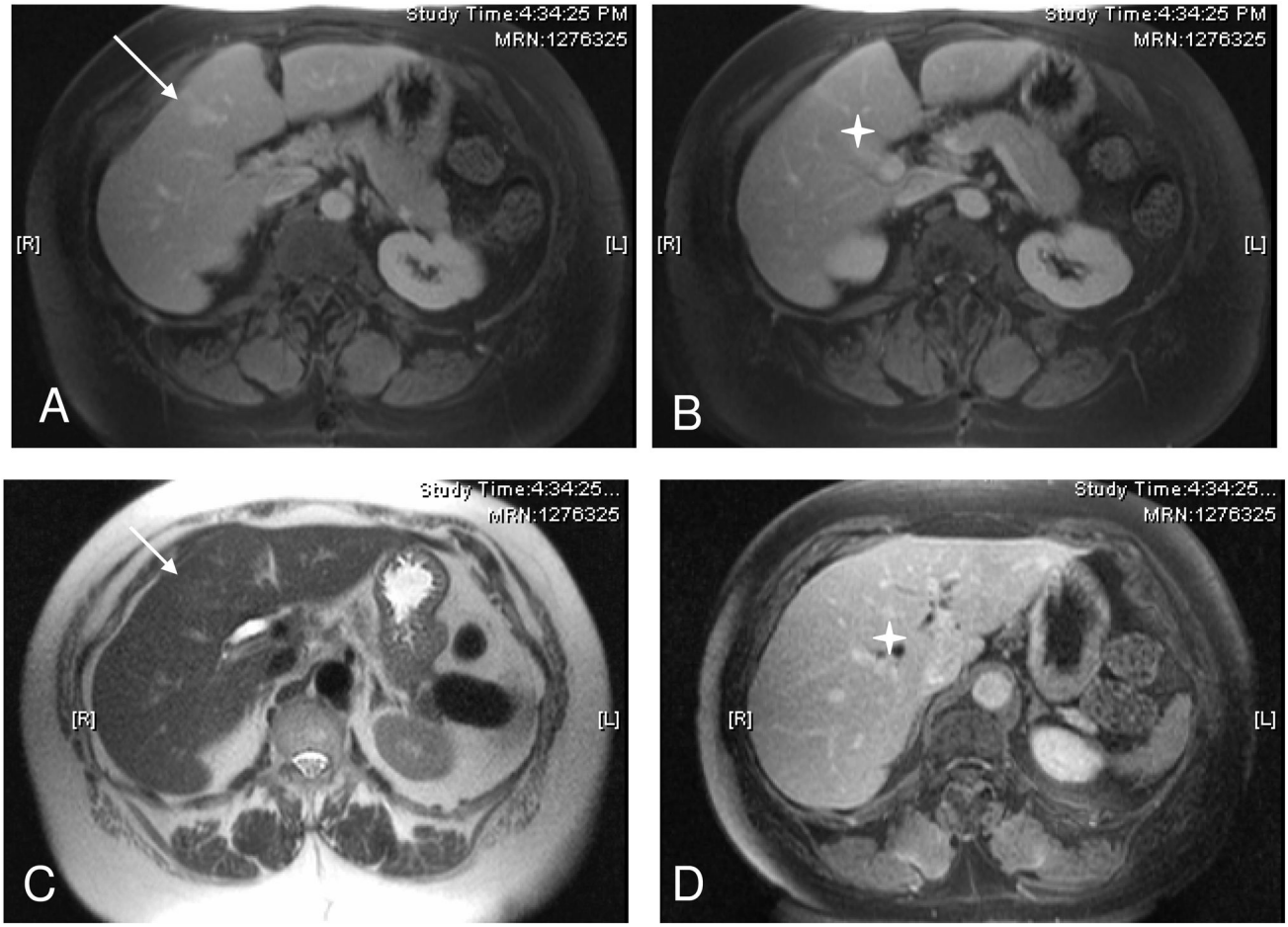

Figure 3.

MRI of the abdomen, with and without contrast. A. T1 weighted image shows hypointense lesion in the medial left lobe of the liver, with enhancement in portal venous phase (white arrow). B. T1-weighted image indicates an ill-defined enhancement that extends to the surface of the liver, with suggestion of focal capsular retraction (star). C. T2-weighted image shows a mildly increased signal in the same area where the lesion is noted in Figure 1A. D. T2-weighted image shows the periphery of the lateral left lobe of the liver with a portal venous phase enhancement that persists on delayed images.

NIH-PA Author Manuscript

NIH-PA Author Manuscript

NIH-PA Author Manuscript

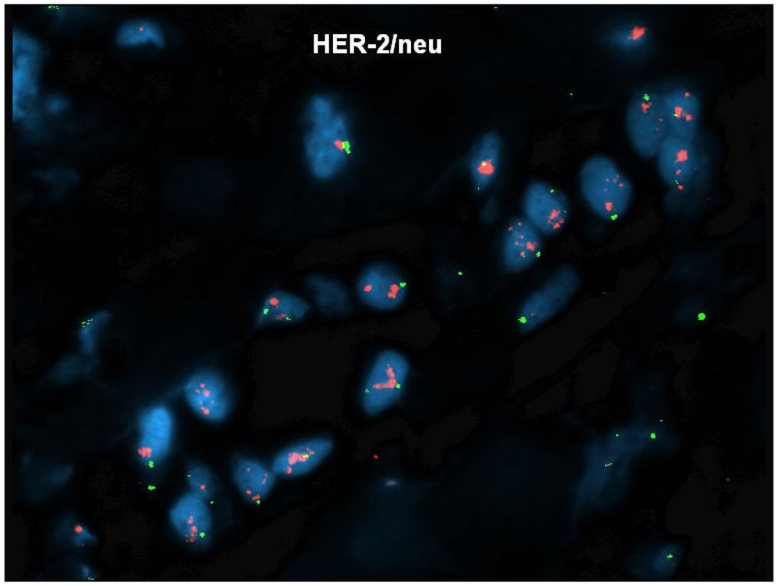

Figure 4.

Fluorescence in situ hybridization (FISH) for Her-2/neu gene in bladder cells. Green signals are specific for the chromosome 17 centromere (D17z1), and red signals represent the nuclei with the Her-2 gene. Her-2 amplification is expressed as ratio of Her-2 to D17z1 = 6.3. Scan: 40x.