

SURGICAL TECHNIQUES

Laser iridotomy in dark irides

Don Julian de Silva, Gus Gazzard, Paul Foster

Br J Ophthalmol 2007;91:222–225. doi: 10.1136/bjo.2006.104315

See end of article for authors' affiliations

Correspondence to: Mr Paul Foster, Department of Epidemiology, UCL Institute of Ophthalmology, 11-43 Bath Street, London EC1V 9EL, UK; p.foster@ucl.ac.uk

Accepted 23 September 2006

Background: Laser iridotomy is the established treatment for angle-closure glaucoma. Nd:YAG (neodymium: yttrium–aluminium–garnet) laser iridotomy is challenging in the heavily pigmented irides of African and Asian patients,

Aim: To present a modified laser iridotomy technique for use in dark irides.

Methods: The argon laser was applied in two stages: firstly, low-power argon was applied, which created a circular area of pitted iris stroma in the superior iris. High-power argon was then applied in the same area to form a punched-out crater at the level of the radial muscle fibres. The iridotomy was then completed with low-energy YAG laser.

Results: 15 eyes of 8 consecutive patients who underwent successful combined argon–YAG laser iridotomy using low levels of YAG energy in dark irides is presented. The combined technique avoids common issues associated with the use of pure YAG laser, including high energy levels and a high risk of iris haemorrhage.

Conclusions: Combined two-stage argon and YAG laser is an effective technique in the treatment of angle-closure glaucoma of dark irides of African and Asian patients. The technique is more effective and has reduced complications in comparison to pure argon or YAG laser techniques.

Laser iridotomy is the established treatment of angle-closure glaucoma and the procedure may be achieved with the argon or Nd:YAG (neodymium: yttrium–aluminium–garnet) lasers. YAG laser iridotomy is an effective treatment for light-coloured irides; however, African, Asian and Chinese irides are often thicker and more heavily pigmented, and the YAG laser is less effective on them.¹ Argon laser is well absorbed by the pigment of dark-coloured irides; however, high energy is required and incomplete partial thickness iridotomy has been reported in up to 20% of cases.^{2–4} More recently, Ho and Fan³ described the use of sequential argon–YAG lasers to perform iridotomy in dark irides of a Chinese origin. Using this technique, the application of high-power argon laser invariably creates large, adherent gas bubbles, which severely limit the application of further laser shots. In addition, the technique was more difficult in eyes of African patients in whom the irides were often thicker and more heavily pigmented. We present a modified technique for sequential argon–YAG laser iridotomy using a two-stage argon laser application. The first stage uses a low-power argon laser to treat the iris stromal surface, which helps to avoid the creation of large gas bubbles, followed by a higher-power setting to produce a stromal crater.

The iridotomy was then completed through the thinned argon-treated iris with low-energy YAG laser.

METHOD

Before laser treatment all patients underwent ophthalmic evaluation, and informed consent was obtained. All patients were diagnosed with primary angle closure with iridotrabecular contact ($>90^\circ$). Pilocarpine drops (4%) were administered, followed by one drop of 0.5% apraclonidine at least 30 min before the procedure, with a second dose immediately before starting treatment.

A drop of 0.5% proxymetacaine was administered, followed by placement of an Abraham contact lens (Ocular Instruments, Bellvue, Washington, DC, USA). The superior iris was assessed, and where possible an iris crypt selected. The argon laser was applied in two stages. Firstly, a low power of 95–180 mW was applied for 0.05 s, 50 μ m diameter of between 15 and 25 laser shots (table 1). The aim was to create a circular area of pitted iris stroma of approximately 250 μ m in diameter, resembling a rosette in appearance (fig 1). Secondly, a high power of 700 mW was applied for 0.1 s, 50 μ m diameter of between 10 and 25 laser shots. This produced a punched-out crater to the

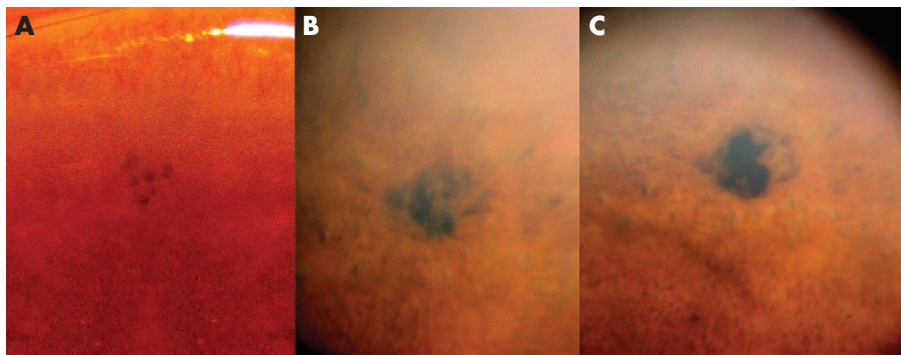


Figure 1 Right: photograph of the superior pitted iris following after low-power argon laser treatment. Centre: punched-out crater appearance of the iris following after high-power argon laser treatment. Left: laser iridotomy of approximately 200 μ m diameter following after YAG laser treatment.

Table 1 Characters of patients who received the combined argon-YAG (yttrium-aluminium-garnet) laser technique

Patient number	Eye	Origin of patient	Age (years)	Low-power argon laser			High-power argon laser			YAG laser			Total energy (J)	Complications	Post-laser iridotomy patency
				Diagnosis	Shots	Power (W)	Energy (J)	Shots	Power (W)	Energy (J)	Shots	Energy (J)			
1	LE	African	63	PAC	15	0.10	0.075	17	700	1.19	32	0.061	1.326	Minor iris haemorrhage	Y
2	RE	Indian	29	PAC	23	0.12	0.138	25	700	1.75	53	0.065	1.9527	Minor iris haemorrhage	Y
	23				0.18	0.207	12	700	0.84	50	0.040	1.0866	Y		
3	RE	Indian	64	PAC	19	0.15	0.143	11	700	0.77	22	0.036	0.9481	Minor iris haemorrhage	Y
4	LE	Indian	50	PAC	19	0.15	0.143	13	700	0.91	25	0.043	1.0957		Y
	RE				19	0.13	0.124	11	700	0.77	15	0.015	0.9081		Y
5	LE	Indian	65	PAC	18	0.13	0.117	13	700	0.91	14	0.014	1.0408	Minor iris haemorrhage	Y
	RE				20	0.095	0.095	20	700	1.40	0.031	1.526	Y		
6	LE	Indian	60	PAC	20	0.095	0.095	21	700	1.47	24	0.028	1.593	Minor iris haemorrhage	Y
	RE				20	0.10	0.100	13	700	0.91	4	0.004	1.0144		Y
7	LE	Indian	48	PAC	21	0.10	0.105	16	700	1.12	4	0.005	1.2296	Minor iris haemorrhage	Y
	RE				15	0.10	0.075	11	700	0.77	39	0.063	0.9076		Y
8	LE	Greek	55	PAC	16	0.10	0.080	14	700	0.98	54	0.077	1.1374	Minor iris haemorrhage	Y
	RE				21	0.12	0.126	18	700	1.26	9	0.009	1.3946		Y
	LE				15	0.12	0.090	18	700	1.26	4	0.004	1.3541		Y
Range			29–65		15–23	0.095–0.18	0.075–0.207	11–25	700	0.77–1.75	4–54	0.004–0.077	0.908–1.953		
Mean (SD)			54 (12)		19 (3)	0.119 (0.03)	0.114 (0.04)	16 (4)	700	1.087 (0.30)	24 (18)	0.033 (0.03)	1.234 (0.29)		

LE, left eye; PAC, primary-angle closure defined by iridotrabecular contact ($>90^\circ$); RE, right eye; YAG, yttrium-aluminium-garnet.

level of the radial muscle fibres and vasculature (fig 1). The iridotomy was completed with YAG laser, 1–3 mJ shots, using between 4 and 55 laser shots. The objective of the YAG treatment is to achieve a full thickness iridotomy, and circumferentially enlarge the hole, aiming for a 200 µm diameter.⁵

Patients were assessed 1 h after treatment and the intraocular pressures measured. After laser treatment, all patients were treated with 1% prednisolone acetate hourly for 24 h and then four times a day until reviewed in clinic 1 week later.

RESULTS

We present 15 eyes of 8 patients with dark irides who underwent the combined argon–YAG laser technique (table 1). In all cases, a patent laser iridotomy was created after a single procedure using low-energy YAG laser energy (mean (SD) 33 (25) mJ). Minor iris haemorrhage was identified in three eyes and was stopped by light pressure with the Abraham contact lens. At 1 week after laser treatment, no inflammation was clinically observed, and a satisfactory iridotomy⁵ diameter of 200 µm was achieved in all cases with a single treatment.

DISCUSSION

During the 1970s, the argon laser was the first laser to be used for performing a non-invasive iridotomy. The argon laser photocoagulates tissues, absorption by iris pigment results in heating, the coagulation of blood and collagen, with shrinking and charring of tissue. Although the laser was well absorbed by iris pigment, argon laser iridotomy alone was often associated with a high failure rate (20% in brown eyes²), and a high subsequent closure rate of up to 30%.^{2–6} In addition, the use of full-thickness argon laser iridotomy was associated with a 10% risk of endothelial cell loss,⁷ and retinal burns were reported.^{8–9}

During the 1980s, the YAG laser was introduced. The YAG laser photodisrupted tissues, focal nanosecond pulses stripped electrons from atoms within the iris, and generated a plasma that rapidly expanded and collapsed, which created a shock wave at the site of focus.^{10–11} The technique was highly effective in light-coloured irides,¹ required considerably less total energy than pure argon laser iridotomy and achieved a higher rate of single treatment success and lower risk of subsequent closure. However, YAG laser iridotomy had drawbacks in highly pigmented irides; high levels of laser energy were required and up to 40% of cases were complicated with iris haemorrhage.^{7–12–14} The haemorrhage may be severe and warrant postponing the procedure or repeating the treatment at an alternative site.¹ Focal corneal opacity above the YAG iridotomy site was identified in up to 35% cases^{7–15} with a reduction in endothelial cell count,¹⁶ dependent on two factors: the distance between the endothelium and iris surface, and the total YAG energy used.^{17–18} In patients with angle-closure glaucoma, there is <1 mm between the mid-peripheral iris and the posterior cornea.^{18–19} Although a more mid-peripheral iridotomy is beneficial to the endothelium, there is an increased risk of postoperative glare and diplopia.¹⁸ A lower energy requirement to complete a YAG iridotomy would be favourable to avoid detrimental effects on the endothelium.

Sequential argon–YAG laser was proposed for use in the dark irides of Chinese patients.³ The argon laser energy is well absorbed by the heavy iris pigment¹ and creates a flattened partial thickness thinning of black pigment crust, with low risk of a retinal burn. Subsequent YAG laser in the area of iris thinning is efficient, using only a third of the corresponding power reported for pure YAG laser iridotomy.³ Pure YAG laser iridotomy often requires high levels of energy to achieve a patent iridotomy in dark irides, and evidence suggests that this may have a detrimental effect on the endothelial cell count.^{16–18}

Summary

We present a modified laser technique for the treatment of primary angle-closure and angle-closure glaucoma in the dark irides of African and Asian patients. We found the combined argon–YAG (yttrium–aluminium–garnet) laser iridotomy technique to have advantages over conventional pure YAG and argon laser.

Although the clinical relevance of this reduction is not known, patients with pre-existing corneal disorders may be placed at risk of endothelial decompensation with high energy YAG laser, and we propose the standard use of argon pre-treatment in these patients. The use of the two-step low-power and high-power argon technique resulted in >50% reduction in total laser energy compared with the previous single-setting combined argon–YAG technique (mean laser energy reduced from 3.609 J³ to 1.234 J). In addition, the morphology of the iridotomy is often large and round, in contrast with the slit opening of YAG iridotomy. Although the combined argon–YAG laser iridotomy required the use of two lasers, the technique is effective with a single sitting.

The combined argon–YAG iridotomy described previously³ is an effective technique; however, we found some limitation with the use of high-power argon laser settings in highly pigmented irides, which often resulted in the generation of large, adherent vapour bubbles at the iris surface. These bubbles are of sufficient size to obscure the underlying iris; although tapping the Abraham lens may dislodge them, this may considerably prolong the procedure. An obscured view of the iris may be potentially hazardous, as pure argon laser iridotomy has been associated with focal lens damage in up to 50% of cases, more rarely retinal burns,^{1–7–12} and may damage the corneal endothelium leading to corneal decompensation.^{20–21} We found that by modifying the argon laser treatment to a two-stage process, low power followed by high power, large vapour bubbles can be avoided. Small vapour bubbles may be formed; however, shooting the laser at the edge of these small vapour bubbles released them from the iris surface.

Iris haemorrhage is a common complication of pure YAG laser iridotomy, occurring in up to 40% of procedures.^{7–12–13} We found iris haemorrhage to be an uncommon complication of combined argon–YAG laser. Minor iris haemorrhage could be stemmed by gentle digital pressure on the Abraham contact lens; no procedure required postponing or treatment at an alternative site.

Combined argon–YAG laser is an effective technique in the dark irides of African and Asian patients. The combined laser offers advantages over conventional pure YAG or argon laser treatments, including a marked reduction in total YAG energy, reduced risk of iris haemorrhage and high patency after primary treatment.

Authors' affiliations

Don Julian de Silva, G Gazzard, P Foster, Moorfields Eye Hospital, London, UK

Competing interests: None.

REFERENCES

- 1 Ho TK, Fan RF. Laser iridotomies in Asian eyes. *Ann Acad Med Singapore* 1994;23:49–51.
- 2 Schwartz LW, Rodrigues MM, Spaeth GL, et al. Argon laser iridotomy in the treatment of patients with primary angle-closure or pupillary block glaucoma: a clinicopathologic study. *Ophthalmology* 1978;85:294–309.
- 3 Ho T, Fan R. Sequential argon-YAG laser iridotomies in dark irides. *Br J Ophthalmol* 1992;76:329–31.

- 4 **Ritch R.** *Techniques of argon laser iridectomy and iridoplasty.* Palo Alto, CA: Coherent Medical, 1983.
- 5 **Fleck BW.** How large must an iridotomy be? *Br J Ophthalmol* 1990;**74**:583–8.
- 6 **Quigley HA.** Long-term follow-up of laser iridotomy. *Ophthalmology* 1981;**88**:218–24.
- 7 **Robin AL, Pollack IP.** A comparison of neodymium: YAG and argon laser iridotomies. *Ophthalmology* 1984;**91**:1011–16.
- 8 **Berger BB.** Foveal photocoagulation from laser iridotomy. *Ophthalmology* 1984;**91**:1029–33.
- 9 **Bongard B, Pederson JE.** Retinal burns from experimental laser iridotomy. *Ophthalmic Surg* 1985;**16**:42–4.
- 10 **Kielkopf JF.** Laser-produced plasma bubble. *Phys Rev E Stat Nonlin Soft Matter Phys* 2001;**63**(Pt 2):016411.
- 11 **Vogel A, Busch S, Jungnickel K, et al.** Mechanisms of intraocular photodisruption with picosecond and nanosecond laser pulses. *Lasers Surg Med* 1994;**15**:32–43.
- 12 **Del Priore LV, Robin AL, Pollack IP.** Neodymium: YAG and argon laser iridotomy. Long-term follow-up in a prospective, randomized clinical trial. *Ophthalmology* 1988;**95**:1207–11.
- 13 **Moster MR, Schwartz LW, Spaeth GL, et al.** Laser iridectomy. A controlled study comparing argon and neodymium: YAG. *Ophthalmology* 1986;**93**:20–4.
- 14 **Fleck BW, Dhillon B, Khanna V, et al.** A randomised, prospective comparison of Nd:YAG laser iridotomy and operative peripheral iridectomy in fellow eyes. *Eye* 1991;**5**(Pt 3):315–21.
- 15 **Schwartz LW, Moster MR, Spaeth GL, et al.** Neodymium-YAG laser iridotomies in glaucoma associated with closed or occludable angles. *Am J Ophthalmol* 1986;**102**:41–4.
- 16 **Kerr Muir MG, Sherrard ES.** Damage to the corneal endothelium during Nd/YAG photodisruption. *Br J Ophthalmol* 1985;**69**:77–85.
- 17 **Meyer KT, Pettit TH, Straatsma BR.** Corneal endothelial damage with neodymium:YAG laser. *Ophthalmology* 1984;**91**:1022–8.
- 18 **Wu SC, Jeng S, Huang SC, et al.** Corneal endothelial damage after neodymium:YAG laser iridotomy. *Ophthalmic Surg Lasers* 2000;**31**:411–16.
- 19 **Marruffa M, Marchini G, Pagliaruso A, et al.** Ultrasound biomicroscopy and corneal endothelium in Nd:YAG-laser iridotomy. *Ophthalmic Surg Lasers* 1995;**26**:519–23.
- 20 **Jeng S, Lee JS, Huang SC.** Corneal decompensation after argon laser iridectomy—a delayed complication. *Ophthalmic Surg* 1991;**22**:565–9.
- 21 **Wilhelmus KR.** Corneal edema following argon laser iridotomy. *Ophthalmic Surg* 1992;**23**:533–7.