

ENDOSCOPIC THERAPY FOR BARRETT'S OESOPHAGUS

Recent advances in clinical practice

H Barr, N Stone, B Rembacken

875

Gut 2005;54:875–884. doi: 10.1136/gut.2004.047118

INTRODUCTION

Barrett's oesophagus or columnar lined oesophagus is among the most intriguing of gastroenterological conditions. This is because of its pathogenesis, prevalence, association with reflux disease, male sex and, in particular, the potential for neoplastic degeneration to adenocarcinoma. The current and dramatic rise in the incidence of oesophageal adenocarcinoma is centred on the UK (5–8.7/100 000), over double that of the USA (3.7/100 000). This epidemic is fairly localised and is not evident in Asia, where squamous cell cancer remains the predominant oesophageal malignancy. Large rises in incidence, up to 30% per year, have been seen in West European White men, a rise not mirrored in Eastern Europe.^{1 2}

At present the incidence remains paralleled by mortality. The prognosis of oesophageal cancer remains universally poor; median survival has hardly changed from 0.75 years between 1973 and 1977 to 0.9 years between 1993 and 1999. This almost trivial change has led some to suggest that the change could be accounted for by improved reporting and detection bias rather than any important therapeutic advance.³

Gradual malignant degeneration within a segment of Barrett's oesophagus occurs in a probabilistic rather than in a deterministic manner. Barrett's appears to be a necessary intermediary step. The relatively long time sequence to cancer may allow early intervention with endoscopic ablation, thus offering the possibility of preventing the lethal development of symptomatic oesophageal adenocarcinoma. Stark choices face patient and clinician in the presence of a degenerating "possibly" premalignant Barrett's mucosa. Radical therapy offers an overaggressive, "possibly" flawed approach if the diagnosis and prognosis remain uncertain. It cannot be considered a triumph to have a millimetre of worrying but superficial disease and remove a whole oesophagus. The alternative of surveillance presents other concerns. It offers intermittent endoscopic inspection at proscribed, economically viable, and societal designated intervals, and awaits the development of cancer; then offers a belated and radical solution.⁴ Early endoscopic detection and therapy offers a possible "middle way". This is particularly appropriate since the diagnostic dilemmas create doubt and indecision.

DIAGNOSTIC DILEMMAS

Accurate and full diagnosis depends on both pathological and endoscopic correlation.⁵ The current definition of Barrett's oesophagus is as a change in the oesophagus epithelium of any length that can be recognised at endoscopy and is confirmed to have intestinal metaplasia by biopsy of the tubular oesophagus and excludes intestinal metaplasia of the cardia. This statement appears simple but its correct application is not straightforward. It would seem self evident that the lower oesophagus can be accurately demarcated; however, this is not the case. Unfortunately, at endoscopic examination its precise boundaries can be easily mistaken.⁶ The distinction of the oesophagus, hiatal hernia, and gastric cardia is often difficult. Similarly, there is a major conundrum for pathologists as there is no characteristic morphological phenotype. Standard teaching is that the gastric cardia is lined by columnar cardiac or junctional epithelium but pathologists are not uniform in their definitions. This epithelium can extend into the oesophagus but is this normal or a variant of Barrett's oesophagus. They can only have confidence that the biopsy is from the oesophagus if an oesophageal gland duct is included.⁷

Much effort and debate is devoted to trying to identify the mechanisms that occur during metaplasia-dysplasia-neoplasia degeneration.⁸ The presence of dysplasia remains the best predictor for malignant degeneration, but can this be identified with certainty? The pathological definition of dysplasia is as "an unequivocal neoplastic alteration of the gastrointestinal epithelium which has the potential to progress to invasive malignancy that remains confined within the basement membrane of the gland within which it arose". There is general agreement on the classification of neoplastic change in the gastrointestinal mucosa. The system has five

See end of article for authors' affiliations

Correspondence to:
Professor H Barr, Cranfield
Postgraduate Medical School,
Gloucestershire Royal
Hospital, Great Western Rd,
Gloucester GL1 3NN, UK;
hugh.barr@glos.nhs.uk

categories; negative for dysplasia, indefinite for dysplasia, low grade dysplasia, high grade dysplasia, and invasive carcinoma.⁹⁻¹² Inter- and intraobserver studies have demonstrated that pathologists can demonstrate acceptable levels of agreement for the two major comparative groups of high grade dysplasia combined with carcinoma, against negative for dysplasia combined with indefinite and low grade dysplasia (kappa values of 0.8). However, the division into the four groups of negative for dysplasia; combined indefinite for dysplasia and low grade dysplasia; high grade dysplasia; and carcinoma has revealed that there are poorer levels of agreement (intraobserver kappa values of 0.64, interobserver kappa values of 0.43).¹³ In 22 patients with indefinite for dysplasia, four progressed to invasive cancer (median progression free survival was 62 months). Similarly, of 25 patients with low grade dysplasia, four progressed (median progression free survival was 60 months). However, of 33 patients with high grade dysplasia, 20 progressed to cancer (median progression free survival eight months).¹⁴ There is a confounding study in which the progression of high grade dysplasia to cancer was far less aggressive. The cumulative cancer incidence over five years was only 9%, with only 12 of 75 (16%) patients developing cancer over 13.9 years of surveillance. This study adopted a very aggressive approach to the diagnosis of synchronous cancer with endoscopic biopsy every three months in the first year before the patient was categorised as having pure high grade dysplasia.¹⁵ These studies create a ubiquitous postmodern dilemma "we can only be certain of our uncertainty". In such a climate there is a clear rationale for the "middle way" of endoscopic therapy.

RATIONALE OF ENDOSCOPIC THERAPY

Even if the finding of high grade dysplasia remains a debateable indicator for radical intervention, surely a major watershed must occur with the diagnosis of intramucosal cancer. It is at this point that intervention with possible major resection may be considered inevitable. The crucial separation of high grade dysplasia from intramucosal cancer depends on penetration of neoplastic cells through the basement membrane to lie in the lamina propria or muscularis mucosa. Even at this stage interobserver agreement between all pathologists and specific gastrointestinal pathologists for high grade dysplasia and intramucosal carcinoma is only fair (kappa values of 0.42 and 0.56, respectively). Unfortunately, this was not seen to improve following repeat evaluation after agreement on uniform histological criteria (kappa values of 0.50 and 0.61, respectively).¹⁶ This study was performed under the ideal circumstances of histological slides from resected oesophageal specimens. Fortunately, submucosal cancer, defined as neoplastic cells penetrating into the submucosa and penetration beyond the muscularis mucosa, was clearly distinguishable from high grade dysplasia (kappa value of 1), but was less clearly differentiated from intramucosal cancer (kappa value of 0.71). These data have profound implications for patients undergoing endoscopic surveillance when the number of biopsies are often collected in a hurried fashion, and are small and difficult to orientate correctly.¹⁷

Some will argue that a diagnosis of high grade dysplasia should still be the end point of surveillance and the patient offered definitive radical therapy. This is usually surgical excision, if the patient is considered fit. This view is justified not only as a prophylactic measure but also because approximately 30% of these patients will have a coexistent

cancer, which is only identified after surgical excision.^{17 18} Data on these initially "occult" post resection detected cancers in patients with high grade dysplasia are so variable (11-73%) that questions as to intensity of preoperative workup and intensity of sampling are raised. A clinician already committed to oesophagectomy at the diagnosis of high grade dysplasia may suspend the search for an invasive cancer. If studies are looked at in a more sophisticated fashion an argument for aggressive initial and repeated frequent biopsy follow up can be convincingly made.^{15 19}

There are a few clinical longitudinal studies that give some further indication of the time sequences involved in the progression or non-progression of high grade dysplasia. Variability is large, with some patients progressing rapidly to invasive cancer and others remaining with persistent dysplasia for prolonged periods. Currently, studies indicate that the average time for progression from high grade dysplasia to cancer is approximately 24 months (range 6-43 months).²⁰ The extent of dysplasia does correlate with the risk of development of cancer. Patients with multifocal disease are five times more likely to progress to cancer than those with focal changes.²¹

PRINCIPLES AND METHODS OF ENDOSCOPIC ABLATION THERAPY

In order to set principles for safe endoscopic therapy, several questions must be addressed. Three relate to the nature of the disease and three to the nature of injury and healing.

The nature of the disease:

- (1) What are the risks of metastatic disease in early oesophageal adenocarcinoma?
- (2) Should the treatment be to the area of dysplasia or of all Barrett's mucosa?
- (3) What is the thickness of Barrett's epithelium and the depth for ablation?

The nature of injury and healing

- (1) Can the method of destruction be safely matched to the depth of disease?
- (2) What are the conditions to allow for safe healing?
- (3) Does the area heal without neoplastic potential?

The nature of the disease

The poor outcome of treatment of oesophageal adenocarcinoma suggests that there may be an unavoidable biological predeterminism, possibly related to early spread. Certainly this appears to be so for invasive cancer (>pT1) as 90% of patients have bone marrow micrometastatic disease.²² The presence of these cells does predict early tumour recurrence.²³ However, a surgical series examining early oesophageal cancer clearly demonstrated that in 10 patients with pT1a lesions measuring 1-8 cm in longitudinal extent (mean 2.5 cm), there were no lymph nodes involved. However, of 36 patients with pT1b lesions invading the submucosa, five had involved regional lymph nodes.²⁴ Accurate staging prior to ablation remains a challenge. This is being addressed by "in vivo pathology" using optical coherence tomography (fig 1). At present, high resolution endosonography has proved unsatisfactory for the detection of early submucosal infiltration, with sensitivities of 48% for ultrasound alone and only 60% when combined with high resolution endoscopy. The problem is much worse at the oesophagogastric junction.²⁵ Thus there is a clear rationale for detection of degeneration at the stage of dysplasia, or pT1a mucosal cancer, at which stage local therapy can cure. Once the

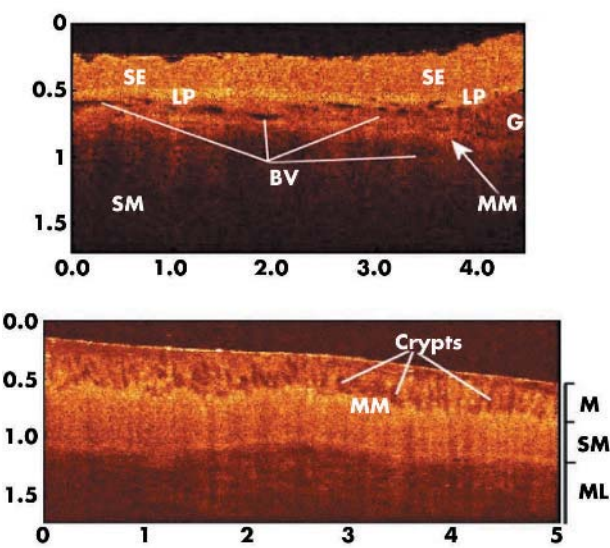


Figure 1 Optical coherence tomography picture demonstrating the thickness of the surface tissue in squamous and columnar lined excised specimens. SE, squamous epithelium; LP, lamina propria; MM, muscularis mucosa; SM, submucosa; BV, blood vessels; G, gland. Measurement scale at the side is in millimetres (courtesy of Professor R Wang, Cranfield University).

disease is invasive, therapy is too late; even radical therapy may well be predetermined to failure.

Secondly, should the whole area be treated or just the area of macroscopic or biopsy proven abnormality. In 41 patients treated with oesophagectomy for early cancer, six had other cancers and 28 had multifocal high grade dysplasia in the Barrett's segment (mean length 6 (1–15) cm).²⁴ Similarly, in 100 patients with dysplastic Barrett's, 33 had focal disease and 67 diffuse disease.²¹ Also, following endoscopic mucosal resection, 14% developed recurrent or metachronous lesions after 12 months of follow up.²⁶ If focal areas are treated then follow up must be rigorous and consideration should be given to eradication of all residual Barrett's oesophagus (fig 2).

Thirdly, it is important to know the thickness of Barrett's oesophagus in order to match the ablative technique with the depth of disease. Columnar lined epithelium measured at histopathology is minimally thicker than normal squamous epithelium, measuring 0.5 mm (range 0.39–0.59 mm) compared with a normal value of 0.49 (range 0.42–0.58 mm).²⁷ It must be assumed that fixation produces 10% shrinkage with a further 10% reduction caused by processing, producing a shrinkage of 20%. Thus the mean thickness of Barrett's epithelium is approximately 0.6 mm. Optical coherence tomography (OCT) of excised unfixed specimens has recorded a depth of between 0.45 and 0.5 mm (fig 2).²⁸ Dysplasia and epithelial cancer are thicker and at OCT appear more optically denser. This represents approximately 15% of the thickness of the distal oesophageal wall, which is approximately 4 mm, as measured by endoscopic ultrasound.²⁹

The nature of injury and healing

Ablation therapy involves an acute mucosal injury, compared with the chronic chemical damage produced by gastro-oesophageal reflux disease. Methods of ablation are dependent on photodynamic, thermal, mechanical (ultrasonic), and cytotoxic destruction. It has to be stated that most of the

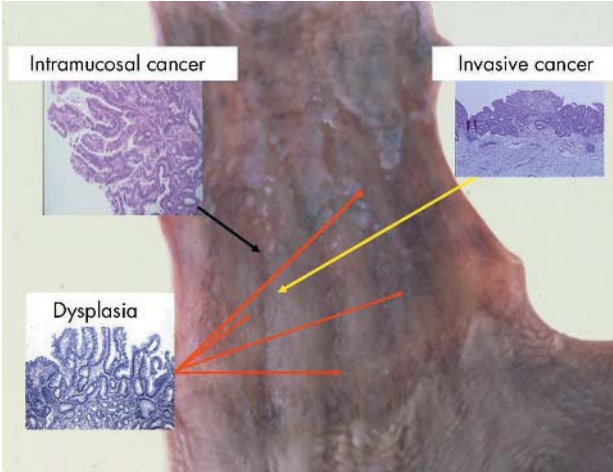


Figure 2 An excised oesophagus, resected for a small invasive Barrett's adenocarcinoma. Areas of dysplasia and intramucosal cancer were identified after excision.

Table 1 Estimated depth of damage for various methods of endoscopic mucosal ablation		
Method of ablation	Approximate depth of ablation (mm)	Author/ref
Argon laser (514 nm)	0.3	Weston 2003 ³⁰
KTP laser (532 nm)	0.4	Dix 1996 ³⁵
Diode laser (805 nm)	1.3	Dix 1996 ³⁵
NdYAG laser (1064 nm)	4–6	Dix 1996 ³⁵
APC (30–90 W)	1–3	Barham 1996, ³¹ Franchimont 2003 ³²
MPEC 15–20 W	1.7–4.8	Sampliner 2003 ³⁰
ALA PDT	2	Tan 1999, ⁴¹ Gossner 1990 ⁴⁰
Exogenous PDT	4–6	Barr 1990, ³⁹ Heier 1995 ³⁸
Cryotherapy	1–4	Johnston 2003 ²⁹

KTP, potassium titanyl phosphate; NdYAG, neodymium yttrium aluminium garnet; APC, argon beam plasma coagulation; MPEC, multipolar electrocoagulation; ALA PDT, 5-aminolaevulinic acid photodynamic therapy.

data on the development of techniques for mucosal ablation of Barrett's oesophagus have been empirical. The principles of treatment are to destroy all the abnormal epithelium and allow regeneration of the mucosa in an environment where the precipitating cause (acid/alkaline/biliary reflux) has been controlled. The constraints of treatment are that these patients may be completely asymptomatic and often healthy. Proton pump inhibitors are very effective for symptomatic control. Also, only a proportion of patients with columnar lined oesophagus will develop invasive carcinoma. Thus "primum nil nocere" is a guiding principle. Any method that causes substantial risks of perforation, bleeding, or serious complications endangering the patient's life are possibly unacceptable. Less serious complications also may not be acceptable to asymptomatic patients. The depth of injury (table 1) and the mechanisms of healing are related in part to the method of ablation.

METHODS OF ABLATION

Thermal

Multipolar electrocoagulation (MPEC) depends on the heating effect of a current passing between electrodes in contact

with the tissue. Usually a 10F probe is used to produce a surface white coagulum over the entire circumferential area of Barrett's oesophagus.³⁰ It has been predominantly used for non-dysplastic Barrett's oesophagus. Strictures requiring dilatation have occurred in less than 1% of patients. Residual areas of Barrett's occur in 8% (0–28%) and the other complications of pain and fever are transient and mild.

Argon beam plasma coagulation (APC) transfers electrical energy to the tissue by means of an ionised electrically conducting plasma of argon gas, delivered at between 1 and 2 litres/minute. APC has certain theoretical safety advantages. The current causing very high temperatures on the surface produces a zone of devitalisation, surrounded by zones of coagulation, desiccation, and tissue shrinkage.^{31–34} As soon as the area on the surface loses electrical conductivity as a result of this desiccation, the plasma beam has to change direction in order to remain electrically conductive. Therefore, the depth effect should be limited and full thickness necrosis and perforation are unlikely to occur.³¹ However, five perforations have been reported; two resolved with conservative medical therapy³³ and three had operations following which two patients died.^{33–34} Strictures are reported in 0–9% of patients and fever may also occur.

Photothermal

On theoretical grounds the potassium titanyl phosphate laser (KTP, at the second harmonic of the neodymium yttrium aluminium garnet (NdYAG) laser) has tissue penetration characteristics that should allow safe thermal treatment of dysplastic columnar lined oesophagus. Three lasers have been directly compared for the thermal destruction of superficial areas of mucosa in the oesophagus using a thermal imaging system. The purpose was to find parameters of between 60 and 100°C (coagulative necrosis+vaporisation) on the luminal (mucosal) surface with less than 37°C (no risk of full thickness necrosis) on the external surface. The three lasers investigated were NdYAG (1064 nm), KTP (532 nm), and diode (805 nm).³⁵ Mounted sections of freshly excised human oesophageal tissue were irradiated on a purpose made jig. The imaging system examined the superficial and deep surface, and looked at the thermal profile. It is certain that in living tissue the thermal relaxation time of the tissue will be reduced because of blood flow. Irradiation with the KTP laser, power 15–20 W for a one second pulse, produced mucosal temperatures of greater than 65°C with a temperature of 21°C on the outer surface of the oesophagus. It was extremely difficult to generate high temperatures on the external surface of the oesophagus using the KTP laser. The diode laser (25 W for five seconds) produced surface temperatures of 90°C but with external temperature of 38°C. The NdYAG laser tended to produce worrying temperatures through to the external surface at energy levels that were sufficient to produce thermal destruction to the mucosa. The KTP laser is generally now used in non-contact mode and set to deliver 15 W.

Cryotherapy and mechanical

Cryotherapy can very effectively destroy a specified volume of tissue with minimal damage to surrounding areas. There are endoscopic devices currently being evaluated.²⁹ Similarly, laparoscopic ultrasonic epithelial ablation is being assessed experimentally but at present requires gastrostomy.

Photodynamic therapy

Photodynamic therapy (PDT) is based on systemic administration of certain photosensitising agents that are retained with some selectivity in rapidly proliferating and malignant tissue. When exposed to appropriate wavelength laser light a cytotoxic reaction mediated by reactive oxygen species (singlet oxygen) occurs causing cellular destruction. One of the attractions of PDT has been the possibility of targeting therapy with selective uptake or retention of the administered photosensitiser in the neoplastic tissue. However, the maximum tumour:normal photosensitiser ratio that can be obtained with a variety of photosensitising agents is only 2–3:1. Investigation of PDT in experimental gastrointestinal neoplasms has demonstrated important biological advantages. Full thickness intestinal damage produced by PDT unlike thermal damage does not reduce the mechanical strength of the bowel or cause perforation because sub-mucosal collagen is preserved. In addition, selective necrosis of small areas (less than 2 mm) is possible with preservation of adjacent non-malignant structures. It is clear that this process is limited to small areas of tissue.³⁶

The most commonly used method of PDT is to administer a photosensitiser intravenously and allow retention in the tissue for 48 hours prior to irradiation with appropriate wavelength light, usually from a laser. The exogenously administered photosensitisers tend to accumulate in tumour stroma and in the submucosal layer of the gastrointestinal tract. The problem of targeting the photosensitiser to the dysplastic mucosa, and reducing systemic photosensitisation, may be overcome by using endogenous photosensitisation. Following excess administration of 5-aminolaevulinic acid (5-ALA), a precursor of haem, intracellular accumulation of the photosensitiser protoporphyrin IX (PpIX) is induced. Synthesis of 5-ALA from glycine and succinyl-CoA is the first step in porphyrin biosynthesis and ultimately haem. This pathway is tightly regulated by end product inhibition. If excess endogenous 5-ALA is administered, then this regulation is bypassed and intracellular accumulation of the photosensitiser protoporphyrin IX (PpIX) is induced.³⁷ The

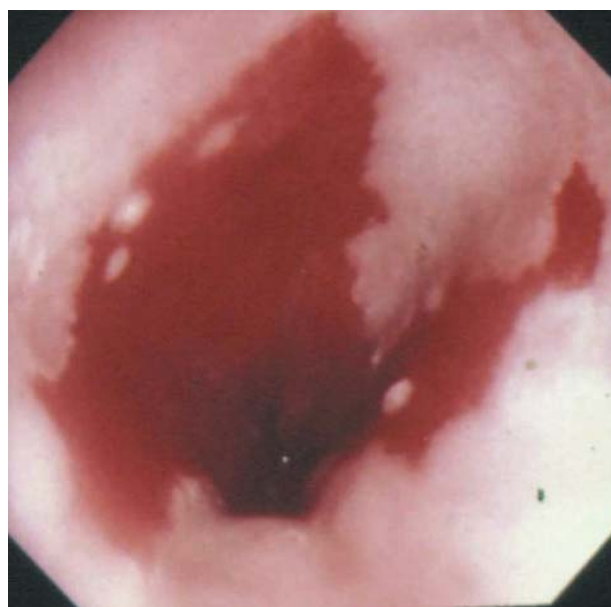

Figure 3 Endoscopic picture of an area of Barrett's oesophagus.

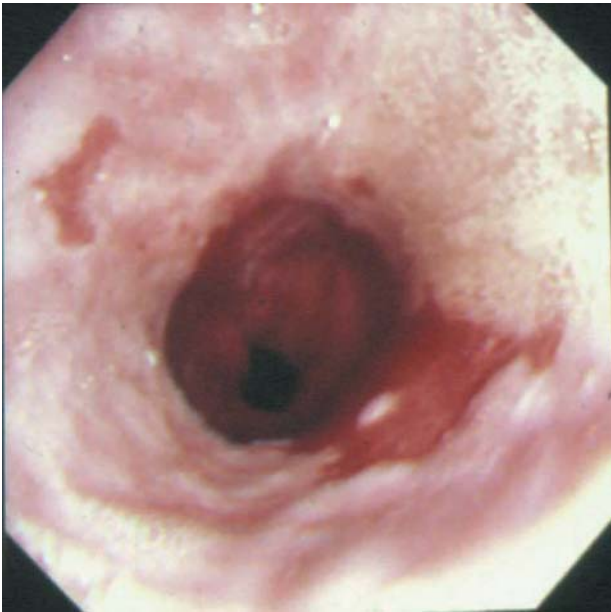

Figure 4 The same area of Barrett's oesophagus six weeks after one half has received photothermal ablation therapy with the KTP laser.

level of systemic and cutaneous photosensitisation is minimised to a few hours. Other photosensitisers can cause skin photosensitivity for up to one month, requiring the patient to avoid direct sunlight or intense light sources. Also, 5-ALA can be administered orally. The photosensitiser is activated in tissue using 630 nm laser light from an appropriate light source, such as a KTP pumped dye or diode laser. The choice of photosensitiser is crucial to achieve the depth of necrosis that is required. The use of an exogenous photosensitiser such as Photofrin or any derivative of di-haematoporphyrin ester/ether will produce damage up to 4–6 mm.^{38–39} PDT to generate PpIX following oral administration of ALA will only produce necrosis to a depth of 2 mm.^{40–41} These measurements are particularly crucial if one is concerned that treatment may not destroy an occult cancer or where there is nodularity and the suspicion of an invasive cancer either clinically or following endoscopic ultrasound evaluation.

MECHANISMS OF HEALING

It is important to examine the mechanisms of regeneration after acute ablation of the surface mucosa. In particular, we must know what structures must be preserved to allow neosquamous regeneration and the level of reflux control that is required.

Conditions for safe healing are of crucial importance and have been addressed in a series of experimental studies.⁴² In a

canine model of gastro-oesophageal reflux, columnar lined oesophagus could be induced and was thought to be associated with regrowth from the proximal columnar lined portion of the deep oesophageal glands. The columnar epithelium was often continuous with the columnar lined portions of these ducts. After full reflux control, an acute injury to the oesophageal mucosa was still associated with some regeneration by columnar cells, as well as squamous islands from the distal squamous part of the oesophageal gland ducts. It was postulated that stems cells, possibly in the oesophageal gland duct, have multi-potentiality for cell differentiation and could produce columnar or squamous cells depending on environmental conditions. Thus the adaptive response to injury under conditions of reflux was to produce columnar epithelium as occurs in the generation of Barrett's oesophagus. Squamous re-epithelialisation could be encouraged by full reflux control. Recent detailed human morphological studies have confirmed that squamous regeneration is universally associated with oesophageal ducts.⁴³

There have been some studies of a rodent model of Barrett's-like oesophagus.⁴⁴ These suggest that the ductal epithelium may not be so crucial as the rat does not have deep oesophageal glands. It is therefore likely that the multi-potential stem cells are not only located in the duct epithelium but reside in the basal layer of the squamous and regenerative columnar epithelium. It appears that the depth of the mucosal injury may be crucial to the type of regeneration.⁴² It has been suggested, but not established, that for squamous cells to predominate, as well as environmental control of reflux being essential, some part of the distal squamous lined oesophageal gland duct must survive. As this duct is the most superficial portion and thus the part most likely to be destroyed by ablation techniques, the empirical evidence does not support this hypothesis. Certainly multi-potential stem cells must survive to regenerate the epithelium but at present the site and source of these cells are unknown, and they may reside deeper in the oesophageal duct. An intriguing study has shown that in a rat model of Barrett's oesophagus some of the epithelium is replaced by cells from the bone marrow.⁴⁵ It is very important that reflux control is adequate. Patients with long segments of Barrett's oesophagus ablated with APC therapy, and those who have persistent acid and bile reflux, are more prone to recurrence after one year of follow up.⁴⁶

Endoscopic ablation: results

The method of ablation does not appear to be crucial to overall outcome. The endoscopic appearance is often gratifying (fig 3, 4). Tables 2 and 3 present the results of endoscopic mucosal ablation.

Table 2 Photodynamic therapy of high grade dysplasia and early carcinoma in Barrett's oesophagus ^{51–54}						
Photosensitiser	High grade dysplasia			Early adenocarcinoma		
	No of patients	Eradication of dysplasia (%)	Follow up (months)	No of patients	Eradication of cancer (%)	Follow up (months)
Photofrin	181	77–100	12–46	56	41–83	15–32
mTHPC	4	100	27	58	74	2–48
ALA	15	100	1–44	37	77–100	9.9–36

mTHPC, m-tetrahydroxyphenyl chlorine; ALA, 5-aminolaevulinic acid.

Table 3 Thermal and photothermal ablation of high grade dysplasia and early carcinoma in Barrett's oesophagus^{32, 47-49}

Device	High grade dysplasia			Early adenocarcinoma		
	No of patients	Eradication of dysplasia (%)	Follow up (months)	No of patients	Eradication of cancer (%)	Follow up (months)
Argon plasma coagulation	17	80-100	20	3		
KTP laser	4	100	10	2	100	10
Nd YAG laser +MPEC	18	73	12	15	94	12

KTP, potassium titanyl phosphate; NdYAG, neodymium yttrium aluminium garnet; MPEC, multipolar electrocoagulation.

Histopathology

Endoscopic mucosal resection does allow the possibility of assessment of the adequacy of resection, and formal assessment of margins of excision, and the deep invasiveness of the tumour. Mucosal ablation does not afford this opportunity, depending on full assessment prior to destruction with ultrasound and, possibly in the future, with OCT. It is important to assess in some detail the histopathological outcomes. Appearances are similar irrespective of the method of ablation. The most concerning feature following PDT and thermal ablation is the finding of endoscopically unsuspected glandular mucosa, both superficially and buried under the neosquamous epithelium (fig 5). The implication of this is that the end point of treatment is not a normal endoscopic appearance. All of those patients treated endoscopically for dysplasia or early cancer must receive lifelong biopsy surveillance. In addition, some of these patients have developed invasive cancer under the neosquamous epithelium.³⁶ There are several patterns associated with neosquamous regeneration.⁵⁵ First is the formation of squamous islands associated with openings of oesophageal squamous gland ducts. We have confirmed that squamous islands are universally associated with oesophageal gland duct epithelium.⁴³ Secondly, there may be long stretches of squamous epithelium growing over glandular mucosa. Thirdly, there may be apparent squamous metaplasia within Barrett's glandular mucosa (fig 6). This latter appearance suggests the existence of a pluripotential stem cell within the columnar mucosa, which is capable of differentiation along a squamous lineage under the correct environmental conditions. Thus there would appear to be several possible mechanisms for the neosquamous re-epithelialisation:

encroachment from adjacent squamous epithelium, squamous metaplasia within Barrett's mucosa itself from pluripotential stem cells, regrowth from squamous lined ducts of the oesophageal mucus gland, and possibly repopulation by circulating stem cells.⁴⁵⁻⁵⁵ The concern that the cancer risk is only reduced and not abolished is appropriate and a further compelling argument that treatment may need to be repeated and surveillance must continue. The risk of neoplastic progression may not be confined to the buried concealed metaplastic dysplastic glands but also occurs in neosquamous epithelium. Oncogenic pluripotential stem cells may have survived and produced malignant squamous cell lineages.

There was a very interesting finding in a blinded randomised trial of ALA PDT where the irradiation source was green light (510 nm).⁵⁶ There was a striking lack of buried glandular epithelium. Green light will penetrate only a short way and is of higher energy. The full significance of this finding remains to be examined further and exploited in therapy.

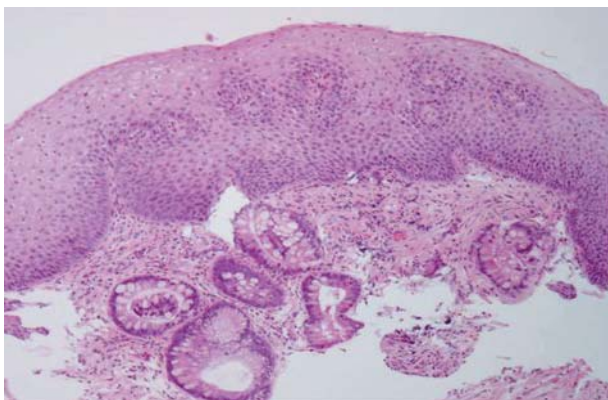


Figure 5 An endoscopically normal appearing area of neosquamous re-epithelialisation with buried glands.

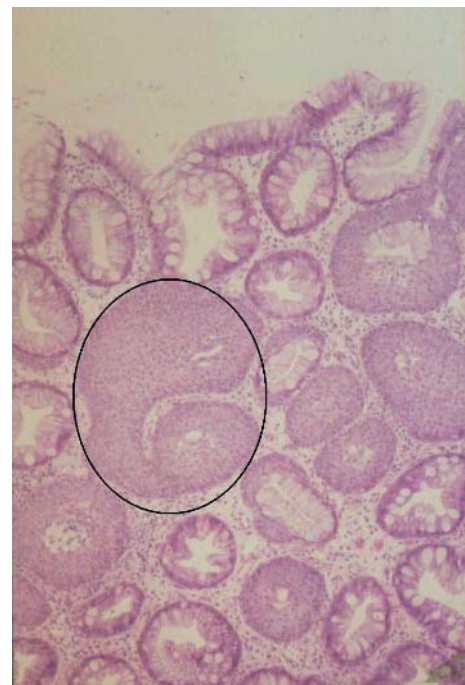


Figure 6 Squamous metaplasia is seen to have occurred within Barrett's glands (an example has been circled). There are also surrounding metaplastic Barrett's mucosa. This was a biopsy taken three months after photodynamic therapy using 5-aminolaevulinic acid from endoscopically appearing normal oesophageal mucosa.

Table 4 Complications after oesophageal endoscopic mucosal resection

	Major haemorrhage (%)	Minor haemorrhage (%)	Stricture (%)	Perforation (%)
Ell ²⁶ (64 patients)	–	12.5	–	–
Seewald ⁶⁵ (12 patients)	–	13	17	–
Noguchi ⁸⁰ (33 patients)	3	–	9	9
Ahmad ⁸¹ (19 patients)	–	11	–	–
Takeshita ⁸² (56 patients)	3.5	–	3.5	2
Nijhawan ⁸³ (25 patients)	–	–	–	–
Buttar ⁸⁴ (17 patients)	–	6	–	–

THE RATIONALE FOR ENDOSCOPIC MUCOSAL RESECTION

The main shortcoming of endoscopic ablation is the absence of histology on the removed specimen. The problem of subjectivity and sampling error is currently very real.^{57–58} Endoscopic ultrasound has proven to be little better than chance in differentiating early from advanced Barrett's adenocarcinoma, with an overall accuracy of only 61%.^{59–60} Assessment of lymph node involvement may also be unreliable by endoscopic ultrasound as enlarged mediastinal nodes are commonly found in patients with Barrett's. Fine needle aspiration cytology from enlarged mediastinal nodes may also be unreliable. The risk of a falsely negative result was 20% in a series of advanced cancers.^{61–63} The performance of fine needle aspiration in early cancer, with lower rates of positive lymph nodes, is likely to be worse.

THE EVOLUTION OF ENDOSCOPIC MUCOSAL RESECTION

Originally endoscopic mucosal resection was reserved for patients who were considered to be an unacceptable surgical risk. However, in the first large series of endoscopic mucosal resection for early Barrett's cancers, 51 of 64 patients were younger than 70 years.²⁶ In this study, 34 of the 35 smaller lesions (average size 9 mm) could be removed endoscopically although one third of lesions required more than one resection. The success rate was lower in the 29 patients with larger lesions. In this group, most lesions (16/29) could not be completely removed endoscopically even after 2–3 attempts. Two years later, the three year follow up results have been published. Metachronous lesions had developed in 30% of patients.⁶⁴ It was concluded that endoscopic mucosal resection was appropriate for discrete lesions. PDT was recommended for high grade dysplasia without a visible lesion.

This view has been challenged; 12 patients with high grade dysplasia but without a visible lesion had attempted removal of the entire Barrett's segment. This was achieved by removing an average of 3.8 cm² of Barrett's mucosa over 2–3 sessions. During the nine month follow up period, no metachronous lesions were found. However 2/12 patients developed oesophageal strictures which required dilatation.⁶⁵

COMPLICATIONS OF ENDOSCOPIC MUCOSAL RESECTION

Complication rates reported after oesophageal endoscopic mucosal resection are shown in table 4. Series reporting on the removal of small lesions (<1 cm/diameter) have few or no complications. The study with the greatest incidence of complications reported on the removal of all visible Barrett's epithelium (average size 38 mm).

Incomplete resections may be quoted as an adverse event. However, this may not always be the case. If lateral margins

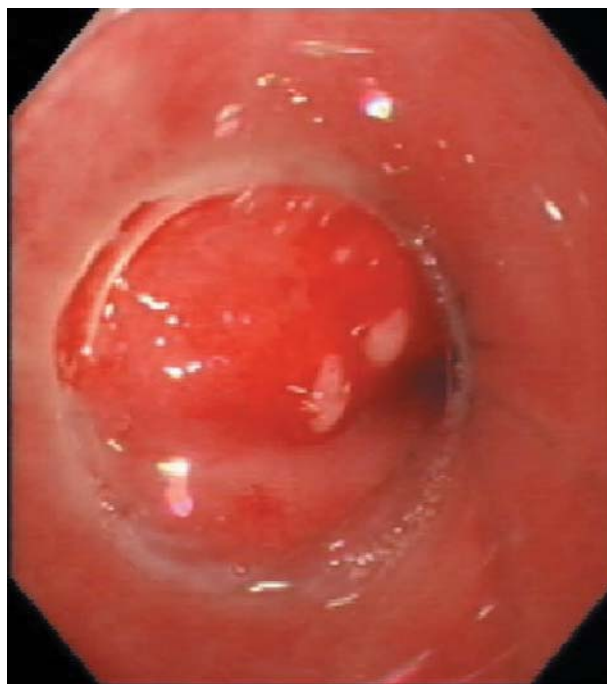


Figure 7 Area of dysplastic Barrett's oesophagus viewed through the suction cup on the endoscope prior to endoscopic mucosal resection.

were positive (40% of cases), patients usually underwent further mucosectomies rather than more radical therapy.⁶⁴ However, patients with lesions invading deeper than 500 µm into the submucosa (measured from the muscularis mucosa) are at greater risk of nodal metastases. A Japanese multi-centre analysis of 1690 lesions has reported on the risk of metastases in patients with early oesophageal squamous carcinomas. Lesions which had started to invade through the muscularis mucosa were associated with a 19% risk of nodal metastases; lesions invading deeper than the superficial one third of the submucosa were associated with a 44% risk.⁶⁶

THE TECHNIQUE OF ENDOSCOPIC MUCOSAL RESECTION

Most oesophageal endoscopic mucosal resections are carried out using the "suction cap technique" (fig 7) first described in 1993.⁶⁷ The advantage of this technique is that it can be performed by one endoscopist with a single assistant. The main disadvantage is that the technique becomes expensive if piecemeal resections are carried out. The snare usually loses its shape after the first resection and a new one is usually required for each cut. To solve this problem and to make the procedure faster, the use of a banding device was described a few years later.^{68–69} With this technique a variceal

multi-banding device is used to ligate each mucosal bleb. These are then cut (above or below the band) using a more sturdy snare which retains its shape. A further shortcoming of the aspiration cap method is that oval mucosal defects are produced, often with intervening islands of intact Barrett's mucosa. Attempting to remove these slim strips of remaining mucosa by the cap technique is hazardous and may risk perforation. At the General Infirmary in Leeds, the majority of lesions referred are large (>1 cm) and most resections are carried out with the "strip biopsy technique/pull within the snare technique" using a double channel endoscope.^{70 71} The advantage is the control over targeting and the size of resection; the drawback is that it requires one endoscopist and two assistants to enable simultaneous lifting and cutting. In the oesophagus, techniques are being developed to achieve the removal of larger pieces of mucosa en bloc. An ingenious device relies on suction to lift the mucosa to allow a cutting wire to be passed through the submucosal plane.⁷² Metachronous lesions are common²⁶ and there is a need for continued surveillance. The situation is analogous to polypectomy follow up in the colon.

Currently, the ideal method of treatment is debated, with advocates for ablation and for endoscopic resection. A pragmatic approach utilises both. For macroscopically visible lesions, endoscopic mucosal resection allows full pathological assessment with removal of the lesion. If the patient has a long segment with the possibility of multifocal disease, this is best treated with PDT. Following complete ablation of the segment there are often residual areas remaining. These can be destroyed using the argon plasma coagulator/multipolar electrocoagulator or photothermal laser therapy.

COMPARATIVE CLINICAL TRIALS

The most important, and very high quality, study addressed the fundamental problem of cancer prevention in patients with high grade dysplasia. It is only reported in abstract and has just been completed. Long term follow up is required as it will impact on cancer prevention strategy. The photosensitiser used was photofrin. There was rigorous quality control in this multicentre multinational study. All patients had a rigorous protocol biopsy regimen with a central laboratory pathological assessment. The patients, all of whom were confirmed to have high grade dysplasia in Barrett's oesophagus, were randomised (2:1) such that 138 had PDT and omeprazole and 70 received omeprazole only. Patients could receive up to three photodynamic treatments of the area of dysplasia and Barrett's oesophagus on separate occasions. It is very instructive to note that over 485 patients (with a diagnosis of high grade dysplasia) had to be screened to enter 208 patients with confirmed high grade dysplasia. After 24 months of follow up, ablation of all areas of high grade dysplasia was noted in 76.8% of patients after PDT versus 38.6% in the omeprazole group ($p < 0.0001$). After two years, 53% of patients remained with no evidence of high grade dysplasia (PDT) and all of the patients treated by omeprazole had relapsed. After a mean follow up of 24.2 months, 13.0% of patients (PDT) had disease progression to cancer compared with 28% after a mean follow up of 18.6 months ($p = 0.006$).⁷³ The major problem (PDT group) was stricture formation in 36%, with photosensitivity (usually mild) in 68%. Although the data are only preliminary, it clearly establishes that PDT is now a highly effective treatment for the eradication of high grade dysplasia in Barrett's oesophagus.

There has been a preliminary randomised comparison of APC and photofrin PDT. PDT was performed at one session while APC required a mean of three sessions (range 1–6 sessions). Dysplasia was eradicated in 10 of 13 (77%) patients treated with PDT and 11 of 16 patients (69%) after APC. Photosensitivity was seen in two (15%) PDT patients whereas three (19%) patients treated with APC had dysphagia, pain, and fever.⁷⁴ A recent randomised trial compared ALA PDT following continuous light and fractionated irradiation, and APC thermal coagulation for the ablation of patients with low grade dysplasia (8) and no dysplasia (32) in Barrett's oesophagus.⁷⁵ The results showed that the mean endoscopic reduction of Barrett's oesophagus at six weeks was 51% for ALA with continuous irradiation, 86% following fractionated irradiation, and 93% following APC treatment. A further study has also shown that complete ablation of Barrett's epithelium following APC treatment occurred in 97% of patients compared with only 24% of patients treated with ALA PDT.⁷⁶

A comparative study of APC and multipolar thermocoagulation has shown that the latter resulted in fewer treatment sessions with significantly more patients achieving histological ablation. The study examined 52 patients with between 2 and 7 cm of Barrett's oesophagus without cancer or high grade dysplasia and followed up with six monthly endoscopies for up to four years.⁷⁷

Summary

The rationale for early detection and endoscopic intervention in patients with Barrett's oesophagus that are at risk of malignant degeneration is becoming increasingly self evident.

- ▶ The annual incidence of oesophageal carcinoma is rising at approximately 0.9% and is centred in the UK.
- ▶ Gastro-oesophageal reflux disease and Barrett's oesophagus are identifiable intermediaries.
- ▶ High grade dysplasia in Barrett's oesophagus is currently the best marker for malignant degeneration.
- ▶ Endoscopic and pathological certainty of dysplasia is difficult and challenging.
- ▶ Symptomatic oesophageal adenocarcinoma has a very poor prognosis.
- ▶ Current strategies of detection and intervention at cancer diagnosis have failed to significantly impact on the disease.
- ▶ A new paradigm of seeking out patients with premalignant phenotypes, followed by endoscopic ablation, is required.
- ▶ Endoscopic PDT has been shown in a randomised trial to significantly reduce the incidence of oesophageal carcinoma in patients with high grade dysplasia.
- ▶ Other endoscopic methods may also be effective, and endoscopic mucosal resection provides vital local staging and eradication of early disease.
- ▶ It is important to note that most patients with metaplastic Barrett's oesophagus will not die of oesophageal adenocarcinoma.
- ▶ Chemoprevention trials hold the promise of identifying societal and generalisable strategies for the management of those in the population with metaplastic Barrett's oesophagus.

CONCLUSIONS

It is quite possible to remove abnormal areas, and indeed resurface the entire lower oesophagus, in a patient with Barrett's oesophagus using a variety of endoscopic techniques. The question remains, who should be treated? Many studies have looked at treating metaplastic Barrett's, which can be easily ablated. Currently, it is not widely used or recommended for patients with metaplasia only.

Treatment is usually restricted to patients with high grade dysplasia at risk of malignant degeneration or early Barrett's adenocarcinoma. Other strategies are being explored for the large numbers of patients with Barrett's metaplasia. Treatment of dysplasia demands an "obsession with regression" whereas "prevention of progression" is the correct approach for metaplasia (personal observation, Professor Neil Shepherd). Most patients in this latter group can have excellent symptom control on proton pump inhibitor therapy. Prevention of progression is being addressed in a clinical trial.

Barrett's oesophagus appears to be a marker for the development of cancer.⁷⁸ There is now a minimally invasive solution to eradication of Barrett's oesophagus when it presents a significant preneoplastic potential. Identification of the "bad Barrett's" is being addressed by molecular methods and optical detection methods without biopsy.⁷⁹ Once a dysplastic "bad Barrett's" segment is identified, then endoscopic therapy should be considered as a realistic and useful option.



Conflict of interest: declared (the declaration can be viewed on the Gut website at <http://www.gut.com/supplemental>).

Authors' affiliations

H Barr, Cranfield Postgraduate Medical School, Gloucestershire Royal Hospital, Gloucester, UK

N Stone, Biophotonics Unit, Cranfield Postgraduate Medical School, Gloucestershire Royal Hospital, Gloucester, UK

B Rembacken, Leeds General Infirmary, Leeds, UK

REFERENCES

- Wei JT, Shaheen NJ. The changing epidemiology of esophageal adenocarcinoma. *Semin Gastrointest Dis* 2003;**14**:112-27.
- El Serag. The epidemic of esophageal adenocarcinoma. *Gastroenterol Endosc Clin N Am* 2002;**31**:421-40.
- Mason AC, Eloubeidi MA, el Serag. Temporal trends in survival of patients with esophageal adenocarcinoma. 1973-1997. *Gastroenterology* 2001;**122**:A30.
- Barr H, Fitzgerald RC. Ablative mucosectomy is the procedure of choice to prevent Barrett's cancer. *Gut* 2003;**52**:14-17.
- Attwood SEA, Morris CD. Who defines Barrett's oesophagus: endoscopist or pathologist. *Eur J Gastroenterol* 2001;**13**:97-9.
- Falk GW. Barrett's esophagus. *Gastroenterology* 2002;**122**:1569-91.
- Shepherd NA. Dysplasia in Barrett's oesophagus. *Acta Endoscopica* 2000;**30**:123-32.
- Jankowski JA, Harrison RF, Perry I, et al. Barrett's metaplasia. *Lancet* 2000;**356**:2079-85.
- Riddell RH, Goldman H, Ransohoff D. Dysplasia in inflammatory bowel disease. Standardised classification with provisional clinical application. *Hum Pathol* 1983;**14**:931-66.
- Reid BJ, Haggitt RC, Rubin CE, et al. Observer variation in the diagnosis of dysplasia in Barrett's esophagus. *Hum Pathol* 1988;**19**:166-78.
- Haggitt RC. Barrett's esophagus, dysplasia, and adenocarcinoma. *Hum Pathol* 1994;**25**:982-93.
- Schlemper RJ, Riddell RH, Kato Y, et al. The Vienna classification of gastrointestinal epithelial neoplasia. *Gut* 2000;**47**:251-5.
- Montgomery E, Bronner MP, Goldblum JR, et al. Reproducibility of the diagnosis of dysplasia in Barrett's oesophagus: A reaffirmation. *Hum Pathol* 2001;**32**:368-78.
- Montgomery E, Goldblum JR, Greenson JK, et al. Dysplasia as a predictive marker for invasive carcinoma in Barrett's esophagus: A follow-up study based on 138 case from a diagnostic variability study. *Hum Pathol* 2001;**32**:379-88.
- Schnell TG, Sontag SJ, Chejfec G, et al. Long term non-surgical management of Barrett's esophagus with high-grade dysplasia. *Gastroenterology* 2001;**120**:1607-19.
- Ormsby AH, Petras RE, Henricks WH, et al. Observer variation in the diagnosis of superficial esophageal adenocarcinoma. *Gut* 2002;**51**:671-6.
- Alderson D. Observer variation in the diagnosis of superficial esophageal adenocarcinoma: another spanner in the works. *Gut* 2002;**51**:620-1.
- Zaninotto G, Parenti AR, Ruol A, et al. Oesophageal resection for high-grade dysplasia in Barrett's oesophagus. *Br J Surg* 2000;**87**:1102-5.
- Kara MA, Bergman JGHM, Tytgat GNJ. Follow-up for high-grade dysplasia in Barrett's oesophagus. *Gastrointest Endosc Clin N Am* 2003;**13**:513-33.
- Cossentino MJ, Wang RKH. Barrett's esophagus and risk of esophageal adenocarcinoma. *Semin Gastrointest Dis* 2003;**14**:128-35.
- Buttar NS, Wang KK, Sebo TJ, et al. Extent of high-grade dysplasia in Barrett's esophagus correlates with risk of adenocarcinoma. *Gastroenterology* 2001;**120**:1630-9.
- O'Sullivan GC, Sheehan D, Clarke Q, et al. Micrometastases in esophagogastric cancer: high detection rate in resected rib segments. *Gastroenterology* 1999;**116**:543-8.
- Yusoff IF, Sahai AV. Staging esophageal adenocarcinoma. *Semin Gastrointest Dis* 2003;**14**:146-54.
- Holscher AH, Bollschweiler E, Schneider PM, et al. Early adenocarcinoma in Barrett's oesophagus. *Br J Surg* 1997;**84**:1470-3.
- May A, Gunter E, Rath F, et al. Accuracy of staging in early esophageal cancer using high resolution endoscopy and high resolution endoscopy: a comparative, prospective, and blinded trial. *Gut* 2004;**53**:634-40.
- Ell C, May A, Gossner L, et al. Endoscopic mucosal resection of early cancer and high-grade dysplasia in Barrett's esophagus. *Gastroenterology* 2000;**118**:670-7.
- Ackroyd R, Brown NJ, Stephenson TJ, et al. Ablation treatment for Barrett esophagus: what depth of tissue destruction is needed. *J Clin Pathol* 1999;**52**:509-12.
- Bamford K, James J, Barr H, et al. Electromagnetic simulation of laser-induced fluorescence in bronchial tissue and predicted optical scattering behaviour. *Opt Imaging Tech Biomonitoring IV* 1998;**3567**:18-28.
- Johnston MH. Cryotherapy and other newer techniques. *Gastrointest Endosc Clin N Am* 2003;**13**:491-504.
- Sampliner RE. Multipolar electrocoagulation. *Gastrointest Endosc Clin N Am* 2003;**13**:449-55.
- Barham CP, Shepherd N, Barr H. Regression of Barrett's epithelium using argon gas coagulation and acid suppression. *Gut* 1996;**39**:114.
- Franchimont D, Van Laethem J-L, Deviere J. Argon plasma coagulation in Barrett's oesophagus. *Gastrointest Endosc Clin N Am* 2003;**13**:457-66.
- Deviere J. Argon plasma coagulation therapy for ablation of Barrett's oesophagus. *Gut* 2002;**51**:763-4.
- Morris CD, Byrne JP, Armstrong GRA, et al. Prevention of neoplastic progression of Barrett's oesophagus by endoscopic argon beam plasma ablation. *Br J Surg* 2001;**88**:1357-62.
- Dix AJ, Barr H. Photothermal ablation of metaplastic columnar-lined (Barrett's) oesophagus, experimental studies for safe endoscopic laser therapy. *Prog Biomed Optics* 1996;**2922**:275-80.
- Barr H. Barrett's esophagus: treatment with 5-aminolevulinic acid photodynamic therapy. *Gastrointest Endosc Clin N Am* 2000;**10**:421-38.
- Barr H, Shepherd NA, Dix A, et al. Eradication of high grade dysplasia in columnar-lined (Barrett's) oesophagus using photodynamic therapy with endogenously generated protoporphyrin IX. *Lancet* 1996;**348**:584-5.
- Heier SK, Rothman KA, Heier LM, et al. Photodynamic therapy for obstructing esophageal cancer: light dosimetry and a randomized comparison with Nd:YAG laser therapy. *Gastroenterology* 1995;**109**:63-72.
- Barr H, Krasner N, Boulos PB, et al. Photodynamic therapy for colorectal cancer: a quantitative pilot study. *Br J Surg* 1990;**77**:93-6.
- Gossner L, May A, Stolle M, et al. KTP laser destruction of dysplasia and early cancer in columnar-lined Barrett's esophagus. *Gastrointest Endosc* 1999;**49**:8-12.
- Tan WC, Fulljames C, Stone N, et al. Photodynamic therapy using 5-aminolevulinic acid for oesophageal adenocarcinoma associated with Barrett's metaplasia. *J Photochem Photobiol B Biology* 1999;**53**:75-80.
- Li H, Walsh TN, O'Dowd G, et al. Mechanisms of columnar metaplasia and squamous regeneration in experimental. *Barretts Esophagus Surg* 1994;**115**:176-81.
- Coad RA, Warner PJ, Barr H, et al. On the genesis of Barrett's oesophagus: A three dimensional study of the relationship between oesophageal gland ducts, Barrett's esophagus and associated squamous islands. *Br J Cancer* 2004;**91**:P105.
- Van den Boogert J, Van Hillegersberg R, De Bruin RWF, et al. A rat model for Barrett's oesophagus and prospects for photodynamic therapy. *Eur J Gastroenterol Hepatol* 1997;**9**:A53.
- Sarosi G, Brown G, Jaiswal K, et al. Reflux-damaged esophageal epithelium is replaced by cells derived from bone marrow in a rat model of Barrett's esophagus. *Gastroenterology* 2004;**126**:A49.
- Basu KK, Pick B, Bale R, et al. Efficacy and one year follow-up of argon plasma coagulation therapy for ablation of Barrett's oesophagus: factors determining persistence and recurrence of Barrett's epithelium. *Gut* 2002;**51**:776-80.
- Morris CD, Byrne JP, Armstrong GRA, et al. Prevention of neoplastic progression of Barrett's esophagus by argon beam plasma ablation. *Br J Surg* 2001;**88**:1357-62.

- 48 **Van Laethem JL**, Jagodzinski R, Peny MO, *et al*. Argon plasma coagulation in the treatment of Barrett's high-grade dysplasia and in situ adenocarcinoma. *Endoscopy* 2001;**33**:257–61.
- 49 **Sharma P**, Jaffe P, Bhattacharya A, *et al*. Fate of high-grade dysplasia at 1 year after endoscopic ablation with Nd:YAG laser and electrocautery. *Am J Gastroenterol* 2000;**95**:79–82.
- 50 **Weston AP**. The use of lasers in Barrett's esophagus. *Gastrointest Endosc* 2003;**57**:467–81.
- 51 **Overholt BF**, Panjehpour M, Halberg DL. Photodynamic therapy of Barrett's esophagus with dysplasia and/or early stage carcinoma: long-term results. *Gastrointest Endosc* 1998;**48**:193–8.
- 52 **Gossner L**, Stolte M, Stroke R, *et al*. Photodynamic therapy of high-grade dysplasia and early stage carcinomas by means of 5-aminolaevulinic acid. *Gastroenterology* 1998;**114**:447–55.
- 53 **Gossner L**, May A, Pech O, *et al*. Photodynamic therapy of Barrett's esophagus with dysplasia or early cancer. *Gastroenterology* 1999;**116**:G1811.
- 54 **Javadi B**, Watt P, Krasner N. Photodynamic therapy (PDT) for oesophageal dysplasia and early carcinoma with mTHPC (m-tetrahydroxyphenyl chlorin): a preliminary study. *Laser Med Sci* 2002;**17**:51–6.
- 55 **Biddlestone LR**, Barham CP, Wilkinson SP, *et al*. The histopathology of treated Barrett's esophagus. *Am J Surg Pathol* 1998;**22**:239–45.
- 56 **Ackroyd R**, Brown NJ, Davis MF, *et al*. Photodynamic therapy for dysplastic Barrett's oesophagus: a prospective, double blind, randomised, placebo-controlled trial. *Gut* 2000;**47**:613–17.
- 57 **Falk GW**, Rice TW, Goldblum TR, *et al*. Jumbo biopsy forceps protocol still misses unsuspected cancer in Barrett's esophagus with high-grade dysplasia. *Gastrointest Endosc* 1999;**49**:170–6.
- 58 **Peters FTM**, Ganesh S, Kuipers EJ, *et al*. Endoscopic regression of Barrett's oesophagus during omeprazole treatment; a randomised double blind study. *Gut* 1999;**45**:489–94.
- 59 **Wang K**, Norbash A, Geller A, *et al*. Endoscopic ultrasonography in the assessment of Barrett's esophagus with high grade dysplasia or carcinoma. *Gastroenterology* 1996;**110**:A611.
- 60 **Scotiniotis IA**, Kochman ML, Lewis JD, *et al*. Accuracy of endoscopic ultrasound in the evaluation of Barrett's esophagus and high-grade dysplasia or intramucosal carcinoma. *Gastrointest Endosc* 2001;**54**:689–96.
- 61 **Canto MIF**, Cruz-Correa MR, Heitmler RF, *et al*. What is the accuracy of endoscopic ultrasound lymph node staging in patients with Barrett's esophagus and high grade dysplasia or early cancer? A prospective study with implications for endoscopic therapy. *Gastrointest Endosc* 2001;**53**:AB171.
- 62 **Buttar N**, Wang K, Lutzke L, *et al*. The use of endoscopic ultrasonography in Barrett's esophagus. *Gastrointest Endosc* 2001;**53**:AB172.
- 63 **Wiersema MJ**, Wiersema LM, Khushro Q, *et al*. Combined endosonography and fine-needle aspiration cytology in the evaluation of gastrointestinal lesions. *Gastrointest Endosc* 1994;**40**:199–206.
- 64 **May A**, Gossner L, Pech P, *et al*. Local endoscopic therapy for intraepithelial high-grade neoplasia and early adenocarcinoma in Barrett's oesophagus: acute-phase and intermediate results of a new treatment approach. *Eur J Gastroenterol Hepatol* 2002;**14**:1085–91.
- 65 **Seewald S**, Akaraviputh T, Seitz U, *et al*. Circumferential endoscopic mucosal resection and complete removal of Barrett's epithelium: a new approach to management of Barrett's esophagus containing high-grade intraepithelial neoplasia and intramucosal carcinoma. *Gastrointest Endosc* 2003;**57**:854–9.
- 66 **Kodama M**, Kakegawa T. Treatment of superficial cancer of the esophagus: a summary of responses to a questionnaire on superficial cancer of the esophagus in Japan. *Surgery* 1998;**123**:432–9.
- 67 **Inoue H**, Takeshita K, Hori H, *et al*. Endoscopic mucosal resection with a cap-fitted panendoscope for esophagus, stomach, and colon mucosal lesions. *Gastrointest Endosc* 1993;**39**:58–62.
- 68 **Chaves DM**, Sakai P, Mester M, *et al*. A new endoscopic technique for the resection of flat polypoid lesions. *Gastrointest Endosc* 1996;**40**:224–6.
- 69 **Fleischer DE**, Dawsey S, Tio TL, *et al*. Tissue band ligation followed by snare resection (band and snare): a new technique for tissue acquisition in the esophagus. *Gastrointest Endosc* 1996;**44**:68–72.
- 70 **Tada M**, Murakami A, Karita M, *et al*. Endoscopic resection of early gastric cancer. *Endoscopy* 1993;**25**:445–50.
- 71 **Martin TR**, Onstad GR, Silvis SE, *et al*. Lift and cut biopsy technique for submucosal sampling. *Gastrointest Endosc* 1976;**23**:29–30.
- 72 **Radu A**, Grosjean P, Fontollet C, *et al*. Endoscopic mucosal resection in the esophagus with a new rigid device: an animal study. *Endoscopy* 2004;**36**:298–305.
- 73 **Overholt BF**, Lightdale CJ, Wang K, *et al*. International multicenter partially blinded randomised study of the efficacy of photodynamic therapy (PDT) using porfimer sodium (PDR) for the ablation of high-grade dysplasia (HGD) in Barrett's esophagus (BE): Results of 24 month follow-up. *Gastroenterology* 2003;**124**(suppl 1):151.
- 74 **Kapoor N**, Ragunath K, Raman VS, *et al*. Endoscopic ablation of dysplastic Barrett's oesophagus comparing argon plasma coagulation and photodynamic therapy: long term results of a randomised prospective trial. *Gut* 2005;**54**(Suppl II):A33.
- 75 **Hage M**, Sieresma PD, van Dekken H, *et al*. 5-Aminolevulinic acid photodynamic therapy versus argon plasma coagulation for ablation of Barrett's oesophagus: a randomised trial. *Gut* 2004;**53**:785–90.
- 76 **Kelly CJ**, Ackroyd R, Brown NJ, *et al*. Endoscopic ablation of Barrett's oesophagus: a randomised controlled trial of photodynamic therapy vs argon plasma coagulation. *Aliment Pharmacol Ther* 2004;**20**:1289–96.
- 77 **Dulai G**, Jensen DM, Cortina G. MPEC is superior to APC in sustained ablation of Barrett's. *Gastroenterology* 2004;**126**:A35.
- 78 **Solaymani-Dodaran M**, Logan RFA, West J, *et al*. Risk of oesophageal cancer in Barrett's oesophagus and gastro-oesophageal reflux. *Gut* 2004;**53**:1070–4.
- 79 **Kendall C**, Stone N, Shepherd N, *et al*. Raman spectroscopy a potential tool for the objective identification and classification of neoplasia in Barrett's oesophagus. *J Pathol* 2003;**200**:602–9.
- 80 **Noguchi H**, Naomoto Y, Kondo H, *et al*. Evaluation of endoscopic mucosal resection for superficial esophageal carcinoma. *Surg Lap Endoscopy Percut Tech* 2000;**10**:343–50.
- 81 **Ahmad NA**, Kochman ML, Long WB, *et al*. Efficacy, safety and clinical outcomes of endoscopic mucosal resection: a study of 101 cases. *Gastrointest Endosc* 2002;**55**:390–6.
- 82 **Takeshita K**, Tani M, Inoue H, *et al*. Endoscopic treatment of early oesophageal or gastric cancer. *Gut* 1997;**40**:123–7.
- 83 **Nijhawan PK**, Wang KK. Endoscopic mucosal resection for lesions with endoscopic features suggestive of malignancy and high-grade dysplasia within Barrett's esophagus. *Gastrointest Endosc* 2000;**52**:328–32.
- 84 **Buttar NS**, Wang KK, Lutzke LS, *et al*. Combined endoscopic mucosal resection and photodynamic therapy for esophageal neoplasia within Barrett's esophagus. *Gastrointest Endosc* 2001;**54**:682–8.