



Best practice No 162

The histological reporting of melanoma

Eduardo Calonje

Abstract

The incidence of malignant melanoma has increased steadily over the past 30 years and this type of malignancy is the leading cause of death from cutaneous malignant disease. Cutaneous malignancies, including melanoma, can be detected at a very early stage and a cure is possible with prompt detection and treatment. In recent years, and mainly because of increased awareness of the early detection of melanoma, histopathologists have been exposed more and more to melanocytic lesions. Therefore, it is essential that histopathologists are able to provide a report to the clinician that conveys relevant information in a concise and precise manner. This paper provides a set of guidelines aimed at helping histopathologists with the gross and microscopic description and diagnosis of malignant melanoma.

(J Clin Pathol 2000;53:587-590)

Keywords: melanoma; histological reporting; diagnosis

Accurate clinical and histological diagnosis of cancer is essential for the adequate management of patients. The report issued by the pathologist should not only provide useful diagnostic information but several parameters that might be important in assessing prognosis. A histological report should be as accurate and thorough as possible.¹ Although some of the information provided might not be of immediate relevance to a given patient, its importance might become apparent at a later date, especially when used in conjunction with information gathered from large numbers of patients in prospective or retrospective studies.

The incidence of malignant melanoma has increased steadily over the past 30 years,² more so than for any other type of malignancy other than lung cancer in women. It remains the leading cause of death in cutaneous malignant disease. However, it can be detected at a very early stage. This, coupled with the fact that the five year survival rate in patients with stage I or II disease is very high (~ 80%), makes it particularly important that we concentrate our efforts on early diagnosis and treatment. Partly because of this, and because of campaigns to educate the general public about early detection of suspicious lesions, pathologists are increasingly ex-

posed to biopsies of melanocytic lesions. This makes it imperative that histopathology reports on melanoma provide as much relevant and clear information as possible to the clinician. What follows is a set of guidelines for the reporting of malignant melanoma, including gross and microscopic description.

Information required in the request form

- (1) Name of the patient.
- (2) Date of birth.
- (3) Hospital number.
- (4) Name of surgeon/clinician and address to which the report should be sent.
- (5) Clinical details including sex, site and accurate description of lesion (outline, colour, measurement).
- (6) Primary, recurrent, or metastatic lesion.
- (7) Patient with or without atypical mole syndrome.
- (8) Family history of skin cancer, particularly malignant melanoma.
- (9) Type of biopsy (shave, punch, simple excision, wide excision).
- (10) Date of biopsy.

All specimens should be adequately fixed in neutral buffered formalin and fixation time should be around 24 hours. Small biopsies can be allowed less fixation time if results are needed urgently. Frozen sections or cytology should not be requested in the diagnosis of primary or recurrent cutaneous malignant melanoma. Suspicious melanocytic lesions should be removed by an excisional biopsy with narrow margins including subcutaneous fat. Small biopsies such as a punch are only justified in exceptional circumstances, as a diagnostic tool for very large lesions or lesions in difficult locations (subungual). Incisional biopsies do not seem to increase the risk of recurrence or metastasis. However, incisional biopsies not only make the evaluation of important prognostic factors (particularly depth of invasion) difficult, but are often non-representative and might lead to errors in diagnosis.

Gross description³

- (1) Type of biopsy.
- (2) Dimensions of the specimen in millimetres (length, breadth, thickness).
- (3) If the specimen is marked with stitches, describe their position in detail.

Department of
Dermatopathology, St
John's Institute of
Dermatology, St
Thomas's Hospital,
London SE1 7EH, UK
E Calonje

Correspondence to:
Dr Calonje
email: jcalonje@
umds.ac.uk

Accepted for publication
7 January 2000

- (4) Length and breadth of pigmented lesion in millimetres.
 - (5) Symmetry, regularity, colour, and outline of pigmented lesion.
 - (6) Presence or absence of nodule and measurement of the latter.
 - (7) Presence or absence of ulceration.
 - (8) Associated lesions (scar, areas of depigmentation).
 - (9) Measurement of distance between edge of lesion and nearest excision margin.
 - (10) If possible, photograph the macroscopic specimen.
- (2) Growth phase (radial or vertical).
 - (3) Presence or absence of ulceration and measurement in millimetres.
 - (4) Clark's level (I, II, III, IV, V).
 - (5) Breslow's thickness (in millimetres).
 - (6) Mitotic rate/mm².
 - (7) Host immune response (tumour infiltrating lymphocytes).
 - (8) Regression.
 - (9) Microsatellites.
 - (10) Vascular invasion.
 - (11) Perineural infiltration.
 - (12) Predominant cell type: epithelioid, spindle cell, small cell, other (including spitzoid).
 - (13) Desmoplasia.
 - (14) Association with a coexistent benign melanocytic lesion. If there is an association, the type of naevus should be recorded (ordinary, congenital, blue, Spitz, etc).
 - (15) Adequacy of excision (this should include measurement of the nearest excision margin).

All specimens from excisional biopsies should be sectioned transversely in a "sliced bread" pattern (fig 1A). The first section should be taken from the centre of the lesion and this should be followed by sectioning the whole specimen every 2–3 mm. All of the specimen should be processed. The use of cruciate section sampling is not recommended because this only allows for the evaluation of part of the specimen in some of the blocks. The latter makes assessment of the architecture difficult (fig 1B). Punch biopsies including small lesions can be embedded intact or cut through the middle and both halves embedded and processed.

For many years, it has been recommended that re-excision specimens should be processed completely, with cutting of blocks every 2–3 mm. However, if a lesion has been excised completely, and there are no macroscopic abnormalities other than a scar, processing of the whole specimen does not seem to offer any additional information and increases the costs for the laboratory. Therefore, it seems more logical to take a single representative section from the centre of the specimen.⁴ If the original lesion was excised incompletely, or there is macroscopic evidence of a residual lesion, it is recommended that blocks every 2–3 mm through the whole scar are cut and embedded.

Microscopic description³

- (1) Histogenetic subtype: superficial spreading melanoma; lentigo maligna melanoma; acral lentiginous melanoma; nodular melanoma; desmoplastic; or unclassifiable.

Additional features that are worth noting in the histological report include necrosis and presence of any other atypical or variable features (for example, heterologous differentiation).

HISTOGENETIC SUBTYPE

Traditionally, every effort is made to try to classify a given melanoma into one of several well defined histogenetic subtypes (superficial spreading, lentigo maligna, acral lentiginous, nodular).^{5,6} Each of these types defines a pattern of radial growth phase (see below) and, except for nodular melanoma, all have a biphasic growth pattern. By definition, nodular melanoma is always in vertical growth phase and lacks a recognisable radial growth phase. It has increasingly been recognised that classification of melanomas into histogenetic subtypes has no significant prognostic relevance. However, its use is still recommended because these subtypes define well known clinicopathological entities. Assigning a given lesion into a particular subtype should be based on strict histological criteria and not on isolated attributes such as location. Not uncommonly, a melanoma cannot be classified into a specific histogenetic subtype and these lesions should be put into a separate category (unclassified). Any histogenetic type of melanoma can develop a prominent desmoplastic component, but this is most commonly seen in lentigo maligna melanoma and acral lentiginous melanoma. A melanoma should only be classified as desmoplastic if this component predominates. In most cases, desmoplastic and neurotropic melanomas are closely associated. It has been suggested that desmoplastic melanomas have a higher recurrence rate, a lower incidence of lymph node metastasis, and a better prognosis than conventional melanomas.⁷ However, this has been challenged recently in a large series showing that there is no difference between the recurrence and survival rate of desmoplastic melanoma and other cutaneous melanomas.⁸

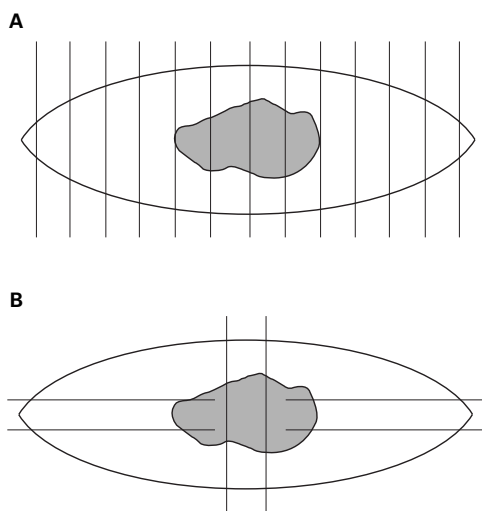


Figure 1 (A) Excisional biopsies of melanocytic lesions should be sectioned transversely, starting from the centre, and all blocks should be processed. (B) Excisional biopsies of melanocytic lesions should not be sectioned by cruciates because this makes interpretation of the architecture of the lesion more difficult.

GROWTH PHASE

The definition of growth phase into radial and vertical derives from the concept of tumour progression and has been of practical relevance in defining lesions with potential for metastatic disease.⁹⁻¹¹ The concept of tumour progression is based on the assumption that a given cancer develops the potential for metastasis by going through different evolutionary steps. Some of these steps should be identifiable on histological examination, and lesions in radial growth phase represent an early step in tumour progression, with no potential for metastasis.¹² All in situ melanomas are by definition in radial growth phase. Invasive radial growth phase refers to individual or small clusters of melanocytes in the papillary or, very rarely, superficial reticular dermis (fig 2A). These melanocytes should have similar features to those seen in the epidermis—no nests should be larger than any epidermal nests and mitotic figures should be absent. Most lesions in invasive radial growth phase are Clark's level II and have a depth of invasion less than 0.76 mm. Accurate categorisation of a lesion as being in radial growth phase is extremely important because the survival of these patients is 100%. Vertical growth phase defines tumours that are characterised by a nodule or plaque filling the papillary dermis with or without extension into the reticular dermis (fig 2B). Differences between dermal and epidermal melanocytes are easy to determine and mitotic figures can be identified. In cases in which there are doubts about assigning a tumour to a given category, the lesion should be classified as being in vertical growth phase. Problems in classification might arise when, as a result of cross sectioning, large nests of melanocytes connected to the epidermis or to adnexal structures appear to be free in the dermis. However, serial sectioning often resolves this problem.

ULCERATION

The presence of ulceration has been regarded as an independent prognostic factor for prediction of melanoma survival.¹³ Ulceration, particularly if ≥ 3 mm in diameter, has been associated with

decreased survival. It is important to make sure that the ulceration is not the result of trauma. This is not always possible and might require close clinicopathological correlation.

CLARK'S LEVELS OF INVASION⁶

There are five categories of invasion: (1) Level I. The melanoma cells are confined to the epidermis. (2) Level II. Refers to invasion of the papillary dermis by melanoma cells. However, these cells do not fill and expand the papillary dermis. Most tumours classified as level II are in radial growth phase. (3) Level III. Tumour cells expand and fill the papillary dermis. These melanomas are almost always in vertical growth phase. (4) Level IV. Melanoma cells infiltrate the reticular dermis. (5) Level V. Tumour cells infiltrate the subcutaneous tissue. It has been clearly demonstrated that increasing levels of invasion correlate with a decrease in survival. However, although this is true when this feature is analysed as a single variable, the same result has not been obtained in most multivariate analyses.

TUMOUR THICKNESS^{11 14 15}

The depth of invasion is measured in millimetres from the top of the granular cell layer to the deepest melanoma cell. Measurement can be difficult in cases with ulceration or prominent epidermal hyperplasia. In the former situation, the thickness of the tumour should be measured from the base of the ulcer to the deepest melanoma cell. When epidermal hyperplasia is present, the depth of invasion might be overestimated, and this should be pointed out in the histological description. Involvement of adnexal structures by melanoma cells should not be included in the measurement. Tumour thickness is the single most important prognostic indicator in melanoma. However, a small number of patients with thin melanoma die of disease and some patients with thick melanoma survive.


MITOTIC RATE^{11 16 17}

There is no standard method for counting mitoses and, until recently, the mitotic rate was expressed as the number of mitoses/10 high power fields. The size of the field varies in different microscopes and this method is therefore inaccurate. In recent years, the preferred method is to report the mitotic count/mm². When a mitotic count is performed, sampling error should be avoided. Therefore, fields with the highest number of mitotic figures should be identified before the count is done. The mitotic rate correlates inversely with survival and it has been found to provide independent predictive prognostic information.

HOST IMMUNE RESPONSES

This attribute is difficult to evaluate and to standardise. It has been proposed that the presence of a host immune response should be divided into infiltrative (tumour infiltrating lymphocytes) or non-infiltrative.¹¹ This is because the presence of tumour infiltrating lymphocytes is an important independent pre-

Figure 2 (A) Radial growth phase melanoma. No mitoses are seen in the dermis and the clusters of intradermal tumour cells are smaller than the largest intraepidermal nest. (B) Vertical growth phase. Mitotic figures are seen in the dermis and there are clusters of dermal melanocytes that are larger than the intraepidermal nests (usually larger than 20 to 25 cells) (these figures are from an original drawing by the late Dr NP Smith).



dictive prognostic factor in melanoma—the presence of such lymphocytes correlates with improved survival.

REGRESSION

This feature is often seen in melanoma and it is characterised in its early stages by a prominent mononuclear cell infiltrate. This is followed by the destruction of tumour cells and melanophages, vascular proliferation, and fibrosis. The association between the presence of regression and prognosis is controversial. Although the reports are contradictory, it seems that the rate of metastasis is higher in thin melanomas with extensive regression.¹⁸

MICROSATELLITES

These are defined as the presence of aggregates of melanoma cells away from the main tumour. These aggregates have been defined arbitrarily as being ≥ 0.05 mm in diameter. Serial sections should always be examined to make sure that there are no connections to the main tumour. Microsatellites probably represent local metastases. It is controversial whether the presence of microsatellites is an independent prognostic factor.¹⁹ However, they do appear to be associated with an increase risk of local recurrence.

VASCULAR INVASION

This feature is not an independent factor in predicting prognosis in patients with melanoma.¹¹ Vascular invasion can be difficult to identify on haematoxylin and eosin stained sections and false positives are often a problem. With the use of immunohistochemistry, it is possible to increase the detection of vascular invasion, but this is an expensive procedure that might require evaluation of multiple sections and offers little advantage.

PERINEURAL INVASION

Infiltration of nerves by tumour cells should be recorded. A melanoma should only be classified as neurotropic if this is the dominant feature.

PREDOMINANT CELL TYPE

This feature is described mainly for the sake of completeness, but there is some suggestion that melanomas with a pure spindle cell morphology have a better prognosis.²⁰ However, this has not been validated adequately.

ASSOCIATION WITH A COEXISTENT BENIGN MELANOCYTIC LESION

Recording this finding can provide useful information for epidemiological studies. Often, it is very difficult to decide whether there is a residual benign component in a given lesion.

ASSESSMENT OF EXCISION MARGINS

Measurement of the distance from both lateral and the deep excision margins should be provided in millimetres.

Special techniques

Immunohistochemical stains including S-100, HMB-45, and MART-1 are useful in the differential diagnosis between melanocytic and non-melanocytic tumours. They should not,

however, be used to distinguish between benign and malignant melanocytic lesions. The importance of calculating the proliferation index with antibodies such as MIB-1 has not been adequately assessed and it should therefore not be used in the routine reporting of melanocytic lesions.

Since the introduction of immunohistochemistry, electron microscopy has been relegated as an aid in the differential diagnosis of poorly differentiated melanocytic tumours. At present, electron microscopy has no role in the routine reporting of melanocytic lesions.

Other techniques that have been used in the evaluation of melanocytic lesions include DNA flow cytometry and cytogenetics. DNA ploidy²¹ has little value in the evaluation of melanocytic lesions because many melanomas have a diploid DNA content. Cytogenetics is still an experimental technique and its value as an aid in the diagnosis of melanocytic tumours remains to be proved because of the heterogeneity of these lesions.

- 1 Miller JM, Slater DN. Do histopathology reports of primary cutaneous melanoma contain enough essential information? *J Clin Pathol* 1996;**49**:202–4.
- 2 Slominski A, Ross J, Mihm M. Cutaneous melanoma pathology, relevant prognostic indicators and progression. *Br Med Bull* 1995;**51**:548–69.
- 3 Cochran AJ, Bailly C, Cook M, et al. Recommendations for the reporting of tissues removed as part of the surgical treatment of cutaneous melanoma. *Hum Pathol* 1997;**28**:1123–5.
- 4 Martin HM, Birkin AJ, Theaker JM. Malignant melanoma re-excision specimens—how many blocks? *Histopathology* 1998;**32**:362–7.
- 5 Clark WH, Jr, Elder DE, van Horn M. The biologic forms of malignant melanoma. *Hum Pathol* 1986;**17**:443–50.
- 6 Clark WH, Jr, From L, Bernardino EA, et al. The histogenesis and biologic behavior of primary human malignant melanoma of the skin. *Cancer Res* 1969;**29**:705–27.
- 7 Carlson JA, Dickersin GR, Sober AJ, et al. Desmoplastic neurotropic melanoma: a clinicopathologic analysis of 28 cases. *Cancer* 1995;**75**:478–94.
- 8 Quinn MJ, Crotty KA, Thompson JF, et al. Desmoplastic and desmoplastic and neurotropic melanoma: experience with 280 patients. *Cancer* 1998;**83**:1128–35.
- 9 Clark WH, Jr, Elder DE, Guerry D IV, et al. A study of tumor progression: the precursor lesions of superficial spreading and nodular melanoma. *Hum Pathol* 1984;**15**:1147–65.
- 10 Clark WH, Jr. Tumor progression and the nature of cancer. *Br J Cancer* 1991;**64**:631–44.
- 11 Clark WH, Jr, Elder DE, Guerry D IV, et al. Model predicting survival in stage I melanoma based on tumor progression. *J Natl Cancer Inst* 1989;**81**:1893–904.
- 12 DuPont Guerry IV, Synnestvedt M, Elder DE, et al. Lessons from tumor progression: the invasive radial growth phase of melanoma is common, incapable of metastasis, and indolent. *J Invest Dermatol* 1993;**100**:342S–5S.
- 13 Balch CM, Wilkerson JA, Murad TM, et al. The prognostic significance of ulceration of cutaneous melanoma. *Cancer* 1980;**45**:3012–17.
- 14 Breslow A. Thickness, cross-sectional areas and depth of invasion in the prognosis of cutaneous melanoma. *Ann Surg* 1970;**172**:902–8.
- 15 Jeffrey I, Royston P, Sowter C, et al. Prognostic value of tumour thickness in cutaneous malignant melanoma. *J Clin Pathol* 1983;**36**:51–6.
- 16 Vollmer RT. Malignant melanoma: a multivariate analysis of prognostic factors. *Pathol Annu* 1989;**24**:383–407.
- 17 Eldh J, Boeryd B, Peterson LE. Prognostic factors in cutaneous malignant melanoma stage I: a clinical, morphological and multivariate analysis. *Scand J Plast Reconstr Surg* 1978;**12**:243–55.
- 18 Ronan SG, Eng AM, Briele HA, et al. Thin malignant melanomas with regression and metastases. *Arch Dermatol* 1987;**123**:1326–30.
- 19 Leon P, Daly JM, Synnestvedt M, et al. The prognostic implications of microscopic satellites in patients with clinical stage I melanoma. *Arch Surg* 1991;**126**:1461–8.
- 20 Van der Esch EP, Cascinelli N, Preda F, et al. Stage I melanoma of the skin: evaluation of prognosis according to histologic characteristics. *Cancer* 1981;**48**:1668–73.
- 21 Herzberg A. Significance of DNA ploidy in cutaneous lesions. *Arch Dermatol* 1992;**128**:663–78.